

## Case Report

DOI: 10.22067/veterinary.v9i1.62662 Received: 2017-Feb-17  
Accepted after revision: 2017-Jun-15  
Published online: 2017-Aug 30

# Histopathologic report of infestation by *Centrocestus formosanus* in Iranian grass carp and common carp

Annahita Rezaie<sup>a</sup>, Zahra Tulaby Dezfuly<sup>b</sup>, Mehrzad Mesbah<sup>c</sup>, Amin Ranjbar<sup>b</sup>

<sup>a</sup> Department of Pathobiology, Faculty of Veterinary Medicine, Shahid Chamran University of Ahvaz, Ahvaz, Iran

<sup>b</sup> Department of Aquatic Animals Health, Faculty of Veterinary Medicine, Shahid Chamran University of Ahvaz, Ahvaz, Iran

<sup>c</sup> Department of Clinical Sciences, Faculty of Veterinary Medicine, Shahid Chamran University of Ahvaz, Ahvaz, Iran

### Keywords

*Centrocestus formosanus*, grass carp, common carp, histopathology

### Abstract

Flukes cause severe and lethal diseases in various animals comprising fish. Both adult and larval stages are found in fish. Centrocestiasis is an infection of the fish gills by heterophyid trematode *Centrocestus formosanus*. In summer 2014, 35 fingerling grass carp and 30 common carp weight of 6 grams were referred to the veterinary hospital of Shahid Chamran University of Ahvaz. In the wet mount of the skin, mild infection of trichodina was observed. Wet mount of grass carp gills revealed large number of parasitic cysts between gill filaments. The cysts were quite clear and contained pear-shaped parasites. In histopathological examination, filaments of gill were thick and distorted. According to the wet mount and histopathologic results, metacercariae was characterised to belong to heterophyidae, *C. formosanus*.

### Abbreviations

*C. formosanus*: *Centrocestus formosanus*  
H&E: Hematoxylin and Eosin

IRANIAN JOURNAL OF VETERINARY SCIENCE AND TECHNOLOGY

Tel: +98 51 3880 3742 Fax: +98 51 3876 3852  
Web: ijvst.um.ac.ir Email: ijvst@um.ac.ir

### Corresponding author:

Annahita Rezaie  
Department of Pathobiology,  
Faculty of Veterinary Medicine,  
Shahid Chamran University of Ahvaz, Ahvaz, Iran

Email: a.rezaie@scu.ac.ir

## Introduction

Centrocestiasis is an infection of the fish gills by heterophyid trematode *Centrocestus formosanus* which has been described in 1924 from adult parasites recovered from natural and experimental definitive hosts in Taiwan [19].

*C. formosanus* is an exotic parasite native to Asia that has been introduced into warm water systems around the world. This digenean requires three separate hosts to complete its complex life cycle. Snail, often red-rim melania *Melanooides tuberculatus*, is the first intermediate host that utilizes the gills of various fishes as second intermediate host [3]. The cycle is completed when a fish infected with metacercariae is eaten by a definitive host, piscivorous birds or fish-eating mammals. In the digestive tract of definitive hosts, the adult trematode develops [5]. It appears that this parasite has a low intraspecific variability since no marked morphological and biometrical differences among worms from the different zoogeographical areas were observed [24].

Metacercarial infection in fish is with the subsequent economic loss. Metacercariae may affect growth and survival, or disfigure fish so that they lose their market cost as a food or ornamental product [10].

Metacercariae have been described from brackish and marine waters in some countries in Asia, particularly from South Korea [2, 7, 25]. Mood et al. (2010) reported *Centrocestus formosanus* metacercarial infection in the gills of different ornamental fish species including Dwarf gourami (*Colisalalia*), Goldfish (*Carassius auratus*), Red fin shark (*Labeo erythrurus*) and Arowana (*Osteoglossum bicirrhosum*) from Iran. Also, Shoabi Omrani et al. (2010) reported the infection with *Ascocotyle tenuicollis* in the imported platy fish in Iran.

The aim of this report was to present clinicopathologic description of Heterophyidae metacercarial *Centrocestus formosanus* infection in the gill of cyprinids in Iran.

## Case description

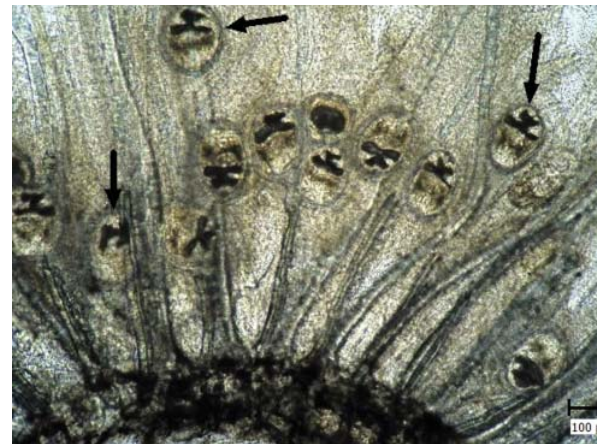
In summer 2014, 35 fingerling grass carp and 30 common carp with an average weight of 6 grams were referred to the veterinary hospital of Shahid Chamran University of Ahvaz, Department of Aquatic Animals Health. The clear clinical symptom was mouth breathing. According to the owner's statements, the fish had high mortality.

Wet mount of the skin and gills were prepared and studied by light microscopy.

All fish samples submitted for histopathology were fixed in 10% buffered formalin. The gill tissues were processed routinely, embedded in paraffin, sectioned, stained with Hematoxylin and Eosin (H & E), and examined using light microscopy [13].

In the wet mount of the skin, mild infestation of trichodina was observed. Wet mount of grass carp gills revealed large number of parasitic cysts between gill filaments. The parasitic cysts in wet mount of common carp gills were low. Infected gill filaments appeared shortened, thickened and severely damaged. A clear layer of tissue was observed surrounding the cyst. Also, fusions of the filaments were observed.

The cysts were quite clear and contained pear-shaped parasites with rapid movements (Figure 1). An X-shaped excretory bladder was seen (Figure 2A). Also, they had 32 circumoral spines around the oral sucker which were arranged in two rows



**Figure 1**

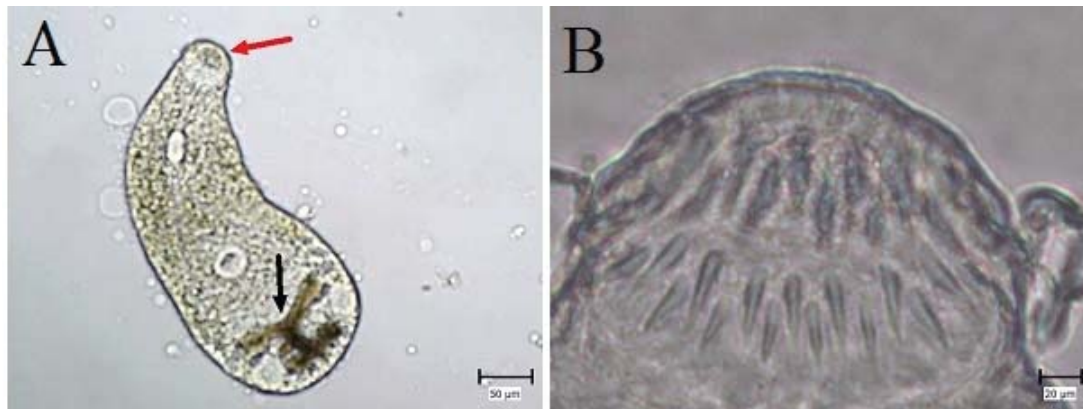Wet mount of grass carp gill infected with metacercariae of *C. formosanus*. Note different cysts which are located in the filaments (Arrows).

(Figure 2B).

Histopathologically, filaments of gill were thick, distorted, and also they were multifocal. This area was composed of proliferated cartilage and sections of parasite in the center (Figure 3A, B). These metacercarial cysts completely disrupted the normal gill morphology. According to wet mount and histopathologic results, metacercariae was characterized to be *C. formosanus*.

## Discussion

Unlike the majority of the digeneans, *C. for-*



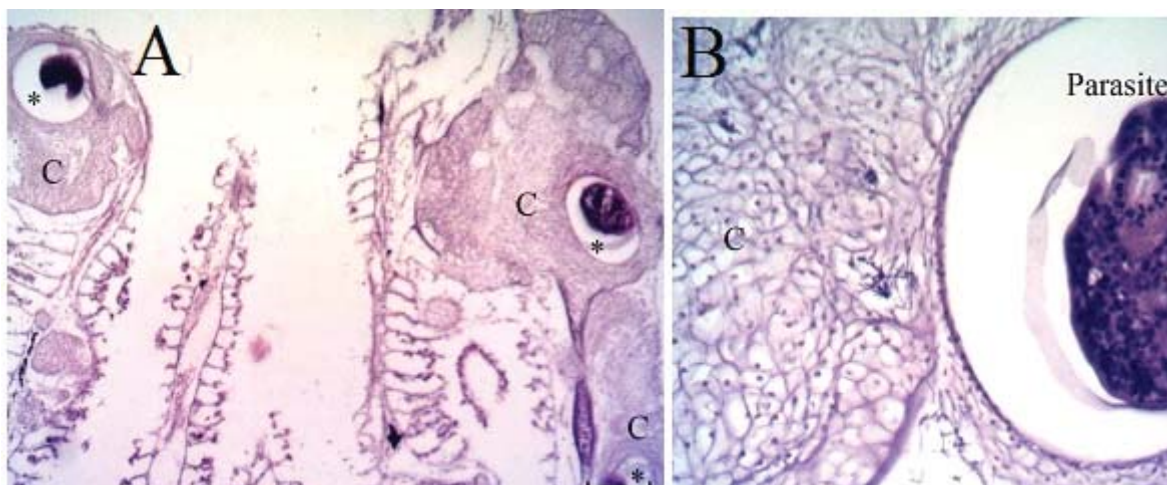
**Figure 2**  
Wet mount of grass carp gill. Metacercariae of *C. formosanus*. A: Note the X-shaped excretory vesicles (black arrow) and oral sucker (red arrow). B: Spines are located in two rows.

*mosanus* causes morbidity and mortality in many wild and cultured fish [24]. The cercariae of *C. formosanus* are highly pathogenic to piscine hosts because they encyst in the gills and cause respiratory problems, however this trematode is not highly pathogenic in mammals, they can cause intestinal pain, diarrhea, and chronic enterocolitis in man, or death in experimental animals if heavily infected [11].

A massive metacercariae infestation of gill with *C. formosanus* was the cause of farmed Cichlid fish's mortalities [23]. Lauckner (1984) showed that only a metacercariae of digenean trematode was sufficient to kill a fish larva. A *Centrocestus* species was the cause of mortality in affected common carp fry in India [17] and so the mortality of fish in this report was probably due to parasitic infestation.

Thien et al. (2007) found that severity of metacercarial infection was significantly correlated with the smaller body weights in common carp, so that small fish have a higher prevalence of metacercarial infection than larger fish [29]. The fingerlings are more susceptible to trematodes infection. This is may be due to their relatively thin skin, lack of previous contact to infection [12], less gill surface area, thus, requiring fewer metacercariae to cause greater disruption of respiratory process, and having slower defense response than larger fish [14]. Differences in the age-related quantity or structure of biochemical compounds expelled by fish might be another reason for higher infection in small fish [6].

Identification of the metacercariae was based on characteristic features (Shape of cysts, existence and size of suckers, and figure of excretory blad-



**Figure 3**  
Gill of grass carp. A: Note to distortion of gill lamellae due to multiple hyperplastic tissue (C) and parasitic cysts (asterisks). B: Parasite is obvious in the center of chondrodysplasia (C) (H & E).

der) [27]. In this case, X-shaped excretory bladder and 32 circumoral spines help to diagnose type of metacercariae which belongs to *C. formosanus*.

The histopathological changes of the gills were chondroblastic hyperplasia of the primary lamellae and fusion of them in the affected gill filaments. They envelope the cysts composing parasite. This histopathological finding was in agreement with Mitchell et al. (2000), Mitchell et al. (2002), Blazer and Gratzek (1985) and Olson and Pierce, (1997). The passage of the cercaria into the gill tissue and formation of a metacercariae induces a reactive chondroplasia and inflammation in the gill. The lesions vastly diminish respiratory capacity.

Exposing to unfavorable conditions for example environmental factors, and stress increase the parasite infection [8]. Recently Alves Pinto et al. (2015) reported that corticosteroid therapy increased development and fecundity of *C. formosanus* in treated mice in comparison with untreated mice. Thus, immunosuppressed host may spread fluke eggs in the environment and/or show greater severity of the disease caused by heterophyids, and perhaps other intestinal trematodes. Thus, the monitoring, diagnosis and treatment are essential.

In conclusion, this report described clinicopathologic characteristics of metacercarial *C. formosanus* infection in the gill of cyprinids in Iran. As the cysts remain for years and they are the source of infection for the definitive hosts [4], it might have important impacts on aquaculture. In order to prevent and control the infection, food safety in fish nurseries, are recommended by Phan et al. (2010), as keeping fish fry in cement or composite tanks in filtered water [28], and removal of the vector snail by using chemical molluscicides such as copper sulphate in fish ponds and circulation systems [26].

## Acknowledgements

The authors wish to thank Dr. Seyed Mohammad Mousavi for his consultation, and Research Council of Shahid Chamran University of Ahvaz for financial support.

## Author Contributions

Conceived and designed the experiments, performed the experiments, and wrote the paper: Z.T.D., M.M, A.Rajabi. Analyzed the data: A.Rezaei.

## Conflict of Interest

The authors have no conflict of interest to declare.

## References

- Blazer VS, Gratzek JB. Cartilage proliferation in response to metacercarial infections of fish gills. *Journal of Comparative Pathology*. 1985 1; 95 [2]:273-80.
- Chai JY, Lee SH. Food-borne intestinal trematode infections in the Republic of Korea. *Parasitology international*. 2002 30; 51 [2]:129-54.
- Fleming BP, Huffman DG, Bonner TH, Brandt TM. Metacercarial distribution of *Centrocestus formosanus* among fish hosts in the Guadalupe River drainage of Texas. *Journal of Aquatic Animal Health*. 2011 1; 23 [3]:117-24.
- Fried B, Graczyk TK, Tamang L. Food-borne intestinal trematodiasis in humans. *Parasitology Research*. 2004 1; 93 [2]:159-70.
- Gjurčević E, Petrinc Z, Kozarić Z, Kužir S, Gjurčević Kantura V, Vučemilo M, Džaja P. Metacercariae of *Centrocestus formosanus* in goldfish [*Carassius auratus* L.] imported into Croatia. *Helminthologia*. 2007 1; 44 [4]:214-6.
- Haas W. Physiological analysis of cercarial behavior. *The Journal of parasitology*. 1992 1:243-55.
- Joo CY. Infestation of larval trematodes from fresh-water fish and brackish-water fish in River Hyungsan, Kyungpook Province, Korea. *Kisaengch'unghak chapchi. The Korean journal of parasitology*. 1984; 22 [1]:78-84.
- Kadlec D, Šimková A, Jarkovský J, Gelnar M. Parasite communities of freshwater fish under flood conditions. *Parasitology Research*. 2003 1; 89 [4]:272-83.
- Lauckner G. Impact of trematode parasitism on the fauna of a North Sea tidal flat. *Helgoländer Meeresuntersuchungen*. 1984 1; 37 [1-4]:185-99.
- Leatherland JF. *Fish diseases and disorders*. Woo PT, editor. CABI; 2006.
- Lo CT, Lee KM. Infectivity of the cercariae of *Centrocestus formosanus* and *Haplorchis pumilio* [Digenea: Heterophyidae] in *Cyprinus carpio*. *ZOOLOGICAL STUDIES-TAIPEI*. 1996 1; 35: 305-9.
- Lun ZR, Gasser RB, Lai DH, Li AX, Zhu XQ, Yu XB, Fang YY. Clonorchiasis: a key foodborne zoonosis in

- China. The Lancet infectious diseases. 2005 31; 5 [1]:31-41.
13. Luna LG. Manual of histologic staining methods of the Armed Forces Institute of Pathology.
  14. McDonald DL, Bonner TH, Brandt TM, Trevino GH. Size susceptibility to trematode-induced mortality in the endangered fountain darter [*Etheostoma fonticola*]. *Journal of Freshwater Ecology*. 2006 1; 21 [2]:293-9.
  15. Mitchell AJ, Goodwin AE, Salmon MJ, Brandt TM. Experimental infection of an exotic heterophyid trematode, *Centrocestus formosanus*, in four aquaculture fishes. *North American Journal of Aquaculture*. 2002 1; 64 [1]:55-9.
  16. Mitchell AJ, Salmon MJ, Huffman DG, Goodwin AE, Brandt TM. Prevalence and pathogenicity of a heterophyid trematode infecting the gills of an endangered fish, the fountain darter, in two central Texas spring-fed rivers. *Journal of Aquatic Animal Health*. 2000 1; 12 [4]:283-9.
  17. Mohan CV, Shankar KM, Ramesh KS. Mortalities of juvenile common carp, *Cyprinus carpio* associated with larval trematode infection-a case study. *Journal of Aquaculture in the Tropics*. 1999; 14 [2]:137-42.
  18. Mood SM, Mousavi HE, Mokhayer B, Ahmadi M, Soltani M, Sharifpour I. *Centrocestus formosanus* metacercarial infection of four ornamental fish species imported into Iran. *Bull. Eur. Ass. Fish Pathol*. 2010 1; 30 [4]:146.
  19. Nishigori M. On a new trematode *Stamnosoma formosanus* n. sp., and its life history. *Taiwan Igakkai Zasshr*. 1924; 234:181-238.
  20. Olson RE, Pierce JR. A trematode metacercaria causing gill cartilage proliferation in steelhead trout from Oregon. *Journal of Wildlife Diseases*. 1997; 33[4]:886-90.
  21. Phan, VT., Ersboll, AK., Nguyen, KV., Madsen, H. and Dalsgaard, A. [2010] Farm-level risk factors for fish-borne zoonotic trematode infection in integrated small-scale fish farms in northern Vietnam. *PLoS Neglected Tropical Diseases*. 4, 742.
  22. Pinto HA, Mati VL, de Melo AL. Experimental centrocestiasis: Worm burden, morphology and fecundity of *Centrocestus formosanus* [Trematoda: Heterophyidae] in dexamethasone immunosuppressed mice. *Parasitology International*. 2015 31; 64 [5]:236-9.
  23. Ramadan RA, Sakr SF, El-Gamal RM. Prevalence and distribution of metacercariae of *Centrocestus* Sp., Nishigori, 1924, Trematoda: Heterophyidae on the gills and other organs of *Oreochromis niloticus* fingerlings. *Suez Canal Veterinary Medicine Journal [Egypt]*. 2002.
  24. Scholz T, Salgado-Maldonado G. The introduction and dispersal of *Centrocestus formosanus* [Nishigori, 1924] [Digenea: Heterophyidae] in Mexico: a review. *The American Midland Naturalist*. 2000; 143 [1]:185-200.
  25. Seo BS, Lee SH, Chai JY, Hong SJ. Studies on intestinal trematodes in Korea XIII. Two cases of natural human infection by *Heterophyopsis continua* and the status of metacercarial infection in brackish water fishes. *Kisaengch'unghak chapchi. The Korean journal of parasitology*. 1984; 22 [1]:51-60.
  26. Shoaibi Omrani B, Ebrahimzadeh Mousavi HA, Sharifpour I. Occurrence and histopathology of *Ascocotyle tenuicollis* metacercaria in gill of platyfish [*Xiphophorus maculatus*] imported to Iran. *Iranian Journal of Fisheries Sciences*. 2010; 9[3]:472-7.
  27. Sukantason KL, Sukontason K, Kuntalue B, Boonsriwong N, Piangjai S, Chaithong U, Vanittanakom P. Surface ultrastructure of excysted metacercariae of *Haplorchis taichui* [Trematoda: Heterophyidae].
  28. Thien CP, Dalsgaard A, Nhan NT, Olsen A, Murrell KD. Prevalence of zoonotic trematode parasites in fish fry and juveniles in fish farms of the Mekong Delta, Vietnam. *Aquaculture*. 2009 1; 295[1]:1-5.
  29. Thien PC, Dalsgaard A, Thanh BN, Olsen A, Murrell KD. Prevalence of fishborne zoonotic parasites in important cultured fish species in the Mekong Delta, Vietnam. *Parasitology Research*. 2007 1; 101[5]:1277-84.

DOI: 10.22067/veterinary.v9i1.62662

## گزارش هیستوپاتولوژی آلودگی توسط سنتروستوس فورموسانوس در کپور علف‌خوار و کپور

### معمولی ایران

آناهیتا رضایی<sup>۱\*</sup>، زهرا طولابی دزفولی<sup>۲</sup>، مهرزاد مصباح<sup>۲</sup>، امین رنجبر<sup>۲</sup>

<sup>۱</sup> گروه پاتوبیولوژی، دانشکده دامپزشکی، دانشگاه شهید چمران اهواز، اهواز، ایران

<sup>۲</sup> دانشجوی دکتری تخصصی بهداشت آبزیان، دانشکده دامپزشکی، دانشگاه شهید چمران اهواز، اهواز، ایران

<sup>۳</sup> گروه علوم درمانگاهی، دانشکده دامپزشکی، دانشگاه شهید چمران اهواز، اهواز، ایران

دریافت مقاله: ۱۳۹۵/۱۱/۲۹ پذیرش نهایی: ۱۳۹۶/۰۳/۲۵

### چکیده

ترماتودها منجر به بیماری‌های شدید و کشنده در حیوانات مختلف از جمله ماهیان شده و در هر دو مراحل بالغ و نوزادی در ماهیان یافت می‌شوند. سنتروستتیزیس یک عفونت مربوط به آبشش بوده که توسط ترماتود سنتروستوس فورموسانوس (C. *formosanus*) ایجاد می‌شود. در تابستان سال ۱۳۹۳، ۳۵ ماهی کپور علف‌خوار و ۳۰ کپور معمولی انگشت قد با وزن ۶ گرم به بیمارستان دامپزشکی دانشگاه شهید چمران اهواز، بخش بیماری‌های آبزیان ارجاع داده شد. در گسترش مرطوب تهیه شده از پوست، آلودگی خفیف با تریکودینا مشاهده شد. گسترش مرطوب آبشش‌های ماهیان کپور علف‌خوار تعداد زیادی انگل کیستی بین رشته‌های آبششی را نشان داد. کیست‌ها کاملاً شفاف بود و انگل گلابی شکلی درون هر کیست مشاهده شد. بررسی هیستوپاتولوژی، ضخیم شدن، خمیده شدن رشته‌های آبششی و مقاطع انگل‌ها را نشان داد. بر اساس نتایج حاصل از گسترش مرطوب و هیستوپاتولوژی، متاسرکر مشاهده شده مربوط به خانواده هتروفیده و سنتروستوس فورموسانوس بوده که منجر به مرگ و میر بالای ناشی از آلودگی انگلی شده بود.

**واژگان کلیدی:** سنتروستوس فورموسانوس، کپور علف‌خوار، کپور معمولی، هیستوپاتولوژی