



## Morphological aspects of the brain in the Indian grey mongoose (*Herpestes Edwardsii*)

Babak Rasouli, Soghra Gholami, Younes Kamali

Department of Basic Sciences, School of Veterinary Medicine, Shiraz University, Shiraz, Iran.

### ABSTRACT

Mongoose is a common name for 29 to 34 species in 14 genera of the family *Herpestidae* which are found in vast areas of southwestern Asia, especially southern Iran. Anatomical and morphological studies of the brain have always been of interest to the researchers in the field of anatomy, due to its high importance in various fields of veterinary and zoology. Because of the lack of information about the brain structure in wild carnivores, the present study was conducted to better understand the morphological features in Indian grey mongoose. For this purpose, 4 carcasses of adult mongooses were used. They were found in different areas of Fars province. The mongooses had died due to natural causes. The brain was carefully separated from the skull and the measurements and observations were made on different parts of it. In this study, it was found that the brain's structure has an ovoid appearance. Also, distinguished olfactory bulbs, deep transverse and longitudinal fissures, and relatively large cerebellar vermis were observed. According to the current study, it can be concluded that the anatomical features of the brain in the mongoose are similar to those of other carnivores and are in perfect harmony with the sensory and motor capabilities of the animal.

### Keywords

*anatomy, brain, mongoose, morphology*

Number of Figures: 2  
Number of Tables: 0  
Number of References: 13  
Pages: 73-76

Archive of SID

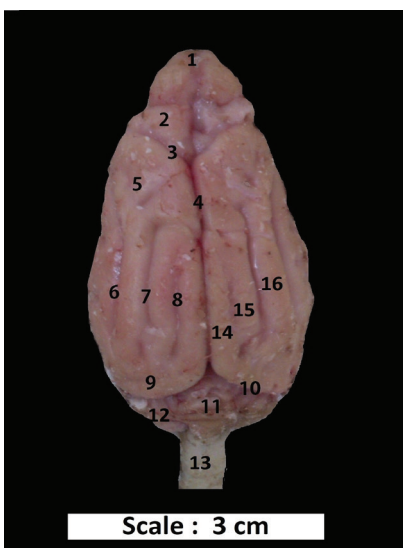
Different varieties of mongoose are relatively widespread geographically and are found in many areas in Iran [1, 2]. Due to a lack of information about the anatomy of the brain in mongooses, the present study was designed and conducted with the aim of an overview of the morphological aspects in the mature mongooses. To conduct the present study, 4 Indian grey mongooses were used for two years. The samples were cases that had recently died of natural causes and were abandoned in the wild, prepared from different areas of Fars province. The skull was opened completely and after separating meningeal layers, the morphological examinations were performed and the required images were taken.

From the dorsal view, in the caudal position of the transverse fissure, there was a relatively large cerebellum included a protrusive and developed vermis. The vermis area was greater than the cerebellar hemispheres and was separated from right and left cerebellar hemispheres by two shallow grooves. The vermis seemed stripped by numerous and arranged transverse grooves. The number of grooves in the samples were found to be 10 to 11. The grooves make the cerebellum seems like cauliflower despite its spherical shape. Moreover, the cerebellar hemispheres also include many irregular bulges and concavities in different directions that provide a stripped appearance (Figure 1). The morphological investigation of the cerebellum structure showed that it is similar to that in other carnivores and different from rodents [3,4,5]. The vermis is a bit larger than each cerebellum hemi-

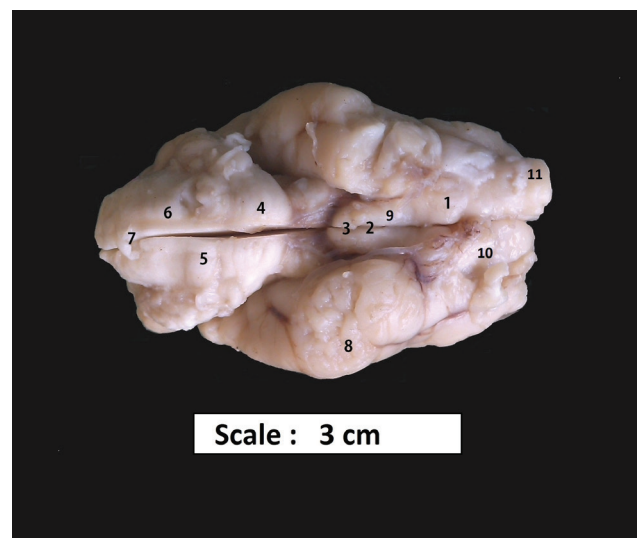
sphere, which shows the considerable balance and coordination of this animal in motion [6].

The two cerebral hemispheres in mongoose had relatively big and developed olfactory bulbs that could be observed on the frontal pole. The olfactory bulb on the right side seemed bigger in all samples. In the caudal side of the bulbs, there were frontal lobes and seemed relatively smaller. The frontal lobe was separated from the parietal lobe by a specific cruciate groove. The longitudinal and transverse fissures were clear and deep and the transverse fissure between the cerebrum and cerebellum was deeper compared to the longitudinal one. Since the frontal pole of the cerebral hemispheres was extremely pressed from the sides and the back pole is wider, the whole cerebrum and cerebellum hemispheres seem oval from the dorsal view. There were clear sulci and gyri on the outer surface (Figure 1).

The hemispheres look square and bulgy on frontal pole from the dorsal view in dogs. Nonetheless, the elongation of the brain structure is distinct in different dog breeds and follows the shape of the skull [7]. The general structure of cerebral hemispheres in cats looks spherical with no angles. Also, the olfactory bulbs in mongooses are big compared to the total size of the brain and this is consistent with the studies conducted on other carnivores [7,8]. No difference was found between mongoose and other carnivores in terms of the number and pattern of the gyri and sulci on the cerebral cortex (Figure 1). [9,10]. Although, due



**Figure 1.** Dorsal view of the brain in male mongoose. 1.Olfactory bulb, 2.Frontal lobe 3.Cruciate sulcus 4.Longitudinal fissure 5.Parietal lobe 6.Suprasylvian sulcus 7.Ectomarginal sulcus, 8.Marginal sulcus, 9.Occipital lobe, 10.Transverse Fissure,11. Vermis of cerebellum 12. Cerebellar hemisphere, 13.Spinal cord, 14.Mrginal gyrus, 15.Ectomarginal gyrus, 16.Ectosylvian gyrus.



**Figure 2.** Ventral view of the brain in male mongoose. 1.Olfactory tract, 2.Infundibulum, 3.Hypophysis, 4.Pons, 5.Trapezoid body, 6.Pyramid band, 7.Medulla oblongata, 8.Piriform lobe, 9.Optic chiasma, 10.Olfactory bulb, 11.Olfactory peduncle.

*Archive of SID*

to the smaller brain size in mongoose, no sylvian sulcus was seen from the lateral view of the brain.

The olfactory bulbs were in the most anterior area of the brain and the olfactory peduncle, as the holder and base of the olfactory bulb, was in the ventral position in the piriform lobe. From this view, the cerebral hemispheres seemed tangled and in triangle form. Moreover, the transverse fissure was the deepest at this view. Also, the occipital lobe that forms the occipital pole of the cerebral hemispheres covered the frontal half of the cerebral hemispheres dorsally. The corpus callosum was broad and sickle-shaped; it was the main identifiable interhemispherical structure on the seriate cuts and clearly distinguished the lining cortex from the internal cerebral segments. The hypothalamus and pituitary gland were also large and developed, as in other carnivores [8]. The medial surface of the thalamus formed the lateral boundary of the third ventricle and the caudal border of the thalamus was wider than the rostral border.

From the ventral view, the olfactory bulb and optic tract could not be observed clearly. There was an infundibulum pore at the caudal of these structures and a mammillary body was observed at the anterior position. The mammillary body was in the form of two bulges separated by a shallow groove. The structure was relatively big and reached the optic chiasma cranially. Following the brainstem, the pons and medulla oblongata appeared as bulges with their borders very clear as a transverse groove. The presence of numerous transverse fibers on the pons helped to identify its area from the medulla oblongata (Figure 2).

The medulla oblongata was wider in comparison to the brain dimensions and it was convex on the surface. The pyramidal bands that form the origin of medulla oblongata were not very clear. However, a trapezoid body was seen as a bulge of transverse fibers between the pons and the medulla oblongata. The longitudinal groove was on the ventral surface of these structures and continued to the beginning of the spinal cord. In fact, it was the rest of the ventral longitudinal groove of the spinal cord (Figure 2).

By looking at the brain from the ventral view, it was found that, like other Felines, the piriform lobe was large. The studies conducted on other mammals such as mice and horses show that the piriform lobe is small [3, 9,11]. Pons was in the shape of a bulge with numerous transverse fibers. The studies conducted on humans, mice and cats are consistent in this regard. However, the pons in the dog is flat and its bulge is not very clear [12,13].

The trapezoid body was observed as a bulge

similar to other carnivores between the pons and medulla oblongata [7, 8]. Since it is the origin of the acoustic nerve, the size of this area can be related to the highly developed auditory system in carnivores. Moreover, consistent with this property, a complicated auditory connection with various and continuous frequencies were reported in mongooses [2].

According to this study, it can be inferred that the morphological properties of mongoose brain is generally very similar to other carnivores and is consistent with the behavioral and social habits of the animal. The large olfactory bulb, trapezoidal body, and the vermis area in the brain is justifiable according to the smelling and hearing senses, and the animal's high balance in quick movements and grabbing the baits.

### Acknowledgments

The authors would like to thank the Shiraz University for financial support.

### Authors' Contributions

BR and YK performed the experiments. SG designed the research project and drafted the manuscript.

### Competing Interests

The authors declare that they have no conflicts of interest.

### References

1. Barun A, Hanson CC, Campbell KJ, et al. A review of small Indian mongoose management and eradications on islands. Island invasives eradication and management. IUCN, Gland, Switzerland 2011;7: 17-25.
2. Blanton JD, Anastasia MA, Murphy SM. Vaccination of Small Asian Mongoose (*Herpestes javanicus*) Against Rabies, J. Wildl. Dis. 2006; 42(3): 663-666.
3. Abraham MS, Muhammad YF, Ademola OA, et al. Comparative Anatomical Studies of the Cerebrum, Cerebellum, and Brainstem of Males Guinea pig (*Cavia porcellus*) and Rabbit (*Oryctolagus cuniculus*). J. Vet. Anat 2016; 9(2):1 -14.
4. Irimescu I, Bolfa P, Crisan M, et al. Macroscopical and histological aspects of the cerebellum in chinchillas, Agric. Agric. Sci. Procedia. 2015; 6: 350-357.
5. Treuting, PM, Dintzis SM, Comparative Anatomy and Histology, A Mouse and Human Atlas, 1st edition, Academic Press, Elsevier, New York 2012; 340-370.

*Archive of SID*

6. Jennings DP, 'Supraspinal control of posture and movement', in W.O. Reece, Dukes' Physiology of Domestic Animals, 1st ed. Cornell University Press 2004; 904-920.
7. Dyce KM, Sack WO, Wensing CJG. Textbook of Veterinary Anatomy. 5th ed. Philadelphia, US, Saunders. 2017: 479 - 490.
8. König HE, Leibich HG. Veterinary Anatomy of Domestic Mammals text book and color atlas, 3rd ed. Schluterschc. 2020 : 189 - 195.
9. Shoshani J, Kupsky WJ, Merchant GH, Elephant Brain. Part 1: Gross Morphology functions, comparative anatomy and evolution. Brain Res. Bulletin 2006; 70: 124-157.
10. Eric HC. Brain facts and figures. In: Neurosciences for Kids. 1st ed. University of Washington, Washington, America. 2006: PP: 1-8.
11. Ibe CS, Onyeansi BI, Hambolu JO. Functional morphology of the brain of the African giant pouched rat (*Cricetomys gambianus* Waterhouse, 1840), OJVR 2014; 81(1): 644 -647.
12. Pakozdy A, Angerer C, Klang A, et al. Gyration of the feline brain: localization, terminology and variability. Anat Histol Embryol 2014.; 44(6):422-7.
13. Danmaigoro A, Hena SA, Ibrahim AA, et al. Comparative Morphometry and Histological Studies of the Cerebellum of Catfish (*Clarias gariepinus*) and Tilapia (*Oreochromis niloticus*). J ALSI. 2016;7(4): 1-6.

**COPYRIGHTS**

©2021 The author(s). This is an open access article distributed under the terms of the Creative Commons Attribution (CC BY 4.0), which permits unrestricted use, distribution, and reproduction in any medium, as long as the original authors and source are cited. No permission is required from the authors or the publishers.

**How to cite this article**

Rasouli B, Gholami S, Kamali Y (2020). Morphological aspects of the brain in Indian grey mongoose (*Herpestes Edwardsii*). Iran J Vet Sci Technol. 12(2):73-76.

DOI: <https://doi.org/10.22067/ijvst.2020.39237>

URL: [https://ijvst.um.ac.ir/article\\_31151.html](https://ijvst.um.ac.ir/article_31151.html)



## مطالعه مقایسه ای آناتومی مغز در خدنگ هندی خاکستری (*Herpestes Edwardsii*)

بابک رسولی، صغری غلامی\*، یونس کمالی

گروه علوم پایه، دانشکده دامپزشکی، دانشگاه شیراز، شیراز، ایران.

### چکیده

خدنگیان خانواده ای از گوشتخواران می باشند که در نواحی وسیعی از جنوب ایران یافت می شوند. مطالعات آناتومیکی و مورفولوژیکی مغز به دلیل اهمیت بالای آن در زمینه های مختلف دامپزشکی و جانور شناسی همواره مورد توجه متخصصین علوم تشریح بوده است. به دلیل کمبود اطلاعات لازم پیرامون ساختمان مغز در گوشتخواران وحشی، مطالعه ی حاضر به منظور ادراک بهتر از ویژگی های کمی و آناتومیکی آن در خدنگ هندی خاکستری انجام گرفت. بدین منظور از لاشه ی ۸ قلاده خدنگ بالغ که در نواحی مختلف استان فارس بر اثر حوادث طبیعی مرده بودند، استفاده گردید. پس از آماده سازی لاشه و تزریق ماده فیکساتیو به داخل بطن های مغزی، ساختمان مغز به دقت از مجسمه جدا شده و اندازه گیری و مشاهدات لازم بر روی قسمت های مختلف آن صورت گرفت. در این مطالعه مشخص گردید که ساختمان مغز از نمای پشتی تخم مرغی شکل بوده و حباب بویایی، شیارهای عرضی و طولی عمیق و هم چنین مخچه و ناحیه کرمینه ی نسبتا بزرگ از ویژگی های آن به حساب می آمد. با توجه به مطالعه فوق می توان اینگونه نتیجه گرفت که ویژگی های آناتومیکی مغز در خدنگ شباهت زیادی با سایر گوشتخواران داشته و در هماهنگی کامل با قابلیت های حسی و حرکتی این حیوان است.

### واژگان کلیدی

آناتومی، مغز، خدنگ، مورفولوژی