



A rare case with the absence of a distinct common brachiocephalic trunk in an adult mixed-breed horse

Younes Kamali, Zabihollah Khaksar

Department of Basic Sciences, School of Veterinary Medicine, Shiraz University, Shiraz, Iran.

ABSTRACT

The only branch that detaches from the aortic arch of adult horses is the common brachiocephalic trunk. This report describes a rare case of the unusual arterial arrangement of the aortic arch in a female adult horse. The aortic arch was found to lack a common brachiocephalic trunk and had instead two branches, the first being a brachiocephalic trunk and the second being a left subclavian artery. The direct origin of the left subclavian artery from the aortic arch is very rare in horses and a similar case has not been reported previously. The potential embryologic and phylogenetic aspects of this variation are discussed.

Keywords

Common brachiocephalic trunk, horse, left subclavian artery

Abbreviations

BCT: Brachiocephalic trunk
LSA: Left subclavian artery
RSA: Right subclavian artery

Number of Figures: 2
Number of Tables: 0
Number of References: 16
Pages: 88-92

Archive of SID Introduction

During the growth of the embryo and fetus, the architecture of the great vessels cranial to the heart derived from the aortic arches, ventral aortae, and cranial parts of the dorsal aortae is altered by the cephalic folding and elongation of the neck. As a result, the aortic arch descends from the cervical region to its definitive position in the thorax. Several species-specific changes also take place that ultimately determine the final branching pattern of the aortic arch [1]. Therefore, depending on the species of animal, the number of the branches that arise directly from the aortic arch differs from three or four to one [2]. However, in domestic animals, two or three of these branches merge at their origins, reducing them to one or two [3]. The only branch that leaves the arch of the aorta in ungulates including equines and ruminants is the common brachiocephalic trunk (BCT) (Figure 1A) [4]. It in turn gives rise to the left subclavian artery (LSA) and the right subclavian artery (RSA) at the level of the second intercostal space or the third rib and the first rib, respectively. Then, it continues as the bicarotid trunk. In pigs, dogs, and cats, the arch of the aorta gives off two separate branches, namely the brachiocephalic trunk and the left subclavian artery [3].

In addition to clinical significance, the anatomic variations of the great vessels at the base of the heart of equines may be of great interest for the clarification of

the embryonic primordium. Hence, we here describe a rare case of an adult horse with the absence of the common brachiocephalic trunk and discuss the potential embryologic and phylogenetic aspects of this variation as well.

Case Presentation

During routine anatomical dissection of the large vessels within the mediastinum to teach veterinary gross anatomy, an unusual branching pattern of the aortic arch was observed in an adult mixed-breed mare, four years old. The case had a history of trauma and showed a severe cervical deviation (scoliosis) concaved to the left and lameness in the right forelimb. Due to unresponsiveness to treatment, it had been donated by its owner to the Anatomy Unit of Shiraz University. Following an injection of IV sodium pentobarbital (88 mg/kg), the horse was humanely euthanized by exsanguination and embalmed with standard formaldehyde solution. After opening the thoracic cavity, the lungs were removed and the pericardium covering the heart, aorta, and great vessels were carefully dissected. To test the arrangement of the aortic arch branches, an incision was made along the concave aspect of the aortic arch to see inside its lumen and determine whether the branches have a common or separate exit from the aorta [5].

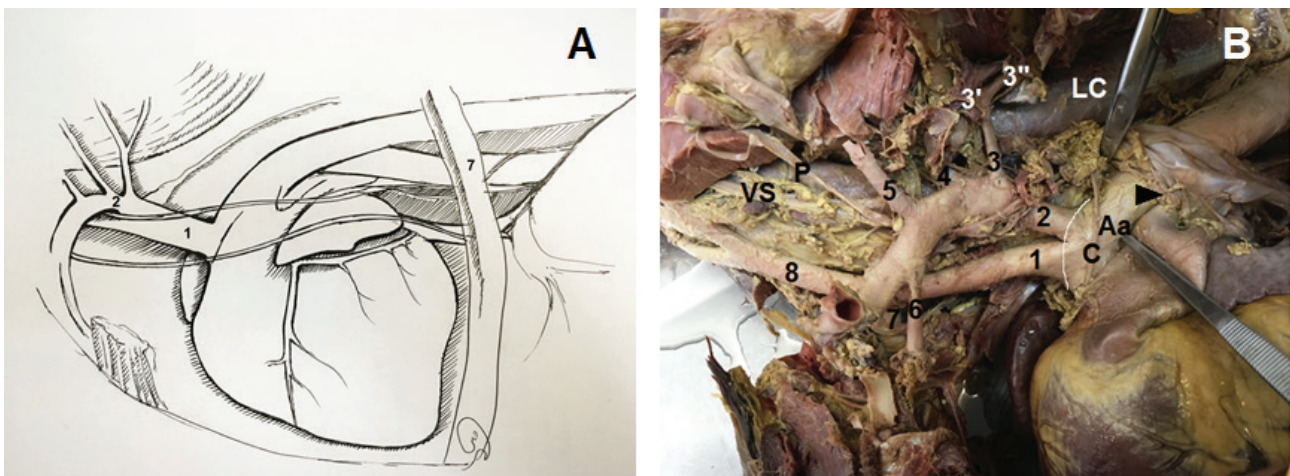


Figure 1.

A: Schematic drawing of the left equine thorax showing the brachiocephalic trunk (1) and left subclavian artery (2). B: The left lateral view of the thorax. The left lung has been removed and the left side of the pericardial sac has been reflected caudally to expose the aortic arch and the great vessels. The brachiocephalic trunk (1); the left subclavian artery (2); the costocervical trunk (3); the dorsal scapular artery (3''); the supreme intercostal artery (3'''); the deep cervical artery (4); the vertebral artery (5); the internal thoracic artery (6); the right subclavian artery (7); the bicarotid trunk (8); the cardiac nerve (C); the phrenic nerve (P); the vagosympathetic trunk (VS); the distal end of the ligamentum arteriosum (the arrowhead) and the longus colli muscle (LC). Note the cranial curvature of the aortic arch (Aa) which is demarcated with the curved white line.

The curvature of the arch of the aorta was located opposite the second intercostal space. It was observed that the aortic arch gave off two great branches rather than the usual one in the cranial direction. The BCT with a length of 7.3 cm and a diameter of 1.64 cm was the first branch to leave the aortic arch giving origin to the RSA. Then, it continued at the level of the first rib as the bicarotid trunk. The second branch was the LSA (with a diameter of 1.18 cm) which separately arose from the similar surface of the aortic arch immediately distal to the BCT origin (Figure 1B). Each branch had a separate exit from the aorta with a ridge projecting between them (Figure 2A), comparable to that of dogs (Figure 2B).

The distal end of the ligamentum arteriosum (LA) joined at the lateral aspect of the aortic arch at the level of the third intercostal space, 3.2 cm caudal to the origin of the LSA.

No other arteries branched off from the BCT in its course toward the first rib. The branching patterns of both subclavian arteries were different on each side. The LSA branched into the costocervical trunk, deep cervical artery, vertebral artery, and internal thoracic artery in order as separate branches. The right costocervical trunk and the deep cervical artery were separated from the RSA by a long common stem, while the vertebral artery independently originated from the RSA (Figure not shown). The bicarotid trunk 6.7 cm cranial to the root of the RSA was bifurcated into two common carotid arteries along the ventral aspect of the trachea.

Encountering anatomic variations during veterinary dissection classes, necropsy or surgical interven-

tions drives us to attempt to clarify their embryological basis. Disposition in various great vessels arising from the aortic arch is attributed to the unusual modes in the development and transformation of aortic arches during the embryonic period [6].

According to Vitums (1969), the definitive aortic arch and the common brachiocephalic trunk in the equine embryos are formed in three distinct phases of development. The typical events that take place in the third phase of development include the elongation of the brachiocephalic trunk and the fusion of the proximal origins of the left and right common carotid arteries into a bicarotid trunk. In this phase, the origin of the LSA along the aortic arch is more cranial in position and lies close to that of the brachiocephalic artery, between the latter and the distal end of the ductus arteriosus (DA). Finally, the aortic arch reaches its definitive position opposite the third to fifth intercostal space and a single great vessel (the common brachiocephalic trunk) develops from the fusion of the BCT and LSA [2]. In the case described here, although the arch of the aorta had completely migrated and reached its final position at the level of the third thoracic vertebra, the lack of formation of the common brachiocephalic trunk may be due to the impaired fusion of the BCT and LSA in the final phase of development. Furthermore, the aortic arch had taken its final form because the distal end of the DA on it was displaced from a more ventral position in the early third phase to a lateral position in the final phase of development. On the other hand, as mentioned earlier, the formation of the bicarotid trunk precedes that of the common brachiocephalic trunk and occurs early in the third phase of the development of equine embryos. Hence, the presence of a bicarotid trunk and

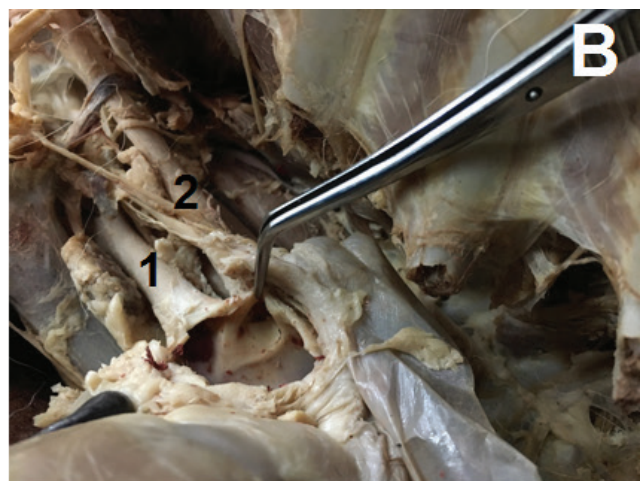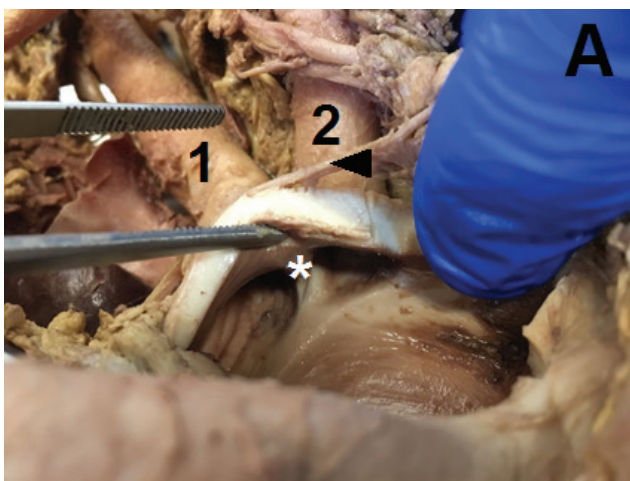


Figure 2.

The aortic arch was opened to show the separate outlets for the brachiocephalic trunk (1) and left subclavian artery (2) and a ridge between them (the asterisk) in the present case (A). The aortic arch of a dog (B) was also opened for comparison with (A). The arrowhead shows the cardiac nerve.

Archive of SID

the direct origin of the LSA cranial to the distal end of the LA in this case may indicate an arrest in the late third phase of development.

A review of comparative morphology associated with the different branching arrangements of the aortic arch can provide a clear understanding of the abnormal conditions in horses and other domestic mammals [7]. A gradually increasing fusion of two or more of the branches forms a common trunk leaving the aorta. Normally, a fusion of the RSA and the right carotid artery produces an innominate artery that has been described in humans [8], monkeys [5], and some other mammals [9-11]. In dogs, pigs, and cats, condensation becomes more complete. However, the LSA remains separate so that the aorta gives the two branches of BCT and the LSA [3].

According to Parsons (1902) the animals with laterally compressed thoraces possibly show the least degree of separation. In ungulates, such as horses and ruminants, the thorax inlet is often twice as deep as it is broad. Furthermore, in these animals, the fusion of great vessels reaches its extremity and only one vessel (the common BCT) arises from the aorta [12]. The direct origin of the LSA from the convex aspect of the aortic arch in horses has not been previously reported in the veterinary literature. This peculiar disposition resembles that normally described in pigs, dogs, and cats [3], as well as other exotic animals such as the white-eared opossum [13], and chinchilla lanigera [14, 15]. In horses, only one large outlet from the aorta belongs to the common BCT is identifiable. But in the present case, two separate outlets for the BCT and LSA visible from inside the aorta confirmed the absence of a common brachiocephalic trunk. This indicates a reversion toward a more primitive condition in which the BCT and LSA take their origins independently from the aorta.

Regarding the branches of the subclavian arteries, the right costocervical trunk and the deep cervical artery arose from the RSA by a common trunk, whereas the vertebral artery arose independently from the RSA. This arrangement on the right side is similar to that observed in the donkey [16]. Because in horses, the right deep cervical artery usually arises from the RSA after the costocervical trunk [4].

To sum up, the present case would potentially be of great interest because the aortic arch had achieved its definitive development before the common BCT was formed.

Authors' Contributions

YK detected the anatomic variation, and wrote the primary draft. ZK revised and reviewed the final draft.

Acknowledgments

The authors wish to thank Mr. H. Haghgooyan for technical assistance.

Competing Interests

There was no conflict of interests.

References

- Hyttel P, Sinowatz F, Vejsted M, Betteridge K. Essentials of domestic animal embryology e-book: Elsevier Health Sciences; 2009.
- Vitums A. Development and transformation of the aortic arches in the equine embryos with special attention to the formation of the definitive arch of the aorta and the common brachiocephalic trunk. *Zeitschrift für Anatomie und Entwicklungsgeschichte*. 1969;128(3):243-70.
- Dyce KM, Sack WO, Wensing CJG. Textbook of veterinary anatomy-E-Book: Elsevier Health Sciences; 2009.
- Getty R, Getty R, Sisson S, Grossman J. Sisson and Grossman's the Anatomy of the Domestic Animals. 1975.
- de Garis CF. Branches of the aortic arch in 153 rhesus monkeys (second series). *The Anatomical Record*. 1938;70(3):251-62.
- McGeady TA, Quinn PJ, Fitzpatrick E, Ryan M, Kilroy D, Loneragan P. *Veterinary embryology*: John Wiley & Sons; 2017.
- Bradley OC. Note on the Morphology of the Branches of the Horse's Aortic Arch. *The Veterinary Journal* (1900). 1908;64(3):123-6.
- Lippert H, Pabst R. *Aortic arch. Arterial Variations in Man: Classification and Frequency* Munich, Germany: JF Bergmann-Verlag. 1985:3-10.
- de Oliveira REM, Santoro GA, Freire ACdB, Attademo FLN, Lima SA, Bomfim AdC, et al. Angioarchitecture of collateral arteries of the aortic arch of Antillean manatee (*Trichechus manatus manatus* Linnaeus, 1758). *Anatomia, Histologia, Embryologia*. 2020;49(1):25-30.
- de Oliveira REM, de Araújo Júnior HN, da Silva Costa H, de Oliveira GB, de Moura CEB, de Oliveira DJA, et al. Collateral Arteries of the Aortic Arch in Mongolian Gerbil (*Meriones unguiculatus*). *Acta Scientiae Veterinariae*. 2018;46(1):8.
- Atalar Ö, Yilmaz S, Burma O, İlkey E. The Macroanatomical Investigations on the Aortic Arch in Porcupines (*Hystrix cristata*). *Anatomia, Histologia, Embryologia*. 2003;32(6):367-9.
- Parsons F. On the arrangement of the branches of the mammalian aortic arch. *Journal of anatomy and physiology*. 1902;36(Pt 4):389.

13. Schimming BC, Jesus LSBSd, Filadelpho AL. Branching pattern of aortic arch in the white-eared opossum (*Didelphis albiventris*). *Braz j vet res anim sci*. 2016;53(3):235-42.
14. Martonos C, Lăcătuș R, Cocan D, Stan F, Damian A, Stroe T, et al. Anatomical and Imagistic Aspects of the Aortic Arch in *Chinchilla lanigera*. *Acta Scientiae Veterinariae*. 2018;46(1):6.
15. Ozdemir V, Cevik-Demirkan A, Turkmenoglu I. Subgross and macroscopic investigation of blood vessels originating from aortic arch in the chinchilla (*Chinchilla lanigera*). *Anat Histol Embryol*. 2008;37(2):131-3.
16. Akbari G, Asadiahranjani B, Goodarzi N, Shokrollahi S. The Branching Pattern of the Brachiocephalic Trunk in the Donkey (*Equus asinus*). *Anat Histol Embryol*. 2017;46(4):359-64.

COPYRIGHTS

©2021 The author(s). This is an open access article distributed under the terms of the Creative Commons Attribution (CC BY 4.0), which permits unrestricted use, distribution, and reproduction in any medium, as long as the original authors and source are cited. No permission is required from the authors or the publishers.

**How to cite this article**

Kamali Y, Khaksar Z (2020). A rare case with the absence of a distinct common brachiocephalic trunk in an adult mixed-breed horse. *Iran J Vet Sci Technol*. 12(2):88-92.
DOI: <https://doi.org/10.22067/ijvst.2020.39238>
URL: https://ijvst.um.ac.ir/article_39238.html



موردی نادر با غیاب تنه بازویی-سری مشترک مشخص در یک اسب بالغ نژاد مخلوط

یونس کمالی، ذبیح ا. خاکسار

گروه علوم پایه، دانشکده دامپزشکی، دانشگاه شیراز، شیراز، ایران.

چکیده

تنها شاخه‌ای که از کمان آئورتی اسب‌های بالغ جدا می‌شود، تنه بازویی-سری مشترک است. این گزارش به توصیف یک مورد نادر از آرایش سرخرگی غیرمعمول کمان آئورتی در یک اسب ماده بالغ می‌پردازد. مشخص گردید که کمان آئورتی فاقد یک تنه بازویی-سری مشترک است و بجای آن دارای دو شاخه یعنی شاخه اول تنه بازویی-سری و شاخه دوم سرخرگ تحت ترقوه‌ای چپ بود. منشاء مستقیم سرخرگ تحت ترقوه‌ای چپ از کمان آئورتی در اسب‌ها بسیار نادر است و مورد مشابهی از آن قبلا گزارش نشده است. جنبه‌های رویان‌شناختی و فیلوژنتیکی این متغیر بحث می‌گردد.

واژگان کلیدی

تنه بازویی-سری مشترک، اسب، سرخرگ تحت ترقوه‌ای چپ