

# Pulp Tissue Reaction of Dog Canines to Root MTA and Portland Cement Compared to ProRoot MTA as Pulp Capping Agents

H. Razmi<sup>1,2</sup>, D. Sharifi<sup>3</sup>, P. Mottahari<sup>4,5</sup>, MR. Khosravi<sup>6</sup>

<sup>1</sup>Associate Professor, Department of Endodontics, Faculty of Dentistry, Medical Sciences/ University of Tehran, Tehran, Iran

<sup>2</sup>Associate Professor, Dental Research Center, Medical Sciences/ University of Tehran, Tehran, Iran

<sup>3</sup>Associate Professor, Department of Surgery, Faculty of Veterinary, Medical Sciences/ University of Tehran, Tehran, Iran

<sup>4</sup>Assistant Professor, Department of Oral and Maxillofacial Pathology, Faculty of Dentistry, Medical Sciences/ University of Tehran, Tehran, Iran

<sup>5</sup>Assistant Professor, Dental Research Center, Medical Sciences/ University of Tehran, Tehran, Iran

<sup>6</sup>Dentist Private Practice

## Abstract:

**Statement of Problem:** Mineral trioxid aggregate (MTA) cement is widely used for root-end filling, pulp capping, perforation repair and other treatments in endodontics. Investigations have shown similar physical and chemical properties for Portland cement (type I), Root MTA and ProRoot MTA.

**Purpose:** The aim of this in vivo study was to evaluate the reaction of dog canine pulp after pulp capping with Root MTA and Portland cement versus ProRoot MTA.

**Materials and Methods:** All four canines from fifteen healthy dogs, 12-18 months of age, were mechanically exposed via buccal class V cavities under aseptic conditions. MTA, Portland cement and Root MTA were prepared according to the manufactures' instructions and placed in the cavities. Tricresol formalin was used in the control group. After 4, 8 and 12 weeks, the animals were sacrificed and the teeth were fixed and processed for light microscopic analysis. The presence and thickness of the dentinal bridge and the degree of inflammation were evaluated. Data were submitted to Mann-Whitney and Kruskal Wallis tests for statistical analysis.

**Results:** No statistically significant difference was found in the presence and thickness of the dentinal bridge, and the degree of inflammation between Root MTA, Portland cement and ProRoot MTA ( $P>0.05$ ).

**Conclusion:** Root MTA, Portland cement and ProRoot MTA showed similar comparative results when used as direct pulp capping materials. The results of this study support the idea that Portland cement and Root MTA have the potential to be used in clinical situation similar to those in which ProRoot MTA is being used.

**Key Words:** Pulp capping; Dentinal bridge; ProRoot MTA; Root MTA; Portland cement

*Journal of Dentistry, Tehran University of Medical Sciences, Tehran, Iran (2006; Vol: 3, No.2)*

✉ Corresponding author:  
H. Razmi, Department of Endodontics, Faculty of Dentistry, Tehran University of Medical Sciences, Keshavarz Bulv., Gode St., Post Code: 14147, Tehran, Iran.  
hrazmi@tums.ac.ir

Received: 8 October 2005  
Accepted: 11 March 2006

## INTRODUCTION

Pulp capping is defined as "treatment of an exposed vital pulp by sealing the pulpal wound with a dental material to facilitate the formation of reparative dentin and main-

tenance of a vital pulp" [1]. Capping of the exposed pulp is indicated for reversible pulp tissue injury after physical or mechanical trauma on developing or mature teeth. The removal of the injurious challenge, the control

of infection and the cytotoxic and biological properties of the capping material are critical factors influencing the treatment prognosis [2]. An effective pulp capping material should be biocompatible, provide a biological seal and prevent bacterial leakage [3]. The main goals of the application of a pulp capping material are to induce dentinal bridge formation by pulp cells and to maintain pulp vitality [1].

Recently MTA has been developed to seal pathways of communication between the root canal system and the external surface of the teeth [4]. MTA has been used as a capping material in mechanically exposed pulps, for completion of root development in immature teeth and to repair root perforations [5]. Several in vitro and in vivo studies have shown that MTA prevents microleakage, is biocompatible and promotes regeneration of the original tissue when placed in contact with dental pulp or periradicular tissues [2,3,6-11]. Wucherpfennig and Green [12] reported that both MTA and Portland cement seem almost identical macroscopically, microscopically and by x-ray diffraction analysis. They also demonstrated apposition of reparative dentin, when the material was used for direct pulp capping in rat teeth. Estrella et al [13] showed that Portland cement contains the same principle chemical elements as MTA, except that MTA also contains bismuth. Holland et al [14] studied the rat subcutaneous connective tissue response to implanted dentin tubes filled with MTA, Portland cement and calcium hydroxide and found very similar mechanisms of action. Saidon et al [15] also demonstrated that MTA and Portland cement have comparative biocompatibility.

Another material called Root MTA that is claimed to be similar to MTA has been produced in Tabriz, Iran [16].

The purpose of this study was to investigate the properties of Iranian-made Root MTA and Portland cement and to compare them with ProRoot MTA when used as pulp capping

materials in intact dog canines.

## MATERIALS AND METHODS

In this experimental study, fifteen healthy mature 12-18 month-old male dogs of Iranian mixed race were initially selected. The experimental protocol was approved by the Animal Care Committee at Tehran University of Medical Sciences. The animals were anesthetized with ketamine hydrochloride (30 mg/kg; Fort Dodge Animal Health, Fort Dodge, Iowa) and 2% aceperomazine maleate (0.05 mg/kg; Aveco Co., Inc., Fort Dodge, IA). Intact canine teeth from both jaws with healthy periodontium were used. The teeth were isolated with cotton rolls, polished and washed with 0.5% chlorhexidine. Buccal class V cavities were prepared by inverted carbide bur #31 (Tiz Kavan, Iran) and the pulps were exposed with a size 0.5 round bur in an air turbine with water spray. The pulp wound was carefully irrigated with sterile saline until the bleeding stopped in order to avoid the formation of a blood clot.

The exposed pulps were capped with ProRoot MTA (Dentsply, Tulsa Dental, Tulsa, OK, USA), Root MTA (Tabriz, Iran) and Portland cement type I (Tehran Cement Factory) after being mixed with distilled water to provide a sandy mixture. The materials were placed on the exposure sites and light pressure was applied with a wet cotton pellet to contact of material with the pulp. The cavities were immediately restored with amalgam (Cina, Faghihi Co, Iran). The thickness of the amalgam was 2 mm. (Fig. 1).

Forty-five teeth were randomly allocated to the three ProRoot MTA, Root MTA and Portland cement groups, 15 teeth in each group. The control group also consisted of 15 teeth.

After 4, 8 and 12 weeks the animals were sacrificed using the vital perfusion technique [17]. The jaws were immediately dissected and the teeth were fixed in 10% buffered formalin and processed for light microscopic analysis.

The teeth were demineralized for 40-50 days in 35% formic acid and embedded in paraffin. Serial sections 6  $\mu$ m thick were cut labiolingually through the exposure sites and stained with hematoxylin-eosin. The amalgam was gently removed before sectioning.

An oral and maxillofacial pathologist studied the images taken from the slides under a light microscope (olympus41-olympus; Japan) without knowledge of the source of the specimens. The degree of inflammation, presence of a dentinal bridge and its thickness were assessed for all specimens. The histologic evaluation of the pulp was carried out according to ISO 7405 with minor modification. From the serial sections cut through the cavity, five evenly spaced sections were selected and the inflammatory infiltrate in the superficial tissues and the deeper pulp were graded separately on the following scale: 0: no inflammation; 1: mild inflammation; 2: moderate inflammation; 3: severe inflammation; For each tooth, dentinal bridge formation was evaluated according to the method proposed by Fitzgerald and Heys [18]. The data were submitted to Mann-Whitney and Kruskal Wallis tests for statistical analysis.

## RESULTS

Two of the 15 dogs died of unrelated causes

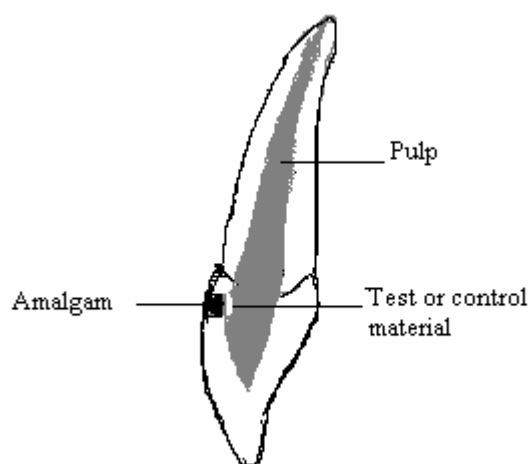


Fig. 1: Schematic model of prepared sample.

Table I: Degree of inflammation after 4, 8 and 12 weeks.

| Time         | Inflammation (%) |          |        | Total    |
|--------------|------------------|----------|--------|----------|
|              | mild             | moderate | severe |          |
| 4 week       | 6 (50)           | 3 (25)   | 3 (25) | 12 (100) |
| 8 week       | 8 (68)           | 2 (16)   | 2 (16) | 12 (100) |
| 12 week      | 13 (87)          | 2 (13)   | 0 (0)  | 15 (100) |
| <b>Total</b> | 27 (71)          | 7 (17)   | 5 (12) | 39 (100) |

on the 4th and 8th week of the study period, leaving 13 animals for evaluation. Considering that four teeth were used in each dog, the total number of investigated teeth were 52.

The Kruskal Wallis test showed no statistically significant differences ( $P=0.07$ ) in the degree of inflammation between MTA, Root MTA and Portland cement.

Presence and thickness of the dentinal bridge also failed to demonstrate a significant difference ( $P=0.09$ ) between the 3 studied materials (Fig. 2).

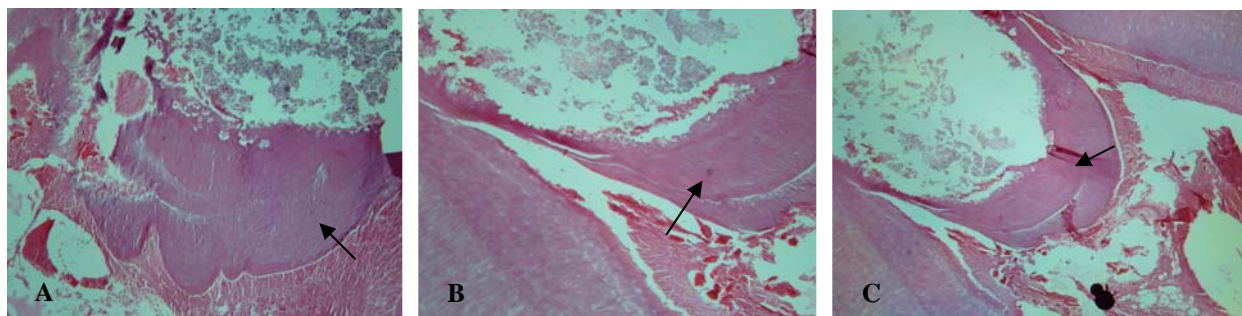
The 12-week group revealed a greater thickness of the dentinal bridge and a lesser degree of inflammation (Tables I and II).

## DISCUSSION

Many clinical and experimental studies have shown that mature dental pulp cells possess the ability to differentiate into a specific cell lineage forming tubular dentin in the absence of bacteria. Microorganisms are the main irritants of the dental pulp and periodontium [2,19,20].

Table II: Thickness of dentinal bridge after 4, 8, and 12 weeks.

| Time         | Thickness (%) |          |         | Total    |
|--------------|---------------|----------|---------|----------|
|              | Thin          | Moderate | Thick   |          |
| 4 week       | 3 (25)        | 6 (50)   | 3 (25)  | 12 (100) |
| 8 week       | 3 (25)        | 5 (42)   | 4 (32)  | 12 (100) |
| 12 week      | 2 (13)        | 5 (33)   | 8 (54)  | 15 (100) |
| <b>Total</b> | 8 (20)        | 16 (41)  | 15 (39) | 39 (100) |



**Fig. 2:** Micrograph of canine (H & E), 12 weeks after treatment with M1A (A), Portland cement (B), and Root MTA; arrows show the newly formed hard tissue sealing at the exposure site ( $\times 25$ ).

The dentinogenic potential can be induced directly as a specific biological effect of the capping material on pulpal cells, or as a part of the wound healing mechanism in the traumatized pulp [2]. Several studies have reported excellent results when using MTA over exposed pulps [2,3,11,12,21,22]. The ability of MTA to induce the formation of a dentin bridge may be due to its excellent sealing ability or biocompatibility [2]. Investigators demonstrated that Portland cements (type I) and MTA have similar physical, chemical and antimicrobial effects [12,13].

The present study was designed to evaluate the degree of pulpal inflammation and the dentin-producing ability of odontoblasts under MTA, Root MTA and Portland cement. Results showed no statically significant differences in the degree of inflammation and the presence and thickness of the dentinal bridge between the studied pulp capping materials.

Holland et al [23] reported that MTA and Portland cement show similar comparative results when used in direct pulp protection after pulpotomy of dog teeth. Wucherpfennig and Green [12] showed that MTA and Portland cement can stimulate the apposition of reparative dentin when used as a direct pulp capping material in rat teeth. Zarabian et al [24] reported similar histological findings on the biocompatibility of root MTA, ProRoot MTA and Portland cement (type I) as a retrograde material in the canines of cats. Moreover, Sharifian et al [25] obtained similar

results when evaluating the cytotoxicity of Root MTA, Portland cement and MTA. Zarabian et al [26] demonstrated identical microleakage properties in MTA, gray and white ProRoot MTA, Root MTA and Portland cement (type I). Also, Razmi et al [27] evaluated the tissue reaction of MTA, Root MTA and Portland cement (type I) in the mandible of cats and obtained similar results.

## CONCLUSION

The results of the current investigation support the idea that Portland cement and Root MTA have the potential to be used in clinical situations similar to those in which MTA is being used. However in order to replace MTA with Root MTA and Portland cement as more suitable and less expensive materials further studies with larger sample size are suggested.

## ACKNOWLEDGMENT

Authors would like to thank Dr. Farid Zaeri for his assistance in statistical analysis of this study.

## REFERENCES

- 1- Moghaddame-Jafari S, Mantellini MG, Botero TM, McDonald NJ, Nor JE. Effect of ProRoot MTA on pulp cell apoptosis and proliferation invitro. *J Endod* 2005;31(5):387-91.
- 2- Tziafas D, Pantelidou O, Alvanou A, Belibasakis G, Papademitriou S. The dentinogenic effect of MTA in short-term capping experiments. *Int Endod J*, 2002;35:245-254.

- 3- Ford TR, Torabinejad M, Abedi HR, Bakland LK, Kariyawasam SP. Using mineral trioxide aggregate as a pulp-capping material. *J Am Dent Assoc.* 1996 Oct;127(10):1491-4.
- 4- Torabinejad M, Chivian N. Clinical Application of Mineral Trioxide Aggregate. *J Endod* 1999;25(3):197-205.
- 5- Schwartz RS, Mauger M, Clement DJ, Walker WA 3rd. Mineral trioxide aggregate: a new material for endodontics. *J Am Dent Assoc* 1999 Jul;130(7):967-75.
- 6- Abdullah D, Ford TR, Papaioannou S, Nicholson J, McDonald F. An evaluation of accelerated Portland cement as a restorative material. *Biomaterials* 2002;23(19):4001-10.
- 7- Torabinejad M, Rastegar AF, Kettering JD, Pitt Ford TR. Bacterial leakage of mineral trioxide aggregate as a root-end filling material. *J Endod* 1995;21:109-112.
- 8- Bates CF, Carnes DL, del Rio CE. Longitudinal sealing ability of mineral trioxide aggregate as a root-end filling material. *J Endod* 1996;22:575-78.
- 9- Koh ET, Torabinejad M, Pitt Ford TR, Brady K, McDonald F. Mineral trioxide aggregate stimulates a biological response in human osteoblasts. *J Biomed Mater Res* 1997;37:432-39.
- 10- Torabinejad M, Watson TF, Pitt Ford TR. Sealing ability of a mineral trioxide aggregate when used as a root end filling material. *J Endod* 1993; 19:591-95.
- 11- Aeinehchi M, Eslami B, Ghanbariha M, Saffar AS. Mineral trioxide aggregate (MTA) and calcium hydroxide as pulp-capping agents in human teeth: a preliminary report. *Int Endod J.* 2003 Mar;36(3):225-31.
- 12- Wucherpfenning AL, Green DB. Mineral Trioxide Aggregate vs Portland cement: two biocompatible filling materials. *J Endod* 1999; 25:308 (Abstract).
- 13- Estrela C, Bammann LL, Estrela CR, Silva RS, Pecora JD. Antimicrobial and Chemical Study of MTA, Portland cement, Calcium Hydroxide paste, Sealapex and Dycal. *Braz Dent J* 2000;11:3-9.
- 14- Holland R, Souza V, Nery MJ, Faraco Junior IM, Bernabe PF, Otoboni Filho JA, Dezan Junior E. Reaction of rat connective tissue to implanted dentine tube filled with mineral trioxide aggregate, Portland cement or calcium hydroxide. *Braz Dent J* 2001;12:3-8.
- 15- Saidon J, He J, Zhu Q, Safavi K, Spangberg LS. Cell and tissue reactions to mineral trioxide aggregate and Portland cement. *Oral Surg Oral Med Oral Pathol Oral Radiol Endod.* 2003 Apr;95(4):483-9.
- 16- Lotfi M, Fayyazpour B. The comparison of microleakage of four root end feeling materials. *J Dent Tabriz university of Medical science and Health services* 1999-2000.
- 17- Asgari M, Eghbal MJ, Parirokh S. Presentation of vital perfusion new technique. *Majaleh Teb o Tazkieh* . 1998; 28:20-22.
- 18- Fitzgerald M, Heys RJ. A clinical and histological evaluation of conservative pulpal therapy in human teeth. *Oper Dent.* 1991;16, 101-12.
- 19- Kakehashi S, Stanley HR, Fitzgerald RJ. The effects of surgical exposures of dental pulps in germ free and conventional laboratory rats. *Oral Surg Oral Med Oral Pathol* 1965;20:340-349.
- 20- Subay RK, Demirci M. Pulp tissue reactions to a dentin bonding agent as a direct pulp capping agent. *J Endod* 2005;31(3):201-204.
- 21- Junn DJ, McMillan P, Bakland LK, Torabinejad M. Quantitative assessment of dentin bridge formation following pulp capping with mineral trioxide aggregate (MTA). *J Endod* 1998; 24:278 (abstract).
- 22- Menezes R, Letra A, Bramante CM, Carvalho VGC. Microscopic analysis of the tissue response of dog's teeth after pulp capping with two types of mineral trioxide aggregate. *J Dent Res* 2003; 82 (special issue): B-322.
- 23- Holland R, de Souza V, Murata SS, Nery MJ, Bernabe PF, Otoboni Filho JA, Dezan Junior E. Healing process of dog dental pulp after pulpotomy and pulp covering with mineral trioxide aggregate or Portland cement. *Braz Dent J* 2001; 12(2):109-13.
- 24- Zarrabian M, Razmi H, Sharifian MR, Sharifi D, Sasani F, Mousavi A. An Investigation on the Histologic Responses of periapical tissues

following retrofilling with root MTA and Portland cement type I versus ProRoot MTA in the canine teeth of cats. *Journal of Dental Medicine*, 2004; 1(4):31-38.

25- Sharifian M, Ghobadi M. Evaluation of cytotoxicity of two materials: Root MTA and Portland cement, on mice fibroblasts L929 and Human gingival fibroblasts, and examination of their chemotaxis in comparison with MTA. Thesis No 446 Dentistry. Tehran University of Medical Sciences. 2002-2003.

26- Zarrabian M, Aligholi M, Shokouhinejad N. Evaluation of bacterial leakage four root end filling materials: gray ProRoot MTA, white ProRoot MTA, Root MTA and portland cement (type I). *Journal of Dental Medicine*, 2005;18(3):15-23.

27- Razmi H, Zarrabian M, Sharifian MR, Sharifi D, Sasani F Ramezankhani N. A histologic evaluation on tissue reaction to three implanted materials (t-MTA, Root MTA and Portland cement Type I) in the mandible of cats. *Journal of Dental Medicine*, 2004;1(3):62-69.

Archive of SID