

Magnet Retained Cheek Plumper in Complete Denture

Esthetics: A Case Report

Suryakant Chhagan Deogade ¹✉

¹Department of Prosthodontics, Hitkarini Dental College & Hospital, Jabalpur, Madhya Pradesh, India

✉ Corresponding author:
S. C. Deogade, Department of
Prosthodontics, Hitkarini Den-
tal College & Hospital, Jabal-
pur, Madhya Pradesh, India

dr_deogade@yahoo.co.in

Received: 22 August 2013
Accepted: 27 October 2013

Abstract

This clinical report describes a technique to improve support for sunken cheeks using magnet retained detachable acrylic cheek plumpers. The new generation of magnets with improved technology provides sufficient denture retention for clinical application. However, further follow-up may be necessary to ascertain the long-term usefulness of the magnet-retained prosthesis, because of corrosion and further loss of magnetism.

Key Words: Aging; Esthetics; Magnets

Journal of Dentistry, Tehran University of Medical Sciences, Tehran, Iran (2014; Vol. 11, No. 1)

INTRODUCTION

Denture esthetics starts with the very first step as one of the objectives of impression making. A prosthodontist plays an important role in restoring the following losses in the patient due to aging including loss of teeth, alveolar process, tonicity of musculature, elasticity of skin as well as impairment of function [1].

Cheeks are an important part of facial esthetics due to their extreme visibility. The support provided by the teeth, the ridges or the dentures determine the form of the cheeks. Factors like extraction of molars, thinning of tissues due to aging, or weight loss may lead to concavities or hollowing of the cheeks [2]. This can make a person appear more older and hence have a negative psychological impact on the patient.

Prosthodontic rehabilitation does not mean to simply replace the missing teeth, but also re-

store the facial support. Conventional procedures can fulfill these requirements. But in some cases, where the patient has sunken cheeks an extra support to the dentures must be provided. This can be achieved by using cheek plumper or cheek lifting appliances. Cheek plumper is basically a prosthesis to enhance the support of sunken cheeks providing better esthetics. Use of plumper prosthesis in maxillofacial prosthodontics is also well documented [3-5]. Addition of an extra quantity of denture base resin to plump the cheek may increase the weight of the denture. Even the construction of single piece prosthesis may cause the same problem that may lead to discomfort for the patient.

These flaws can be hindered by using a detachable plumper prosthesis; where plumper can be detached easily and conveniently from the complete denture.




Fig 1. Magnet used

Magnets are a good option to retain such detachable plumpers to the basic prosthesis due to their small compact size and strong attraction forces [6]. This clinical report illustrates the use of magnets to retain a detachable cheek plumper prosthesis in a completely edentulous patient with hollow cheeks.

CASE REPORT

A 42-year-old male patient reported to Hitkarini Dental College and Hospital, Jabalpur, Madhya Pradesh, India requesting replacement of his missing teeth. On intraoral examination, the patient had completely edentulous maxillary and mandibular arches. He had lost his teeth over a period of 3 years because of periodontal problems and was edentulous for the past 2 years. The patient was conscious about his sunken cheeks and desired a prosthesis that would make his face look fuller and healthier. He was leading a socially isolated life due to the psychological stress of his appearance. Treatment plan was formulated, keeping the patient's demand in mind. It was decided to give the patient maxillary and mandibular complete dentures with intraoral closed faced magnet retained cheek plumpers for the maxillary denture. Primary impressions of maxillary and mandibular arches were made using impression material (Y Dents, MDM Corporation, Delhi). Custom trays were made using autopolymerizing acrylic resin. Border molding was done using low fusing impression compound (DPI Pinnacle, The Bombay Bur-

mah Trading Corporation Limited, Mumbai, India) and wash impression was made with medium body addition silicone impression material (Aquasil, Dentsply/ caulk). Jaw relations were recorded. For the try-in appointment waxed denture was first tried for occlusion and esthetics. At the same appointment, cheek plumpers were made in wax and were attached to the upper waxed-up denture. Then it was evaluated to give the patient a fuller appearance. A dramatic change in the appearance with and without wax-up cheek plumper was observed and it was immediately accepted by the patient. The waxed plumper was separated from the waxed-up denture. After that flasking and dewaxing procedures were completed separately for the final prosthesis and cheek plumpers. The mold space was packed with heat-polymerizing acrylic material (DPI, Mumbai, India) and curing procedures were performed according to the manufacturer's instructions. After deflasking, the cured final prosthesis and plumpers were retrieved. Trimming, finishing, and polishing procedures were performed. Then a pair of commercially available magnets (cobalt-samarium, Ambika Corporation, New Delhi, India), 5 mm in diameter and 2 mm in thickness was employed to retain the cheek plumper with final prosthesis (Fig 1). Provision for placement of magnets in the flange of the final prosthesis and in the cheek plumper was made and positioned with the help of autopolymerizing resin (Fig 2, 3 & 4). Complete polymerization was ensured by placing in a pressure pot and finishing and polishing was then carried out. The attachment of plumper to the prosthesis was first checked outside the patient's mouth (Fig 5 & 6). The prosthesis along with the plumper was then checked in the patient's mouth for comfort, function and esthetics (Fig 7).

The patient was educated about the positioning of the plumper to the prosthesis. The patient's demands were fulfilled (Fig 8 & 9). He was called for regular check up to evaluate any soreness or looseness of dentures.

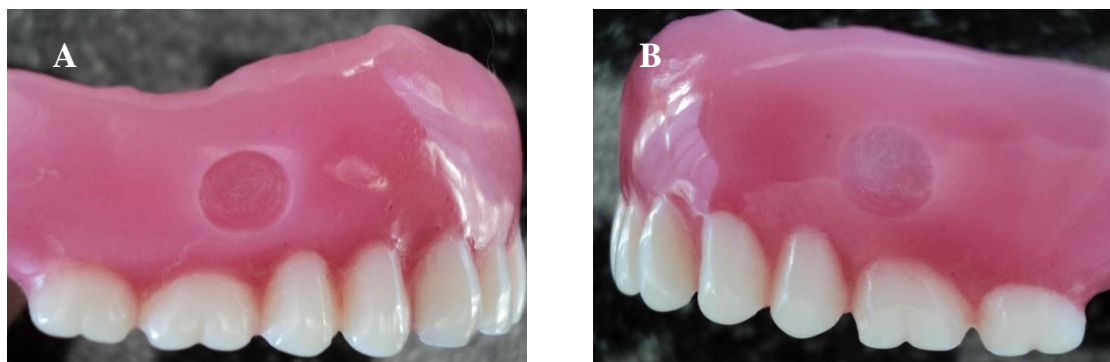


Fig 2. Provision made for attaching the magnet: A) Right side, and B) Left side

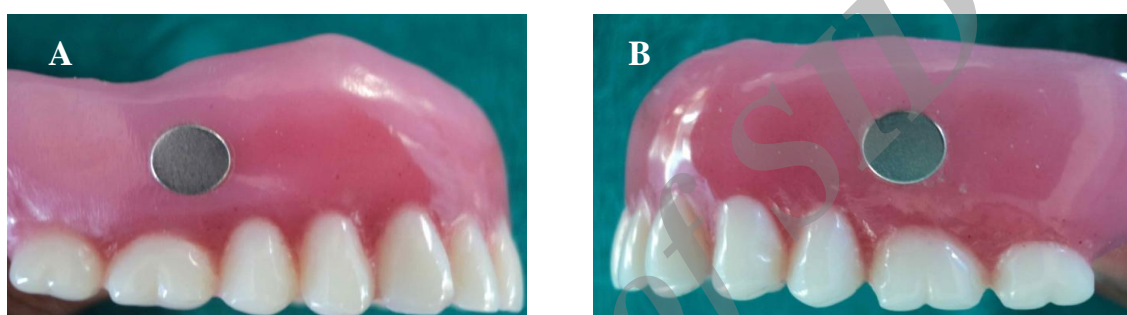


Fig 3. Magnets attached to the denture: A) Right side, and B) Left side

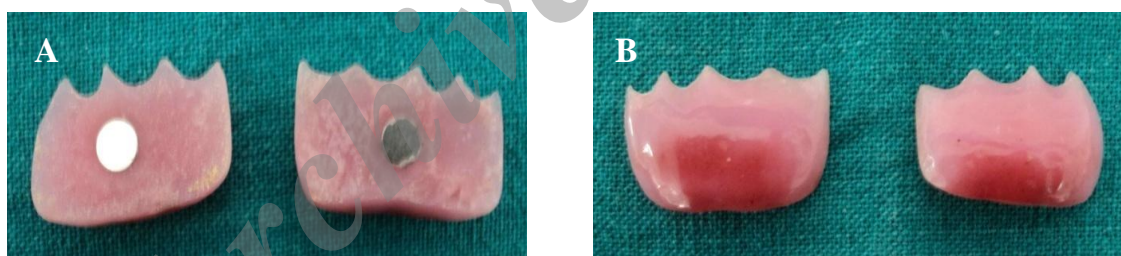


Fig 4. Cheek plumpers with counter-magnets: A) Fitting surface view, and B) Buccal surface view

DISCUSSION

The term 'esthetics' was coined in 1750; a blend of knowledge to give beauty, in contrast to the science of logic for the truth [7]. According to GPT, denture esthetics is defined as the effect produced by a dental prosthesis that affects the beauty and attractiveness of the person [8].

Denture esthetics is not confined to selection of teeth based on factors like form, shape, color, arrangement and sex, but it has approached a new horizon.

In today's world it is more about harmonization between the artificial and natural tissues [9, 10].

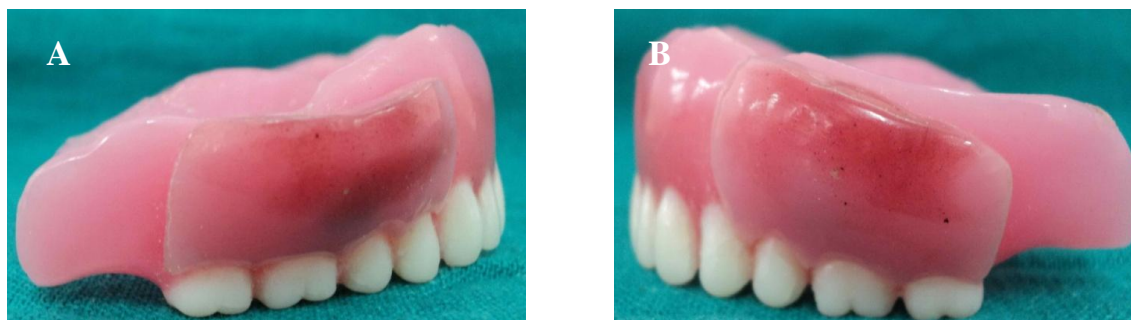


Fig 5. Denture with cheek plumpers: A) Right side, and B) Left side

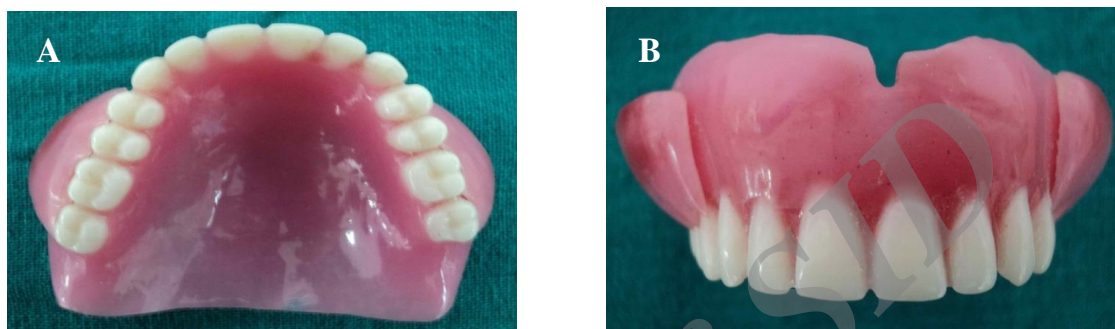


Fig 6. Denture with cheek plumpers: A) Occlusal view, and B) Frontal view

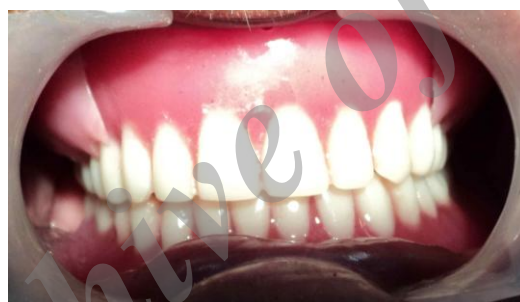

Fig 7. Denture with cheek plumper in patient's mouth

Due to the aging process a drastic change including tissue atrophy, exaggeration of folds and creases of face occurs in the facial esthetics.

This happens particularly because of loss of support by the alveolar bone and teeth leading to collapse of the lower third of the face.

This also results in deepening of the nasolabial fold, drooping of the corner of the mouth, loss of the vermilion border and depression of the lips with exaggerated wrinkling [11]. Loss of posterior teeth results in loss of cheek support, which tends to move medially to meet laterally encroaching tongue [1].

There is even change in cheek contour due to loss of the vertical dimension of occlusion. Factors such as loss of subcutaneous fat, buccal pad of fat and elasticity of the connective tissue are the reason of the sunken cheeks that are seen in the aged [1]. Complete denture prosthesis should concern supporting of the slumped tissue. This can be achieved by increasing the thickness of the upper and lower denture flanges. Some authors have even reported arranging the second row of teeth only for esthetic reasons. Adjustment of the occlusal rim should be precise for anterior and posterior placement of the teeth and esthetics

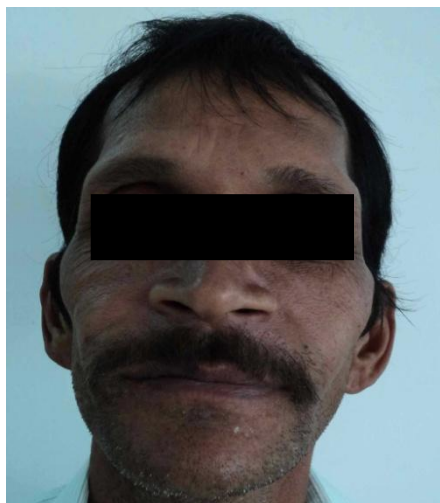

Fig 8. Pre-operative view

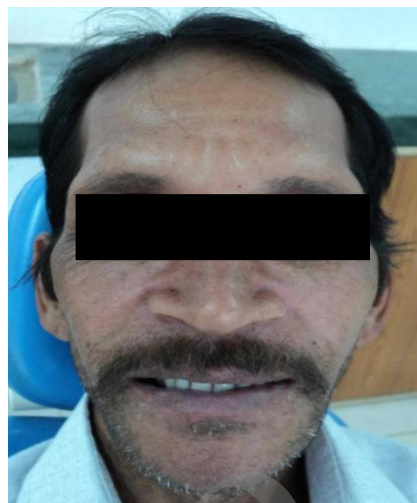

Fig 9. Post-operative view

should be evaluated at rest and function. To restore physiological muscle length and to eliminate pseudopognathic appearance, proper and correct vertical dimension is necessary [12]. Magnets are used due to their small compact size and strong attractive forces. Some of the advantages include easy cleaning, easy placement for both the dentist and the patient, automatic reseating, simplicity of the clinical and laboratory procedures, and constant retentive force with the consecutive number of insertion-removal cycles.

This means magnets can provide a constant amount of retentive force even with a number of insertion and removal cycles of prosthesis [6, 15]. However, the long term durability of the magnets remains a problem.

The cobalt-samarium magnet used in this case provided an essential retention and was cost effective for the patient. The patient was informed about the procedure and the materials used, and informed consent was procured.

The patient also accepted the need for frequent review calls after insertion of the prostheses. A constant follow-up on a longitudinal basis is necessary, and further research on the magnetic field of commercially available magnets is needed.

CONCLUSION

A simple and non-invasive treatment modality to enhance the facial esthetics of a patient with sunken cheeks has been described in this article. An alternative option such as magnets was tried to improve the patient's facial appearance. The magnet retained cheek plumper prosthesis successfully restored the contour of the cheek, improved the esthetics and psychological well being of the patient.

Magnetic retention for hollow cheek patients is advantageous due to its small compact size and strong attractive forces; however, over a period of time the magnets used intraorally require replacement due to lack of long-term durability in oral conditions.

As we have used such intraoral magnets, the patient was informed about the limitations, and he was instructed to report to the clinic once every 6 months to replace the magnets if required.

REFERENCES

- 1- Martone AL. Effects of complete dentures on facial esthetics. *J Prosthet Dent.* 1964 Apr; 14:231-55.
- 2- Bains JW, Elia JP. The role of facial skeletal augmentation and dental restoration in facial rejuvenation. *Aesthetic Plast Surg.* 1994

Summer;18(3):243-6.

3- Lazzari JB. Intraoral splints for support of lips in Bells palsy. *J Prosthet Dent.* 1995;5(4):579-81.

4- Larzen SJ, Carten JF, Abrahamian HA. Prosthetic support for unilateral facial paralysis. *J Prosthet Dent.* 1976 Feb;35(2):192-201.

5- Mukohyama H, Kadota C, Ohyama T, Taniguchi H. Lip plumper prosthesis for a patient with a marginal mandibulectomy: a clinical report. *J Prosthet Dent.* 2004 Jul;92(1):23-6.

6- Riley MA, Walmsley AD, Harris IR. Magnets in prosthetic dentistry. *J Prosthet Dent.* 2001 Aug;86(2):137-42.

7- Young HA. Denture esthetics. *J Prosthet Dent.* 1956;6(6):748-55.

8- Glossary of prosthodontic terms. *J Prosthet Dent.* 2005 Jul;94(1):10-92.

9- Clair F, Picard Jr. Complete denture esthetics. *J Prosthet Dent.* 1958 Mar;8(2):252-9.

10- Waliszewski M. Restoring dentate appear-

ance: a literature review for modern complete denture esthetics. *J Prosthet Dent.* 2005 Apr;93(4):386-94.11- Tautin FS. Denture esthetics is more than teeth selection. *J Prosthet Dent.* 1978 Aug;40(2):127-30.

12- Lombardi RE. The principle of visual perception and their clinical application to denture esthetics. *J Prosthet Dent.* 1973 Apr;29(4):358-82.

13- Punia V, Mishra R, Khandelwal M, Verma N, Handa M. Magnet retained detachable cheek plumper: innovation personified – a case report. *Int J Prosthet Dent.* 2013;4(1):16-20.

14- Sunil MV, Rao H, Sohi KS. Artificial cheek plumper's: a step ahead in denture esthetics- a case report. *Indian J Stomatol.* 2011;2(2):134-7.

15- Javid N. The use of magnets in a maxillofacial prosthesis. *J Prosthet Dent.* 1971 Mar;25(3):334-41.

Archive of SID