



Apical Transportation of Mesio Buccal Canals of Maxillary Molars Following Root Canal Preparation with Two Rotary Systems and Hand Files: A Cone-Beam Computed Tomographic Assessment

Pegah Sarraf^{1*}, Nazanin Kiomarsi², Farrokh Haj Taheri³, Behrang Moghaddamzade⁴, Fatemeh Dibaji¹, Mohammad Javad Kharazifard⁵

1. Department of Endodontics, School of Dentistry, Tehran University of Medical Sciences, Tehran, Iran
2. Department of Restorative Dentistry, School of Dentistry, Tehran University of Medical Sciences, Tehran, Iran
3. Private Practice, Tehran, Iran
4. Department of Oral and Maxillofacial Radiology, School of Dentistry, Tehran University of Medical Sciences, Tehran, Iran
5. Dental Research Center, Dentistry Research Institute, Tehran University of Medical Sciences, Tehran, Iran

Article Info

Article type:
Original Article

Article History:

Received: 7 April 2018
Accepted: 29 August 2018
Published: 30 August 2019

* Corresponding author:

Department of Endodontics, School of Dentistry, Tehran University of Medical Sciences, Tehran, Iran

Email: Pegah_s@yahoo.com

ABSTRACT

Objectives: This study aimed to compare the transportation of the mesio buccal canal of maxillary molars following root canal preparation with HyFlex CM (HCM) and Edge Taper Platinum (ETP) rotary systems and stainless steel (SS) hand files using cone-beam computed tomography (CBCT).

Materials and Methods: This in-vitro study was performed on 48 maxillary molars in three groups of 16. The teeth were mounted in acrylic blocks, and root canals were prepared using HCM in group 1 (up to #30/0.06), ETP in group 2 (up to F3/0.06), and SS hand files in group 3 (up to #30). CBCT scans were taken before and after root canal preparation. The amount of canal transportation was measured at 0, 3, 6, and 9mm from the apex. Data were analyzed using Kruskal-Wallis and Mann-Whitney tests.

Results: The difference in canal transportation at 0 and 6mm from the apex was significant between the HCM and ETP groups ($P=0.031$ and 0.023) but none of the systems showed any significant difference with hand files at 0- and 6-mm levels ($P=0.10$, 0.56 , 0.22 , and 0.50), respectively. At 3mm from the apex, no significant difference was noted among the groups ($P=0.30$). At the 9-mm level, the amount of canal transportation was not significantly different between HCM and ETP ($P=0.83$) but they showed significant differences with hand files ($P<0.001$).

Conclusion: ETP and HCM caused less canal transportation at the curvature of the mesio buccal canal of maxillary molars compared to hand files. ETP showed superior efficacy in root canal preparation compared to HCM.

Keywords: Root Canal Preparations; Dental Instruments; Stainless Steel; Maxilla; Molars; Cone-Beam Computed Tomography

- **Cite this article as:** Sarraf P, Kiomarsi N, Haj Taheri F, Moghaddamzade B, Dibaji F, Kharazifard MJ. Apical Transportation of Mesio Buccal Canals of Maxillary Molars Following Root Canal Preparation with Two Rotary Systems and Hand Files: A Cone-Beam Computed Tomographic Assessment. *Front Dent.* 2019;16(4):272-278. doi: 10.18502/ffd.v16i4.2086

INTRODUCTION

Elimination of microorganisms from the pulp and periapical region through root canal cleaning and shaping is among the most important goals of endodontic treatment [1]. Root canal shaping is a key step in root canal treatment; if performed perfectly, it leads to a favorable prognosis. Cleaning and shaping of the root canal system should provide a conical shape with a consistent taper from the crown to the apex while preserving the original path of the canal [1]. Also, the size of the apical foramen must remain as small as possible [1,2]. However, procedural errors such as ledge formation, zipping, perforation or canal transportation may occur during root canal preparation, especially in curved canals [3]. Irrespective of the techniques and instruments used, the cleaning and shaping process of the root canal system continuously removes dentin from the root canal wall. Excessive removal of intracanal dentin in a single direction (instead of equal dentin removal in all directions) leads to canal transportation [4]. Canal transportation is the result of displacement of the physiologic apex to a new position on the external root surface by clinicians [5-8]. These changes may negatively affect the quality of endodontic treatment by lowering the efficiency of disinfection [9-12]. During root canal preparation, instruments must remain at the center of root canal space in order not to undermine or excessively weaken the tooth structure; this is referred to as the centering ability of the instruments [13]. By the introduction of new instruments made of nickel-titanium (NiTi) alloy, great advances were made in root canal shaping since NiTi instruments have higher flexibility and shear strength, yielding predictable results. These instruments decrease dentist-related errors even in severely curved canals [13]. On the other hand, NiTi rotary files apply less lateral forces to dentinal walls in curved canals due to having a lower modulus of elasticity than stainless steel (SS) instruments [11]. HyFlex CM (HCM) files, compared to other conventional NiTi files, comprise a lower weight percentage of Ni [14]. The reduction in Ni content decreases the toughness of the

alloy. This softer alloy has less tendency to remove dentin and remains at the center of the canal path during root canal preparation [15]. A particular technique with a specific thermal sequence is used in the manufacturing process of these files (patent pendency). This specific thermal sequence increases the fatigue resistance of NiTi alloys [14]. The manufacturer claims that due to the increased flexibility of HCM, this file is the best option for preparation of curved canals compared to conventional files [14]. Edge Taper Platinum (ETP) files are newly introduced files that have the properties of heated NiTi files with characteristics similar to those of ProTaper Gold files [15]. The manufacturer claims that the cyclic fatigue of these files at a certain torque and speed is twice that of ProTaper Gold and six times that of ProTaper Universal files [15].

Computed tomographic (CT) scans are among the commonly used conventional methods to assess changes in the root canal system that occur during cleaning and shaping and to evaluate the shaping ability of endodontic rotary files. Cone-beam computed tomography (CBCT) is highly accurate compared to conventional imaging techniques and provides images of different sections [16].

Since no previous study has evaluated the efficacy of the ETP rotary system in root canal shaping, this study aimed to assess the efficacy of ETP and HCM rotary files in root canal preparation in comparison with hand files by measuring canal transportation using CBCT.

MATERIALS AND METHODS

Forty-eight maxillary first molars, extracted for periodontal disease or severe caries, were chosen for this study. All teeth had mature apices and non-calcified mesiobuccal canals, confirmed by periapical radiography. Canal curvature was determined on periapical radiographs using Schneider's method [17]. AutoCAD 2008 (Auto Desk Inc., Mill Valley, CA, USA) was used to calculate the curvature radius according to a method described by Estrela et al [18]. The teeth with 20° to 45° curvatures and 4-mm curvature radius were selected for root canal preparation.

Sample preparation:

The teeth were immersed in 0.5% chloramine-T solution for 24 hours for disinfection. If needed, the crowns were cut to standardize the teeth to have an 18-mm root length. The teeth were then randomly divided into three groups. To standardize the conditions for taking radiographs, the teeth were mounted in acrylic blocks. Before root canal preparation, high-resolution three-dimensional (3D) CBCT scans were obtained using the NewTom Giano system (NewTom, Verona, Italy) with 0.2-mm slice thickness and 11×8-mm² field of view (FOV) in the axial plane.

An access cavity was then prepared, and a #10 K-file (Dentsply Maillefer, Ballaigues, Switzerland) was introduced into the root canal with minimal pressure to ensure patency. The working length was determined by introducing a K-file into the canal until its tip was visible at the apex. One millimeter was subtracted from this length to determine the working length.

In group 1 (n=16), the canals were prepared using the HCM system (Coltene, Whaledent, OH, USA). First, a straight path was achieved in the mesiobuccal canal using #10, #15, and #20 K-files (Dentsply Maillefer, Ballaigues, Switzerland) followed by HCM rotary file and rotary handpiece (MORITA Tri Auto Mini, Morita, USA) at 500 revolutions per minute (rpm) and 2.4-N/cm torque. Using the crown-down technique, first, #25/0.08 was used for flaring of the root canal orifice. Next, #30/0.04 and then #30/0.06 were used 3-5 mm shorter of the working length. Next, #25/0.04 and #25/0.06 were used to the working length. Finally, #30/0.04 and then #30/0.06 were used to the working length for shaping of the apical region. After using each rotary file, a hand K-file was used to maintain the patency of the canal.

In group two (n=16), the canals were prepared using The ETP system (EdgeEndo, Albuquerque, NM, USA). First, a straight path was achieved in the mesiobuccal canal using a #15 K-file and ETP file and rotary handpiece (MORITA Tri Auto Mini, Morita, USA) at 300 rpm and 4-N/cm torque. First, the Sx file (#19/0.06) was introduced into the canal to

the working length followed by the S1 (#18). The S2 file (#20/0.06) was introduced into the canal to the working length. Next, the F1 file (#20/0.06) was used to the working length. The F2 file (#25/0.06) was used for preparation of the apical region. Finally, the F3 file (#30/0.06) was used to accomplish root canal preparation. A hand K-file was used to maintain the patency.

In group 3 (n=16), the canals were prepared using SS hand K-files (Dentsply Maillefer, Ballaigues, Switzerland) with the following sequence: #10, #15, #20, #25, and #30. Root canals were prepared using the standard technique followed by the step-back technique to file #60. Root canals were rinsed with 3 ml of 2.5% sodium hypochlorite (NaOCl; Cerkamed, Nisko, Poland) between files. After completion of root canal preparation, the canals were irrigated with 5 ml of 17% ethylenediaminetetraacetic acid (EDTA; Master-Dent, Dentonics, Inc. USA) for one minute, 3 ml of 2.5% NaOCl, and 5 ml of saline as the final rinse. After root canal preparation, CBCT scans were taken again and measurements were made at 0, 3, 6, and 9 mm from the apex using NNT Viewer software (NewTom, Verona, Italy).

Calculation of the amount of canal transportation:

The following formula, introduced by Gambill et al [19], was used for the calculation of the amount of canal transportation (Fig. 1): $(A_1 - A_2) - (B_1 - B_2)$, where A1 is the smallest distance between the external root surface and the

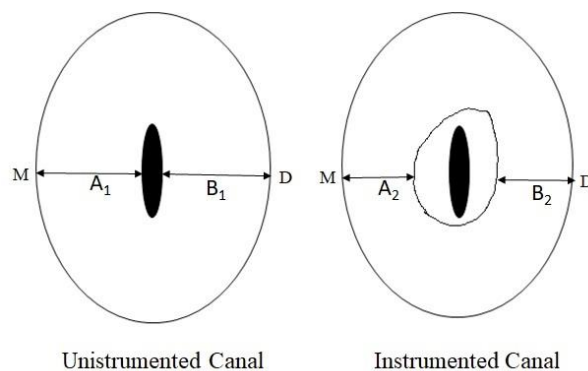


Fig. 1: The schematic cone-beam computed tomographic axial view of the root canal before and after preparation

external mesial surface of an unprepared root canal, B1 is the smallest distance between the external root surface and the external distal surface of an unprepared root canal, A2 is the smallest distance between the external root surface and the external mesial surface of a prepared root canal, and B2 is the smallest distance between the external root surface and the external distal surface of a prepared root canal [19]. An oral and maxillofacial radiologist made the measurements. The data were analyzed using SPSS software (SPSS Inc., Chicago, IL, USA). The values were placed in the above-mentioned formula. If the result was zero, it indicated no transportation. Any

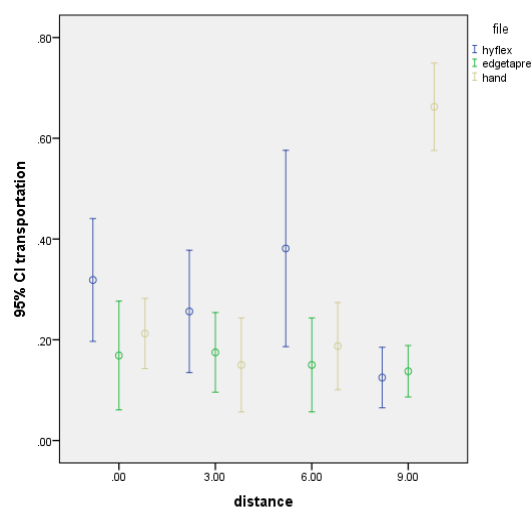


Fig. 2: The error bar of mean and 95% confidence interval of mean of canal transportation before and after root canal treatment by different endodontic files.

value other than zero indicated canal transportation. The results were analyzed using Kruskal-Wallis and Mann-Whitney tests.

RESULTS

The results showed no significant difference among the three groups at 3 mm from the apex ($P=0.3$). However, the amount of canal transportation among the three groups was significantly different at 0, 6, and 9 mm from the apex ($P=0.044$, 0.046 , and <0.001 ; Fig. 2). Thus, pairwise comparisons of the groups were made at 0, 6, and 9 mm from the apex. At 0 and 6 mm from the apex, canal

transportation by ETP was less than that by HCM ($P=0.031$ and 0.023). At 9 mm from the apex, canal transportations by HCM and ETP were not significantly different ($P=0.838$). At 9-mm level, canal transportation by the two rotary systems was significantly different from that by hand files ($P<0.001$). The comparison of canal transportation by HCM and hand files and by ETP and hand files at 0 and 6 mm from the apex revealed no significant difference ($P=0.10$, 0.56 , 0.22 , and 0.50 ; Table 1).

DISCUSSION

This study aimed to assess the efficacy of two newly introduced rotary file systems and traditional hand files by measuring the transportation of the maxillary mesiobuccal canal using CBCT.

Table 1: Mean and standard deviation (SD) of transportation (mm) of the mesiobuccal canal

	Distance to apex (mm)			
	0	3	6	9
HCM	0.31±0.22	0.25±0.22	0.38±0.36	0.12±0.11
ETP	0.16±0.20	0.17±0.14	0.15±0.17	0.13±0.09
HKf	0.21±0.13	0.15±0.17	0.18±0.16	0.66±0.16

HCM: HyFlex CM, ETP: Edge Taper Platinum, HKf: Hand K-file

Several methods have been suggested for the assessment of the efficacy of endodontic files, root canal preparation techniques, and the quality of root canal preparation, allowing the comparison of the canal shape before and after root canal preparation. Conventional radiography and root sectioning are among these methods, which have some shortcomings. Conventional radiography provides a two-dimensional (2D) image of the samples and does not allow the assessment of root cross-sections [20-22]. Root sectioning used to be a common method; however, it damages the samples [23].

The introduction of CBCT allowed for the assessment of the function of rotary files and the evaluation of root canal transportation. In this technique, CBCT scans are obtained before and after root canal preparation, measurements are made on the images, and

the values are compared to detect any changes. This method is highly accurate and does not damage the samples. It also allows taking various images of the canal [16,24,25]. In the current study, only the mesiobuccal canal of the maxillary first molars was used to minimize dispersion and range of variability among the samples. The mesiobuccal canal of first molars is among the most difficult canals for preparation since it is curved and often very narrow [26].

Since the highest degree of curvature is often seen in the middle and apical thirds, these areas are more susceptible to procedural errors [27]. Therefore, in this study, sections were made at 0, 3, 6, and 9 mm from the apex to assess transportation [23,28]. Khademi et al [29] showed that for better penetration of irrigating solutions into the apical third of the root canal, this region must be prepared at least to size 30. Thus, in our study, the apical region was prepared to size 30 in all three groups.

In the current study, canal transportation at 9 mm from the apex, which corresponds to the middle third of the root where the curvature starts, was less with the use of HCM and EPT rotary systems compared to hand files. This was in agreement with the results reported by Kumar et al [30], who compared HCM, Twisted File, and hand files. Also, our study showed no difference in canal transportation between HCM and ETP at 3 and 9 mm from the apex; however, both systems showed superior efficacy compared to hand files at the site of initiation of curvature. This finding was in accord with the results reported by Zhao et al [31], who stated acceptable results with minimal procedural errors using micro-CT.

The search of the literature yielded no study on the efficacy of ETP. However, it should be noted that, in our study, ETP caused less canal transportation than HCM at 0 and 6 mm from the apex; therefore, it may be stated that it had a superior function compared to HCM.

In our study, no significant difference was noted among the three groups in terms of canal transportation at 3 mm from the apex, which may be because the canal curvature at

this level was mild, and all three methods had optimal efficacy.

According to the manufacturer's instructions, HCM must use the crown down technique in canal preparation while the single-length technique must be used with ETP. A previous study showed that Race file (the crown down technique) caused fewer irregularities in the canal compared to the Mtwo system (the single-length method) with superior canal centering ability [28]. However, in the current study, ETP showed superior results at 0 and 6 mm from the apex compared to HCM. The difference between our study and previous ones is in the type of teeth used, method of assessment of canal transportation, and type of files used. Less canal transportation with the ETP system compared to HCM may be attributed to the fewer number of files used in the apical region since six files in the ETP system is used for apical preparation versus seven files in the HCM system.

CONCLUSION

The ETP and HCM rotary systems showed less canal transportation at the curvature of the mesiobuccal canal of maxillary first molars compared to hand files. ETP showed superior efficacy in root canal preparation compared to HCM.

ACKNOWLEDGMENTS

The project for this research was supported by Tehran University of Medical Sciences, International Campus.

CONFLICT OF INTEREST STATEMENT

None declared.

REFERENCES

1. Jara CM, Hartmann RC, Bottcher DE, Souza TS, Gomes MS, Figueiredo JAP. Influence of apical enlargement on the repair of apical periodontitis in rats. *Int Endod J*. 2018 Nov;51(11):1261-1270.
2. Schilder H. Cleaning and shaping the root canal. *Dent Clin North Am*. 1974 Apr;18(2):269-96.
3. Weine FS, Kelly RF, Lio PJ. The effect of

- preparation procedures on original canal shape and on apical foramen shape. *J Endod.* 1975 Aug;1(8):255-62.
4. Nagaraja S, Sreenivasa Murthy BV. CT evaluation of canal preparation using rotary and hand Ni-Ti instruments: An in vitro study. *Conserv Dent.* 2010 Jan;13(1):16-22.
 5. Nazarimoghadam K, Daryaeian M, Ramazani N. An in vitro comparison of root canal transportation by reciproc file with and without glide path. *J Dent (Tehran).* 2014 Sep;11(5):554-9.
 6. Özer SY. Comparison of root canal transportation induced by three rotary systems with noncutting tips using computed tomography. *Oral Surg Oral Med Oral Pathol Oral Radiol Endod.* 2011 Feb;111(2):244-50.
 7. Schäfer E, Dammaschke T. Development and sequelae of canal transportation. *Endod Topics.* 2006 Nov;15(1):75-90.
 8. Vallaey K, Chevalier V, Arbab-Chirani R. Comparative analysis of canal transportation and centring ability of three Ni-Ti rotary endodontic systems: Protaper®, MTwo® and Revo-S™, assessed by micro-computed tomography. *Odontology.* 2016 Jan;104(1):83-8.
 9. Mantri SP, Kapur R, Gupta NA, Kapur CA. Type III apical transportation of root canal. *Contemp Clin Dent.* 2012 Jan;3(1):134-6 .
 10. Pettiette MT, Delano EO, Trope M. Evaluation of success rate of endodontic treatment performed by students with stainless-steel K-files and nickel-titanium hand files. *J Endod.* 2001 Feb;27(2):124-7.
 11. Walia HM, Brantley WA, Gerstein H. An initial investigation of the bending and torsional properties of Nitinol root canal files. *J Endod.* 1988 Jul;14(7):346-51.
 12. Wu MK, Fan B, Wesselink PR. Leakage along apical root fillings in curved root canals. Part I: effects of apical transportation on seal of root fillings. *J Endod.* 2000 Apr;26(4):210-6.
 13. Peters OA. Current challenges and concepts in the preparation of root canal systems: a review. *J Endod.* 2004 Aug;30(8):559-67.
 14. Bürklein S, Börjes L, Schäfer E. Comparison of preparation of curved root canals with Hyflex CM and Revo-S rotary nickel-titanium instruments. *Int Endod J.* 2014 May;47(5):470-6.
 15. Thompson M, Sidow SJ, Lindsey K, Chuang A, McPherson JC 3rd. Evaluation of a new filing system's ability to maintain canal morphology. *J Endod.* 2014 Jun;40(6):867-70 .
 16. Madani ZS, Goudarzipor D, Haddadi A, Saeidi A, Bijani A. A CBCT Assessment of Apical Transportation in Root Canals Prepared with Hand K-Flexofile and K3 Rotary Instruments. *Iran Endod J.* 2015 Winter;10(1):44-8 .
 17. Schneider SW. A comparison of canal preparations in straight and curved root canals. *Oral Surg Oral Med Oral Pathol.* 1971 Aug;32(2):271-5.
 18. Estrela C, Bueno MR, Sousa-Neto MD, Pécora JD. Method for determination of root curvature radius using cone-beam computed tomography images. *Braz Dent J.* 2008;19(2):114-8.
 19. Gambill JM, Alder M, del Rio CE. Comparison of nickel-titanium and stainless steel hand-file instrumentation using computed tomography. *J Endod.* 1996 Jul;22(7):369-75.
 20. Haapasalo M1, Shen Y, Qian W, Gao Y. Irrigation in endodontics. *Dent Clin North Am.* 2010 Apr;54(2):291-312.
 21. Sabeti MA, Nekofar M, Motahhary P, Ghandi M, Simon JH. Healing of apical periodontitis after endodontic treatment with and without obturation in dogs. *J Endod.* 2006 Jul;32(7):628-33.
 22. Dowker SE, Davis GR, Elliott JC. X-ray microtomography: nondestructive three-dimensional imaging for in vitro endodontic studies. *Oral Surg Oral Med Oral Pathol Oral Radiol Endod.* 1997 Apr;83(4):510-6.
 23. Mokhtari H, Niknami M, Sohrabi A, Habibivand E, Mokhtari Zonouzi HR, et al. Cone-Beam Computed Tomography Comparison of Canal Transportation after Preparation with BioRaCe and Mtwo Rotary Instruments and Hand K-Flexofiles. *Iran Endod J.* 2014 Summer;9(3):180-4 .
 24. Gergi R, Rjeily JA, Sader J, Naaman A. Comparison of canal transportation and centering ability of twisted files, Pathfile-ProTaper system, and stainless steel hand K-

files by using computed tomography. *J Endod.* 2010 May;36(5):904-7.

25. Hartmann MS, Barletta FB, Camargo Fontanella VR, Vanni JR. Canal transportation after root canal instrumentation: a comparative study with computed tomography. *J Endod.* 2007 Aug;33(8):962-5 .

26. Madani ZS, Haddadi A, Haghanifar S, Bijani A. Cone-beam computed tomography for evaluation of apical transportation in root canals prepared by two rotary systems. *Iran Endod J.* 2014 Spring;9(2):109-12 .

27. Arora A, Taneja S, Kumar M. Comparative evaluation of shaping ability of different rotary NiTi instruments in curved canals using CBCT. *J Conserv Dent.* 2014 Jan;17(1):35-9.

28. Ehsani M, Zahedpasha S, Moghadamnia AA, Mirjani J. An ex-vivo study on the shaping parameters of two nickel-titanium rotary systems compared with hand

instruments. *Iran Endod J.* 2011 Spring;6(2):74-9.

29. Khademi A, Yazdizadeh M, Feizianfar M. Determination of the minimum instrumentation size for penetration of irrigants to the apical third of root canal systems. *J Endod.* 2006 May;32(5):417-20.

30. Kumar BS, Pattanshetty S, Prasad M, Soni S, Pattanshetty KS, Prasad S. An in-vitro Evaluation of canal transportation and centering ability of two rotary Nickel Titanium systems (Twisted Files and Hyflex files) with conventional stainless Steel hand K-flexofiles by using Spiral Computed Tomography. *J Int Oral Health.* 2013 Oct;5(5):108-15.

31. Zhao D, Shen Y, Peng B, Haapasalo M. Micro-computed tomography evaluation of the preparation of mesiobuccal root canals in maxillary first molars with Hyflex CM, Twisted Files, and K3 instruments. *J Endod.* 2013 Mar;39(3):385-8.