



# A Model for Induction of Dysplasia in Hamster Mucosal Pouch

Sara Pourshahidi<sup>1</sup>, Elaheh Ghasemzadeh Hoseini<sup>2\*</sup>, Hooman Ebrahimi<sup>3</sup>, Mojgan Alaeddini<sup>4</sup>, Shahroo Etemad-Moghadam<sup>4</sup>, Shiva Shirazian<sup>1</sup>

1. Laser Research Center of Dentistry, Dentistry Research Institute, Tehran University of Medical Sciences, Tehran, Iran
2. Department of Oral and Maxillofacial Medicine, School of Dentistry, Tehran University of Medical Sciences, Tehran, Iran
3. Oral Medicine Department, Dental Branch, Islamic Azad University, Tehran, Iran
4. Dental Research Center, Dentistry Research Institute, Tehran University of Medical Sciences, Tehran, Iran

## Article Info

**Article type:**  
Short Communication

### Article History:

Received: 21 January 2019  
Accepted: 4 August 2019  
Published: 15 October 2019

### \* Corresponding author:

Department of Oral & Maxillofacial Medicine, School of Dentistry, Tehran University of Medical Sciences, Tehran, Iran

Email: dr.el.ghasemzade@gmail.com

## ABSTRACT

Induction of premalignant lesions in animal models is of high value for research purposes. This study aimed to induce dysplasia in hamster mucosal pouch for investigation of dysplastic lesions using dimethylbenz(a)anthracene. The buccal pouch of 10 hamsters was painted with dimethylbenz(a)anthracene for 10 weeks every other day. At 5 and 10 weeks, they underwent histopathological analysis. Clinically, there was no change until week 7; after which mucosal thickening occurred. Hamsters scarified at 5 weeks and 10 weeks demonstrated mild and moderate dysplasia, respectively. dimethylbenz(a)anthracene is a useful tool for inducing dysplastic lesions in the buccal pouch mucosa of hamsters.

**Keywords:** Precancerous Conditions; 7,12-dimethylbenz(a)anthracene; Administration, Mucosal

- **Cite this article as:** Pourshahidi S, Ghasemzadeh Hoseini E, Ebrahimi H, Alaeddini M, Etemad-Moghadam S, Shirazian S. A Model for Induction of Dysplasia in Hamster Mucosal Pouch. *Front Dent.* 2019;16(5):402-406. doi: 10.18502/fid.v16i5.2291

## INTRODUCTION

Premalignant lesions are lesions with changes in their epithelium, which have a higher malignancy potential. The most common premalignant lesions include hyperplasia, atypia, and dysplasia. Hyperplasia and atypia are lesions with low risk of malignant transformation; whereas, mild and moderate dysplasia represent early premalignant changes. Severe dysplasia is among the lesions with high malignant potential [1].

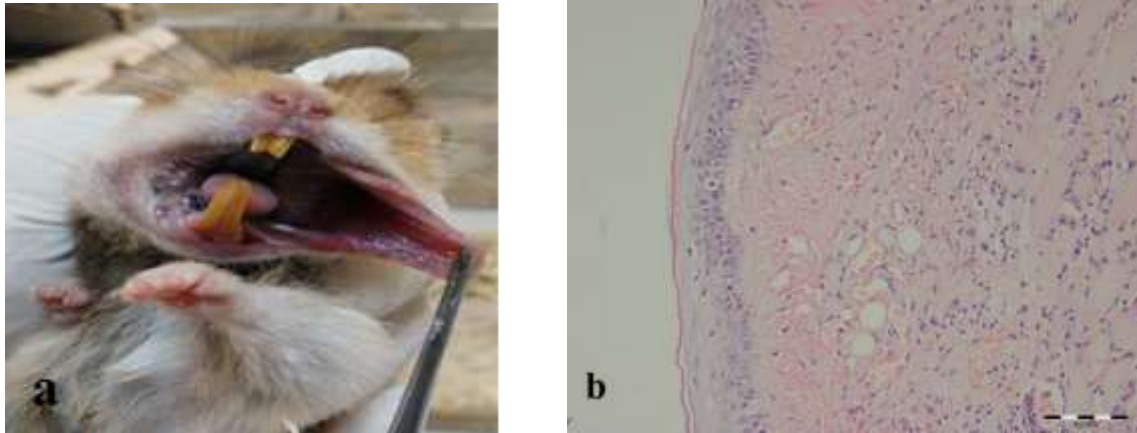
Leukoplakia, erythroplakia, and verrucous hyperplasia are samples of premalignant lesions, which can have variable levels of dysplasia [2-5].

Squamous cell carcinoma (SCC) - the most common oral cancer - is a debilitating condition that brings about negative effects on the quality of life of patients [6]. In spite of the advances in treatment modalities, the 5-year survival rate of patients with oral SCC has not changed over the past two decades, and

remains at about 50% [6-9]. Therefore, finding the factors that affect the disease pathogenesis and efficacy of treatment is critical. Testing different materials and methods on human samples is unethical and thus impossible. Most studies on SCC have been conducted on cell lines and have an *in vitro* design but premalignant lesions need to be studied *in situ*. Thus, induction of premalignant lesions in animal models is of high value for research purposes. The hamster buccal pouch as an induction model was first suggested in 1954 and modified in 1961. In the preliminary protocol, 9,10-dimethyl-1,2-benzanthracene (DMBA) solution in acetone or benzene was painted on the pouch 3 times a week for 16 weeks, which was able to induce the development of SCC. DMBA is a prototype of polycyclic aromatic hydrocarbons, and its role in developing oral cancer has been demonstrated in the mammal cells; this compound is metabolized as electrophilic diol-epoxides [1-3]. It then binds to adenine and then guanine in DNA; thereby, forming harmful compounds. In 1991, Lin and Chen [10] revealed that after 8 weeks of cancer induction by application of 0.5% DMBA 3 times a week and arecaidine 6 times a week for 4 weeks, the initiation period of cancer was shortened. A sustained-release delivery method, in which sutures were loaded with DMBA, was able to induce SCC in 20 weeks [11]. Bampi et al. [12] employed peroxide carbamide gel along with DMBA to reduce latency in tumor development. Most of the above mentioned studies focused on carcinogenesis and reported the development of tumor as the main purpose but in this study, we aimed to focus on induction of dysplasia, a borderline lesion in which, small changes can return to normal while more changes lead to SCC. The Animal Experimentation Ethical Committee of the School of Dentistry of Tehran University of Medical Sciences approved the present study. The aim of this pilot study was to examine the development of dysplasia in hamster pouch to perform further studies on dysplastic cells. For this purpose, 10 young male Golden Syrian outbreed hamsters

with an approximate age of 8 weeks and weight of 100 g were kept in cages with floors covered by wood chips [4,5] under constant conditions (22°C temperature, 12/12 h light/dark cycle) with pelleted laboratory diet and separate water bowls [5-9].

The hamsters were allowed to adapt to the new environment for 1 week [1,3,7]. Then, about 1 cm<sup>2</sup> of the anterior wall of the buccal pouch of each hamster was painted with 0.5% DMBA (Sigma, ST Louis, MO, USA) dissolved in liquid paraffin (a mixture of 0.5 g DMBA in 99.5 g oil, which was kept in a brown bottle) every other day for 10 weeks [1,13,14]. A #4 oil paint brush [1,13,15] was used for this purpose with 10 rotational movements [1,13]. This movement was selected to ensure adequate distribution of the carcinogenic compound and avoid buccal mucosal damage [1]. About 0.2-0.4 mg of the substance was used each time [7]. After sacrificing the animals, we biopsied the pouch mucosa immediately in order to prevent any effect of time discrepancy [4,8]. The thickness of the sections was 4 mm and they were stained with hematoxylin and eosin. Two experienced pathologists analyzed the samples. We classified the dysplasia according to the presence of these morphological alterations: loss of polarity of basal cells, basilar hyperplasia, increasing nuclear/cytoplasm ratio, epithelial projections resembling tear drops, irregular stratifications of the epithelium, atypical or increased mitosis, presence of mitosis in superficial half of the epithelium, hyperchromatic nuclei, pleomorphic cells, loss of cell cohesion, enlargement of nucleoli, and keratinization in the spinous layer (individual or as a cell group). Presence of up to two of the abovementioned changes represented "mild", three to four represented "moderate" and more than five represented "severe" dysplasia [16]. In the present study, variations in the mucosa of all hamsters were investigated and recorded every week, and histopathological changes were evaluated at 5 and 10 weeks. Two hamsters died in the course of study, one at 6 and the other at 8 weeks.



**Fig. 1.** Clinical (a) and histopathologic (b) image of dysplasia induced in hamster pouch mucosa. Microscopic photomicrograph demonstrates mild dysplasia in the epithelial layer (H&E staining, scale bar represents 0.1mm)

To better investigate the detail of the events over weeks, five hamsters were sacrificed at the end of the fifth week and the remaining were sacrificed at 10 weeks. No change was observed during the first 2 weeks in the buccal pouch mucosa of the samples. Between the third and fifth weeks, the changes were limited to textural variations and coarseness of the mucosa (Fig. 1).

At 5 weeks, histopathological analysis in most regions revealed a hyperkeratotic and hyperplastic epithelium. Superficial ulcers and absence of epithelium along with necrosis and edema were also observed in some parts. The epithelium showed loss of cellular polarity in the basal region and increased nucleus-to-cytoplasm ratio in some areas. These results represented mild dysplasia (Fig. 1). In the remaining hamsters, the mucosal redness gradually increased at 6 weeks. Also, one hamster died at 6 weeks, and the study was continued with four hamsters. From the seventh week onwards, the mucosal thickness gradually increased, such that by the end of the eighth week, a thick plaque was observed. Another hamster died at this time. Until the 10<sup>th</sup> week, the thickness of plaque constantly increased in the remaining three hamsters. In the 10<sup>th</sup> week, the remaining hamsters were sacrificed and the samples were examined histopathologically. In microscopic

observation, most regions lacked epithelium and superficial ulcers and exudates were seen; the connective tissue inflammation was extensive.

In the epithelial parts, hyperkeratosis and acanthosis as well as vacuolization of basal and parabasal cells along with atrophy were observed in some regions. In other parts of the epithelium, basilar hyperplasia and loss of cellular polarity in the basal region, along with trivial hyperchromatism and increased nucleus-to-cytoplasm ratio were identified. The results suggested moderate dysplasia (Fig. 1). In our study, the hamsters scarified at 5 weeks only showed epithelial coarseness clinically and mild dysplasia histopathologically. However, in the studies by Chen and Lin [2] and Chen et al, [7] mild dysplasia was observed under the microscope at 3 to 4 weeks. This difference between the results of studies may be due to the outbred nature of our hamsters. In our study, the hamsters sacrificed at 5 weeks only showed mucosal coarseness clinically and mild dysplasia histopathologically. Chen and Lin [2] who reported mild dysplasia at 3 to 4 weeks did not describe clinical changes. Later induction of mild dysplasia in our hamsters may also be due to the older age of our hamsters at the beginning of the study in comparison with their samples (8 weeks old

versus 6 weeks old). One of the differences of our methodology with that of Chen and Lin [2] is that they painted both of the buccal pouches of the hamsters; whereas, we painted one pouch of each animal. Painting of both sides would induce higher mortality (although they did not mention the mortality rate in their study). Even though they used a more toxic dose of the substance overall for each hamster since they painted the pouches bilaterally, this cannot be the reason for earlier induction of dysplasia since the topical effect of DMBA was emphasized in both studies. On the other hand, Shin et al. [4] reported increased printability of hyperplastic basal cell layer at 4 weeks, which was somehow compatible with the results of our study. At 8 weeks, they observed severe dysplasia. In our study, dysplasia was developed later compared with the study by Wani et al [3]. The reason could be the usage of arecaidine promoter, causing development of carcinoma. This study can serve as a guide for future animal studies on dysplastic lesions. We induced the formation of mild and moderate dysplastic lesions in buccal pouch mucosa of hamsters by painting their pouches with DMBA, which can be used by further studies on risk factors and prevention of dysplastic lesions.

#### ACKNOWLEDGMENTS

This study was supported by the Laser Research Center of Dentistry, Dentistry Research Institute, Tehran university of Medical Sciences, Tehran, Iran. grant number: 96-01-97-34912). It was part of a post-graduate thesis by Dr. Elaheh Ghasemzadeh Hoseini (thesis no. T954). The authors appreciate Mr. Mahdi Gholami for his cooperation.

#### CONFLICT OF INTEREST STATEMENT

None declared.

#### REFERENCES

1. Nagini S, Kowshik J. The hamster buccal pouch model of oral carcinogenesis. *Methods Mol Biol.* 2016 Jun;1422:341-50.
2. Chen YK, Lin LM. DMBA-induced hamster buccal pouch carcinoma and VX2-

induced rabbit cancer as a model for human oral carcinogenesis. *Expert Rev Anticancer Ther.* 2010 Sep;10(9):1485-96.

3. Wani MK, Yarber RH, Ahmed A, Hengesteg A, Robbins KT. Cancer induction in the DMBA hamster cheek pouch: a modified technique using a promoter. *Laryngoscope.* 2001 Feb;111(2):204-6.

4. Shin DM, Gimenez IB, Lee JS, Nishioka K, Wargovich MJ, Thacher S, et al. Expression of epidermal growth factor receptor, polyamine levels, ornithine decarboxylase activity, micronuclei, and transglutaminase I in a 7,12-dimethylbenz(a)anthracene-induced hamster buccal pouch carcinogenesis model. *Cancer Res.* 1990 Apr;50(8):2505-10.

5. de CMJS, de Oliveira SC, Reis Junior JA, Gurgel CA, de Souza SC, Pinheiro AL, et al. Effects of imiquimod and low-intensity laser ( $\lambda$ 660 nm) in chemically induced oral carcinomas in hamster buccal pouch mucosa. *Lasers Med Sci.* 2013 May;28(3):1017-24.

6. Mahakian LM, Farwell DG, Zhang H, Seo JW, Poirier B, Tinling SP, et al. Comparison of PET imaging with  $^{64}\text{Cu}$ -liposomes and  $^{18}\text{F}$ -FDG in the 7,12-dimethylbenz[a]anthracene (DMBA)-induced hamster buccal pouch model of oral dysplasia and squamous cell carcinoma. *Mol. Imaging Biol.* 2014 Apr;16(2):284-92.

7. Chen YK, Hsue SS, Lin LM. Immunohistochemical demonstration of p63 in DMBA-induced hamster buccal pouch squamous cell carcinogenesis. *Oral Dis.* 2003 Sep;9(5):235-40.

8. Low KP, Bhuvaneshwari R, Thong PS, Bunte RM, Soo KC. Novel delivery of Chlorin e6 using anti-EGFR antibody tagged virosomes for fluorescence diagnosis of oral cancer in a hamster cheek pouch model. *Eur J Pharm Sci.* 2016 Feb;83:143-54.

9. Parihar A, Dube A, Gupta PK. Photodynamic treatment of oral squamous cell carcinoma in hamster cheek pouch model using chlorin p6-histamine conjugate. *Photodiagnosis Photodyn Ther.* 2013 Feb;10(1):79-86.

10. Lin LM, Chen YK. Creatine kinase isoenzymes activity in serum and buccal pouch tissue of hamsters during DMBA-

induced squamous cell carcinogenesis. *J Oral Pathol Med.* 1991 Nov;20(10):479-85.

11. Heller B, Klufftinger AM, Davis NL, Quenville NF. A modified method of carcinogenesis induction in the DMBA hamster cheek pouch model of squamous neoplasia. *Am J Surg.* 1996 Dec;172(6):678-80.

12. Bampi VF, Vilela WF, Gonçalves RV, Rheingantz MG, Minello LF, da Silva JL, et al. The promoting effect of carbamide peroxide teeth bleaching gel in a preclinical model of head and neck cancer in hamster buccal pouch. *Clin Exp Otorhinolaryngol.* 2014 Sep;7(3):210.

13. Shen L, Xu Q, Li P, Zhou G. Efficacy of krypton laser photodynamic therapy for oral

mucosa dysplasia in 9,10-dimethyl-1,2-benzanthracene-treated hamsters. *Oncol Lett.* 2013 Nov;6(5):1358-1362.

14. Manjunath KS, Raj A, Talukdar JS, Kundu M, Arun PD, Vijayan S. Lasers in the Management of Oral Pre-Malignant Lesions. *Int J Sci Stud* 2015;3(5):183-86.

15. Sudhakara Reddy R, Kotha R, Tataoudi R, Gudapati S, Sai Madhavai N, Sai Kiran CH. Photodynamic Therapy in oral Disease. *Int J Biol Med Res.* 2012 Jan;3(2):1857-83.

16. Salum FG, Cherubini K, de Figueiredo MA, Amado Mde O, Rodrigues ET, Yurgel LS. Histologic evaluation of effect of thiocyanate topical application on hamster cheek pouch. *Clin Oral Investig.* 2006 Sep;10(3):211-5.