



Nephroprotective activity of *Mammea africana* stem bark against paracetamol induced kidney injury

Jude Efiom Okokon*, and Bawo Michael

Department of Pharmacology and Toxicology Faculty of Pharmacy, University of Uyo, Uyo, Nigeria;

*Email: judeefiom@yahoo.com

ARTICLE INFO

Type: Original Research

Topic: Ethnopharmacology

Received 24th June 2014

Accepted 28th July 2014

Key words:

- ✓ *Mammea africana*
- ✓ Nephroprotective
- ✓ Antioxidant
- ✓ Kidney

ABSTRACT

Background & Aim: *Mammea africana* sabin (Guttiferae) stem bark commonly used traditionally to treat various diseases and ailments was evaluated for nephroprotective activity against paracetamol – induced kidney injury in rats to confirm its use in the treatment of kidney diseases.

Experimental: The nephroprotective effect of the extract was evaluated by the determination of some kidney function parameters such as serum urea and creatinine, electrolytes (K^+ , Na^+ , Cl^- and HCO_3^-), antioxidant enzymes (superoxide dismutase (SOD), catalase (CAT), reduced glutathione (GSH), malondialdehyde (MDA) and histopathological study of the liver.

Results & Discussion: The administration of the stem bark extract caused significant dose-dependent reduction of high levels of serum creatinine and urea. The electrolytes levels were not affected. Histology of the kidney sections of extract and silymarin- treated animals showed reductions in the pathological features compared to the paracetamol- treated animals. The chemical pathological changes were consistent with histopathological observations suggesting marked nephroprotective effect of the stem bark extract of *M. africana*

Recommended applications/industries: The results show that the stem bark extract of *Mammea africana* has nephroprotective potential which may be due to its antioxidant effect activity.

1. Introduction

Mammea africana sabin (Guttiferae) (syn. *Ochrocarpus africana* Oliv.) is a large forest tree of 50 to 100 feet high with bark often yellow with pale scales and resinous yellow sap (Hutchison and Daziel, 1958). The plant is widely distributed in tropical Africa. The stem bark of the plant is used traditionally by the Ibibios of Niger Delta region of Nigeria in the treatment of malaria related fever, diabetes, microbial infections and mental disorders. The stem bark is also used traditionally to treat stomach pains,

rheumatisms, scabies, cough and hypertension (Raponda-Walter and Sillans, 1961; Adjanohoun *et al.*, 1996). The stem bark extract have been reported to possess cytotoxic activity on cell culture (Chapuis *et al.*, 1988, Okokon *et al.*, 2012). Ouahou *et al.* (2004) reported cytotoxic coumarins with antimicrobial activity against *Staphylococcus aureus* from the plant stem bark. The stem bark has been reported to possess antiplasmodial (Okokon *et al.*, 2006), cardioprotective (Okokon and Antia, 2007), antidiabetic and hypolipidaemic (Okokon *et al.*, 2007), vasorelaxant

(Dongmo *et al.*, 2007), antihypertensive (Nguelefack-Mbuyo *et al.*, 2008), anti-inflammatory and analgesic (Okokon *et al.*, 2009), antioxidant (Nguelefack-Mbuyo *et al.*, 2010), antidiarrheal and antiulcer (Okokon *et al.*, 2010), immunomodulatory and anti-leishmanial (Okokon *et al.*, 2012), as well as depressant and anticonvulsant activities (Okokon *et al.*, 2014). The stem bark has been reported to contain 5,7-dihydroxy-8-(12-methyl-butyl) -4- N - Pentyl coumarins (Carpenter *et al.*, 1971; Crichton and Waterman, 1978; Carpenter *et al.*, 1970), 4-phenyl and 4-alkylcoumarins (Games, 1972), Mesuxanthone B (Carpenter *et al.*, 1971). Alkaloids have been reported to be absent in the entire plant parts (Garlands *et al.*, 1980).

We, therefore, report in this study the kidney protective activities of the stem bark extract of *M. africana* from Nigeria.

2. Materials and Methods

2.1. Plants collection

The plant material *Mammea africana* (stem barks) were collected in a forest in Uruan area, Akwa Ibom State, Nigeria in April, 2013. The plant was identified and authenticated by Dr. Magaret Basse of Department of Botany and Ecological Studies, University of Uyo, Uyo, Nigeria.

2.2. Extraction

The pieces of the stem bark were washed and shade-dried for two weeks. The dried plants' materials were further chopped into smaller pieces and reduced to powder. The powdered material was soaked in 70% ethanol for 72 h. The liquid filtrates were concentrated and evaporated to dryness in vacuo 40°C using rotary evaporator.

2.3. Animals

Swiss albino rats of either sex (190 – 220 g) that were used for these experiments were obtained from University of Uyo animal house. The animals were housed in standard cages and were maintained on a standard pelleted feed (Guinea feed) and water *ad libitum*. Permission and approval for animal studies were obtained from College of Health Sciences Animal Ethics committee, University of Uyo.

2.4. Animal treatment

A total of 36 rats of both sexes were weighed and divided into six groups of 6 animals each and treated as follows: Groups A consisted of normal animals that were administered with distilled water (0.2 ml/kg), Group B was administered with vehicle control (distilled water, 0.2 ml/kg), while groups C, D and E were respectively administered p.o with 30, 60 and 90 mg/kg of *M. africana* stem bark extract (MASBEX) daily for 8 days. Group F treated with silymarin (100 mg/kg) (standard drug) for the same period of time. Paracetamol, 2 g/kg, was administered to groups B – F on the eighth day. Twenty-four hours after paracetamol administration, the animals were sacrificed under light diethyl ether vapor. Blood were collected by cardiac puncture and used immediately.

2.5 The protective effect of the extract against Paracetamol-induced kidney injury on Biochemical parameters and histology of kidney of rats

The various serum samples collected after treatment of the animals were analyzed according to standard methods for effect of the extract on various biochemical parameters of rats such as uric acid, urea, and creatinine as well as some ions like sodium, potassium and chloride. This analysis were done at Department of Chemical Pathology, University of Uyo Teaching Hospital, (UUTH), Uyo using various diagnostic kits like Randox Laboratory kits, Dialab diagnostic kits, HUMAN diagnostic kits and TECO analytical kits. The kidneys of the animals fixed in 10% formaldehyde were processed, sectioned and stained with Hematoxylin and eosin (H&E) according to standard procedures at Department of Chemical Pathology, University of Uyo Teaching Hospital, Uyo.

2.6. Preparation of renal homogenate

The kidneys were removed and dissected free from the surrounding fat and connective tissue. Each kidney was longitudinally sectioned, and renal cortex was separated and kept at -8°C. Subsequently, renal cortex was homogenized in cold potassium phosphate buffer (0.05 M, pH 7.4). The renal cortical homogenates were centrifuged at 5000rpm for 10 min at 4°C. The resulting supernatant was used for the determination of malondialdehyde (MDA) content (Wilbur *et al.*, 1949; Esterbauer and Cheeseman, 1990), reduced glutathione (GSH) (Ellman, 1959) and antioxidant enzyme levels

such as superoxide dismutase (SOD) (Marklund *et al.*, 1974) and catalase (CAT) (Sinha, 1972) using colorimetric assay.

2.7. Statistical analysis and data evaluation

Data obtained from this work were analyzed statistically using Students't-test and ANOVA (One - way) followed by a post test (Tukey-Kramer multiple comparison test). Differences between means were considered significant at 1% and 5% level of significance i.e $p \leq 0.01$ and 0.05.

3. Results and discussion

In the present study the ethanolic stembark extract of *M. africana* was evaluated for nephroprotective activity against paracetamol-induced nephrotoxicity in rats. Biochemical markers of kidney function like blood urea, serum creatinine, electrolytes levels, tissue GSH, SOD, CAT, and lipid peroxidation were considered for assessing nephroprotective properties. Paracetamol administration exhibited a marked depletion of tissue GSH level with increased lipid peroxidation levels as shown by the increased MDA level. Kidney antioxidative enzymes like SOD and CAT activities were reduced. Significant elevation of serum markers like blood urea and serum creatinine were also observed. Various degrees of histological lesions were observed.

The kidney weights of rats treated with paracetamol were significantly ($p < 0.001$) increased when compared to that of the control group. However, animals in groups pre-treated with the stembark extract (30-90 mg/kg) and silymarin (100 mg/kg) had their kidney weights significantly ($p < 0.01 - 0.001$) reduced (Table 1). This results from the activity of the stembark extract against the damaging effect of paracetamol.

Paracetamol induces acute renal damage by elevating plasma creatinine and blood urea, while depleting glutathione levels with consequent induction of tubular necrosis (Abraham, 2005) as was observed histologically in this study. Blood urea nitrogen is found in the liver protein that is derived from diet or tissue sources and is normally excreted in the urine. In renal disease, the serum urea accumulates because the rate of serum urea production exceeds the rate of clearance. Elevation of urea and creatinine levels in the serum was taken as the index of nephrotoxicity.

Creatinine, on the other hand, is mostly derived from endogenous sources by tissue creatinine breakdown. Thus serum urea concentration is often considered a more reliable renal function predictor than serum creatinine (Palani *et al.*, 2009).

Table 1. Effect of *Mammea africana* stembark extract on Kidney weight in paracetamol-induced kidney injury in rats.

Parameters/Treatment	Kidney(g)
Normal control	1.42±0.06
PCM +Dist. water	2.54±0.04 ^c
MA. 30mg/kg + PCM	1.52±0.08 ^{cd}
MA. 60mg/kg+ PCM	1.48±0.06 ^f
MA. 90mg/kg+ PCM	1.44±0.02 ^f
Silymarin 100mg/kg + PCM	1.53±0.06 ^f

Data were expressed as mean ± SEM. significant at ap< 0.05, bp< 0.01, cp < 0.001 when compared to control. dp< 0.05, ep< 0.01, fp< 0.001 when compared to paracetamol. n = 6.

Treatment of rats with paracetamol (2g/kg) caused significant ($p < 0.001$) elevation of serum urea and creatinine levels when compared to normal control. These increased levels of serum urea and creatinine were significantly ($p < 0.05 - 0.001$) reduced with the pretreatment of the rats with stembark extract of *M. africana* (30 – 90 mg/kg) in a dose dependent fashion. However, the administration of paracetamol did not affect the electrolytes (K^+ , Na^+ , Cl^- and HCO_3^-) levels of rats. Pretreatment of the rats did not also affect the levels of the electrolytes as there was no significant ($p > 0.05$) difference with that of the control rats. (Table 2). These findings further confirm the protective role of the extract.

Paracetamol treatment also caused significant ($p < 0.001$) decreases in the activities of SOD, catalase and GSH levels and significant ($p < 0.001$) increase in the concentration of MDA in kidney tissue when compared with control group (Table 3). Pre-treatment with stembark extract of *M. africana* (30 – 90 mg/kg) resulted in a significant ($p < 0.05 - 0.001$) increase in the activities of SOD, catalase and GSH levels as well as significant ($p < 0.001$) decrease in the concentration of MDA. Silymarin treated animals also showed a significant ($p < 0.001$) increase in antioxidant enzymes; SOD, catalase and GSH levels with significant ($p < 0.001$) decrease in the level of MDA compared to paracetamol treated rats (Table 3).

Large quantities of oxidative free radicals such as superoxide anions and derivatives; especially the highly reactive and damaging hydroxyl radical which

induces peroxidation of cell membrane lipids (Bhattacharya *et al.*, 1999), are generated in living cells. Lipid peroxidation refers to the oxidative stress degradation of lipid in which malondialdehyde (MDA) is one of its end products (Asha *et al.*, 2001). It mostly affects polyunsaturated fatty acids causing tissue damage (Khan *et al.*, 2012) and the elevation in MDA levels in the kidney of paracetamol treated rats as observed in our results, which may be due to the enrichment of cell membrane with polyunsaturated highly oxidizable fatty acids (Cini *et al.*, 1994). Lipid peroxidation (LP) has a relationship with the release of lysosomal enzymes. Hence, LP activates the phospholipases and removes the peroxidized lipid from the membrane (Kappus, 1985). The oxidation of unsaturated fatty acids in biological membranes by free radical leads to a decrease in membrane fluidity and disruption of membrane structure and function (Haragushi *et al.*, 1997). In the present study, MDA level was significantly increased whereas catalase and SOD activities were decreased noticeably in paracetamol treated group as compared to control group. It has been proposed that oxidative stress may be responsible for tubular damage. It is well known that the production of ROS causes cell damage due to cytotoxic action of oxygen and nitrogen derived free radical species.

Natural antioxidant systems are inactivated by lipid peroxidation and reactive oxygen species (ROS) (Halliwell and Gutteridge, 1984). Antioxidants act as cell's defense against free radicals. Enzymatic antioxidants such as SOD, CAT and GPx are the first line of defense against oxidative injury. SOD is the first antioxidant enzyme to deal with oxyradicals by accelerating the dismutation of superoxide radicals (O_2^-) to hydrogen peroxide (H_2O_2). In the present study, significant decreases in SOD and CAT activities in the tissues of paracetamol treated rats were observed. These decreases could have resulted from ineffective scavenging of ROS and possibly, oxidative inactivation of enzymes (Pigeolet *et al.*, 1999). CAT acts as a preventive antioxidant and plays an important role in protecting against the deleterious effects of lipid peroxidation. A significant decrease in catalase activity during paracetamol ingestion indicates inefficient scavenging of H_2O_2 (Mallikarjuna *et al.*, 2008; Husain and Somani, 1997). The results of this study corroborate the above reports. Thus paracetamol

consumption suppresses the activities of these enzymatic antioxidants and renders the cells more susceptible to free radical induced injury. Besides, non-enzymatic antioxidants play significant role in protecting the cells from oxidative damage. Non enzymatic antioxidant systems such as GSH, Vitamin C and E are considered as the second line of defense against free radicals. GSH a major non-protein thiol, considered as an important endogenous defense against peroxidative destruction of cellular membranes. Glutathione reacts directly with ROS and electrophilic metabolites, protects essential thiol groups from oxidation and serves as a substrate for several enzymes including GPx. In this study, the concentration of GSH was significantly reduced in paracetamol treated rats, which corroborates other reports (Fernandez and Videla, 1981; Jaya *et al.*, 1993). The reduced form of GSH therefore becomes readily oxidized to GSSG on interacting with free radicals (Fernandez-Checa *et al.*, 1997). Other antioxidants such as naturally occurring free radical scavengers like vitamin C and E (Yu *et al.*, 1994), also play great role in preventing lipid peroxidation under experimental conditions. Vitamin C (ascorbic acid) is an important H_2O soluble antioxidant in biological fluids and an essential micronutrient required for normal metabolic functioning of the body.

Histopathological study revealed the normal renal architecture in control group showing normal tubular brush borders and intact glomeruli and Bowman's capsule (Figure 6 A). Paracetamol treated rats showed severe damage in the kidney cells observed as variable size and atrophic cellular glomeruli, marked cloudy swelling in tubules, narrow lumens, cortical vascular dilation and congestion, chronic inflammation and destruction of glomeruli, focal cortical degeneration, and chronic inflammatory exudates in the cortex around glomeruli (Figure 6B). Pretreatment with stem bark extract of *M. africana* (30 – 90 mg/kg) and standard drug, Silymarin (100 mg/kg) helped in decreasing the cellular damage induced by Paracetamol. Cellular appearance showed mostly nearly normal glomeruli with few variable size atrophic glomeruli, mild tubular degeneration, glomerular inflammation, necrosis and cloudy swelling (Figure 6 C – F).

Table 2. Effect of ethanolic stem bark extract of *Mammea africana* on some kidney function parameters of rat.

Parameters/Treatment	Na ⁺ (mmol/l)	K ⁺ (mmol/l)	CL(mmol/l)	HCO(mmol/l)	UREA(mmol/l)	Creatinine(mmol/l)
Normal control	136.8±0.73	7.06±0.37	105.8±2.30	25.46±1.25	4.40±0.53	63.46±3.34
PCM +Dist. water	136.0±1.64	7.92±0.59	111.6±2.37	26.10±0.96	12.02±0.95 ^c	95.48 ±3.11 ^c
MA. 30mg/kg + PCM	136.2±1.06	8.64±0.93	107.8±2.95	27.04± 1.21	6.76±0.67 ^f	75.38±6.36 ^d
MA. 60mg/kg+ PCM	131.6 ± 3.72	7.98±0.85	106.4±2.65	25.57± 0.97	5.96±0.95 ^f	69.68±4.51 ^e
MA. 90mg/kg+ PCM	138.2 ± 1.77	7.28±0.41	109.8±3.21	27.45± 0.65	5.36±0.47 ^f	68.40±2.98 ^f
Silymarin 100 mg/kg + PCM	136.8±1.59	7.66±0.49	108.6±1.16	27.72± 0.75	5.92±0.95 ^f	69.54±2.36 ^f

Data were expressed as mean ± SEM. significant at ap< 0.05, bp< 0.01, cp< 0.001 when compared to control. dp< 0.05, ep< 0.01, fp< 0.001 when compared to paracetamol. n = 6.

Table 3. Effect of *Mammea africana* stem bark extract on kidney antioxidant enzymes in paracetamol-induced kidney injury in rats.

Parameters/Treatment	SOD(U/mg of protein)	CAT(U/mg of protein)	MDA(U/mg of protein)	GSH(µg/mg of protein)
Normal control	20.26 ±0.86	45.38±1.86	46.42±3.66	0.30±0.01
PCM +Dist. water	7.33 ± 0.22 ^c	23.20±1.64 ^c	84.34±4.42 ^c	0.10±0.01 ^c
MA. 30mg/kg + PCM	10.18±0.16 ^{cd}	32.02±1.38 ^{cd}	62.12±4.54 ^c	0.16±0.02 ^{ce}
MA. 60mg/kg+ PCM	15.26 ±0. 28 ^{bf}	35.11±1.41 ^f	54.86±2.25 ^{cf}	0.20±0.02 ^{bf}
MA. 90mg/kg+ PCM	17.78± 0.19 ^{cf}	41.12±1.22 ^f	48.24±1.65 ^{bf}	0.22±0.01 ^{af}
Silymarin 100mg/kg + PCM	19.45 ±0.28 ^{cf}	53.25± 1.33 ^f	48.86±1.14 ^f	0.25±0.01 ^f

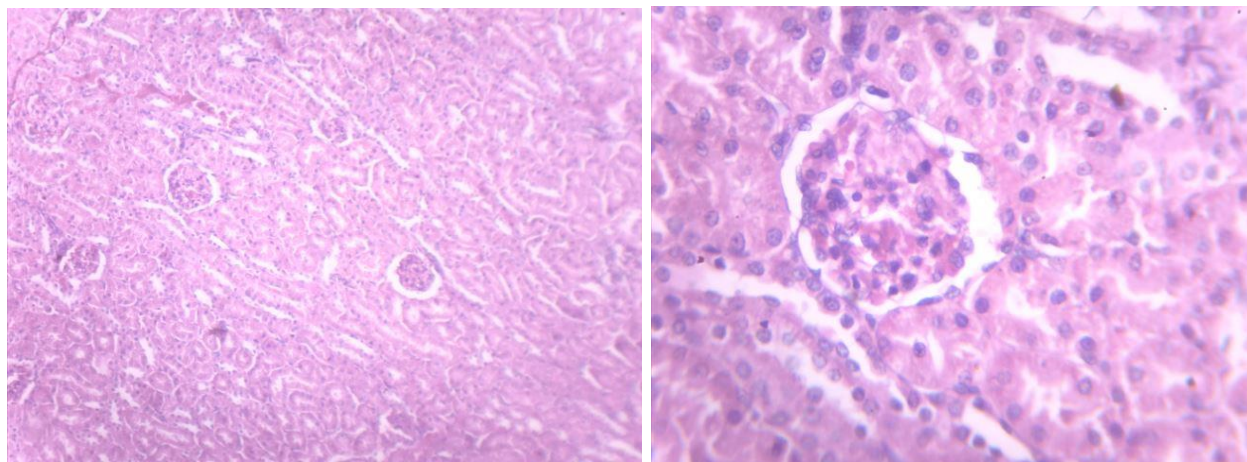
Data were expressed as mean ± SEM. significant at ap< 0.05, bp< 0.01, cp< 0.001 when compared to control. dp< 0.05, ep< 0.01, fp< 0.001 when compared to paracetamol. n = 6.

Table 4. Effect of treatment with ethanolic extract of *Mammea africana* on the blood hematological parameters, in rats with paracetamol -induced nephrotoxicity.

Parameters Treatment Dose (mg/kg)	RBC (X 10 ¹² /l)	PCV(%)	Hb(g/dl)	WBC (X 10 ⁹ /l)	Neutrophils. (%)	Lymphocytes (%)	Monocytes (%)	Eosinophils (%)	Basophils (%)
Normal control	3.82±0.32	44.2±10.37	14.8±0.12	11.4±1.85	20.2±1.42	73.8±1.06	2.00±0.05	4.0±0.37	2.20±0.40
PCM +Dist. water	3.08±0.34	44.4±1.80	14.82±0.52	10.74±1.80	41.60±1.23 ^c	54.4±2.39 ^c	1.0±0.02 ^c	2.80±0.96 ^a	0.2±0.20 ^c
MA. 30mg/kg + PCM	3.98±0.52	46.2±1.24	15.4±0.34	9.92±1.28	36.9±1.65 ^c	62.6±2.47 ^b	1.0±0.01 ^c	0.00±0.00 ^{ce}	0.00±0.00 ^c
MA. 60mg/kg+ PCM	4.13±0.26	43.5±2.63	14.62±0.63	9.80±1.34	43.2±2.02 ^c	56.6±2.30 ^c	0.4±0.04 ^{cf}	0.2±0.20 ^{ce}	0.00±0.00 ^c
MA. 90mg/kg+ PCM	4.18±0.60	44.8±1.15	14.62±0.34	11.36±1.24	35.8±2.66 ^c	61.2±1.57 ^b	0.8±0.02 ^{ce}	2.00±0.14 ^a	0.00±0.00 ^c
Silymarin 100mg/kg+ PCM	4.05±0.12	43.2±1.56	14.8±0.12	9.66±2.34	30.4±1.47 ^{bf}	68.2±2.57 ^e	1.0±0.04 ^c	0.4±0.40 ^{ce}	0.00±0.00 ^c

Data were expressed as mean ± SEM. significant at ap< 0.05, bp< 0.01, cp< 0.001 when compared to control. dp< 0.05, ep< 0.01, fp< 0.001 when compared to paracetamol . n = 6.

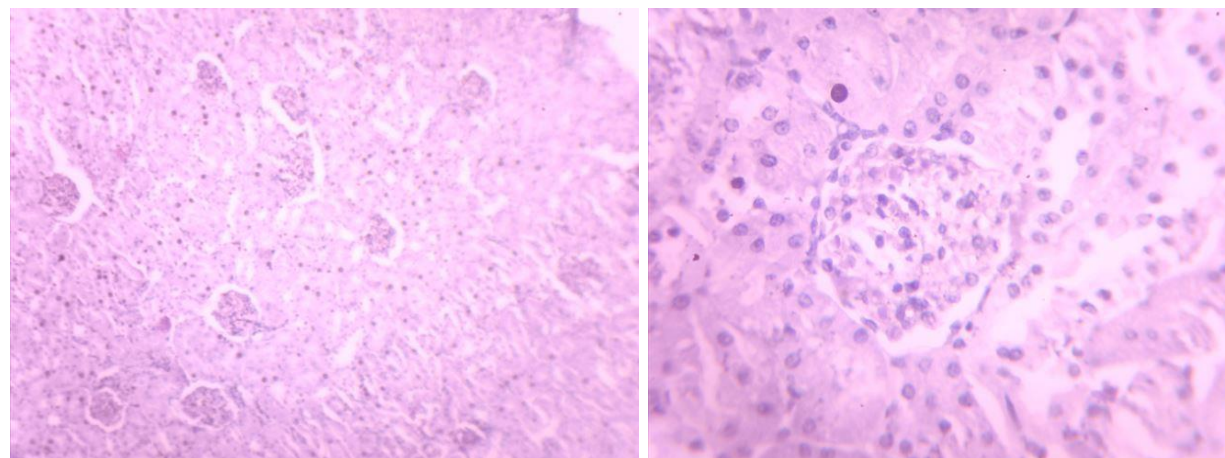
GROUP - A



Keys: *RC* –Renal corpuscle, *PCT*- proximal convoluted tubules, *DCT*- Distal convoluted tubules, *G*- glomerulus, *SEL* – Squamous epithelial lining, *C* – Cortex and *M* – Medulla, *LH*- loop of Henles, *CT*- Collecting ducts

Figure 1 - A(X100) and B(X400) of Kidney tissue without treatment revealed normal cellular pattern with area of distal and proximal convoluted tubules, renal corpuscle, collecting tubules and loop of Henles, no abnormality seen.

GROUP - B



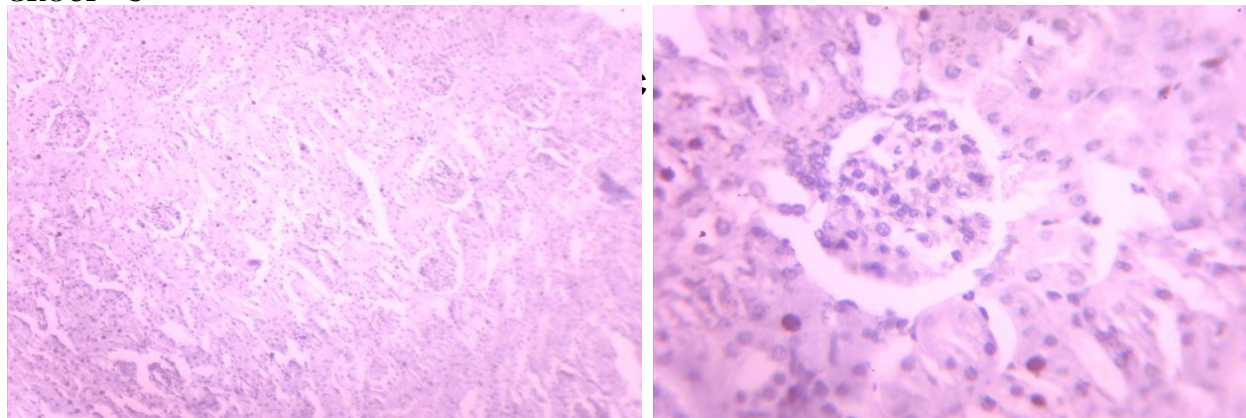
Keys: *RC* –Renal corpuscle, *GI*- Glomerular inflammation, *PCT*- proximal convoluted tubules, *DCT*- Distal convoluted tubules, *H* – Hyperplasia, *G*- glomerulus, *ELD* –epithelial lining degeneration, *C* – Cortex and *M* – Medulla, *LH*- loop of Henles, *CT*- Collecting ducts

Figure 1. C(X100) and D(X400) of Kidney tissue treated with 2mg/kg of PCM revealed severe glomerular inflammation, cellular and vascular degeneration as compared to normal control group.

In the kidney, p-amino phenol is normally formed from paracetamol by deacetylation and excreted in urine. This exposes the kidney to damage by p-amino phenol as it plays a major role in the pathogenesis of paracetamol induced renal damage (Carpenter and Mudge, 1981; Mugford and Tarloff, 1997). Hepatically derived glutathione conjugates are also involved in paracetamol induced renal injury (Trumper *et al.*, 1996)

as well as nitric oxide (Li *et al.*, 2003). Kidneys are involved in the excretion of various xenobiotics, pollutants, toxins and are exposed to high quantities of free radicals which contribute to high oxidative stress. This is responsible for the pathogenesis of kidney damage. Since the paracetamol induced nephrotoxicity was reported to be via NAPQI radical.

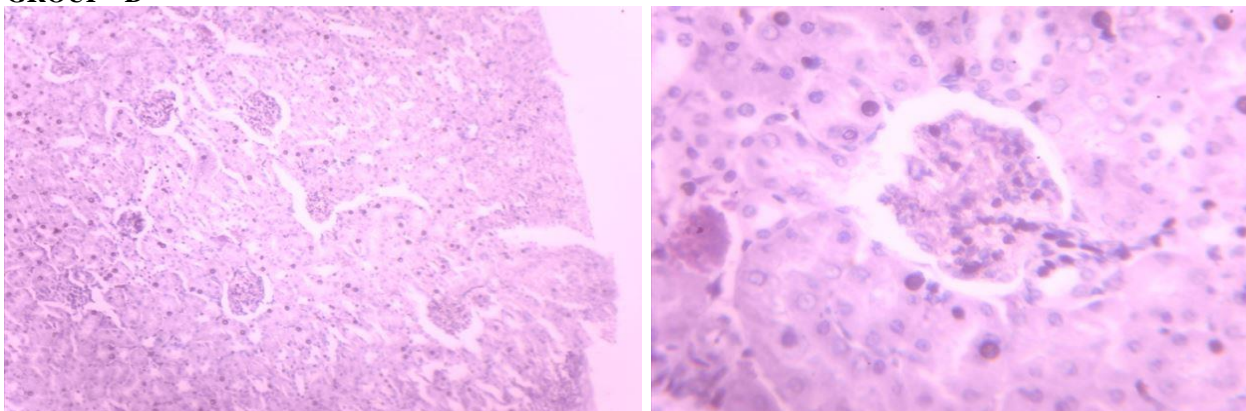
GROUP - C



Keys: *RC* –Renal corpuscle, *GI*- Glomerular inflammation, *PCT*- proximal convoluted tubules, *DCT*- Distal convoluted tubules, *H* – Hyperplasia, *G*- glomerulus, *ELD* –epithelial lining degeneration, *C* – Cortex and *M* – Medulla, *LH*- loop of Henles, *CT*- Collecting ducts

Figure 1 - E(X100) and F(X400) of Kidney tissue treated with 30 mg/kg of *Mammea africana* revealed glomerular inflammation as compared to normal control group.

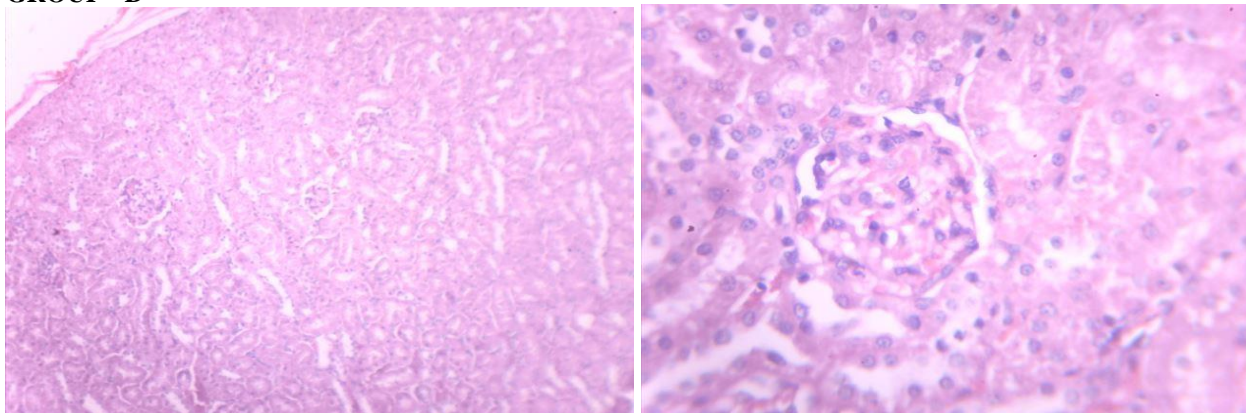
GROUP - D



Keys: *RC* –Renal corpuscle, *GI*- Glomerular inflammation, *PCT*- proximal convoluted tubules, *DCT*- Distal convoluted tubules, *H* – Hyperplasia, *G*- glomerulus, *ELD* –epithelial lining degeneration, *C* – Cortex and *M* – Medulla, *LH*- loop of Henles, *CT*- Collecting ducts

Figure 1 - G(X100) and H(X400) of Kidney tissue treated with 60 mg/kg of *Mammea africana* revealed mild glomerular inflammation as compared to normal control group

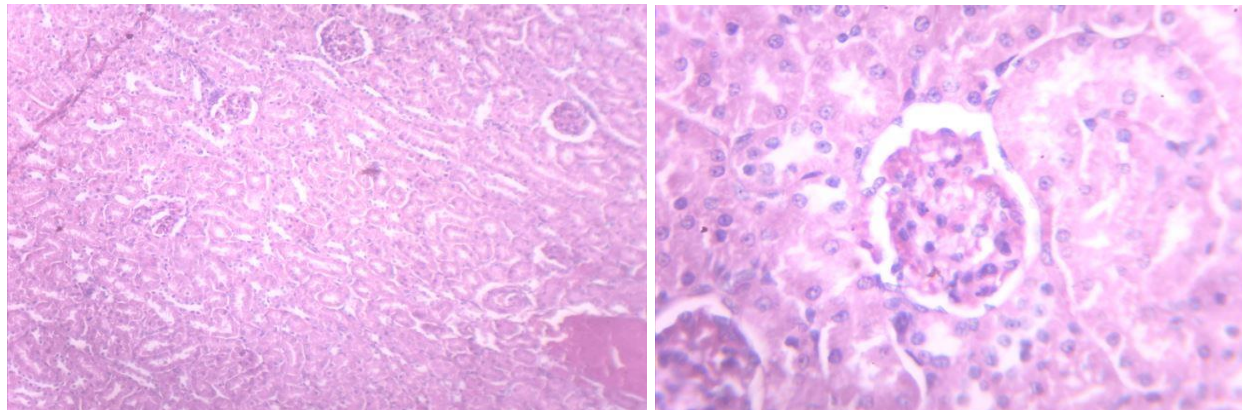
GROUP - D



Keys: *RC* –Renal corpuscle, *PCT*- proximal convoluted tubules, *DCT*- Distal convoluted tubules, *G*- glomerulus, *SEL* –Squamous epithelial lining, *C* – Cortex and *M* – Medulla, *LH*- loop of Henles, *CT*- Collecting ducts.

Figure 1 - I(X100) and J(X400) of Kidney tissue treated with 90 mg/kg of *Mammea africana* revealed mild glomerular

GROUP - F



Keys: *RC* –Renal corpuscle, *GI*- Glomerular inflammation, *PCT*- proximal convoluted tubules, *DCT*- Distal convoluted tubules, *G*- glomerulus, *ELD* –epithelial lining degeneration, *C* – Cortex and *M* – Medulla, *LH*- loop of Henles, *CT*- Collecting ducts

Figure 1 - K(X100) and L(X400) of Kidney tissue treated with Sylamrin revealed mild glomerular inflammation as compared to normal control group.

Co-administration of test extract normalized tissue lipid peroxidation level and prevented the reduction of tissue GSH level as well as activities of antioxidant enzymes. The nephro protective property of the extract is further confirmed by significant improvement of the kidney architecture by reversing the glomerular congestion, interstium with inflammatory cells, tubular necrosis, peritubular necrosis and basement degeneration over paracetamol administered group.

The stembark extract and fractions have been reported to exhibit strong cellular antioxidant activity in whole blood, neutrophils (extracellular and intracellular) and macrophages (Okokon *et al.*, 2013). Similarly, the cytotoxic coumarins isolated from the stembark have also been reported to exert strong antioxidant activity (Nguelefack-Mbuyo *et al.*, 2010). This activity demonstrate the potential of the extract to inhibit reactive oxygen species (ROS) and scavenge free radicals; superoxide, hydrogen peroxide, etc which can be attributable to the presence of coumarins and other phenolic compounds in the stembark as reported earlier (Carpenter *et al.*, 1970; Carpenter *et al.*, 1971; Games, 1972; Crichton and Waterman, 1978; Ouahou *et al.*, 2004; Okokon *et al.*, 2013).

The strong antioxidant activities of antioxidant counteract the redox state precipitated intracellular and hence ensure nephroprotection against paracetamol

-induced kidney injury. The antioxidant activity of this extract may as well explain the mechanism of action of the observed hepatoprotective activity of *Mammea africana*. Besides, *M. africana* stem bark extract has been reported to possess renal protective activity on L-NAME hypertensive rats as well as caused transient diuretic effect at high doses (Nguelefack-Mbuyo *et al.*, 2010).

4. Conclusion

The findings of this study further support the renal protective potential of stembark of *M. africana* which can be attributed to its antioxidant and diuretic properties which are important in renal protective activities of medicinal plants. Hence, the stembark of *Mammea africana* possess nephroprotective active against paracetamol induced kidney injury.

5. Acknowledgement

The authors are grateful to Mr Adewale Adebisi of Department of Anatomy, University of Uyo, for his Technical assistance

6. References

- Abraham, P. 2005. Oxidative stress in paracetamol induced pathogenesis: (I) renal damage. *Indian Journal of Biochemistry and Biophysics.*, 42: 59-62.
- Adjanohoun, J.E., Aboubakar, N., Dramane, K., Ebot, M. E., Ekpere, J.A., Enoworok, E.G., Foncho, D., Gbile, Z. O., Kamanyi, A., Kamoukom, J., Keeta, A., Mbenkum, T., Mbi, C.M., Mbielle, A.L., Mbome, I.L., Mubiru, N.K., Naney, W.L., Nkongmeneck, B., Satabie, B., Sofowora, A., Tanze, V. and Wirmum, C. K. 1996. *Traditional Medicine and Pharmacopeia-Contribution to Ethnobotanical and Floristic Studies in Cameroon*. Porto-Novo, Benin: CNPMS, p. 15.
- Asha, V.V. 2001. Preliminary studies on hepatoprotective activities of *Momordica sabangulata* and *Naragama alat*. *Indian Journal of Pharmacology.*, 33: 276-279.
- Bhattacharya, A., Chatterjee, A., Ghosal, S. and Bhattacharya, S. K. 1999. Antioxidant activity of active tannoid principles of *Embllica officinalis* (amla). *Indian Journal of Experimental Biology.*, 37: 676-680.
- Carpenter, H.M. and Mudge, G.H. 1981. Acetaminophen nephrotoxicity: studies on renal acetylation and deacetylation. *Journal of Pharmacology and Experimental Therapeutics.*, 218: 161-167.
- Carpenter I, Mc Garry EJ. and Scheimann F. 1970. The neoflavonoids and 4-alkylcoumarins from *Mammea africana* G. Don. *Tetrahedron Letters.*, 46: 3983 - 3986.
- Carpenter, I., Mc Garry, E. J. and Scheimann, F. 1971. Extractives from Guttiferae. Part XXI. The isolation and structure of nine coumarins from the bark of *Mammea africana* G. Don. *Journal of Chemical Society.*, 22: 3783 - 3789.
- Chapius, J. C., Sordat, B., Hostettman, K. 1988. Screening for cytotoxic activities of Plants used in traditional Medicine. *Journal of Ethnopharmacology.*, 2322 (2/3): 273 - 284.
- Cini, M., Fariello, R.Y., Bianchettei, A. and Morettei, A. 1994. Studies on lipid peroxidation in the rat brain. *Neurochemical Research.*, 19:283.
- Crichton, E.G. and Waterman, P. G. 1978. Dihydromammea c/ob: A New Coumarin from the seed of *Mammea africana*. *Phytochemistry* 17: 1783 - 1786.
- Dongmo, A.B., Azebaze, A. and Nguielefack, T.B. 2007. Vasodilator effect of the extracts and some coumarins from the stem bark of *Mammea africana* (Guttiferae). *Journal of Ethnopharmacology.*, 111:329 - 334.
- Ellman, G. L. 1959. Tissue sulfhydryl groups. *Archives of Biochemistry and Biophysics.*, 82, 70-77.
- Esterbauer, H. and Cheeseman, K.H. 1990. Determination of aldehydic lipid peroxidation products: malonaldehyde and 4-hydroxynonenal. *Methods in Enzymology.*, 186: 407-421.
- Fernandez, V. and Videla, I. A. 1981. Effect of acute and chronic ethanol ingestion on the content of reduced glutathione on various tissues of the rat. *Experientia.*, 37:392-394.
- Fernández-Checa, J.C., Kaplowitz, N., García-Ruiz, C., Colell, A., Miranda, M., Marí, M., Ardite, E. and Morales, A. 1997. GSH transport in mitochondria: defense against TNF-induced oxidative stress and alcohol induced defect. *American Journal of Physiology.*, 273:7-17.
- Games, D. E. 1972. Identification of 4-phenyl and 4-alkylcoumarins in *Mammea Americana*, *Mammea africana* and *Calophyllum ionophyllum* by gas chromatography - mass spectrometry. *Tetrahedron.*, 31: 3187 - 3190.
- Garlans, J. S., Key, D. B., Waterman, P. G., Mbi, C. N. and Struhsaker, T. T. 1980. Comparative study of the Phytochemistry of two African rain forests. *Biochemical Systematics and Ecology.*, 8: 401- 422.
- Halliwell, B. and Gutteridge, J. M. 1984. Oxygen toxicity, oxygen radicals, transition metals and disease. *Biochemical Journal.*, 219: 1-14.
- Haragushi, H., Ishikawa, H. and Kubo, I. 1997. Antioxidant action of diterpenoids from *Prodocarpas nagi*, *Planta Medica.*, 63: 213-215.
- Husain, K., Somani, S. M. 1997. Interaction of exercise and ethanol and hepatic and plasma antioxidant system in rat. *Pathophysiology.*, 4:60-74.
- Hutchinson, L. J. and Daziel, J.M. 1958. *Flora of West Tropical Africa*, revised by R. W. J. Keay. Vol.1, part 2, 2nd edition. White Press, London.
- Jaya, D.S., Augustine, J., Menon, V. P. 1993. Role of lipid peroxides, glutathione and antiperoxidative enzymes in alcohol and drug toxicity. *Indian Journal of Experimental Biology.*, 31:453-459.
- Kappus, H. 1985. *Oxidative stress* Academic Press, London, 273.

- Khan, R.A., Khan, M.R., Sahreen, S. and Ahmed, M. 2012. Evaluation of phenolic contents and antioxidant activity of various solvent extracts of *Sonchus asper* (L.) Hill. *Chemistry Central Journal*, 6: 12.
- Li, C., Lui, J., Saaedra, J.E., Keefer, L.K. and Waalkes, M.P. 2003. The Nitric oxide donor, V-PYRRO/NO, protects against acetaminophen-induced nephrotoxicity in mice. *Toxicology*, 189: 173-80.
- Mallikarjuna, K., Sahitya, P., Sathyavelu, K. and Rajendra, W. 2008. Ethanol toxicity: Rehabilitation of hepatic antioxidant defense system with dietary ginger. *Fitoterapia*, 79: 174-178.
- Marklund, S., Marklund, G. 1974. Involvement of superoxide anion radical in the autooxidation of pyrogallol and a convenient assay for superoxide dismutase. *European Journal Biochemistry*, 47: 469-474.
- Mingatto, F. E., dos Santos, A. C., Rodrigues, T., Pigoso, A. A., Uyemura, S. A. and Curti, C. 2000. Effects of nimesulide and its reduced metabolite on mitochondria. *British Journal of Pharmacology*, 131: 1154-1160.
- Mitchell, J.R., Jollow, D. J., Potter, W. Z., Davis, D. C., Gillette, J. R. and Brodie, B. B. 1973. Acetaminophen-induced hepatic necrosis. 1. Role of drug metabolism. *Journal of Pharmacology and Experimental Therapeutics*, 187: 185-194.
- Mugford, C.A. and Tarloff, J.B. 1997. The contribution of oxidation and deacetylation to acetaminophen nephrotoxicity in female Sprague-Dawley rats. *Toxicological Letter*, 93: 15-18.
- Nguelefack-Mbuyo, E.P., Dimo, T., Nguelefack, T.B., Azebaze, A.G., Dongmo, A.B., Kamtchouing, P. and Kamanyi, A. 2010. In vitro antioxidant activity of extracts and coumarins from the stem bark of *Mammea africana* Sabine. *Journal of Complementary and Integrative Medicine*, 7(1): 1-11.
- Nguelefack-Mbuyo, P. E., Nguelefack, T. B. and Dongmo, A. B. 2008. Anti-hypertensive effects of the methanol/methylene chloride stem bark extract of *Mammea africana* in L-NAME- induced hypertensive rats. *Journal of Ethnopharmacology*, 117: 446 – 450.
- Okokon, J.E., Dar, A. and Choudhary, M. I. 2012. Immunostimulatory, Anticancer, and antileishmanial activities of *Mammea africana* from Nigeria. *Journal of Natural Pharmaceuticals*, 3(2): 105 - 109.
- Okokon, J. E. and Antia, B. S. 2007. Hypolipidaemic and Cardioprotective activity of *Mammea africana*. *Research Journal Medicinal Plants*, 1(4): 154 – 157.
- Okokon, J. E., Antia, B. S., Osuji, L., Udia, P. M. 2007. Antidiabetic and Hypolipidaemic activity of ethanolic stem bark extract of *Mammea africana*. *Journal of Pharmacology and Toxicology*, 2: 278 - 283.
- Okokon, J.E and Davies, K. 2014. Psychopharmacological studies of *Mammea africana* stem bark extract. *The Journal of Phytopharmacology*, 4 (3): (In Press)
- Okokon, J. E., Udokpoh, A. E. and Essiet, G. A. 2006. Antimalarial Activity of *Mammea africana*. *African Journal of Traditional, Complementary and Alternative Medicine*, 3: 43 – 49.
- Okokon, J. E., Umoh, E. and Umoh, U. 2009. Antiinflammatory and antinociceptive effects of ethanolic stem bark extract of *Mammea africana*. *Journal of Biomedical Research*, 12(2): 135 – 139.
- Okokon, J.E., Umoh, U. F., Umoh, E. E. and Etim E. I. 2010. Antiulcer and anti diarrhoeal activity of *Mammea africana*. *Iranian Journal of Pharmacology and Therapeutics*, 9(2): 96-101.
- Ouahouo, B. M. W., Asebaze, A. G. B., Meyer, M., Bodo, B., Fomum, Z.T. and Ngengfack, A. E. 2004. Cytotoxic and antimicrobial coumarins from *Mammea africana*. *Annals of Tropical Medicine and Parasitology*, 98: 737 – 739.
- Palani, S., Raja, S., Rajalingam, D., Praveen Kumar, R. and Senthil Kumar B. 2009. Therapeutic efficacy of *Pimpinella tirupatiensis* (Apiaceae) on acetaminophen induced nephrotoxicity and oxidative stress in male albino rats, *International Journal of PharmTech Research*, 1(3): 925-934
- Pigeolet, E., Corbisier, P., Houbion, A., Lambert, D., Michiels, C. and Raes, M. 1999. Antioxidant and oxidative stress in exercise. *Experimental Biology and Medicine*, 22: 283-292.
- Raponda-Walker, A. and Sillans, R. 1961. Les plantes utiles du Gabon. Paris: Paul Lechevalier.
- Sinha, A. K. 1972. Colorimetric assay of catalase. *Analytical Biochemistry*, 47: 389-94.
- Trumper, L., Mansterolo, L.A. and Elias, M. M. 1996. Nephrotoxicity of acetaminophen in male Wistar

rats: role of hepatically derived metabolites.

Journal of Pharmacology and Experimental Therapeutics., 279: 548 - 554

Wilbur, K. M., Bernhein, F. and Shapiro, O.W.1949.

Determination of lipid peroxidation. *Archives of Biochemistry.*, 24: 305-310.

Yu, B.P. 1994. Cellular defenses against damage from

reactive oxygen species. *Physiological Reviews.*, 74: 139-162.