

Treatment of Ankyloglossia with Carbon Dioxide (CO₂) Laser in a Pediatric Patient

Nasim Chiniforush¹, Sara Ghadimi², Nazli Yarahmadi³, Abbas Kamali⁴

¹Laser Research Center of Dentistry (LRCD), School of Dentistry, Tehran University of Medical Sciences, Tehran, Iran

²Laser Research Center of Dentistry (LRCD), Tehran University of Medical Sciences, Tehran, Iran

³Tehran University of Medical Sciences, Tehran, Iran

⁴Periodontist

Abstract:

Introduction: Laser surgery as an alternative for conventional surgical procedure has gained special attention. Using Carbon Dioxide (CO₂) laser has some benefits like less post-operative pain, swelling and infection, decrease in risk of metastasis and edema, and less bleeding providing dry sites for surgery.

Case Report: A 12 years old boy with lingual frenum with indication for excision was referred to the laser department of Tehran University of medical sciences dental school. CO₂ laser was used with 10600 nm wavelength, 1.5 W output power, 100 Hz frequency and 400 µsec pulse duration in non-contact mode.

Results: The result of using CO₂ laser was dry and bloodless field during operation, no post operative swelling, no pain or discomfort, with normal healing process.

Conclusion: We suggest and stimulate the use of CO₂ laser for soft tissue surgery because of elimination of suture, convenient coagulation, time saving, patients' comfort and easy manipulation.

Keywords: lingual frenums; CO₂ laser; laser surgery

Please cite this article as follows:

Chiniforush N, Ghadimi S, Yarahmadi N, Kamali A. Treatment of Ankyloglossia with CO₂ Laser in a Pediatric Patient. J Lasers Med Sci 2013; 4(1):53-5

***Corresponding Author:** Sara Ghadimi, Assistant Professor of Pediatric Dentistry, Laser Research Center of Dentistry (LRCD), Tehran University of Medical Sciences, Tehran, Iran. Tel: +98-2188015017; Fax: +98-2188015800; Email: ghadimi.sara@gmail.com

Introduction

The development of tongues starts at approximately 4 weeks and first, second, and third pharyngeal arches have a role in its creation. Then, on both sides of front part of tongue, U-shaped sulcus develops. So, the tongue gains the ability to move freely except in lingual frenulum area where it is attached. Tongue tie or ankyloglossia is formed by disturbances during this stage (1).

Ankyloglossia or tongue tie caused by short, thick or tight lingual frenum limits tongue's mobility (2,3).

Besides, short frenum leads to breastfeeding problems, including sore and damaged nipples and

insufficient feeding can be followed by lower weight gain in these infants (3). In past years, conventional frenectomy (scalpel and suturing) was the only way to remove the abnormal frenum. Recently, laser surgery as an alternative for conventional frenectomies was introduced (4,5) and various studies showed the ability of carbon dioxide (CO₂) laser for conservative management of oral diseases (6,7).

Using CO₂ laser has some benefits like less post-operative pain, swelling and infection, decrease in risk of metastasis and edema, less bleeding providing dry sites for surgery, minimal wound contraction and scarring and no need for sutures. On the other hand, only some disadvantages are reported such as a slightly

delay on healing due to the thermal damage around the irradiation site, high cost of the equipment, and need of surgeon's skill on laser application (8).

Case Report

A 12- year-old boy referred to laser department of the dental school of Tehran University of Medical Sciences with the complaint of limited mobility of tongue and speech problems (Figures 1A, B)

Patient's medical history was non-contributory. Patient was given oral hygiene instructions. Parental informed written consent was taken after explaining the procedure to them.

Procedure was performed without local anesthesia. Tip of tongue was caught and firmly restricted during the surgical procedure. CO₂ laser (Smart US20D, Deka, Italy) was used with 10600 nm wavelength, 1.5 W output power, 100 Hz frequency, 400 μ sec pulse duration and 47.77 W/Cm² power density in non-contact mode with a distance of 1 or 2 mm above

the surface. All laser safety measures were followed during procedure. The child and dentist's eyes were protected with laser glasses.

Complete dissection was performed by separating the fibers (Figures 2A, B). Neither sutures after excision, nor wound dressing were applied.

The child was advised to resume normal soft diet as tolerated. Good initial healing was noticed after 7 days (Figure 3) He reported increase in tongue mobility following surgery and was also satisfied regarding his social problem. Speech articulation problems were improved by speech therapy.

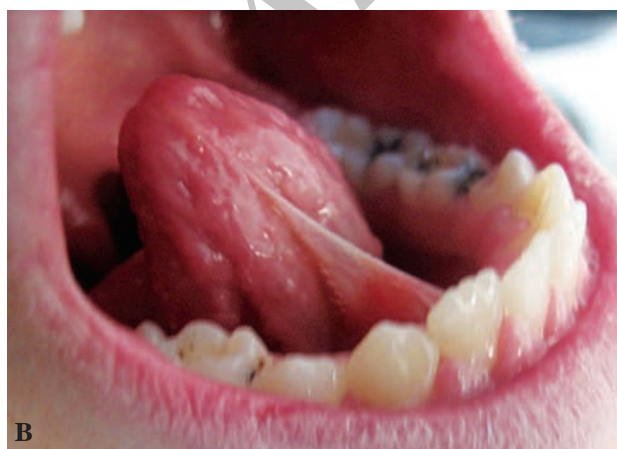
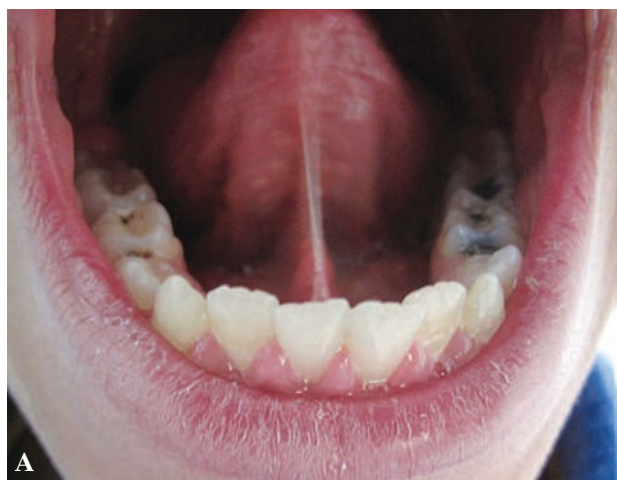

Figure 1A, B. The front and lateral view of ankyloglossia in pediatric patient

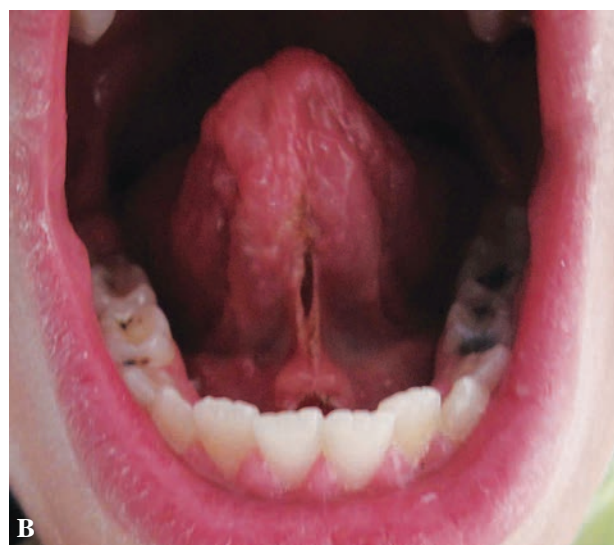
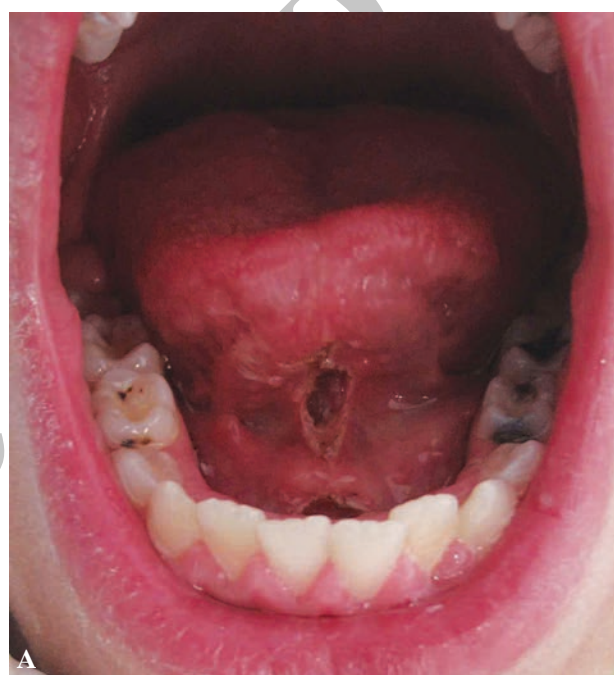
Figure 2A, B. Immediately after procedure

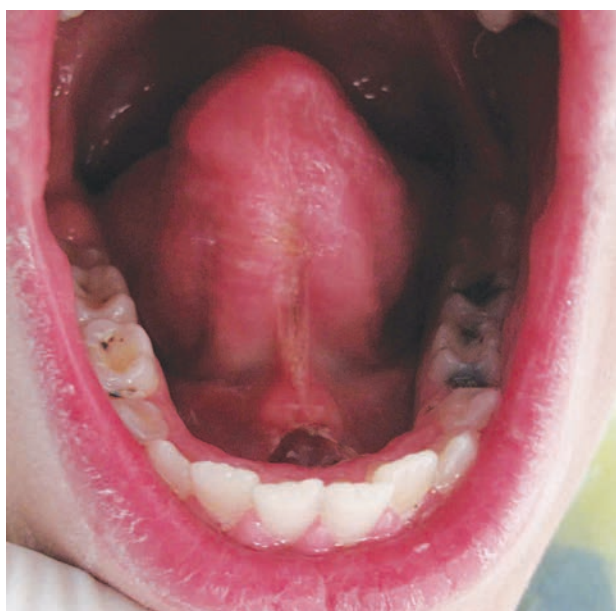

Figure 3. The follow up session after 7 days

Discussion

Different types of lasers are used on hard and soft tissues procedures in oral cavity according to their different wavelengths and their interaction with tissues. In this study we used CO₂ laser with wavelength of 10600 nm and output power of 1.5 W, frequency of 100 Hz and pulse duration of 400 μ sec in non-contact mode. CO₂ laser just like other lasers have a uniform depth due to its characteristics and this can reduce unwanted damage to underlying tissues (9).

Providing local hemostasis, cauterization of nerve endings and sealing of lymphatic vessels make CO₂ laser suitable for surgical procedures. In addition, sterilization of the wound surface offered by high temperature generated by the laser. Cauterization of the nerve endings results in less postoperative pain and avoidance of use of pain killers (8,10). No analgesics were prescribed to our patient and he did not complain of pain in the postoperative course.

Due to laser capability of sterilization of the site, the risk of infection is reduced which avoids the use of antibiotic therapy (8). In this case no antibiotic was prescribed to the child and no signs of local infection were seen on follow up.

It has been shown that the presence of myofibroblasts on CO₂ laser wound is sparse compared to scalpel wounds which lead to minimized scar formation (10). No sutures are used on CO₂ laser wounds and the

healing procedure obtained by second intention.

Another important aspect of laser application especially in children is the reduction in surgical time and lessened stress and fear of child during surgery which can be considered as an important criteria for behavior management of child (11).

Conclusion

We suggest and stimulate the use of CO₂ laser for soft tissue surgery because of elimination of suture, convenient coagulation, time saving, patients' comfort and easy manipulation.

References

1. Patel PK and Shyamsunder NB. Head and Neck Embryology. [updated 2012 Jan 31; cited 2012 Oct 21]. Available from: [http:// emedicine.medscape.com/article/1289057-overview](http://emedicine.medscape.com/article/1289057-overview)
2. Jackson R. Improving breast feeding outcomes: the impact of tongue-tie. *Community Pract* 2012 ;85(6):42-4.
3. Edmunds J, Miles SC, Fulbrook P. Tongue-tie and breastfeeding: a review of the literature. *Breastfeed Rev*. 2011 Mar;19(1):19-26.
4. Epstein SR. The frenectomy: a comparison of classic versus laser technique. *Pract Periodontics Aesthet Dent* 1991;3(5):27-30.
5. Haytac MC, Ozcelik O. Evaluation of patient perceptions after frenectomy operations: a comparison of carbon dioxide laser and scalpel techniques. *J Periodontol* 2006 ;77(11):1815-9.
6. De Magalhaes-Junior EB, Aciole GT, Santos NR, dos Santos JN, Pinheiro AL. Removal of oral lichen planus by CO₂ laser. *Braz Dent J* 2011;22(6):522-6.
7. Jerjes W, Hamdoon Z, Hopper C. CO₂ lasers in the management of potentially malignant and malignant oral disorders. *Head Neck Oncol* 2012;4(1):17.
8. Gama SK, de Araújo TM, Pinheiro AL. Benefits of the use of the CO₂ laser in orthodontics. *Lasers Med Sci* 2008 23(4):459-65.
9. Puthussery FJ, Shekar K, Gulati A, Downie IP. Use of carbon dioxide laser in lingual frenectomy. *Br J Oral Maxillofac Surg* 2011;49(7):580-1.
10. Aciole GT, Aciole JM, Soares LG, Santos NR, Santos JN, Pinheiro AL. Surgical Treatment of Oral Lymphangiomas with CO₂ Laser: Report of Two Uncommon Cases *Braz Dent J* 2010; 21(4): 5-369.
11. Ghadimi S, Chiniforush N, Bouraima SA, Johari M. Clinical approach of laser application in different aspects of pediatric dentistry. *J Lasers Med Sci* 2012; 3(2):84-90.