

# Photothrombosis of Corneal Neovascularization by Photodynamic Therapy Utilizing Verteporfin and Diode Laser

Aziza Ahmed Hassan<sup>1</sup>, Dina Foad Ghoneim<sup>1</sup>, Amr Abdelraheem El-dib<sup>1</sup>, Salwa Abdelkawi Ahmed<sup>2</sup>, Ahmed Medhat Abdel- Salam<sup>1</sup>

<sup>1</sup>Ophthalmic Department, National Institute of Laser Enhanced Science, Cairo University, Egypt.

<sup>2</sup>Department of Vision Science, Biophysics and Laser Science Unit, Research Institute of Ophthalmology, Giza, Egypt.

## Abstract:

**Introduction:** The aim of the present study was to evaluate the effect of photodynamic therapy in the treatment of experimental corneal neovascularization (NV) with benzoporphyrin derivative (BPD).

**Methods:** One group was considered as control (n=6 eyes) then, corneal NV was induced in 30 New Zealand male rabbits (n=60 eyes) by placing 7.0 silk sutures at midstromal depth approximately 1mm from the limbus. Fifteen rabbits with corneal NV were left without any treatment, and 15 rabbits were subjected to photodynamic therapy (PDT) by intravenous injection with Verteporfin at a dose of 1.5 mg /Kg. Diode laser (660 nm) was applied after 15 minutes for 5 minutes with a power of 50 mW/cm<sup>2</sup>. All rabbits were successively followed up by slit lamp examination for periods of 1 day, 1, 2, 3 and 4 weeks. Three rabbits were selected and sacrificed weekly (n=6 eyes each) and the corneas were isolated for histopathological examination.

**Results:** The results of slit lamp examination indicated the gradual regression of the cornea neovascularization 4 weeks of PDT. Furthermore, regression of corneal neovascularization was documented clinically by decrease number and length of blood vessels and by histopathological examination.

**Conclusion:** PDT with Verteporfin can provide efficacious treatment of corneal neovascularization.

**Keywords:** corneal neovascularizations; photodynamic therapy; diode laser

Please cite this article as follows:

Hassan AA, Ghoneim DF, El-dib AA, Abdelkawi SA, Abdel- Salam AM. Photothrombosis of Corneal Neovascularization by Photodynamic Therapy Utilizing Verteporfin and Diode Laser: J Lasers Med Sci 2013; 4(3):131-9

\*Corresponding Author: Salwa Abdelkawi, Vision Sciences Department, Biophysics and Laser Science Unit, Research Institute of Ophthalmology, 2 El-ahram St. Giza, Egypt. Postal code: 12511, Fax: +202 35735688, Phone: +20100 1670590, E-mail: saelkawi@yahoo.com

## Introduction

The cornea is the transparent front part of the eye that covers the iris, pupil, and anterior chamber. Because transparency is of prime importance, the cornea does not have blood vessels; it receives nutrients via diffusion from the tear fluid, the aqueous humor. The cornea has no blood supply; it gets oxygen directly from the air through the tears<sup>1</sup>.

Corneal neovascularization (NV) is considered as

one of the most common cause of blindness worldwide<sup>2</sup>. It is caused by many factors such as, inflammation, degenerative disorder, infection, chemical burns, and long-term contact lens wear<sup>3</sup>. The lack of blood vessels in the cornea allows the passage of light and the absorption of oxygen from the air. Under certain conditions, such as injuries, infections and hypoxia, this privilege may be disrupted and hence, inflammation and/or neovascularization can occur. In corneal NV the body attempts to provide the eye with the necessary nutrients

and oxygen to the corneal tissue by increasing the activity of vascular endothelial growth factor (VEGF), inducing the formation of new vascular growth<sup>4</sup>. The primary treatments for these vessels are the topical corticosteroids and non-steroids anti-inflammatory drugs. However, if the vessels have been established for an extended period, these treatments are ineffective<sup>5</sup>. Although, argon laser treatment for corneal NV has been reported, but this method achieved an inadequate effect because of the high incidence of revascularization and thermal damage to the adjacent tissues<sup>6,7</sup>.

Recent advances in understanding the molecular mechanisms have facilitated the development of new therapies for neovascular ocular diseases<sup>8,9,10</sup>. Corneal NV is a challenging condition, and because corneal clarity and avascularity are critical for maintaining vision, developing treatments for corneal NV is crucial. In photodynamic therapy, systemically administered porphyrin derivatives accumulate in proliferating endothelial cells. Laser energy is used to activate the porphyrin derivatives liberating cytotoxic oxygen free radicals<sup>11,12</sup>. This reactive oxygen species (ROS) facilitate the damage to vascular endothelium by activating platelets, leading to the formation of thrombus that occludes the target vessels.

Verteporfin, (C<sub>41</sub>H<sub>42</sub>N<sub>4</sub>O<sub>8</sub>) otherwise known as benzoporphyrin derivative (trade name Visudyne<sup>®</sup>), is a medication used as antineoplastic agents, photosensitizing agents and anti neovascularisation agents. Verteporfin was used in conjunction with a laser to eliminate the abnormal blood vessels in the eye associated with conditions such as the wet form of macular degeneration (Corneal Neovascularization or CNV). Verteporfin accumulates in these abnormal blood vessels and, when stimulated by non-thermal red light laser in the presence of oxygen, produces highly reactive short-lived singlet oxygen and other reactive oxygen radicals, resulting in local damage to the vascular endothelium and blockage of the new formed vessels<sup>13,14</sup>. The aim of the present work was to evaluate the use of verteporfin as a type of photodynamic therapy (PDT) that has been introduced recently as a novel treatment for corneal neovascularization.

## Methods

### Animals

Thirty-three New Zealand male rabbits weighing

2-2.5 kg were selected from the animal house of Research Institute of Ophthalmology, Giza, Egypt. The animals were maintained in a standard 12- hr light- dark cycle with free access to water and balanced diet. All procedures were conducted according to the principles enunciated in the Guide for Care and Use of Laboratory Animals, National Institute of health or NIH publication No. 85-23. They were subjected to experimental protocols approved by the local experimental ethics committee of ophthalmic and vision research.

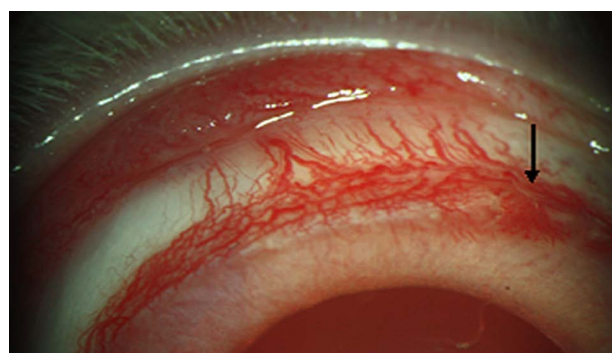### Clinical examination

All rabbits' eyes were examined by slit lamp biomicroscope before induction of corneal neovascularization. The results indicate no signs of edema, corneal neovascularization or intraocular inflammation in all eyes.

### Corneal neovascularization

Three rabbits were used as control, and 30 rabbits (n=60 eyes) were generally anesthetized using intramuscular Xylaject (0.2 ml/kg) and ketamine hydrochloride (0.6ml/ kg). Benoxinate eye drops (0.4%) was used for local anesthesia. Corneal neovascularization was induced by a three-interrupted 7.0 silk sutures at midstromal depth approximately 1 mm from the limbus<sup>15</sup>. Anti - inflammatory eye drops (Diclofenac) was used three times daily to treat pain and inflammation. After four days sutures were removed and slit lamp examinations were performed to determine the area of corneal neovascularization (Figure 1). After the demonstrated periods, animals were classified into three groups as follows:

**Group I:** Control group; consisted of three rabbits



**Figure 1.** Slit lamp photography immediately after removing sutures, showing the extent of neovascularization.

without any treatment.

**Group II:** Neovascularized group (n=15 rabbits) was divided to five subgroups (n=3 rabbits each). After 1 day, 1, 2, 3, 4 weeks, all rabbits were subjected to slit lamp photographs with a standard magnification ( $\times 25$ ).

**Group III:** Neovascularized group (n=15 rabbits) were generally anesthetized, and verteporfin (Visudyne®; Novartis AG, Basel, Switzerland) with a dose of 1.5 mg/Kg was administered by slow intravenous injection in the marginal ear vein. After 15 minutes, rabbit's eyes were exposed to diode laser (SIM-MED Gallium Midi, UK) at 1 cm distance from the cornea in a continuous mode at 660 nm for five minutes and a power of 50 mW/cm<sup>2</sup> (Ophthalmology Department, National Institute of Laser Enhanced Science, Cairo University, Egypt). After photodynamic therapy, rabbits were divided to five subgroups (n=3 rabbits each). For periods of 1 day, 1, 2, 3, 4 weeks, three rabbits were selected and subjected to slit lamp photographs with a standard magnification ( $\times 25$ ) and sacrificed for histological examination respectively.

### Histological examination of the cornea

The corneal specimens were immediately fixed in 2.5% phosphate buffered glutaraldehyde (pH 7.4) at 4 °C for 24 hours and post fixed in 1% osmium tetroxide for one hour, then dehydrated in an ascending grades of ethanol. After immersion in propylene oxide, the specimens were embedded in araldite 512 mixtures. Semithin sections (1 $\mu$ m) were cut, stained with toluidine blue and examined by light microscope.

### Amount of corneal neovascularization

The amount of corneal neovascularization was assessed by a scoring system modified from a semi quantitative method of the references number 5 for determination of numbers and lengths of visible corneal blood vessels<sup>16</sup>.

### Statistical Evaluation

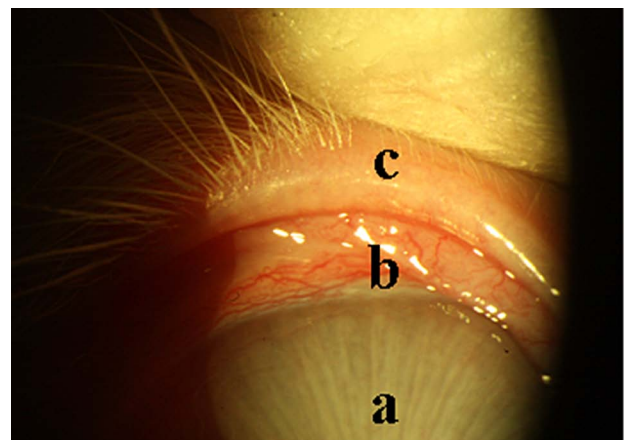
The results of corneal neovascularization were compared between neovascularized and PDT exposed eyes. The results were statistically evaluated according to the "Students" t- test<sup>17</sup>. Where "t" is the test of significance, differences were considered significant at P = 0.05.

## Results

### Slit lamp examination

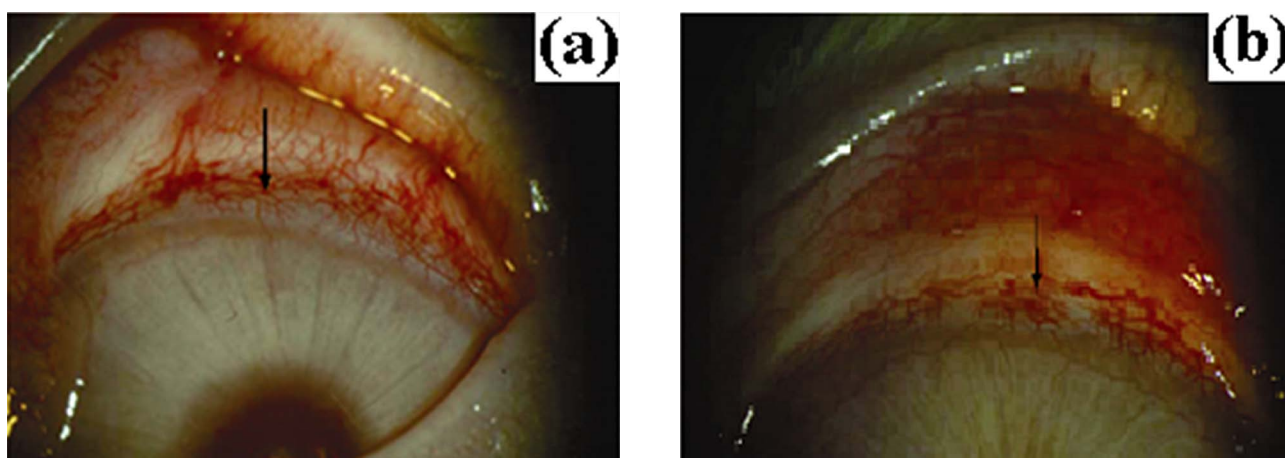
Slit lamp examination for normal rabbit was illustrated in Figure 2 with clear cornea without any vascularization. After one day of removing sutures (Figure 3a) the number of vessels was  $7.3 \pm 0.47$  decreased to  $6.7 \pm 0.42$  after PDT (Figure 3b) with a percentage change of -8.2% (P=0.05). The examination of rabbit's cornea after 1 week of neovascularization (Figure 4a) showed significant progression of Corneal NV and the number of vessels was  $8.7 \pm 0.45$  and significantly decrease to  $5.7 \pm 0.44$  after PDT (Figure 4b) with a percentage change of -34.5% (P=0.01). Two weeks after neovascularization (Figure 5a), the number of vessels varied from  $9.3 \pm 0.47$  to  $4.3 \pm 0.46$  after PDT (Figure 5b) with a percentage change of -53.8% (P=0.001). Furthermore, slit lamp photography three weeks after corneal neovascularization (Figure 6a) showed the increase in progression of number of vessels ( $10.0 \pm 0.81$ ). After PDT (Figure 6b), this progression, showing marked regression of the neovascularized portion of the cornea with a very high significant change in the number of vessels ( $1.7 \pm 0.48$ , -83% and P=0.001). In addition, there was a very high significant decrease in number of vessels of neovascularized cornea 4 weeks after removing sutures and exposed to PDT (Figures. 7a,7b). The results indicated approximately complete recovery with values of  $12.4 \pm 0.49$  and  $1.3 \pm 0.47$  respectively (-89.5%, P=0.001).

The assessment of lengths of visible corneal blood vessels 1 day, 1, 2, 3, and 4 weeks after neovascularization showed very high significant change with respect to the other groups exposed to PDT

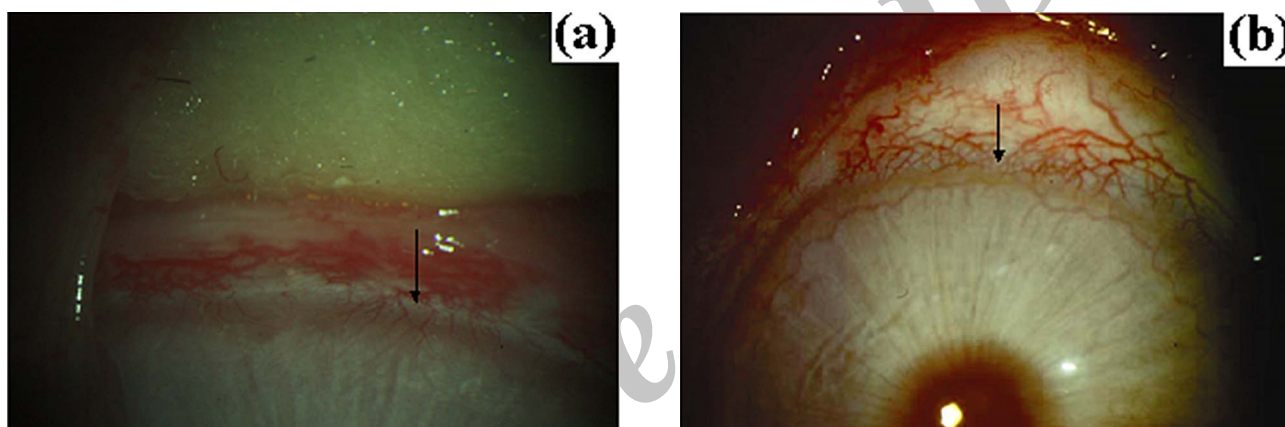


**Figure 2.** Normal rabbit's cornea, a: the cornea, b: Limbus, c: upper lid.

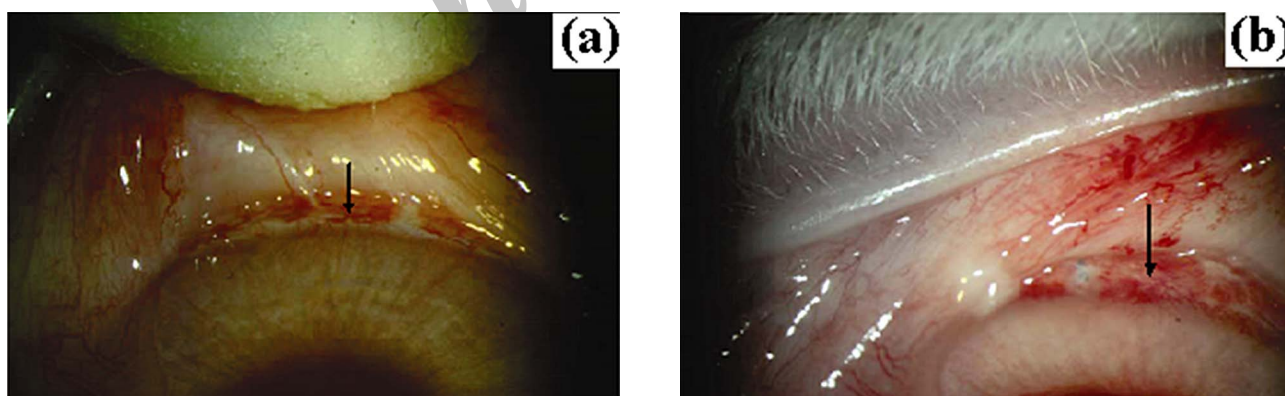




**Figure 3.** Slit lamp photography, (a): One day after removal of suture showing the extent of corneal neovascularization, (b): One day after PDT, showing mild change in the extent of corneal neovascularization.



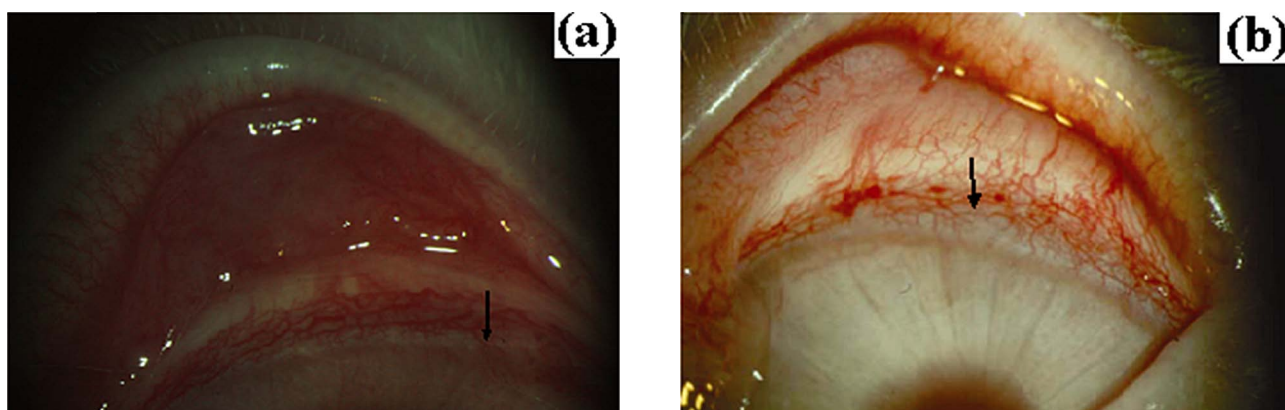
**Figure 4.** Slit lamp photography, (a): One week after removal of sutures, showing increase in the extent of corneal neovascularization, (b): One week after PDT, showing marked regression of the neovascularized portion of the cornea.



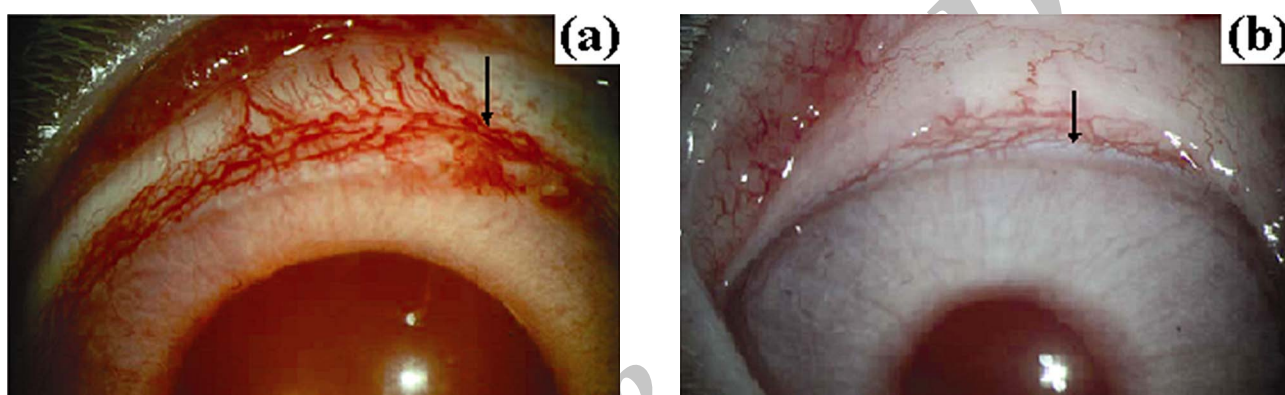
**Figure 5.** Slit lamp photography, (a): Two weeks after removal of sutures showing increase in the extent of the neovascularized portion of the cornea, (b): Two week after PDT, showing less marked regression of the neovascularized portion of the cornea.

( $P=0.001$ ). For the neovascularized corneas, the values were  $0.84\pm 0.03$  mm,  $0.92\pm 0.02$  mm,  $1.3\pm 0.04$  mm,  $1.6\pm 0.04$  and  $1.8\pm 0.13$  respectively. Moreover, after PDT there were remarkable reduction in the length of vessels with values of  $0.54\pm 0.03$  mm,  $0.40\pm 0.06$

mm,  $0.28\pm 0.01$ mm,  $0.25\pm 0.01$  mm and  $0.17\pm 0.05$  respectively. In addition, the percentage change in the lengths of corneal vessels showed dramatic alteration with values of -30 %, -56.5 %, -80.7%, -84.3% and -90.5% respectively. The assessment of the numbers



**Figure 6.** Slit lamp photography, (a): Three weeks after removal of sutures, showing increase in the extent of the neovascularized portion of the cornea, (b): Three weeks after PDT, showing marked regression of the neovascularized portion of the cornea.



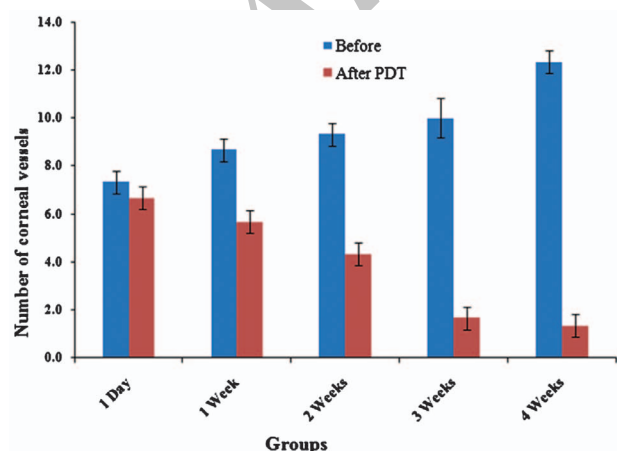
**Figure 7.** Slit lamp photography, (a): Four weeks after removal of sutures, showing marked increase in the extent of the neovascularized portion of the cornea, (b): Four weeks after PDT, showing absence of corneal neovascularization.

and lengths of corneal vessels before and after PDT were illustrated in Figures 8 and 9.

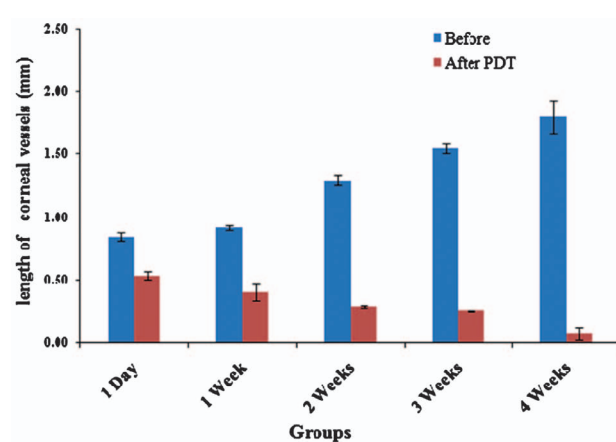
### Histological examination

Light microscopic examination of control rabbit's

cornea showed no microscopic alteration with normal arrangement of epithelial cells, regular Bowman's membrane and normal stromal collagen (Figure 10). Light microscopic examination of neovascularized cornea (Figure 11) showed irregularity in the stromal lamellae with appearance of thickened wall blood

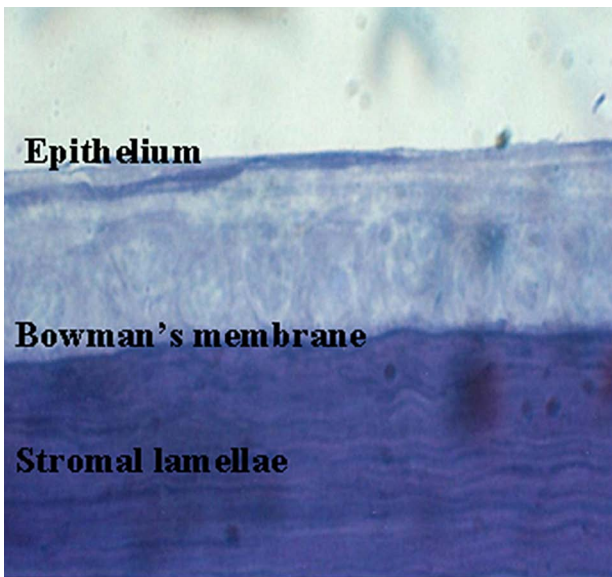


**Figure 8.** Number of corneal vessels between limbus and corneal center before and after different periods of PDT.

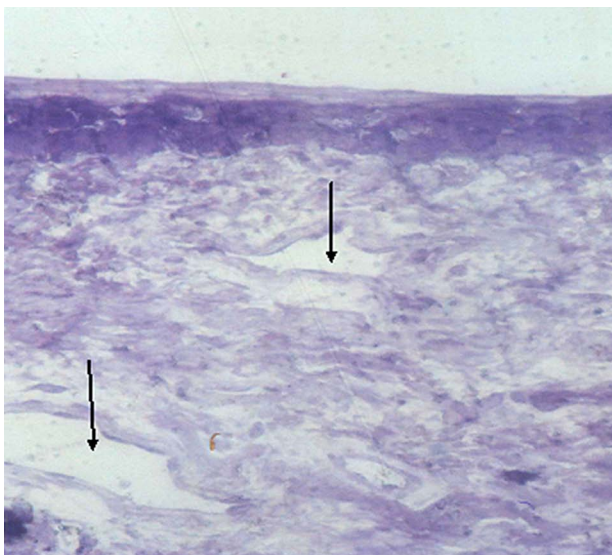


**Figure 9.** Proportionate length of longest corneal vessels between limbus and corneal center, before and after different periods of PDT.



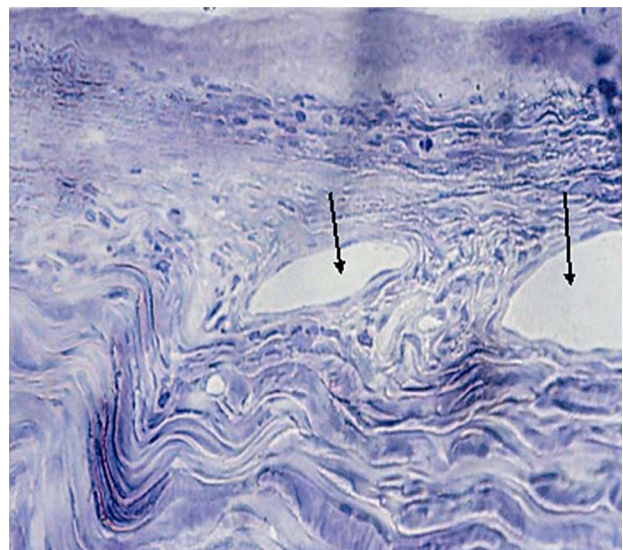


**Figure 10.** Light micrograph of control rabbit cornea. Shows its normal layers stratified epithelial thickness with regular Bowman's membrane and stromal lamellae. (Toluidine blue  $\times 500$ ).

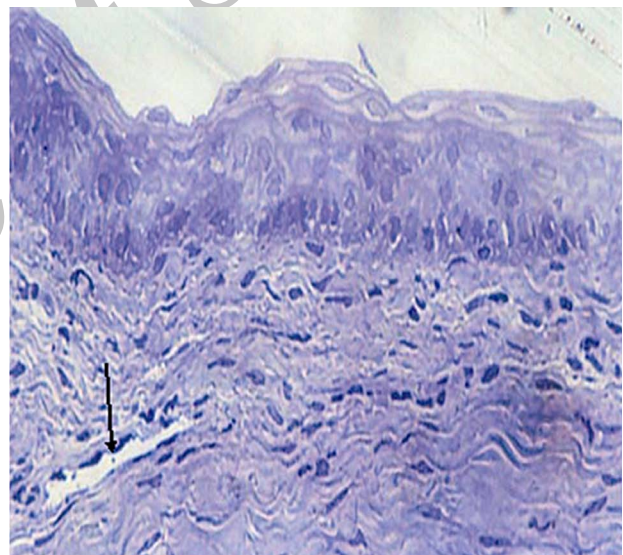


**Figure 11.** Light micrograph of neovascularized rabbit's cornea, showing multiple neovascularized superficial stroma with thickened wall of the capillaries. (Toluidine blue  $\times 500$ ).

vessels. One day after photodynamic therapy the examination showed slight regression in the extent of blood vessels (Figure 12). The extent of corneal neovascularization showed moderate regression with irregularity in stromal lamellae and reduction in the thickness of blood capillaries after one week of photodynamic therapy (Figure 13). Moreover, histological study of the cornea after two and three weeks (Figures 14,15) of photodynamic therapy showed disappearance of blood capillaries with



**Figure 12.** Light micrograph of rabbit's cornea, one day after photodynamic therapy showing slight regression of the neovascularized stroma with slightly thickened wall of blood capillaries. (Toluidine blue  $\times 500$ ).



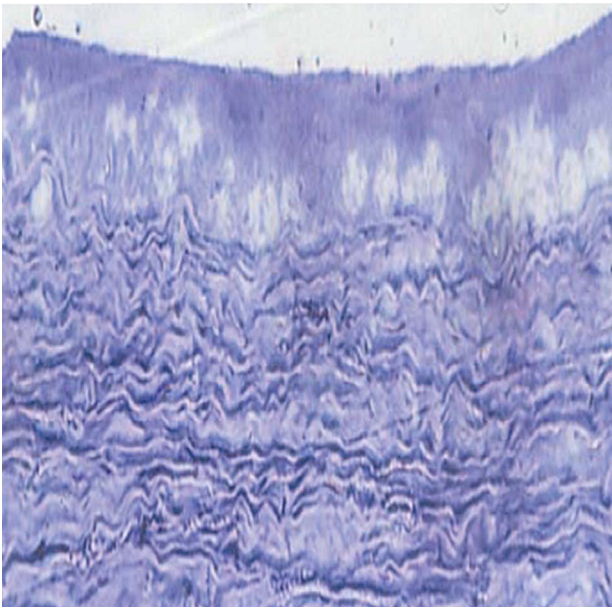
**Figure 13.** Light micrograph of rabbit's cornea, one week after photodynamic therapy showing moderate regression of the neovascularized stroma with slightly thickened wall of blood capillaries. (Toluidine blue  $\times 500$ ).

some irregularities in stromal lamellae. Furthermore, the histological examination of the corneas after 4 weeks of photodynamic therapy indicated complete recovery which approximately matched the control one (Figure 16).

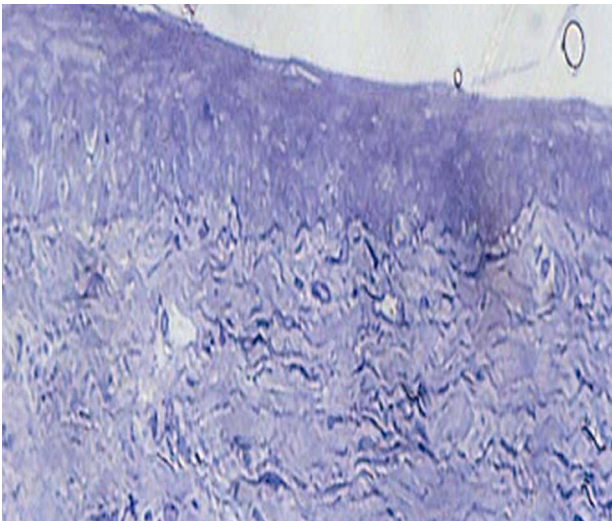
## Discussion

Verteporfin, a liposomal formulation of benzoporphyrin derivative monoacid ring A (BPD-





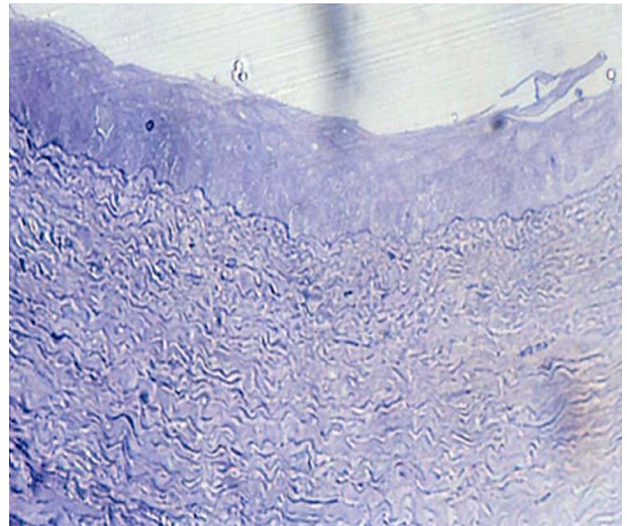
**Figure 14.** Light micrograph of rabbit's cornea two weeks after photodynamic therapy, showing swelling of the basal cells of the capillaries. (Toluidine blue  $\times 500$ )



**Figure 15.** Light micrograph of rabbit's cornea three weeks after photodynamic therapy showing slight irregularities in corneal stroma. (Toluidine blue  $\times 500$ ).

MA), is being used clinically in photodynamic therapy for age-related macular degeneration<sup>18</sup>. Verteporfin is transported in the plasma primarily by lipoproteins (especially low-density lipoproteins), are known to deliver hydrophobic materials to tumor cells<sup>19,20,21</sup>.

Photodynamic therapy has gained increasing interest in ophthalmology, representing an experimental tool for the diagnosis and treatment of tumors located in the eye. PDT is a treatment modality involving the administration of photosensitizing compound, which



**Figure 16.** Light micrograph of a rabbit's cornea four weeks after photodynamic therapy showing unchanged cornea. (Toluidine blue  $\times 500$ )

selectively accumulates in the hyper proliferative target cells followed by local irradiation of lesion with visible light. The combination of two nontoxic elements, i. e. drug, and light, in the presence of oxygen results in the selective destruction of the target tissue by necrosis and apoptosis<sup>22</sup>.

Numerous investigations supported the idea that the efficacy of PDT was directly related to the yield of  $O_2$  in the tumor environment and the yield of  $O_2$  depends on the concentration of oxygen in the tissue. Hypoxic cells are very resistant to photosensitization and the photodynamic reaction mechanism itself may consume oxygen at a rate sufficient to inhibit further photosensitization effects. It has been suggested, that hyperbaric oxygen might enhance the photosensitization effect<sup>23</sup>.

In the present study, the amount of corneal regression of NV was evaluated, after exposure to PDT. The change in cornea structure after induction of NV was evaluated. The results of slit lamp examination indicated increase in numbers of blood capillaries ranged from  $7.3 \pm 0.47$  after one day of NV to  $1.3 \pm 0.47$  after 4 weeks of exposure to PDT (with percentage change of  $-89.5\%$  ( $P=0.001$ )). Furthermore, decreasing of lengths of corneal vessels was observed during the next four weeks after exposure to PDT due to regression of corneal NV. The percentage reduction in lengths ranged from  $-30\%$  after one day to  $-90.5\%$  after 4 weeks. These results suggested that, the induction of corneal NV caused corneal hypoxia, inducing the formation of new vascular growth by increasing the

activity of vascular endothelial growth factor (VEGF)<sup>4</sup>. This process was associated with an enhanced formation of blood vessels. Furthermore, once Verteporfin was activated by light in the presence of oxygen, highly reactive, short-lived singlet oxygen and reactive oxygen radicals are generated. Light activation of Verteporfin resulted in local damage to neovascular endothelium, vessel occlusion, leading to gradual improvement in corneal structure. The improvements of corneas were documented by histological examination during the next four weeks after PDT indicating the suppression of vessels growth and the survival of corneal tissue.

These data indicated that PDT using liposomal Verteporfin, showed a stronger cytotoxicity to neovascular endothelium that observed after laser treatment. Furthermore, since this toxic effect of PDT appeared time dependently, the results indicated gradual improvement of the cornea after the 3<sup>rd</sup> and 4<sup>th</sup> week of PDT.

Reactive oxygen species (ROS) are produced in metabolic and physiological processes, and harmful oxidative reactions may occur in organisms that remove them via enzymatic and non-enzymatic antioxidative mechanisms. Unstable free radical species attack cellular components causing damage to lipids, proteins, and DNA, which can initiate a chain of events resulting in the onset of a variety of diseases. Living organisms have developed complex antioxidant systems to counteract ROS and to reduce their damage<sup>24,25,26</sup>.

These antioxidant systems include enzymes such as superoxide dismutase, catalase, and glutathione peroxidase; macromolecules such as albumin, ceruloplasmin, and ferritin; and an array of small molecules, including ascorbic acid,  $\alpha$ -tocopherol,  $\beta$ -carotene, reduced glutathione, uric acid, and bilirubin<sup>27</sup>.

Oxidative stress resulted from increased number of lipid and protein oxidation products and decreased number of antioxidant enzymes and vitamins<sup>28</sup>. In addition, reflecting the redox balance between oxidation and antioxidation<sup>29,30,31</sup>.

Interestingly, these results suggested that the oxidative/antioxidative balance shifts towards the antioxidative status and PDT with Verteporfin caused growth cycle arrest that helps to prevent further damage and give the cell time to repair the defect (Figures 8,9). These results agree with previous reports of reference number 13 and 14. They concluded that, damaged endothelium is known to

release procoagulant and vasoactive factors through the lipo-oxygenase (leukotriene) and cyclo-oxygenase (eicosanoids such as thromboxane) pathways, resulting in platelet aggregation, fibrin clot formation, and vasoconstriction. In addition, the antiproliferative activities would be not due to direct toxicity against neovascularized cells but due to blocking of some proliferative steps<sup>32</sup>.

In summary, this paper concluded that PDT with Verteporfin for treatment of corneal neovascularization is a safe and efficacious procedure that leads to improvement in the corneal tissues. Further experimental and clinical studies are obviously needed for longer follow up periods and to identify the parameters associated with the most effective procedures with the least adverse effect.

## References

1. Cassin B, Solomon S. Dictionary of Eye Terminology. Triad Publishing Company, Gainesville, Florida.1990.
2. Faraj LA, Said DG, Dua HS. Evaluation of corneal neovascularization. Br J Ophthalmol 2011; 95:1343-4.
3. Lee P, Wang CC, Adamis AP. Ocular neovascularization an epidemiologic review. Surv Ophthalmol 1998; 43: 245-69.
4. ARVO. The Association for Research in Vision and Ophthalmology Inc. Invest Ophthalmol Vis Sci 2008; 49: 894-9.
5. Epstein RJ, Stulting RD, Hendricks RL, Harris DM. Corneal neovascularization: Pathogenesis and inhibition. Cornea 1987; 6: 250-7.
6. Nirankari VS, Bear JC. Corneal argon laser photocoagulation for neovascularization in penetrating keratoplasty. Ophthalmology 1986; 93: 1304-9.
7. Marsh R J. Argon laser treatment of lipid keratopathy. Br J Ophthalmol 1988; 72: 900-904.
8. Lynch SS, Cheng CM. Bevacizumab for neovascular ocular diseases. Ann Pharmacol Ther 2007; 41: 614-25.
9. Hosseini H, Nejabat M. A potential therapeutic strategy for inhibition of corneal neovascularization with new anti-VEGF agents. Med Hypotheses 2007; 68:799-801.
10. Kim SW, Ha BJ, Kim EK, Tchah H, Kim TI. The effect of topical Bevacizumab on corneal neovascularization. Ophthalmology 2008; 115: 33-8.
11. Gohto Y, Obana A, Kaneda K, Nakajima S, Takemura T, Miki T. Accumulation of photosensitizer ATX- S10 (Na) in experimental corneal neovascularization. Jpn J ophthalmol 2000; 44: 348-53.
12. Gohto Y, Obana A, Kanai M, Nagata S, Miki T, Nakajima S. Photodynamic therapy for corneal neovascularization using topically administered ATX- S10 (Na). Ophthalmic Sur Lasers 2000; 31: 55- 60.



13. Nowak-Sliwinska P, Karocki A, Elas M, Pawlak A, Stochel G, Urbanska K. Verteporfin, photofrin II, and merocyanine 540 as PDT photosensitizers against melanoma cells. *Biochem Biophys Res Commun* 2006; 349: 549-55.
14. Chan WM, Lim TH, Pece A, Silva R, Yoshimura N. Verteporfin PDT for non-standard indications- a review of current literature. *Graefes Arch Clin Exp Ophthalmol* 2010; 248: 613-26.
15. Schmidt - Erfurth U, Hasan T, Schomacker k, Flotte T, Birngruber R. In vivo uptake of liposomal benzoporphyrin derivative and photothrombosis in experimental corneal neovascularization. *Laser Surg Med* 1995; 17, 178-189.
16. Cursiefen C, Wenkel H, Martus P, Langenbucher A, Nguyen NX, Seitz B, et al. Impact of short-term versus long- term topical steroids on corneal neovascularization after non-high-risk keratoplasty. *Graefes Arch Clin Exp Ophthalmol* 2001; 239: 514-21.
17. Snedecore GW, Cochran WG. *Statistical Methods*, 6<sup>th</sup> ed., Ames., Iowa, USA. 1976.
18. Ichikawa K, Takeuchi Y, Yonezawa S, Hikita T, Kurohane K, Namba Y, et al. Antiangiogenic photodynamic therapy (PDT) using Visudyne causes effective suppression of tumor growth. *Cancer Lett* 2004; 205: 39-48.
19. De Smidt PC, Verslus AJ, van Berkel TJ. Properties of incorporation, redistribution, and integrity of porphyrin-low-density lipoprotein complexes. *Biochemistry* 1993; 32: 2916-22.
20. Koller-Lucaie SK, Schott H, Schwendener RA. Low-density lipoprotein and liposome mediated uptake and cytotoxic effect of N<sup>4</sup>-octadecyl-1-β-D-arabinofuranosylcytosine in Daudi lymphoma cells. *Br J Cancer* 1999; 80:1542-9.
21. Pan G, Oie S, Lu DR. Uptake of the carborane derivative of cholesteryl ester by glioma cancer cells is mediated through LDL receptors. *Pharm Res* 2004; 21: 1257-62.
22. Lukšienė Ž. Photodynamic therapy: mechanism of action and ways to improve the efficiency of treatment. *Medicina* 2003; 39: 1137-50.
23. Henderson BW, Dougherty TJ. How does photodynamic therapy work? *Photochem Photobiol* 1992; 55:145-57.
24. Yanik M, Erel O, Kati M. The relationship between potency of oxidative stress and severity of depression. *Acta Neuropsychiatr* 2004; 16: 200-3.
25. Harma M, Harma M, Erel O. Oxidative stress in women with preeclampsia. *Am J Obstet Gynecol* 2005; 192: 656-7.
26. Yeni E, Gulum M, Selek S, Erel O, Unal D, Verit A, et al. Comparison of oxidative/antioxidative status of penile corpus cavernosum blood and peripheral venous blood. *Int J Impot Res* 2005; 17:19-22.
27. Koracevic D, Koracevic G, Djordjevic V, Andrejevic S, Cosic V. Method for the measurement of antioxidant activity in human fluids. *J Clin Pathol* 2001; 54:356-61.
28. Koksai H, Kurban S. Total oxidant status, total antioxidant status, and paraoxonase and arylesterase activities during laparoscopic cholecystectomy. *Clinics* 2010; 65:285-90.
29. Erel O. A new automated colorimetric method for measuring total oxidant status. *Clin Biochem* 2005; 38: 1103-11.
30. Demirbag R, Gur M, Yilmaz R, Kunt AS, Erel O, Andac MH. Influence of oxidative stress on the development of collateral circulation in total coronary occlusions. *Int J Cardiol* 2007;116: 14-9.
31. Rabus M, Demirbağ R, Sezen Y, Konukoğlu O, Yıldız A, Erel Ö, et al. Plasma and tissue oxidative stress index in patients with rheumatic and degenerative heart valve disease. *Arch Turk Soc Cardiol* 2008; 36: 536-540.
32. Bortner CD, Cidlowski JA. Cellular mechanisms for the repression of apoptosis. *Ann Rev Pharmacol Toxicol* 2002; 42:259-81.