



# The Combined Effects of Levothyroxine and Low Level Laser Therapy on Wound Healing in Hypothyroidism Male Rat Model

Amin Firouzi<sup>1</sup>, Fatemeh Fadaei Fathabadi<sup>2\*</sup>, Mohsen Norozian<sup>2</sup>, Abdollah Amini<sup>2</sup>, Mohammad-Amin Abdollahifar<sup>2</sup>, Mohammad Noruzian<sup>3</sup>

<sup>1</sup>Medical School, Shahid Beheshti University of Medical Sciences, Tehran, Iran

<sup>2</sup>Department of Anatomical Sciences and Biology, Medical School, Shahid Beheshti University of Medical Sciences, Tehran, Iran

<sup>3</sup>School of Dentistry, Shahid Beheshti University of Medical Sciences, Tehran, Iran

## \*Correspondence to

Fatemeh Fadaei Fathabadi, PhD,  
Associate professor, Department  
of Anatomical Sciences and  
Biology, Medical School, Shahid  
Beheshti University of Medical  
Sciences, Tehran, Iran.  
Tel: +98 9120067541;  
Fax: +87 2122439976;  
Email:  
Fatemehfadaeifathabadi@gmail.  
com

Published online 26 December  
2017



## Abstract

**Introduction:** Hypothyroidism is caused by inadequate production and storage of thyroid hormones. Hypothyroidism is associated with delayed wound healing. Laser therapy may stimulate wound regeneration. The aim of this study was to determine the combined effects of levothyroxine and low level laser therapy during the wound healing process on skin of hypothyroidism male rat model.

**Methods:** Thirty male Wistar rats were randomly divided into 5 groups: control group, hypothyroidism group, hypothyroidism group treated by laser, hypothyroidism group treated by levothyroxine, and hypothyroidism group treated by laser and levothyroxine. To induce hypothyroidism, methimazole was given at a dose of 4 mg/100 mL in their drinking water. After hypothyroidism was proven through immunoassay commercial kit, rats were generally anesthetized with ketamine and xylazine, then, an incisional skin wound was created in a length of 1.2 cm on the back of the ribcage. The surgical day is considered as the zero day. The third and fifth groups were treated with a pulse laser, 810 nm wavelength 80 Hz frequency and 0.2 J/cm<sup>2</sup> energy densities for 200 seconds. Levothyroxine was injected to the fourth and fifth groups intraperitoneally. On the 14th day, a normal sample of each healing skin wound was harvested for biomechanical examination. The obtained data were analyzed by the SPSS software 21 and reported as a mean ± standard error of mean (SEM).  $P < 0.05$  was considered statistically significant.

**Results:** The results showed that the mean maximum force and the accomplished work (energy) made a significant difference in the group receiving both laser and levothyroxine synchronously rather than the other groups ( $P \leq 0.05$ ). The elasticity of the wound healing in the groups that received laser and levothyroxine synchronously was significantly higher in comparison with the control and hypothyroidism groups but the difference was not significant in comparison with the laser or levothyroxine groups.

**Conclusion:** The results of our study showed that the application of laser and levothyroxine synchronously improves the biomechanical parameters of wound during healing in comparison to the use of laser and levothyroxine solely

**Keywords:** Hypothyroidism; Wound healing; Laser; Levothyroxine.

## Introduction

Hypothyroidism is one of the most prevalent exocrine gland disorders. It occurs in females 8-10 times more than males.<sup>1,2</sup> Its prevalence depends directly on age. Hypothyroidism is caused by inadequate production and storage of thyroid hormones.<sup>3</sup> Thyroid hormone is essential for the normal functioning of some tissues in the body.<sup>4</sup> Patients with hypothyroidism usually complain a lot about delay in the wound healing, dermatophytosis and post-surgical pains. In the past decades, different methods have been proposed to accelerate wound healing and decrease the side effects of healing. Modalities such

as laser have been proposed alongside pharmacotherapy.<sup>5</sup> Mester et al discovered the advantages of laser to wound healing.<sup>6</sup> All studies on lab animals emphasize that low-level laser accelerates wound healing through increased proliferation of fibroblasts and formation of fibrous granulation, increased collagen synthesis and ATP production, lymphocytes activation as well as increased ability to attach to pathogens.<sup>7</sup> In laser therapy, various parameters are important including wavelength, frequency, and duration of the radiation.<sup>8</sup> Numerous lasers are being used to heal wounds, including the gallium- aluminum arsenide laser.<sup>9</sup>

**Please cite this article as follows:** Firouzi A, Fadaei Fathabadi F, Norozian M, Amini A, Abdollahifar MA, Noruzian M. The combined effects of levothyroxine and low level laser therapy on wound healing in hypothyroidism male rat model. *J Lasers Med Sci*. 2018;9(1):7-10. doi:10.15171/jlms.2018.02.

The other method to heal the wound is the use of pomades made from the compounds of thyroid hormones topically. Studies show that one of the target organs for thyroid hormones is the skin and the decrease of the hormones causes delay in wound healing, so the alternative hormone therapy has an effect on accelerating wound healing. A lot of studies present that pomades made from thyroid hormone hasten wound healing.<sup>10-12</sup> Levothyroxine is used to treat hypothyroidism. Because all methods used alone are not enough yet, the study investigates the combined effect of levothyroxine with laser on hypothyroidism rats' wounds healing.

## Methods

### Animals

Thirty male Wistar rats were provided from Iran Pasteur Institute. They were kept in the animal lab for about 2 weeks to acclimatize to the condition of the animal lab and obtain 200-220 g in weight. The rats were kept in clean single cages with free access to water and food. The temperature of the animal lab was about 22°C, and the light was on for 12 hours and off for 12 hours. After acclimation to lab terms, rats were divided into control group, hypothyroidism group, hypothyroidism group treated by the laser, hypothyroidism group treated by levothyroxine, and hypothyroidism group treated by the laser and levothyroxine.

### Induced Hypothyroidism

Methimazole powder at 4 mg dose dissolved in 100 mL distilled water was daily given orally to all groups for 1 month, with exception of the control group. To prove hypothyroidism, rat's the eye corner was exsanguinated for 2 mL and the level of thyroid hormones (T3 and T4) was examined through the radioimmunoassay commercial ELISA kit (Dia Plus, USA).

### Surgery

After hypothyroidism induction, all rats were anesthetized with the injection of ketamine hydrochloride (50 mg/kg) and xylazine (20 mg/kg) intramuscularly. Their back hairs were shaved and disinfected with betadine 10% (Tolid Daru Co., Iran) and alcohol. Then, a wound was linearly created in a length of 12 mm by means of a No. 24 scalpel, the depth of incision encompassed both dermis and hypodermis, i.e., the thickness was full.<sup>13</sup>

### Treatment With Low Level Laser

An 810 nm laser (80 Hz at 0.2 J /cm<sup>2</sup>) was used. The treatment with the laser began 24 hours post-surgery. The wound was classified into 12 points (4 rows, 3 columns) including the healthy skins around the wound and the injured part. Each point was radiated by the laser for 200 seconds. And the laser probe touched the wound directly. The wound was radiated through the laser for 6 days a week and continued for 14 days.

### Treatment With Levothyroxine

Levothyroxine (20 ug/kg, Sigma St. Louis, MO) was injected daily to the levothyroxine - treated groups intraperitoneally.<sup>14</sup>

### Biomechanical Examination

At the end of treatment (On the 14th day after surgery), the length of wound was measured, then the rats were deeply anesthetized and sacrificed. For the evaluation of the biomechanical parameters, after careful dissection of skin from underlying deep fascia, standardized rectangular skin specimens (5 × 50 mm strips) were harvested across the wound using a double-blade cutting instrument. The sample thickness was measured by a digital caliper. The samples were saturated with normal saline (9%) during the process. Both sides of the sample were placed into clamps (Eng. Design Co, Ltd., Tehran, Iran), the distance of the 2 clamps was about 30 mm. Both speeded up 10 mm/min. Finally, the maximal used power, tissue tension, and accomplished work were measured through tensiometry set.

### Statistical Analysis

The quantitative data were analyzed through SPSS21 and one-way analysis of variance (ANOVA) method. Normal distribution of data was analyzed using the Shapiro test. The data were expressed in the form of mean ± standard error of mean (SEM) and the significant level was considered  $P < 0.05$ .

## Results

### The Analysis of the Biomechanical Parameters

As Figure 1 presents, the maximum extension of the laser-levothyroxine group was significantly higher in comparison with the hypothyroidism and normal control groups ( $P \leq 0.05$ ) but the amount of the tension did not show a significant increase in comparison with the other groups (the laser group,  $P \geq 0.11$ ; levothyroxine group,  $P \geq 0.76$ ).

Also, the study indicated that for the laser-levothyroxine group, the accomplished work was significantly higher in comparison with the other groups ( $P \leq 0.05$ ), but the laser group ( $P \geq 0.367$ ) or levothyroxine group ( $P \geq 0.080$ )

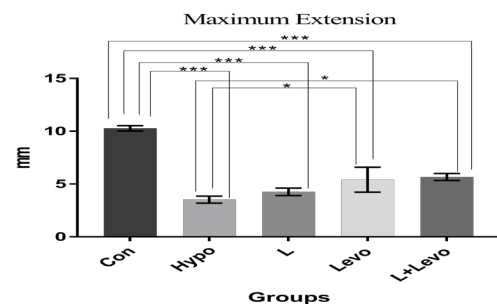


Figure 1. Mean ± SEM of Maximum Extension in the Study Groups Compared Using One Way ANOVA. \* $P < 0.05$ , \*\*\* $P < 0.001$ .

did not have a significant difference in comparison with the hypothyroidism group. Also, there was no significant difference between the laser-receiving and the levothyroxine groups ( $P \geq 0.359$ ) (Figure 2).

The maximal power mean of the laser-levothyroxine group showed a significant difference in comparison with the other groups, but there was no significant difference between the laser and hypothyroidism groups ( $P \geq 0.456$ ). The maximal power mean was significant between the laser group and levothyroxine group ( $P \leq 0.05$ ) (Figure 3).

## Discussion

This study has shown that the combined effect of laser and levothyroxine on the experimental hypothyroidism group accelerates wound healing. Hypothyroidism is known as one of the most prevalent disorders of the endocrine system affecting different systems and metabolisms the body. One of the consequences of thyroid insufficiency is a delay in wound healing. Numerous studies have investigated wound healing and the problems related to its delay, in hope to solve them. Some researchers have discovered the positive effect of laser in improving wounds, but some others have disagreed with the effect, which are in agreement with our results as our study showed the ineffectiveness of low-level laser on healing the hypothyroidism rat's wound. There was no significant difference between the laser-receiving group and the laser-excluding group. Viegas et al observed that laser does not effect on accelerating wound healing,<sup>15</sup> but others believe in the positive effect.<sup>16-18</sup> Lacjakova et al reported that laser at different doses decreases the inflammatory phases and accelerates wound healing.<sup>19</sup>

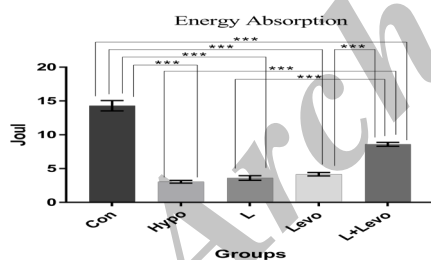


Figure 2. Mean  $\pm$  SEM of Energy Absorption in the Study Groups Compared Using One Way ANOVA. \*\*\* $P < 0.001$

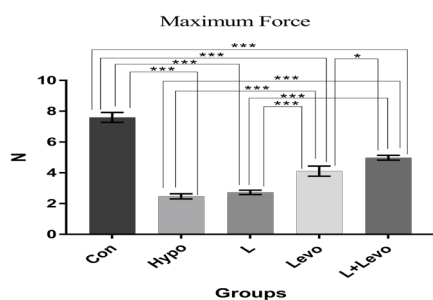


Figure 3. Mean  $\pm$  SEM of Maximum Force in the Study Groups Compared Using One Way ANOVA. \* $P < 0.05$ , \*\*\* $P < 0.001$ .

Dawood and Salman showed that laser accelerates wound healing through increased collagen synthesis.<sup>20</sup> Studies show that different parameters are considered to heal the wounds through laser, for example: wavelength, the duration of the radiation, and the power density. Because, there are many different protocols in related to radiation, and wavelength interrupts the use of the laser, causing the different consequences.

Levothyroxine is one of the treatments for hypothyroidism which replaces thyroid insufficiency and has a positive effect on the metabolism as well as on the tissues that are highly proliferated as the skin. In most studies, the pomades that are made from compounds of thyroid hormones have been used. Kassem et al indicated the positive effect of T3 pomades on wounds.<sup>10</sup> The positive effect of the pomades has been demonstrated by other researchers. Safer et al also indicated that this pomade accelerates wound healing.<sup>11</sup> Because studies on tissues have proved the effect of the pomades made from the compounds of the thyroid hormones on healing wounds, we used the medicine prescribed to treat hypothyroid namely levothyroxine. Although our experiments assessed biomechanical parameters, the results of these studies are in accordance with the results of our research.

## Conclusion

To conclude, LLLT with 810 nm wavelength, 80 Hz frequency, and 0.2 J/cm<sup>2</sup> energy density in combination with levothyroxine significantly improves the biomechanical properties of wound in the hypothyroidism model rat.

## Conflict of Interests

The authors declare no conflict of interest.

## Ethical Considerations

Not applicable.

## Acknowledgments

We would like to thank Laser Application in Medical Sciences Research Center of Shahid Beheshti University of Medical Sciences for their support.

## References

1. Canaris GJ, Manowitz NR, Mayor G, Ridgway EC. The Colorado thyroid disease prevalence study. *Arch Intern Med.* 2000;160(4):526-534.
2. Biondi B, Wartofsky L. Treatment with thyroid hormone. *Endocr Rev.* 2014;35(3):433-512. doi:10.1210/er.2013-1083
3. Persani L. Clinical review: Central hypothyroidism: pathogenic, diagnostic, and therapeutic challenges. *J Clin Endocrinol Metab.* 2012;97(9):3068-3078. doi:10.1210/jc.2012-1616
4. Maia AL, Goemann IM, Meyer EL, Wajner SM. Deiodinases: the balance of thyroid hormone: type 1 iodothyronine deiodinase in human physiology and disease. *J Endocrinol.* 2011;209(3):283-297. doi:10.1530/joe-10-0481

5. Hodjati H, Rakei S, Johari HG, Geramizedeh B, Sabet B, Zeraatian S. Low-level laser therapy: an experimental design for wound management: a case-controlled study in rabbit model. *J Cutan Aesthet Surg*. 2014;7(1):14-17. doi:10.4103/0974-2077.129962
6. Mester E, Ludany G, Selyei M, Szende B, Total GJ. The stimulating effect of low-power laser rays on biological systems. *Laser Rev*. 1968;1:3.
7. Woodruff LD, Bounkeo JM, Brannon WM, et al. The efficacy of laser therapy in wound repair: a meta-analysis of the literature. *Photomed Laser Surg*. 2004;22(3):241-247. doi:10.1089/1549541041438623
8. Lucas C, Stanborough RW, Freeman CL, De Haan RJ. Efficacy of Low-Level Laser Therapy on Wound Healing in Human Subjects: A Systematic Review. *Lasers Med Sci*. 2000;15(2):84-93. doi:10.1007/s101030050053
9. Beigom Taheri J, Bagheri F, Mojahedi M, et al. Comparison of the Effect of Low-Level Laser and Phenytoin Therapy on Skin Wound Healing in Rats. *J Lasers Med Sci*. 2015;6(3):124-128. doi:10.15171/jlms.2015.06
10. Kassem R, Liberty Z, Babaev M, Trau H, Cohen O. Harnessing the skin-thyroid connection for wound healing: a prospective controlled trial in guinea pigs. *Clin Exp Dermatol*. 2012;37(8):850-856. doi:10.1111/j.1365-2230.2012.04456.x
11. Safer JD, Crawford TM, Holick MF. Topical thyroid hormone accelerates wound healing in mice. *Endocrinology*. 2005;146(10):4425-4430. doi:10.1210/en.2005-0192
12. Tarameshloo M, Norouzian M, Zarein-Dolab S, Dadpay M, Gazor R. A comparative study of the effects of topical application of Aloe vera, thyroid hormone and silver sulfadiazine on skin wounds in Wistar rats. *Lab Anim Res*. 2012;28(1):17-21. doi:10.5625/lar.2012.28.1.17
13. Pouriran R, Piryaei A, Mostafavinia A, et al. The effect of combined pulsed wave low-level laser therapy and human bone marrow mesenchymal stem cell-conditioned medium on open skin wound healing in diabetic rats. *Photomed Laser Surg*. 2016;34(8):345-354. doi:10.1089/pho.2015.4020
14. Alzoubi KH, Alkadhi KA. Levothyroxin replacement therapy restores hypothyroidism induced impairment of L-LTP induction: critical role of CREB. *Brain Res Bull*. 2014;100:29-37. doi:10.1016/j.brainresbull.2013.10.011
15. Viegas VN, Abreu ME, Viezzer C, et al. Effect of low-level laser therapy on inflammatory reactions during wound healing: comparison with meloxicam. *Photomed Laser Surg*. 2007;25(6):467-473. doi:10.1089/pho.2007.1098
16. Allendorf JD, Bessler M, Huang J, et al. Helium-neon laser irradiation at fluences of 1, 2, and 4 J/cm<sup>2</sup> failed to accelerate wound healing as assessed by both wound contracture rate and tensile strength. *Lasers Surg Med*. 1997;20(3):340-345.
17. Colver GB, Priestley GC. Failure of a helium-neon laser to affect components of wound healing in vitro. *Br J Dermatol*. 1989;121(2):179-186.
18. Anneroth G, Hall G, Ryden H, Zetterqvist L. The effect of low-energy infra-red laser radiation on wound healing in rats. *Br J Oral Maxillofac Surg*. 1988;26(1):12-17.
19. Lacjakova K, Bobrov N, Polakova M, et al. Effects of equal daily doses delivered by different power densities of low-level laser therapy at 670 nm on open skin wound healing in normal and corticosteroid-treated rats: a brief report. *Lasers Med Sci*. 2010;25(5):761-766. doi:10.1007/s10103-010-0791-z
20. Dawood MS, Salman SD. Low level diode laser accelerates wound healing. *Lasers Med Sci*. 2013;28(3):941-945. doi:10.1007/s10103-012-1182-4