

Rhinophyma Treatment by Copper Vapor Laser With the Computerized Scanner



Igor V. Ponomarev^{1*}, Sergey B. Topchiy¹, Svetlana V. Klyuchareva², Alexandra E. Pushkareva³

¹P.N. Lebedev Physics Institute, RAS, 53, Leninsky Prospect, Moscow, 119991, Russian Federation

²I.I. Mechnikov North-West State Medical University, 47, Piskarevkiy Prospect, Saint-Petersburg, 195067, Russian Federation

³Saint Petersburg National Research University of Information Technologies, Mechanics and Optics; 49, Kronverkskiy Prospect, Saint Petersburg, 197101, Russian Federation

*Correspondence to

Igor V. Ponomarev, Head of Laser Project, Department of Quantum Radiophysics.
Tel: +74958510609;
Fax: +74958510452;
Email: luklalukla@ya.ru

Published online February 25, 2019



Abstract

Introduction: Rhinophyma is recognized as a common and severe skin disease manifested as progressive thickening of the nasal skin due to hypertrophy of the soft tissue. The most severe complication of rhinophyma is telangiectasis. So far the pathogenetic approach for the treatment of rhinophyma should be based on the removal of the dysplastic vessels to provide the appropriate revascularization of the involved skin area.

Case Report: This study presented the experience of the treatment of rhinophyma with the copper vapor laser (CVL) designed with the computerized scanner device. A 52-year-old elderly Caucasian male patient with typical clinical signs of rhinophyma was successfully managed during three sessions of CVL treatment. CVL emits light with a wavelength of 578 nm, exposure time of 0.2 seconds. The settings used for the CVL in scanner mode were set at 1.2 W. The scanner device has a hexagonal frame with a maximum width of 12 mm with the distance of 1 mm between centers of laser spots. The CVL treatment resulted in a restoration of the natural appearance of the nose without side effect during 18 months after treatment.

Conclusion: The described clinical case demonstrates excellent results of the management of rhinophyma by means of the scanned CVL. CVL treatment was associated with the removal both of dysplastic superficial skin vessels, the solution of the inflammation, decline of the sebum production and the disappearance of the nasal hypertrophy.

Keywords: Rhinophyma; Laser treatment; Copper vapor laser.

Introduction

Rhinophyma is considered to be the most advanced stage of rosacea associated with hyperproliferation of nasal skin epithelium and hyperproduction of sebaceous gland associated with persisted telangiectasia.¹ Rhinophyma usually affects middle-aged to elderly men. The surface of the nose seemed to be erythematous and telangiectatic with enlarged pores. Patients seek medical treatment to improve the shape of their disfigured noses. Treatment options for rhinophyma include surgical excision,^{2,3} dermabrasion, electrocautery, cryosurgery or laser treatment.⁴⁻⁸ Many doctors have recommended surgery as the first line of therapy for these lesions when applicable. But surgery is not always applicable due to the possible complications of anesthesia, cardiac failure, impaired hemostasis, and allergies to drugs used for anesthesia. Telangiectasis has been proved to promote the progression of rosacea due to the violation of venous outflow and following the aggravation of neuroimmune inflammation

around dysplastic vessels.⁹ So the removal of dysplastic vessels should be considered to provide the pathogenetic approach to the management of rhinophyma. The laser treatment with copper vapor laser (CVL) designed with scanner device was proved to be relevant in the management of telangiectasias without remote side effects.^{10,11}

Case Presentation

A 52-year-old elderly Caucasian male patient presented with typical clinical manifestations of rhinophyma (Figure 1). Fifteen years ago the patient noticed the reddening and inflamed skin on his nose. There was no improvement after previous treatment with Trichopol in tablets (repeatedly, for 6 months), vascular preparations, i.e., isotretinoin (for 6 months), externally various ointments with trichopol. During the last 5 years, the volume of neoplasm in the nasal area has increased by 2 times, the color of the skin has become cyanotic, formed stable cysts

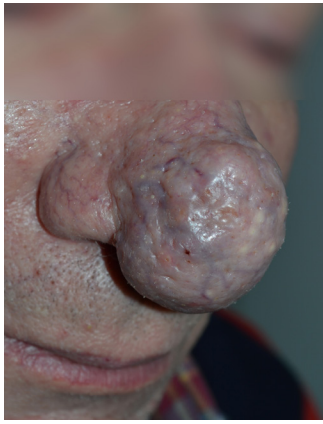

Figure 1. Male Patient 52 Years With Rhinophyma.

permanently inflamed. The excessive sebaceous excretion was observed. The patient felt a serious psychological dependence on the condition of the skin of the nose. He could not leave the house without a mask. The biopsy confirmed the diagnosis of rhinophyma. The patient was prescribed selective laser treatment of the total nasal skin area.

Step 1. First Treatment

The treatment with CVL (Yakhroma-Med, Lebedev Physics Institute of RAS) was performed with a wavelength of 578 nm, the pulse duration of 15 ns, exposure time of 0.2 seconds, the maximal power of 1.2 W. The procedure was performed under local anesthesia with Sol. Lidocaine 2%-2.0 mL. After each treatment session, the treated area was cooled with ice packs for 10 minutes. The patient was instructed about the importance of not injuring the treated sites. If crusts appeared, the patient was advised to apply an ointment with antibiotics three times a day until the crusts come off. The patient was informed of the need to protect the skin from the sun and the use of a broad-spectrum sunscreen (a factor of not less than 30) throughout the treatment, as well as two weeks after the laser treatment.

The surface of the skin of the nose was treated tightly with pulses imposed by scanner until pronounced bleaching appeared. The scanner can be used to treat a rhinophyma quickly and easily. The minimal illumination time quoted was 25 ms and a computer controlled scanner had been used in conjunction with a 5 W CVL (3 W at 511 nm, 2 W at 578 nm). The spot diameter was 1 mm. We have used a hexagonal pattern with a maximum width of 12 mm with 1 mm distance between the centers of laser spots. The delivery of energy in spots with surrounding zones of uninjured tissue promotes rapid wound healing. Uniform blanching was obtained with the scanner across the surface of the lesion. Mild erythema appeared during 15 minutes after the procedure. The formation of the crust began on the next day, was fully completed on the

second day and persisted for five days. The epithelial gel was prescribed externally. After the crust falling-off, the structure of the skin changed dramatically: tissue infiltration significantly diminished, no cysts were noted.

Step 2. Second Treatment

The patient sought medical attention again two months later. Despite the pronounced positive result of the first procedure, the patient complained of the presence on his nasal skin single cyanotic vessels, which he did not cosmetically like (Figure 2). Since the aesthetic defect was determined by the venous vascular bed, the mode of laser radiation was corrected: (wavelength 578 nm; the maximum power of 0.7-0.8 W; exposure time of 0.2 seconds).

Stage 3. Third Treatment

After another 2 months of the observation in some sites of the nasal skin, the persistence of large vessels was noted. To improve the aesthetic effect and prevent the recurrence of the disease, the procedure was repeated, but in a smaller volume - only on the vessels of the lateral surface of the nose. Individual vessels were traced via the lensed handpiece until an endpoint of vessel blanching was seen.

Results

The patient was followed up in clinic and reepithelialization was observed to take place within 2 weeks. There were no postoperative complications such as bleeding, pain or infection.

4 months after the first laser procedure, the volume of neoplasm in the nasal area of the patient decreased in sizes by 2 times (due to the reduction in the number of vessels. The volume of connective tissue decreased, due to normalization of the lymph drainage the edema resolved), the color of the nasal skin became light, the cysts formed no longer, the sebaceous excretions have ceased (Figure 3). The patient regarded the result of the treatment as

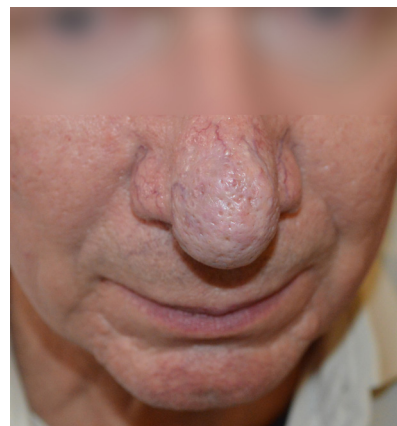

Figure 2. Stage 2. Two Months After 1 session of Copper Vapor Laser Exposure $\lambda = 578$ nm, power 1.2 W, Pulse Duration 0.2 Seconds.

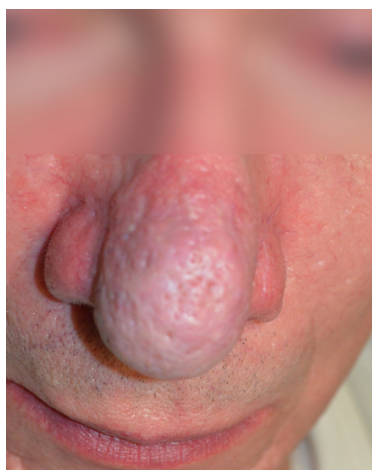

Figure 3. Stage 3. Four Months After 1 Session of Copper Vapor Laser Exposure $\lambda = 578$ nm, Power 0.8 W, Pulse Duration 0.2 s 1 Session.

very good, the quality of life fundamentally increased. No serious side effects were recorded.

Discussion

Over the last ten years some treatments and surgical techniques have been used to improve the cosmetic appearance of rhinophyma. Histologically, there is sebaceous gland hyperplasia, fibrosis, and hypervascularity. Rhinophyma is usually limited to the lower third of the nose. The main complaint in patients with rhinophyma is the facial disfigurement. Ablative laser treatment, such as CO₂ and erbium-doped yttrium aluminium garnet (Er:YAG),³⁻⁷ has become the favored method for the rhinophyma treatment. Despite their efficacy, they are associated with significant side effects including swelling, erythema, crusting, the risk for textural changes, and scarring. Ablative laser treatment causes an open wound, which makes the patient unable to work for several days and requires wound care.⁷ Ablative fractional devices demonstrated similar efficacy as the

previous generation of lasers with an improved safety profile.^{12,13}

The abnormal blood vessels of rhinophyma may be able to be targeted using the principle of selective photothermolysis.^{14,15} In the clinical study¹⁶ the rosacea telangiectasia was successfully treated by long pulse Nd:YAG (neodymium-doped yttrium aluminum garnet) laser at fluences between 160 and 210 J/cm² and 10 at 15 ms pulse duration. The CVL at 578 nm provides an effective tool for removal of vascular lesions.¹⁰⁻¹² To compare these laser sources, we performed the simulation procedure of the vessel heating by CVL and Nd:YAG laser on the base of the Matlab mathematical simulation software and applications thereof for solving differential equations in the Femlab partial derivatives and using the Finite Element Method as we described in.¹⁷

Figure 4 shows the calculated temperature levels for 9 vessels (3 vessels with a diameter of 30 μm (on the left), 3 vessels with a diameter of 100 μm (in the middle center) and 3 vessels with a diameter of 300 μm (on the right), exposed by CVL and Nd:YAG laser. The vessels of each diameter were assumed to be located at a depth of 150, 500 and 1000 μm respectively.

According to the results of our simulations, the 10-times higher fluences were needed for vessel heating to the coagulation temperature with the Nd:YAG laser radiation. It causes the increased heat dissipation throughout the dermis and produces the risk of scarring, hypo- and hyperpigmentation. So the use of CVL yellow light, which falls into the oxyhemoglobin and deoxyhemoglobin high absorption band, allows achieving the maximum efficiency of the selective heating of the dysplastic vessels.

CVL treatment aimed to decrease capillary blood flow and shrink the hypertrophic tissue of rhinophyma. CVL coagulates the dilated blood vessels up to a depth of about 0.6 mm¹⁸ and lead to a cure of the telangiectasia and diminished blood supply to the hypertrophic tissues and provides a shrinkage of the hypertrophic tissue.

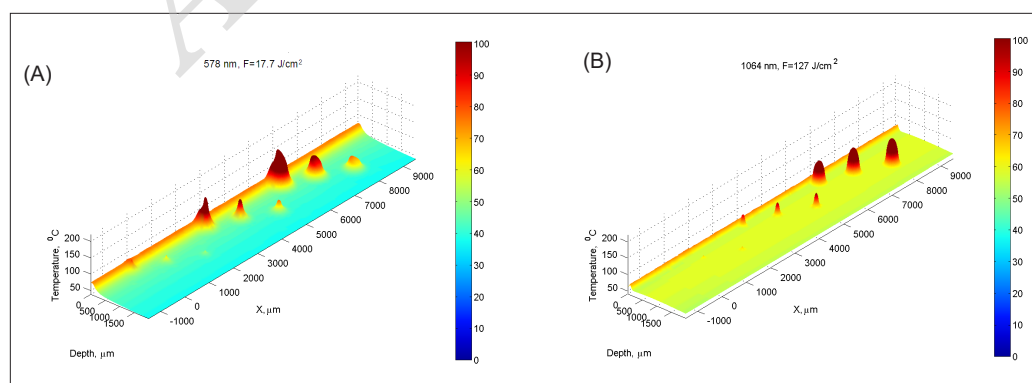


Figure 4. The Calculated Temperature Distribution of the Tissue and Vessel According to the Depth and Transverse Coordinate. Three vessels with a diameter of 30 μm (on the left), three vessels with a diameter of 100 μm (at the center) and three vessels with a diameter of 300 μm (on the right) are located at a depth of 150, 500 and 1000 μm respectively. Fluence value for CVL ($F = 17.7$ J/cm²(A)) and for Nd:YAG laser ($F = 127$ J/cm²) (B).

Conclusion

The efficacy of the selective laser treatment of a patient diagnosed with rhinophyma was shown to be good. The effect of laser therapy on the microcirculatory bed of the skin is caused by the destruction of pathologically dilated vessels, the optimization of tissue blood flow and the normalization of vascular tone, which produces an anti-inflammatory effect and more favorable conditions for the course of the reparative process in tissues. The advantage of this method is the option of repeating the application in cases of recurrence, easy handling in the delicate nasal area. Our patient demonstrates excellent results with scanned CVL treatment. The CVL treatment in the scanner mode provides more delicate exposure to treated areas, the intact dermal zones appeared to be more protected and healing time appeared to be shorter.

Ethical Considerations

Written informed consent was obtained from the patient before treatment.

Conflict of Interests

The authors declare no conflict of interest.

References

- Anzengruber F, Czernielewski J, Conrad C, et al. Swiss S1 guideline for the treatment of rosacea. *J Eur Acad Dermatol Venereol.* 2017;31(11):1775-1791. doi: 10.1111/jdv.14349
- Rosenberg WA, Felsher IM. Rhinophyma and acne rosacea treated with the electrosection current. *Illinois Med J.* 1950;97(5):281-282.
- Neagu TP, Al-Falah Kh, Tiglis M, et al. A curious case of rhinophyma in a 73-year-old patient. *Modern Medicine.* 2017;24(2):111-5.
- Lim SW, Lim SW, Bekhor P. Rhinophyma: Carbon dioxide laser with computerized scanner is still an outstanding treatment. *Australas J Dermatol.* 2009;50(4):289-293. doi: 10.1111/j.1440-0960.2009.00561.x.
- Orenstein A, Haik J, Tamir J, et al. Treatment of rhinophyma with Er:YAG laser. *Lasers Surg Med.* 2001;29(3):230-5.
- Serowka KL, Saedi N, Dover JS, Zachary CB. Fractionated ablative carbon dioxide laser for the treatment of rhinophyma. *Lasers Surg Med.* 2014;46(1):8-12. doi: 10.1002/lsm.22184.
- Bernstein LJ, Kauvar AN, Grossman MC, Geronemus RG. The short- and long-term side effects of carbon dioxide laser resurfacing. *Dermatol Surg.* 1997;23(7):519-525.
- Campolmi P, Bonan P, Cannarozzo G, et al. Highlights of thirty-year experience of CO2 laser use at the Florence (Italy) department of dermatology. *Scientific World Journal.* 2012;2012:546528. doi: 10.1100/2012/546528.
- Holmes AD, Spoenclin J, Chien AL, Baldwin H, Chang ALS. Evidence-based update on rosacea comorbidities and their common physiologic pathways. *J Am Acad Dermatol.* 2018;78(1):156-166. doi: 10.1016/j.jaad.2017.07.055.
- Klyuchareva SV, Ponomarev IV, Andrusenko YuN. Venous Ectasia of the vermilion border: copper vapor laser treatment (Russian). *Vestnik dermatologii i venerologii.* 2017;4:53-61. doi:10.25208/0042-4609-2017-0-4-53-61
- Smithies DJ, Butler PH, Pickering JW, Walker EP. A computer controlled scanner for the laser treatment of vascular lesions and hyperpigmentation. *Clin Phys Physiol Meas.* 1991;12(3):261-267.
- Madan V, Ferguson JE, August PJ. Carbon dioxide laser treatment of rhinophyma: a review of 124 patients. *Br J Dermatol.* 2009;161(4):814-818. doi: 10.1111/j.1365-2133.2009.09317.x.
- Kraeva E, Ho D, Jagdeo J. Successful Treatment of Rhinophyma With Fractionated Carbon Dioxide (CO2) Laser in an African-American Man: Case Report and Review of Literature of Fractionated CO2 Laser Treatment of Rhinophyma. *J Drugs Dermatol.* 2016;15(11):1465-1468.
- Anderson RR, Parrish JA. Microvasculature can be selectively damaged using dye lasers: A basic theory and experimental evidence in human skin. *Lasers Surg Med.* 1981;1(3):263-276.
- Moreira A, Leite I, Guedes R, Baptista A, Mota G. Surgical treatment of rhinophyma using carbon dioxide (CO2) laser and pulsed dye laser (PDL). *J Cosmet Laser Ther.* 2010;12(2):73-76. doi: 10.3109/14764171003706208
- Kozarev J. Use of long pulse Nd:YAG 1064nm laser for treatment of rosacea telangiectatica. *Journal of the Laser and Health Academy* 2011;2011(1):33-36.
- Pushkareva A, Ponomarev I, Isaev A, Klyuchareva S. Numerical investigation of vessel heating using a copper vapor laser and a pulsed dye laser in treating vascular skin lesions. *Laser Phys.* 2018;28:1-5. doi: 10.1088/1555-6611/aa8cdb
- Neumann R, Knobler R, Leonhartsberger H, Gebhart W. Comparative histochemistry of port-wine stains after copper vapor laser (578 nm) and argon laser treatment. *J Invest Dermatol.* 1992;99(2):160-167.