



# Clinical and Biological Effects of Adjunctive Photodynamic Therapy in Refractory Periodontitis

Rola Al Habashneh<sup>1\*</sup>, Mohammad A Mashal<sup>1</sup>, Yousef Khader<sup>2</sup>, Rana Qudah<sup>1</sup>

<sup>1</sup>Department of Preventive Dentistry, Jordan University of Science and Technology, Ramtha, Jordan

<sup>2</sup>Medical Education and Biostatistics, Department of Community Medicine, Public Health and Family Medicine, Faculty of Medicine, Jordan University of Science & Technology, Ramtha, Jordan

## \*Correspondence to

Rola Al Habashneh,  
Departments of Preventive  
Dentistry, Faculty of Dentistry,  
Jordan University of Science &  
Technology. P.O. Box (3030),  
Irbid 22110, Jordan  
Email: rolaperio@yahoo.com

Published online February 25,  
2019



## Abstract

**Introduction:** To date, no novel treatment approach is available for optimum outcomes regarding refractory periodontitis. The aim of the present study was to assess the efficiency of photodynamic therapy (PDT) in treating patients diagnosed with refractory periodontitis and compare the clinical and biological outcomes of conventional periodontal treatment with or without adjunctive PDT in these patients, by assessing clinical parameters (plaque index [PI], gingival recession [GR], bleeding on probing [BOP], periodontal probing depth [PPD] and clinical attachment level [CAL]) as well as biological parameters (IL-1 $\beta$ ) in the gingival crevicular fluid (GCF).

**Methods:** Sixteen patients within the age of 30 to 60 years, with a mean age of 40 years old, diagnosed with refractory periodontitis were included. In this split mouth design study, 2 quads (1 upper + 1 lower) from the same patient were randomly treated with (scaling and root planing [SRP]+PDT) together. The other 2 quadrants (1 upper + 1 lower) were treated by SRP only and selected to serve as controls. Clinical parameters including PI, GR, BOP, PPD and CAL and biological parameters (IL-1 $\beta$ ) in the GCF were measured at baseline, then at, 2 and 6 months after therapy.

**Results:** A statistically significant reduction in several clinical parameters as, BOP ( $P < 0.001$ ), PI ( $P < 0.001$ ), PPD ( $P < 0.001$ ) and CAL ( $P < 0.001$ ) in quadrant treated with SRP and adjunctive PDT when compared to control group treated with SRP alone was observed and both therapies showed non-statistically significant differences in the reduction of IL-1 $\beta$  level.

**Conclusion:** The inclusion of PDT as an adjunctive measure to nonsurgical conventional periodontal treatment seems to be a useful therapeutic measure in refractory periodontitis treatment.

**Keywords:** Gingival recession; Tooth, Photodynamic; Bleeding; Pocket depth.

## Introduction

Periodontitis is an inflammatory disease of the gingival and periodontal tissue, induced by pathogenic bacteria within the dental plaque biofilms, leading to clinical signs of inflammation and loss of the attachment apparatus supporting the teeth<sup>1,2</sup> Periodontitis is one of the most common diseases of the oral cavity<sup>3</sup> and is a multifactorial disease, several risk factors play a role in the disease etiology and modifies it's course.<sup>4</sup>

Up to now the critical objective of various periodontal treatment modalities has been to halt the progression of the disease and prevent its recurrence.

The conventional mechanical elimination of subgingival bacterial biofilms followed by an effective periodontal maintenance program are the cornerstone for controlling inflammatory periodontal disease, but this mechanical instrumentation of the root surface alone may fail to remove bacterial biofilm in some areas inaccessible

to periodontal instruments, such as root depression and furcation.<sup>5</sup> Also, periodontal mechanical debridement efficiency may decrease with increasing periodontal probing depths (PPDs) and with furcal involvement.<sup>6,7</sup> Thus, bacterial reservoirs could remain within the periodontal pockets on the root surface and promote recolonization which would affect periodontal healing and disease progression following treatment.

Patients exhibiting refractory periodontitis, despite the therapeutic efforts show low responsiveness to periodontal therapy by dental professionals and continue to show destruction of periodontal tissue.<sup>8</sup> The nature of refractory periodontitis has not been clearly understood yet. Various factors modulating host immune responses to bacterial challenge, including genetic factors, microbiological factors and other host-related factors (local or systemic) as local anatomic variations, smoking, diabetes, and other systemic diseases, were implicated in

the disease pathogenesis.<sup>9,10</sup>

The adjunctive use of systemic antibiotic has been proven to be an effective measure in the management of refractory periodontitis. However, many drawbacks associated with their use have been known as resistance-related phenomena, development of opportunistic infections, their unfavorable systemic side effects and the disagreements regarding their prescription.<sup>11,12</sup> Such drawbacks necessitate alternative strategies to control bacterial biofilms and to treat periodontal diseases.<sup>13</sup>

Photodynamic therapy (PDT) has been proposed as adjunctive treatment strategy to conventional mechanical therapy. This therapy utilizes singlet oxygen and free radicals, produced upon light – mediated activation of a photosensitizing agent to kill microbes.<sup>14</sup>

PDT seems to be an attractive treatment modality, which may be useful during initial and maintenance therapy for the treatment of refractory periodontitis, especially for residual pocket treatment, as it is a noninvasive low-level therapy, localized, low-cost, quick and simple treatment approach with confirmed clinical safety.<sup>15</sup>

Antimicrobial effects of PDT not only kills the bacteria but may also lead to the detoxification of endotoxins, such as lipopolysaccharide, inhibiting their stimulatory effect on proinflammatory cytokines production by mononuclear cells, and decreasing their biological activity.<sup>16</sup>

PDT was also expected to promote periodontal healing, due to its potential biomodulatory effects,<sup>15,17,18</sup> by inhibiting inflammatory mediators and host-derived cytokines, such as tumor necrosis factor- $\alpha$ , interleukin-1 $\beta$  (IL-1 $\beta$ ), and modulating host innate immunity, thus favoring cellular chemotaxis, promoting local vasodilation and collagen synthesis and angiogenesis.<sup>17,19,20</sup>

Due to the intricacy and many mysterious elements for refractory periodontitis, management may not be conceivable in all cases. PDT may be a helpful modality in treating and managing refractory periodontitis.

The main objective of this study was to assess the efficiency of PDT as an adjunctive therapy to nonsurgical periodontal therapy in refractory periodontitis by assessing clinical parameters (plaque index [PI], gingival recession [GR], bleeding on probing [BOP], PPD and clinical attachment level [CAL]) as well as biological parameters (IL-1 $\beta$ ) in the gingival crevicular fluid (GCF).

## Methods

Patients, who have been diagnosed with refractory periodontitis according to patient's records, were recruited from the Department of Periodontics, Faculty of Dentistry, and Jordan University of science and Technology, from October 2014 to December 2015. A diagnosis of refractory periodontitis only complies in patients who adequately comply with the recommended oral hygiene measures, attend regularly the scheduled periodontal maintenance appointments though continue

to demonstrate a decline in their periodontal status, as evidenced by the clinical signs and symptoms.

The clinical characteristics of refractory periodontitis by Kornman<sup>21</sup> were adopted to confirm diagnosis:

1. Multiple sites display clinically noticeable disease advancement.
2. Disease progress is distinct to former severity i.e. progression occurs even in sites of slight or no prior disease.
3. Disease advancement is not stopped by traditional periodontal treatment and regular supportive care that focuses on reduction of tooth-adherent bacterial accumulations.

Moreover, the diagnosis of “refractory” periodontitis was only made in patients who satisfactorily complied with the recommended oral hygiene measures and followed a regularly scheduled program of periodontal maintenance since diagnosis; this was confirmed by patients' records.

Upon entering the study each patient completed a patient questionnaire and received a periodontal clinical examination. Patients who fulfilled the inclusion criteria for the study had been informed about the study and were invited to participate in the study which required patient's commitment for a period of 6 months and each had been given a unique identifier.

The inclusion criteria included (1) aged 35 years or more; (2) having >12 natural teeth with a minimum of three in each quadrant, and (3) having refractory periodontitis.<sup>22</sup>

Patients with the following criteria were excluded (1) current smokers; (2) pregnant females; (3) females on estrogen therapy; (4) those who had received systemic antibiotics or surgical periodontal treatment within the past 12 months and (5) those who had a history of poorly controlled diabetes, liver disease, malignancy, radiotherapy, or allergy to toluidine blue.

At the beginning, a total sample of 20 patients (9 males and 11 females) diagnosed with refractory periodontitis had met the inclusion/exclusion criteria. All subjects were examined on dental chairs in the periodontal clinics in the dental teaching center of Jordan University of science and technology using sterile dental mirror, dental explorer and periodontal probe to assess the oral condition. Periodontal examination was conducted by a blinded investigator who was not involved in the treatment of the patients. All periodontal clinical measurements were performed by one periodontist, allowing an intra-experimental comparison of the values. Four patients with refractory periodontitis were examined at an interval of 48 hours. The intraclass correlation coefficients as a measure of intraexaminer reproducibility were 0.89 and 0.90 for the mean PPD and CAL.

At the start of every recall visit, the periodontist evaluated the gingival and periodontal tissues using a University of Michigan O' Probe with William's calibration. PPD, CAL, and GR were obtained at six sites of each tooth

(mesiobuccal, distobuccal, mesiolingual, distolingual and middle sites of the buccal and lingual sides). BOP was assessed at four sites of each tooth (mesial and distal sites of the buccal and lingual sides). Bleeding points were assessed 30 seconds after probing. Third molars were excluded from the examination. Clinical probing depths were measured to the nearest mm.

As shown in Figure 1, using a split-mouth design, 2 quadrants were treated with scaling and root planing (SRP) (control group), while the other 2 quadrants were additionally treated with PDT (test group). All patients received a conventional periodontal treatment, comprising SRP of all periodontally involved teeth, both hand instruments (Gracey curettes) and a piezoelectric ultrasonic handpiece were employed, 2 quadrants (test group) were additionally treated with PDT. Therefore, after periodontal debridement, the quadrants were assigned to different groups.

A total of 245 sites from 32 quadrants (16 upper and 16 lower) were treated by SRP with PDT as adjunctive treatment and a total of 257 sites from 32 quadrants (16 upper and 16 lower) were treated by SRP alone. Sites in contralateral quadrants had been separated by 1 tooth or more to avoid the photosensitizing agent flowing across the interdental papillae to the contra-lateral quadrant. Periodontal parameters were examined again after 2 months and after 6 months of the treatment. Of eligible patients, one male and one female participant did not attend the follow-up examinations and were therefore excluded. Two other females were excluded also due to ingestion of systemic antibiotics during the follow-up

examinations.

A total of 16 subjects had successfully completed the study period of 6 months and were included in the data analyses.

## Results

In our clinical trial, PDT was performed with a PAD™ high level disinfection which is based on 2 components, the PAD™ solution (Orange dental, Denfotex Research Ltd, UK) and PAD Plus device (Orange dental, Denfotex Research Ltd, UK): a red LED light system of a specific wavelength (635 nm) to activate the PAD™ solution. This is the peak wavelength (635 nm) at which Toluidine Blue O (TBO) absorbs energy so maximum excitation and release of singlet oxygen is achieved. Photosensitizer was applied by placing the applicator at the bottom of the periodontal pocket and was continuously deposited in a coronal direction and left for 60 seconds. Afterwards, the PAD Plus was used with an 8.5-cm-long flexible fiber optic tip curved at an angle of 60° with a spot size 0.06 cm in diameter for 60 seconds. This treatment approach was applied to all test sites. Laser was applied circumferentially at 6 sites per tooth. The application time of both the photosensitizer and laser light was monitored, to avoid phototoxic reactions. The calibration of the diode laser was performed according to the manufacturer instructions.

Collection of GCF was done at baseline, 2 months and after 6 months for control and test sites. The site with the deepest pocket in each quadrant was chosen to take a GCF sample. These sites were isolated with cotton rolls

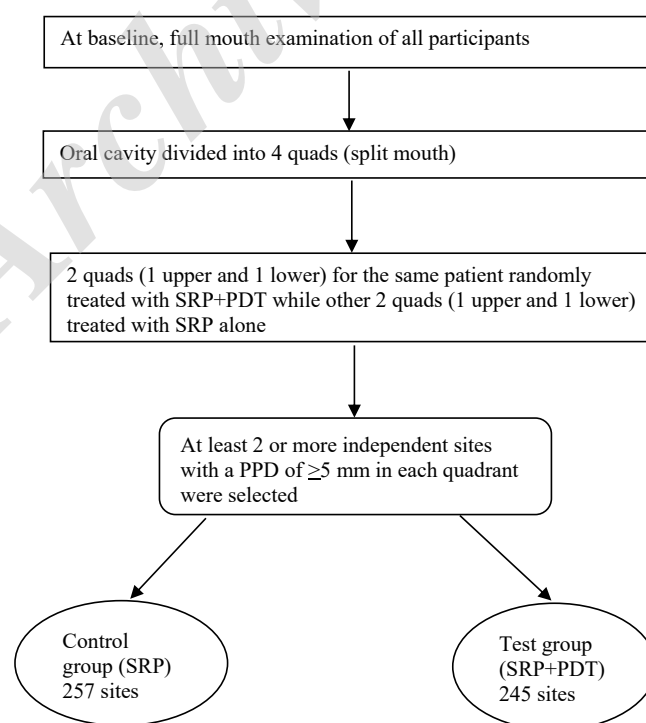


Figure 1. Procedure and Studied Groups.

and a saliva ejector and gently air-dried after removal of the supragingival plaque from the interproximal surfaces.

The GCF samples were collected with sterile paper strips (Periopaper, Oraflow Inc, Smithtown, NY, USA) carefully inserted into the crevice until mild resistance was felt and left in place for 30 seconds. Subsequently, the paper strips were placed into a sterile microtube vial and stored immediately at  $-20^{\circ}\text{C}$  until analyzed. Samples visibly contaminated with blood were discarded. The levels of total IL-1 $\beta$  was measured using enzyme-linked immunosorbent assay (ELISA) kit (Platinum ELISA, eBioscience Inc, San Diego, CA, USA).

## Results

A total of 16 patients (8 males and 8 females) with refractory periodontitis had successfully completed the study period of 6 months. Patients aged between 30 and 60 year, with a mean of 43.2 years. All subjects were Jordanian and none of them was smoker.

The multivariate analysis using the general linear model (GLM) repeated measures procedures showed significant interaction between treatment and time effects on the studied parameters ( $P < 0.001$ ) except for IL-1 $\beta$  ( $P = 0.379$ ). Table 1 shows the mean of clinical parameters of both treatment groups at baseline, 2 and 6 months.

At the baseline, the 2 groups differed significantly in the mean PI only being higher in the SRP group ( $P = 0.019$ ). Using the repeated analysis PDT as an adjunct treatment was superior to conventional treatment in patients diagnosed with refractory periodontitis in terms of clinical

parameters including PI, BOP, PPD, and CAL. Except for IL-1 $\beta$ , there were remarkable and significant reduction in all clinical parameters after 2 months of the treatment in both treatment and control groups ( $P < 0.001$ ). Thereafter, the mean of each clinical parameter increased significantly in both groups compared to the means at 2 months. At 6 months, the means of clinical parameters remained significantly lower than the means at the baseline. At both 2 and 6 maintenance visits, the means of clinical parameters remained significantly lower in the test group than that in the control group.

The study revealed superior results for PDT used as an adjunct to conventional treatment in patients diagnosed with refractory periodontitis in terms of clinical parameters. However PDT had no effects on the level of expression of cytokines (IL-1 $\beta$ ).

No adverse effects, such as discomfort, burning sensation, bleeding or pain related to the use of PDT, were reported by any of the participants.

## Discussion

To the best of our knowledge, this is the first clinical trial that studied the effect of PDT on refractory periodontitis.

Several therapeutic modalities have been adopted for the treatment of refractory periodontitis, which includes scaling and root planning, surgical intervention and often systemic antibiotics administration. However, optimum results were hampered with the regrowth of bacterial biofilms leading to recurrence of inflammation and subsequent tissue destruction.

**Table 1.** The Change in the Means of Clinical Parameters Over Time for the Treatment (SRP+PDT) and Control (SRP) Groups

	Baseline (0 Month), Mean (SD)	2 Months Mean (SD)	6 Months Mean (SD)	P value (0 vs. 2 Months)	P value (0 vs. 6 Months)	P value (2 vs. 6 Months)
<b>PI</b>						
SRP	1.26 (0.63)	0.67(0.47)	0.89(0.48)	<0.001	<0.001	<0.001
SRP+PDT	1.13 (0.61)	0.38(0.49)	0.62(0.54)	<0.001	<0.001	<0.001
P value (SRP vs. SRP+PDT)	0.019	<0.001	<0.001			
<b>BOP</b>						
SRP	0.99 (0.11)	0.61(0.49)	0.81(0.4)	<0.001	<0.001	<0.001
SRP+PDT	0.96 (0.19)	0.03(0.18)	0.29(0.45)	<0.001	<0.001	<0.001
P value (SRP vs. SRP+PDT)	0.066	<0.001	<0.001			
<b>PD</b>						
SRP	5.87 (1.2)	4.94(1.1)	5.4(1.17)	<0.001	<0.001	<0.001
SRP+PDT	5.74 (1.16)	4.22(0.95)	4.62(0.9)	<0.001	<0.001	<0.001
P value (SRP vs. SRP+PDT)	0.230	<0.001	<0.001			
<b>CAL</b>						
SRP	6.75 (1.79)	5.9(1.77)	6.3(1.75)	<0.001	<0.001	<0.001
SRP+PDT	6.65 (1.68)	5.27(1.5)	5.61(1.43)	<0.001	<0.001	<0.001
P value (SRP vs. SRP+PDT)	0.512	<0.001	<0.001			
<b>IL-1<math>\beta</math></b>						
SRP	344.2 (277.4)	410.4 (174.2)	352.5 (204.3)	0.463	0.988	0.554
SRP+PDT	373.5 (215.0)	392.2 (139.8)	282.5 (159.2)	0.903	0.098	0.073
P value (SRP vs. SRP+PDT)	0.639	0.648	0.131			

Abbreviations: PI, plaque index; GR, gingival recession; BOP, bleeding on probing; PPD, periodontal probing depth; CAL, clinical attachment level; IL-1 $\beta$ , interleukin-1 $\beta$ ; PDT, photodynamic therapy; SRP, scaling and root planing; PD, Probing depth.



PDT was found to have a direct effect on extracellular molecules within the biofilm, such as polysaccharides, which were highly sensitive to singlet oxygen and susceptible to photo damage.<sup>23</sup> Also, damage to DNA and plasma membrane proteins of periodontal pathogens have been demonstrated resulting in their deactivation, as *Porphyromonas gingivalis* or *Fusobacterium nucleatum*.<sup>24,25</sup> PDT were found to be equally effective against antibiotic-resistant and antibiotic-susceptible bacteria, and upon repeated application of PDT, development of resistant strains has not been induced.<sup>26</sup>

Some concerns regarding the clinical application of PDT were raised. One concern is the PDT's potential photocytotoxicity to host cells. However, it has been demonstrated that PDT laser light dose required for bacterial killing is much lower than the toxic dose for keratinocytes and fibroblasts.<sup>27</sup> Killing the entire flora leaving the host susceptible to opportunistic infections were another concern, which were managed by the introduction of selective photosensitizers, that selectively stain and kill the targeted pathogenic bacteria without affecting the surrounding periodontal tissues adversely.<sup>28,29</sup>

In the present study, PI, BOP, PPD and CAL improved significantly in the sites treated with a combination of SRP and PDT from baseline to the final examination compared to SRP alone.

Our results are consistent with what was reported by a study showing a significant decrease in the mean value of BOP and gain in the mean CAL from baseline, at six weeks and at 12 weeks compared to SRP alone on patients with moderate to advanced periodontal disease.<sup>30</sup> This was supported by another study as well, adjunctive PDT was not only superior to SRP in terms of improvements in PD and CAL, but also in BOP.<sup>31</sup>

In our study BOP was reduced in both groups. The decrease in BOP incidence in the present study in both test and control sites reflects the decrease in the periodontal inflammation, since the BOP index is a predictor of the progression of periodontal disease. These results were similar to a study that found improvement in full mouth bleeding score (FMBS) with adjunctive PDT.<sup>32</sup> Improvement only in bleeding scores could be attributed to photobiomodulation, as light can reduce inflammation and inflammatory cell infiltration, decrease the formation of abnormal blood vessels and bleeding, and maintains healthy blood vessels by the accelerating of collagen synthesis and organization.<sup>33,34</sup>

The data out on PDT and periodontitis is not conclusive as a published systematic review/meta-analysis, concluded that using PDT as an adjunct or alternative to SRP did not add clinically significant benefits.<sup>35</sup> A study stated that adjunctive PDT did not provide any additional benefits clinically or biologically.<sup>36</sup> But all agreed that some benefits can be achieved by PDT, such as it is a noninvasive modality with minimal risk of thermal injury preventing damage to adjacent hard and soft periodontal

tissue, reduced tendency to develop bacterial resistance, elimination of microorganisms in sites that might be inaccessible to selectivity in its effect, technical simplicity with rapid and painless application.

In this study, a significant reduction of the mean PI for (SRP) and (SRP+PDT) groups was noticed at the recall visits compared with the baseline measurement. The significant reduction of plaque was due to the thorough SRP performed at the first visit for both test and control sites and oral hygiene instructions. Our findings also showed significant reduction in mean values for PI in the test sites at 2 and 6 months postoperatively in comparison with the control sites. This is generally consistent with the results of previous studies.<sup>37</sup>

Our findings for IL-1 $\beta$  levels analysis are consistent with the results of other investigations, which revealed that adjunctive PDT did not result in any significant changes in the levels of the inflammatory marker IL-1 $\beta$ .<sup>38</sup>

Thus, by adding adjunctive photodynamic treatment to conventional mechanical and chemical approaches, it might be possible to improve nonsurgical periodontal therapy approach. However, Further more detailed, controlled clinical, microbiological, and biochemical research and meta-analysis is necessary to determine the effectiveness of PDT in the treatment of refractory periodontitis.

Few limitations have been observed in the study. The study was done for a short duration with a small sample size and confined to bilateral teeth exhibiting similar disease pattern. No microbiological sampling and analysis were carried on.

Within the limitation of this study, it is concluded that the PDT as an adjunct to SRP was superior to conventional treatment in patients diagnosed with refractory periodontitis in terms of clinical parameters. Results showed significant clinical improvement in terms of CAL gain, PI reduction, PD reduction and BOP reduction. Therefore, PDT adjunctive treatment may provide a more favorable healing environment and improve the periodontal clinical parameters.

### Ethical Considerations

The study was approved by the Institutional Review Board of Jordan University of Science and Technology. All procedures performed in studies involving human participants were in accordance with the ethical standards of the institutional and/or national research committee and with the 1964 Helsinki Declaration and its later amendments or comparable ethical standards.

### Conflict of Interests

The authors declare no conflict of interest.

### References

1. Tonetti MS, Claffey N; European Workshop in Periodontology group C. Advances in the progression of

- periodontitis and proposal of definitions of a periodontitis case and disease progression for use in risk factor research. Group C consensus report of the 5th European Workshop in Periodontology. *J Clin Periodontol.* 2005;32(Suppl. 6):210-213.
2. Eke PI, Dye BA, Wei L, Thornton-Evans GO, Genco RJ; CDC Periodontal Disease Surveillance workgroup. Prevalence of periodontitis in adults in the United States: 2009 and 2010. *J Dent Res.* 2012;91:914-920. doi:10.1177/0022034512457373
  3. Eke PI, Dye AB, Wei L, Slade G, et al. Update on prevalence of periodontitis in adults in the United States: NHANES 2009 to 2012. *J Periodontol.* 2015;86:611-622 doi:10.1902/jop.2015.140520
  4. Genco RJ. Current view of risk factors for periodontal diseases. *J Periodontol.* 1996;67(10):1041-1049. doi:10.1902/jop.1996.67.10.1041
  5. Adriaens PA, Edwards CA, DeBoever JA, Loesche WJ. Ultrastructural observations on bacterial invasion in cementum and radicular dentin of periodontally diseased human teeth. *J Periodontol.* 1988;59(8):493-503. doi:10.1902/jop.1988.59.8.493
  6. Brayer W, Mellonig J, Dunlap R, Mrinak K, Carson R. Scaling and root planing effectiveness: the effect of root surface access and operator experience. *J Periodontol.* 1989; 60:67-72. doi:10.1902/jop.1989.60.1.67
  7. Rabbani G, Ash M, Caffesse R. The effectiveness of subgingival scaling and root planing in calculus removal. *J Periodontol.* 1981;52:119-123
  8. Parameters on "Refractory" Periodontitis. *J Periodontol* 2000; 71(Parameters of Care Supplement): 859-860.
  9. Bhide VM, Tenenbaum HC, Goldberg MB. Characterization of patients presenting for treatment to a university refractory periodontal diseases unit: three case reports. *J Periodontol.* 2006;77:316-322. doi:10.1902/jop.2006.050108
  10. Bhide VM, Tenenbaum HC, Goldberg MB. Characterization of patients presenting for treatment to a university refractory periodontal diseases unit: three case reports. *J Periodontol.* 2006;77(2):316-22. doi:10.1902/jop.2006.050108
  11. Walker CB, Gordon JM, Mangunsson I, Clark WB. A role for antibiotics in the treatment of refractory periodontitis. *J Periodontol* 1993;64(8 Suppl):772-81. doi:10.1902/jop.1993.64.8s.772
  12. Haffajee AD, Socransky SS, Gunsolley JC. Systemic anti-infective periodontal therapy. A systematic review. *Ann Periodontol.* 2003;8(1):115-81.
  13. Lee HJ, Kang IK, Chung CP, Choi SM. The subgingival microflora and gingival crevicular fluid cytokines in refractory periodontitis. *J Clin Periodontol* 1995;22:885-890.
  14. Takasaki AA, Aoki A, Mizutani K, et al. Application of antimicrobial photodynamic therapy in periodontal and peri-implant diseases. *Periodontol* 2000. 2009;51:109-140. doi:10.1111/j.1600-0757.2009.00302.x
  15. Sgolastra F, Petrucci A, Severino M, Graziani F, Gatto R, Monaco A. Adjunctive photodynamic therapy to non-surgical treatment of chronic periodontitis: a systematic review and meta-analysis. *J Clin Periodontol.* 2013; 40(5):514-526. doi:10.1111/jcpe.12094
  16. Komerik N, Wilson M, Poole S. The effect of photodynamic action on two virulence factors of gram – negative bacteria. *Photochem Photobiol.* 2000;72:676–680.
  17. Huang YY, Tanaka M, Vecchio, D. Garcia-Diaz M. Chang J, Morimoto Y, Hamblin M. Photodynamic therapy induces an immune response against a bacterial pathogen. *Expert R Clin Immunol.* 2012;8:479–494. doi:10.1586/eci.12.37
  18. Marques MM, Pereira AN, Fujihara NA, Nogueira FN, Eduardo CP. Effect of low-power laser irradiation on protein synthesis and ultrastructure of human gingival fibroblasts. *Lasers Surg Med.* 2004;34:260–265. doi:10.1002/lsm.20008
  19. Tanaka M, Mroz P, Dai T, et al. Photodynamic therapy can induce a protective innate immune response against murine bacterial arthritis via neutrophil accumulation. *PLoS One.* 2012;7:e39823.
  20. Houreld N, Abrahamse H. In vitro exposure of wounded diabetic fibroblast cells to a helium-neon laser at 5 and 16 J/cm<sup>2</sup>. *Photomed Laser Surg.* 2007;25:78–84. doi:10.1089/pho.2006.990
  21. Kornman KS. Refractory periodontitis: critical questions in clinical management. *J Clin Periodontol.* 1996;23(3):293-298. PMID: 8707993
  22. Colombo AP, Haffajee AD, Dewhirst FE, et al. Clinical and microbiological features of refractory periodontitis subjects. *J Clin Periodontol.* 1998;25:169–180.
  23. Konopka K, Goslinski T. Photodynamic therapy in dentistry. *J Den Res.* 2007;86:694-707. doi:10.1177/154405910708600803
  24. Vaara M. Agents that increase the permeability of the outer membrane. *Microbiol Rev.* 1992;56:395–411.
  25. Makdoui K, Bäckman A. Photodynamic UVA-riboflavin bacterial elimination in antibiotic-resistant bacteria. *Clin Exp Ophthalmol.* 2016;44(7):582-586. doi:10.1111/ceo.12723
  26. Pfitzner A, Sigusch BW, Albrecht V, Glockmann E. Killing of eriodontopathogenic bacteria by photodynamic therapy. *J Periodontol.* 2004;75(10):1343–1349. doi:10.1902/jop.2004.75.10.1343
  27. Soukos NS, Wilson M, Burns T, Speight PM. Photodynamic effects of toluidine blue on human oral keratinocytes and fibroblasts and streptococcus sanguis evaluated in vitro. *Lasers Surg Med.* 1996;18:253–9. doi:10.1002/(SICI)1096-9101(1996)18:3<253::AID-LSM6>3.0.CO;2-R
  28. Kolbe MF, Ribeiro FV, Luchesi VH, et al. Photodynamic therapy during supportive periodontal care: clinical, microbiologic, immunoinflammatory, and patient-centered performance in a split-mouth randomized clinical trial. *J Periodontol.* 2014;85(8):e277-286. doi:10.1902/jop.2014.130559
  29. Bhatti M, MacRobert A, Meghji S, Henderson B, Wilson M. A study of the update of Toluidine Blue O by porphyromonas gingivalis and the mechanism of lethal photosensitization. *Photochem Photobiol.* 1998;68:370–376.
  30. Andersen R, Loebel N, Hammond D, Wilson M. Treatment of periodontal disease by photodisinfection compared to scaling and root planing. *J Clin Dent.* 2007;18(2):34-38.
  31. Braun A, Dehn C, Krause F, Jepsen S. Short-term clinical effects of adjunctive antimicrobial photodynamic therapy in periodontal treatment: a randomized clinical trial. *J Clin Periodontol.* 2008;35(10):877-884. doi:10.1111/j.1600-051X.2008.01303.x

32. Christodoulides N, Nikolidakis D, Chondros P, et al. Photodynamic therapy as an adjunct to nonsurgical periodontal treatment: a randomized, controlled clinical trial. *J Periodontol.* 2008;79:1638-44 doi:10.1902/jop.2008.070652
33. Woodruff LD, Bounkeo JM, Brannon WM, et al. The efficacy of laser therapy in wound repair: a metaanalysis of the literature. *Photomed Laser Surg.* 2004;22:241-247. doi:10.1089/1549541041438623
34. Prates RA, Yamada AM, Suzuki LC, et al. Histomorphometric and microbiological assessment of photodynamic therapy an adjuvant treatment for periodontitis: a short-term evaluation of inflammatory periodon conditions and bacterial reduction in a rat model. *Photomed Laser Surg.* 2011;29:835-844. doi:10.1089/pho.2010.2984
35. Azarpazhooh A, Shah PS, Tenenbaum HC, Goldberg MB. The effect of photodynamic therapy for periodontitis: A systematic review and meta-analysis. *J Periodontol.* 2010;81(1):4-14. doi:10.1902/jop.2009.090285
36. Birang R, Shahaboui M, Shadmehr E, Naqsh N. Effect of nonsurgical periodontal treatment combined with diode laser or photodynamictherapy on chronic periodontitis: a randomized controlled split-mouth clinical trial. *J Laser Med Sci.* 2015;6(3):112-9. doi:10.15171/jlms.2015.04
37. Badersten A, Nilvéus R, Egelberg J. Effect of nonsurgical periodontal therapy. *J Clin Periodontol.* 1981;8(1):57-72.
38. Giannopoulou C, Cappuyns I, Cancela J, Cionca N, Mombelli A. Effect of photodynamic therapy, diode laser, and deep scaling on cytokine and acute-phase protein levels in gingival crevicular fluid of residual periodontal pockets. *J Periodontol.* 2012;83(8):1018-102. doi:10.1902/jop.2011.110281

Archive of SID