



Original Research Paper

Histopathologic changes of lung in asthmatic male rats treated with hydro-alcoholic extract of *Plantago major* and theophylline

Farah Farokhi^{1*}, Fereshteh Khaneshi

Abstract

Objective: *Plantago major* (*P. major*) is one of the medicinal crops in the world which has therapeutic properties for treatment of respiratory and gastrointestinal diseases. Theophylline is commonly used for the treatment of respiratory diseases. In this study, we investigated the protective effects of hydro-alcoholic extract of *P. major* on lung in asthmatic male rats.

Materials and Methods: 32 male adult rats were randomly divided into 4 groups: The control group (C) received normal saline; Asthma (A) group received a normal diet; Asthma group treated with Theophylline (200 mg/kg b.w.) (T); Asthma group which received *p.major* (100 mg/kg b.w.) (P). Asthma was induced by citric acid, 0.1 mg in form of spraying. The injection of *P.major* extract and theophylline was administered intraperitoneally for four weeks. At the end of the treatment, all of the rats were sacrificed and lungs were taken out, fixed, and stained with H&E, toluidine blue, and PAS, then histological studies were followed with light microscope.

Results: Results showed that, in asthmatic group, the mean number of mast cells was significantly increased ($p < 0.05$). Thickness of alveolar epithelium and accumulation of glycoprotein in airways was increased. Moreover, in some of alveolar sac hemorrhaging was observed. Administration of *p.major* extract in asthmatic rats restored these changes towards normal group.

Conclusion: The present study revealed that *P. major* compared with theophylline, has a protective effect on lung in asthmatic rats.

Keywords: Asthma, Lung, Male Rats, *Plantago major*, Theophylline

1- Department of Biology, Faculty of Science, Urmia University, I. R. Iran

Corresponding author: Tel: 09143460715

E-mail: f.farokhi@urmia.ac.ir

Introduction

Airways inflammation is thought to play a central role in the pathogenesis of asthma. Clinical investigations show a correlation between the presence of activated inflammatory cells (neutrophils, mast cells, and eosinophils), histological changes to pulmonary tissue, and the development of airways hyperreactivity (Wagelie steffen et al., 2006). Although there is no cure for asthma, there are ways to control and prevent symptoms. Drugs used in asthma have been divided into two categories: drugs that cause dilated respiratory tract and preventive medications that suppresses inflammation and prevent symptoms of respiratory tract diseases. Asthma symptoms are removed with specific mechanisms of enzyme function in the airway cells (Boskabady et al., 2002). One of the anti-asthma drugs is theophylline which belongs to xanthin family that causes dilation of the smooth muscles and eliminates sudden obstruction (Sohrabi et al., 2009). Traditionally, using medicinal plants for curing of respiratory diseases has been considered many years ago (Rahimian, 2002). Researchers have been reported that ginger plants could be effective in treating asthma. *Plantain* is found all over the world and is one of the most abundant accessible medicinal herbs (Green, 2000). It contains many bioactive compounds including allantoin, aucubin, ursolic acid, flavonoids, and asperuloside. Scientific studies have shown that plantain extract has a wide range of biological effects including "wound healing activity, anti-inflammatory, analgesic, antioxidant, weak antibiotic, immunomodulating, and anti-ulcerogenic activity" (Samuelsen, 2000).

The root of *plantain* was traditionally used to treat wounds, as well as fever and respiratory infections. This plant consists of phenol combinations and has antioxidant property (Mehrabian et al., 2009). Its leaf (due to consist of Tanen and Mucilage) is beneficial in the treatment of the inflammation of the upper portion of

respiratory system. (Razavi et al, 2009). *Plantago major* (*P. major*) with specific polysaccharides improves wound. A research has shown that *P. major* can be effective in the treatment of chronic bronchitis (Tilford et al., 1997). This research revealed that *Plantago lanceolata* has antitussive effects in Guinea pigs (Boskabady et al., 2006). In this research, the antiasthmatic effect of *P. major* was evaluated.

Materials and Methods

Preparation of extracts

Fresh, green *P. major* plants were collected from Urmia highland in May 2011 and authenticated by a professor from the Department of Biology at Urmia University with herbarium number of 3996. The leaves of samples were dried in shadow at room temperature for seven days. Collected samples were ground by an electrical mill. One hundred grams of powder samples were added to 1000 ml ethanol 96%, then after 24 h, the solution was filtered. In the second step, ethanol 70% was added to the remained dry materials. After 24 h, the solution was filtered and then evaporated repeatedly to half of the first volume by rotary evaporator in 50 °C and 70 rpm. Concentrated extracts were dried on water bath at 40 °C temperature to prepare injected extract. This powder was solved in specific volume of normal saline (Boskabady et al., 2006).

Animal treatment

The current study was conducted on 32 healthy adult male Wistar rats weighing 200±20 g. Animals were kept in standard conditions with constant 12h light/dark cycle at temperature of 22±5 °C. The rats were fed with standard diet. Rats were purchased from Pasteur Institute, Tehran, Iran. The animals were handled in accordance with the Institutional Guidelines for the Care and Use of Animals for Experimental Purpose. The animals

were acclimatized to the animal room condition for two weeks prior to the experiment. These rats were divided into equal four groups with 8 rats per group as follows: The first control group received normal saline. The experimental groups were asthmatic rats. The second group (A): untreated asthma, received normal diet. The third asthmatic group was injected Theophylline 200 mg/kg b.w. intraperitoneally (T). The fourth asthmatic group received intraperitoneally hydro-alcoholic extract of *p. major* which was dissolved in normal saline with dosage of 100 mg/kg b.w. (P). Treatment periods were 4 weeks and drugs were administered intraperitoneally with insulin needle.

Induction of asthma in rats

Asthma was induced by citric acid 0.1 mg in form of spraying for seven minutes along fifteen days. Asthma symptoms including wheezing (a whistling sound when breathe), chest tightness, shortness of breath, and coughing were observed (Bartlett et al., 2008).

Tissue preparation

At the end of the experiment, the rats were anesthetized by chloroform and their lungs were taken out and fixed in 10% natural buffer formalin. After tissue processing, the samples were blocked in paraffin blockers and then stained with H&E, toluidine blue, and PAS. Histopathological studies were followed by light microscope. Mast cells were counted with netted lenses in the unit area (mm²).

Statistical analysis

All data were expressed as mean±SEM. One-way ANOVA followed by Tukey's post hoc test for comparisons were used for statistical evaluation. Statistical significance was accepted at p<0.05. The graphs were drawn by Excell software, 2007.

Results

Histopathological study of lung tissue in healthy normal control group revealed the alveolar sac and bronchioles with normal epithelium. In asthmatic group, the accumulation of inflammatory cells and lymphoid nodules around the interalveolar septum was seen. Moreover, thickness of epithelium in the alveoli was increased with multiple centers of hemorrhage in some of alveoli and replete with blood in the connective tissue between alveoli were observed. In the group treated with the extract of *plantago*, the thickness of epithelium was decreased and improved, meanwhile presence of lymphoid cells was less and scattered. In this group, bronchioles and alveolar sacs were similar to the control group. In the group treated with theophylline compared with asthma group, the thickness of epithelium was reduced, while in some of the alveoli, the thickness of epithelium was increased and replete with blood was observed (Figure 1).

Histopathological study with toluidine blue staining revealed the reduction of the size and number of mast cells in the control group. Moreover, alveolar sac and bronchioles with normal height epithelium were seen. In asthmatic group, thickness of alveolar epithelium, the size, and number of mast cells was significantly increased (p<0.05). Furthermore, multiple centers of hemorrhage in some of alveolar sacs were observed with presence of hemosiderin pigments. In the P group which was treated with extract of *p. major*, the thickness of epithelium was recovered, the size and the number of lymphoid cells were less and scattered. In the theophylline group compared with the asthma group, the thickness of epithelium was reduced, but number and size of mast cells was similar to the asthma group (Figure 2).

Histopathological study in the asthma group with PAS staining revealed that the glycoprotein compounds accumulates in airways and all of goblet cells in bronchioles were emptied and height of bronchiolar epithelium was increased. Moreover, thickness of epithelium in the alveoli was increased and a lot of large

nodules around bronchioles were observed. While in the *plantago* groups, the bronchioles and air sacs were similar to the control group, meanwhile presence of lymphoid cells was less and scattered. In the group treated with theophylline not only all of goblet cells in bronchioles were

evacuated compared with the control group, but also presence of glycoprotein compounds in airways was conspicuous. The thickness of epithelium was reduced, but in some alveoli it was similar to asthma group (Figure 3).

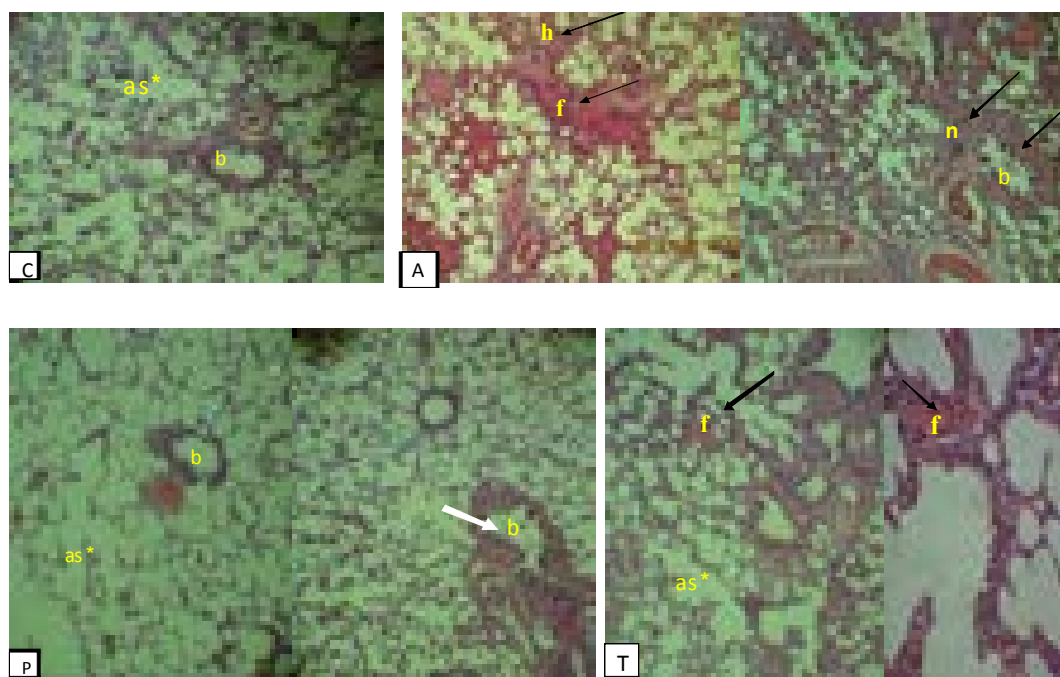


Figure 1. Cross sections of lung in experimental groups stained with H&E, 40×. C: Normal control; A: Asthma group; P: *Plantago* group; T: Theophylline group; Lymphoid nodules (n); alveolar sac (as); epithelium (ep); hemorrhage (h); replete blood (f); bronchiole (b).

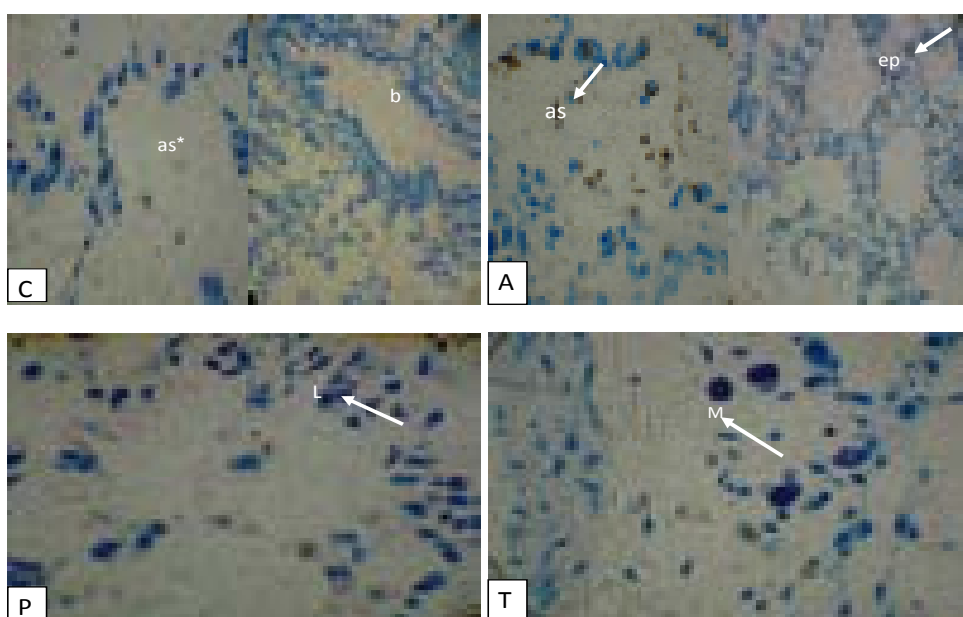


Figure 2. Cross sections of lung in experimental groups stained with toluidine blue, 400×. C: Normal control; A: Asthma group; P: *Plantago* group; T: Theophylline group; epithelium (ep); mast cell (M); alveolar sac (as); bronchiole (b); lymphocyte (L).

Effects of *Plantago major* on asthma

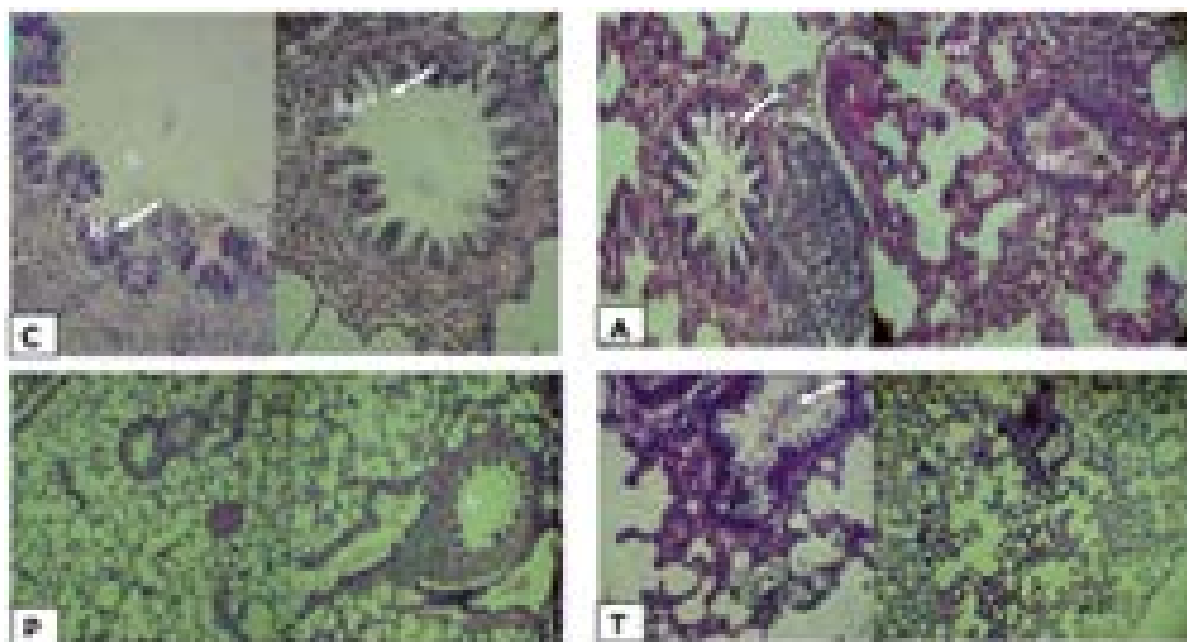


Figure 3. Cross sections of lung in experimental groups, stained with PAS, 100 \times . C: Normal control; A: Asthma group; P: *Plantago* group; T: Theophylline group; epithelium (ep); glycoprotein (gp); bronchiole (b); lymphatic nodule (n), goblet cell (g). This figure is showing increasing of glycoprotein compounds in bronchial of asthmatic and theophylline groups, while reduction of these symptoms in control and *plantago* groups.

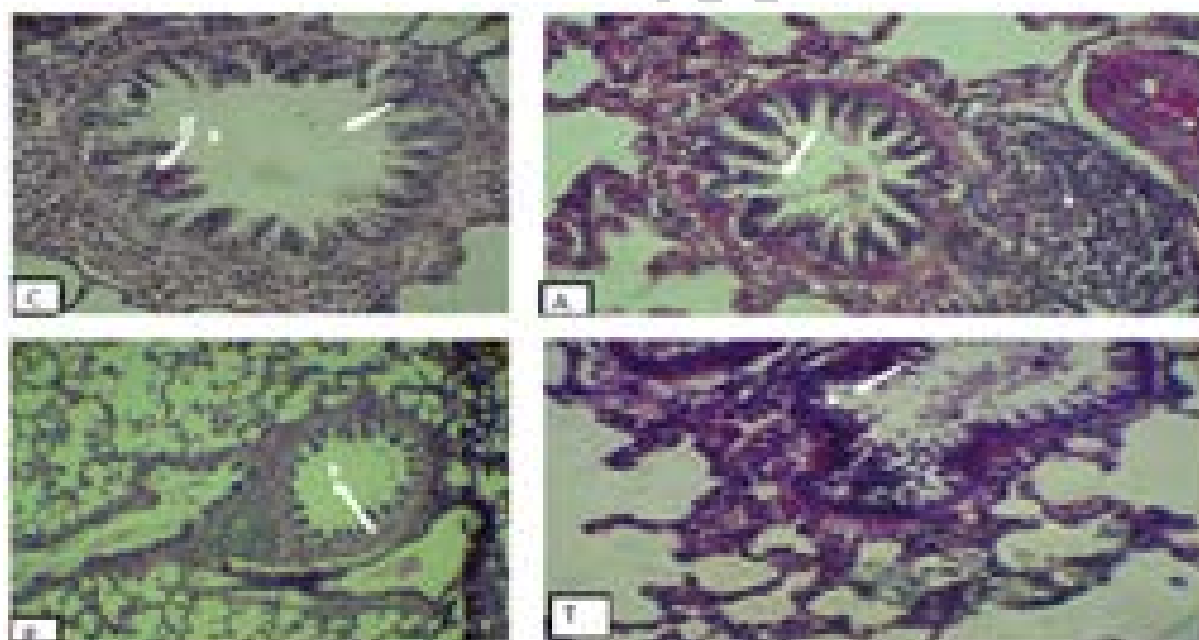


Figure 4. Cross section of bronchial in experimental groups with PAS staining, 100 \times : C: Normal control; A: Asthma group; P: *Plantago* group; T: Theophylline group; Lymphoid nodules (n); goblet cell (g); bronchiole (b). As shown in this figure, in the control group (b) bronchial was empty and without any secretion compounds, but a lot of goblet cells (g) with normal epithelium were observed. In the asthmatic group, bronchioles were filled with glycoprotein compounds and height of epithelium was increased. Furthermore, a few lymphatic nodules (n) around bronchioles were observed. In this group, most of goblet cells were emptied. In the theophylline group, height of epithelium and glycoprotein compounds was reduced, meanwhile some normal goblet cells were observed. In the *plantago* group, similar to control group, bronchial was empty and goblet cells with normal epithelium were observed.

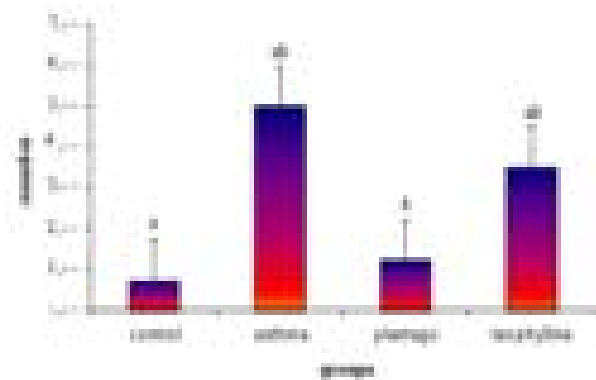


Figure 5. The mean number of mast cells in mm² in the experimental groups. Values are statistically significant at $p < 0.05$ in different characters.

As shown in this figure, the mean number of mast cells in mm² in the asthmatic group was significantly increased in comparison with the control and plantago groups ($p < 0.05$). In the theophylline group, the mean number of mast cells in mm² was significantly increased ($p < 0.05$) in comparison with the control and plantago groups, while the plantago group was similar to the control group ($p > 0.05$). Furthermore, there was no significant decrease in the theophylline group compared with the asthmatic group ($p > 0.05$).

Discussion

It is important that mouse models are valid and reflect clinical asthma as closely as possible. Animal models have been used to elucidate asthma and to identify and evaluate novel therapeutic targets.

Stimulating factors for asthma are related to the accumulation of inflammatory cells in airways (Makhlof *et al.*, 2006). It has been proved that airway eosinophils are increased in asthma (Zhou *et al.*, 2001). IL-17 may be involved in the infiltration of neutrophils into the lung tissue (Sergejeva *et al.*, 2005). Neutrophils secrete elastase, which is a neutrophil serine protease that causes degeneration of lung elastin. The production of reactive oxygen is activated and airway inflammation is increased (Khosrou *et al.*, 2006). IL-17 is one of the cytokines that may increase inflammation by attracting neutrophils to the peripheral tissues (Hellings *et al.*, 2003; Molet *et al.*, 2001).

Neutrophils secrete metalloproteinase (MMPs) which have destructive effects on tissue. Some

researchers have proved that as the number of mast cells in asthma is increased, the density of free radicals after immunological stimulation increases (Poli *et al.*, 2004). Furthermore, there is little or no recruitment of mast cells into the airway wall or epithelium (Boyce and Austen, 2005) which may reflect the paucity of mast cells in the airways of mice (Kumar and Foster, 2002). In the present study, it was observed that in the asthmatic group, the number of lymphoid and mast cells increased. Moreover, the glycoprotein compounds accumulate in airways and all of the goblet cells in bronchioles were emptied. In order to compensate for these changes, the thickness of the epithelium in the alveoli was increased and some large nodules around bronchioles were observed. Therefore, multiple centers of replete with blood in the connective tissue between alveoli and hemorrhage in some alveolar sacs were observed. Hemosiderin particles were scattered in alveoli, thus making the breathing difficult.

Theophylline has been a popular medication for asthma for over 50 years. It causes dilation of the smooth muscles and eliminates sudden obstruction (Sohrabi *et al.*, 2009). It inhibits phosphodiesterase enzyme, which is responsible for cAMP destruction. With an increase of cAMP, the respiratory tract is dilated and asthma symptoms usually go away (Boskabady *et al.*, 2002). Theophylline down-regulates the function of inflammatory and immune cells in vitro and in vivo in animals with airway inflammation (Scordamaglia *et al.*, 1988). In patients with allergic asthma, it attenuates the late-phase increase in airway obstruction and airway responsiveness to histamine and decreases allergen-induced migration of activated eosinophils into the bronchial mucosa (Sullivan *et al.*, 1994). The bronchoprotection may be effected by direct inhibition of smooth-muscle contraction. In contrast, attenuation of the early response to allergens or exercise by theophylline may involve inhibition of the release of leukotrienes from the airways,

attenuation of the effects of leukotriene D4 at its receptor, or blocking of adenosine-induced enhancement of mediator release from mast cells (Welton et al., 1980).

Sanati and colleagues in 2009 reported the effect of theophylline in patients with syndrome X (chest). Theophylline could reduce the chest pain with non-specific inhibitor adenosine receptors. Pour Abuli and colleagues in 2008 revealed that inhibition of adenosine receptors by theophylline caused the reduction of inflammatory edema, vascular permeability, and vasodilatation. In the present research, it was revealed that in the group treated with theophylline compared with the asthma group, the thickness of some alveolar epithelium was reduced and the accumulation of inflammatory cells and lymphoid nodules around the septum was smaller than the asthma group. Moreover, presence of glycoprotein compounds in airways was reduced, and the height of bronchial epithelium was recovered. However, size of mast cells and macrophages was increased.

Modern medical research is proving to uphold many of the historical uses of *plantain* (Mukhtar et al., 2008) especially as a wound healer and as a treatment for lung conditions such as bronchitis and asthma (Galvez et al., 2003). Medicinally, *plantain* is used for mucous membrane irritation associated with upper respiratory tract. Two Bulgarian clinical trials have suggested that *plantain* may be effective in the treatment of chronic bronchitis (Tilford, 1997). *Plantain* has been used medicinally for centuries. It was considered that historically it has been recommended as a treatment for just about everything, such as ulcers, ringworm, jaundice, epilepsy, liver obstructions, and hemorrhoids! *Plantain* was so commonly known that it is even found referenced in works by both Chaucer and Shakespeare (Tilford et al., 1998). Previous study demonstrated that *plantago lanceolata* in four weeks in Guinea pigs has sedative and anti-cough properties. (Boskabady et al.,

2006). The leaf of *plantago* prevents inflammation of the mouth (stomatitis) in chemotherapy (Pour Ismail et al., 2003).

P. major is one of the most abundant and widely distributed medicinal crops in the world. The active chemical constituents are aucubin (an anti-microbial agent), allantoin which stimulates cellular growth and tissue regeneration (Velasco-Lezama et al., 2006), and mucilage which reduces pain and discomfort (Duke et al., 2001). Together, these constituents are thought to give *plantain* mild anti-inflammatory, antimicrobial, antihemorrhagic, and expectorant actions. In this research, in the group treated with the extract of *plantago* due to allantoin constituents, goblet cells in bronchioles were recovered and regenerated. Furthermore, due to mucilage compounds in *plantago*, the rate of lymphoid cells and nodules were small and decreased. Moreover, the thickness of epithelium was decreased and improved. The bronchioles and air sacs were observed to be similar to the control group.

In summary, the results of this research revealed that *p. major* compared with theophylline, prevent histopathological changes of lung in asthmatic rats. The effect can be due to Tanen and Mucilage. Anti-inflammatory, analgesic, antioxidant, immunomodulating and anti-ulcerogenic activity of this plant has a protective effect on lung in asthmatic rats. Therefore, it is beneficial in the treatment of the inflammation of the upper part of respiratory system.

Acknowledgments

This research was supported by a grant from Research Council of Urmia University. The authors declare that they have no conflict of interest.

Conflict of interest

There is not conflict of interest in this study.

References

- Asthmatic airways and induces human bronchial fibroblasts to produce cytokines. *J Allergy Clin Immunol*, 108: 430-438.
- Bartlett NW, Walton RP, Edwards MR, Aniscenko J, Caramori G, Zhu J, Glanville N, Choy KJ, Jourdan P, Burnet J, et al. 2008. Mouse models of rhinovirus-induced disease and exacerbation of allergic airway inflammation. *Nat Med*, 14: 199-204.
- Boskabady M, Ouladi MR. 2002. Children's medication regimen Comparison of the effects bronchodilators. Mashhad University of Medical Sciences. 1:26-21.
- Boskabady MH, Rakhshandah H, Afiat M, Aelami Z, Amiri S. 2006. Anti tussive effect of *Plantago lanceolata* in guinea pigs. *Iran J Med Sci*, 31: 143-146.
- Boyce JA, Austen KF. 2005. No audible wheezing: nuggets and conundrums from mouse asthma models. *J Exp Med*, 201: 1869-1873.
- Duke James. 2001. Handbook of Edible Weeds. CRC Press. p.151. ISBN.
- Fatemil F, Allameh1 A, Khalafi H, Rezaei MB, Seyhoon M. 2010. The effect of essential oils and hydroalcoholic extract of caraway seed on oxidativestress parameters in rats suffering from acute lung inflammation before and after γ -irradiation. *Iran J Med Aromatic Plant*, 25: 44-49.
- Galvez M, Cordero MC, Cortes F, Ayus MY. 2003. Cytotoxic effect of *Plantago* spp. on cancerallins. *J Ethnopharmacol*, 88: 125-130.
- Green, James. 2000. The Herbal Medicine Maker's Handbook: A Home Manual. Chelsea Green Publishing, pp. 3: 14-315.
- Hellings PW, Kasran A, Liu Z, Vandekerckhove P, Wuyts A. 2003. Interleukin-17 Orchestrates the Granulocyte Influx into Airways after Allergen Inhalation in a Mouse Model of Allergic Asthma. *Am J Respir Cell Mol Biol*, 28: 42-50.
- Khosrou A, Sarvghadi F. 2006. The investigation of Hypogonadism and the level of the serum of free testosterone in chemical injures who suffer from asthma which is the result of sulfur demostard. *Military J Med Sci*, 4: 975-979.
- Kumar RK, Foster PS. 2002. Modeling allergic asthma in mice: pitfalls and opportunities. *Am J Respir Cell Mol Biol*, 27: 267-272.
- Makhlogh E, MohseniA, Bagheri B, Fatahian E. 2006. The investigation of the effect of theophylline on the contrast of nephropathy results from the angiography of corner vessels. *Med sci Mazandaran*, 16: 27-34.
- Mehrabian S, Majd A, Dana A. 2009 . Antimutagenic and anticarcinogenic effect of vegetative and generative parts of plantago major l. In langrood (gilan) and hesarak (karaj) areas. *Q J biol sci*, 1:23-31.
- Molet S, Hamid Q, Davoine F, Nutku E, Taha R, Pagé N. 2001. IL-17 is increased in asthmatic airways and induces human bronchial fibroblasts to produce cytokines. *J Allergy Clin Immunol*. 108: 430-438.
- Mukhtar M, Arshad M, Ahmad M, Pomerantz RJ, WigdahlB, Parveen Z. 2008. Antiviral potentials of medicinal plants .*Virus Res*, 131: 111-120.
- Poli G, Leonarduzzi G, Biasi F, et al. 2004. Oxidative stress and cell signaling. *Curr Med Chem*, 11: 1163-1182.
- Pour Ismail Z, Shouri BidgoliR, Zaragari E. 2009. The effect of the suspension the plantago's leaf in prevention of the inflammation of mouth which is the result of the chemotherapy. *J med sci Shahid Beheshti Univ*, 3: 175-179
- Pouraboli I, Hajizadeh S, Najafipour H, Khoshbaten A, Rasaei M. 2008. Does PGE2 mediate indomethacin and theophylline effects on joint diameter and vascular response to saphenous nerve stimulationin chronically inflamed rat knee joint. *Physiol Pharmacol*, 12: 68 - 75
- Rahimian M. 2002. The study of the effect of inspiration of the extract of Darmaneh plant on the health and spirometric of asthma sickness. *J med sci Yazd*, 10: 20-25
- Razavi M, Zahedi Y, Mahdavian Mehr H. 2009. The engineer of the seed of plantago. *Res publication food indust*, 2: 88-96.
- Samuelsen AB. 2000. The traditionaluses, chemical constituents and biological activities of *Plantago major* L. *Rev J Ethnopharmacol*, 71: 1-21.
- Sanati A, Sadegiyani H. 2009. Theophylline effects in patients with syndrome x. *J Med Sci Tehran*, 3: 20-23
- Scordamaglia A, Ciprandi G, Ruffoni S. 1988. Theophylline and the immune response: in vitro and in vivo effects. *Clin Immunol Immunopathol*, 48: 238-246.
- Sergejeva S, Ivanov S, Lotvall J, Lidn A. 2005. Interlukin-17 as a recruitment and survival factorfor airway macrophages in allergic airway inflammation. *Am J Respir Cell Mol Biol*, 33: 248-53.

Effects of *Plantago major* on asthma

- Sohrabi M, Alaedini A, Javanbakht M, Sarban M, Marandi P. 2009. The approach of exchanging and spectrophotometry to analyze Hemezman teophillin and gabaphizin in drug formulation. Appl chem publication, 9: 15-20.
- Sullivan P, Bekir S, Jaffar Z, Page C, Jeffery P, Costello J. 1994. Anti-inflammatory effects of low-dose oral theophylline in atopic asthma. Lancet.343:1006-1008.
- Tilford M, Gregory L. 1997. Edible and Medicinal Plants of the West . Mountain Press. p. 112.
- Tilford Gregory L and Gladstar Rosemary . 1998. From Earth to Herbalist Conscious Guide to Medicinal Plants. Mountain Press. p. 160.
- Velasco-Lezama R, Tapia Aguilar R, Roman-Ramos R, Vega-Avila E, Perez-Gutierrez Ma. 2006. Effect of *Plantago major* on cell proliferation in vitro .J Ethnopharmacol, 103: 36-42.
- Wagelie steffen AL, Kavanaugh AF, Wasserman IS. 2006 .Biologic Therapies for the Treatmentof Asthma. Clin Chest Med, 103: 36-42
- Welton AF and Simko BA. 1980. Regulatory role of adenosine in antigen-induced histamine release from the lung tissue of actively sensitized guinea pigs. Biochem Pharmacol, 29: 1085-1092.
- Zhou Y, McLane M, Levitt RC. 2001. Th2 cytokines and asthma. Interleukin-9 as a therapeutic target for asthma. Respir Res, 2: 80-84.