

Short-Communication

The effect of royal jelly and silver nanoparticles on liver and kidney inflammation

Hossein Pourmobini¹, Mohammad Kazemi Arababadi², Mohammad Reza Salahshoor³, Shiva Roshankhah³, Mohammad Mohsen Taghavi⁴, Zahra Taghipour⁵, Ahmad Shabanizadeh^{6,*}

¹Immunology of Infectious Diseases Research Center, Research Institute of Basic Medical Sciences, Rafsanjan University of Medical Sciences, Rafsanjan, Iran

²Department of Immunology, Faculty of Medicine, Immunology of Infectious Diseases Research Center, Research Institute of Basic Medical Sciences, Rafsanjan University of Medical Sciences, Rafsanjan, Iran

³Department of Anatomical Sciences, Medical School, Kermanshah University of Medical Sciences, Kermanshah, Iran

⁴Department of Anatomy, Faculty of Medicine, Social Determinants of Health Research center Rafsanjan University of Medical Sciences, Rafsanjan, Iran

⁵Department of Anatomy, Faculty of Medicine, Rafsanjan University of Medical Sciences, Rafsanjan, Iran

⁶Department of Anatomy, Faculty of Medicine, Immunology of Infectious Diseases Research Center, Research Institute of Basic Medical Sciences, Rafsanjan University of Medical Sciences, Rafsanjan, Iran

Article history:

Received: Sep 24, 2019

Received in revised form:

Aug 31, 2020

Accepted: Sep 05, 2020

Vol. 11, No. 3, May-Jun 2021,
218-223.

* Corresponding Author:

Tel: 09162734757

Fax: 034-31315003

shabani54@yahoo.com

Keywords:

Kidney

Liver

Nano-silver

Royal jelly

Abstract

Objective: Royal jelly (RJ) is a honey bee product for which, anti-inflammatory properties were shown *in vitro*. Nanoparticles, including nano-silver (NS), are plausible inflammation inducers that act by activation of immune cells and consequent production of pro-inflammatory cytokines. This project aimed to explore immunomodulatory effects of royal jelly and nano-silver on the kidney and liver.

Materials and Methods: In this project, 40 male rats were grouped as follows: 10 rats as controls, 10 rats treated with RJ; 10 rats treated with both NS and RJ and 10 rats treated with NS. Liver and kidney interleukin (IL)-1 β , -2, -6, and -33 levels were determined using commercial ELISA kits.

Results: RJ reduced kidney IL-6 levels in comparison to control and NS--RJ groups. RJ and NS reduced kidney and liver IL-1 β levels. Kidney IL-33 levels were decreased in the RJ and nano-silver groups in comparison to the NS--RJ group.

Conclusion: Based on this study, it may be concluded that RJ together with NS can play anti-inflammatory roles and may affect the function of immune cells.

Please cite this paper as:

Pourmobini H, Kazemi-Arababadi, Salahshoor MR, Roshankhah SH, Taghavi MM, Taghipour Z, Shabanizadeh A. The effect of royal jelly and silver nanoparticles on inflammation of the liver and kidney inflammation. Avicenna J Phytomed, 2021; 11(3): 218-223.

Introduction

Royal jelly (RJ), as a viscous macromolecule, is produced by worker bees

(*Apis mellifera*), and is an essential food for queen of bees (Kamakura, 2011). Nowadays, RJ is widely used in production of several materials, such as dietary

supplements and cosmetics (Ramadan and Al-Ghamdi, 2012). It has been reported that RJ has several bioactive properties, including anti-inflammatory (Ramadan and Al-Ghamdi, 2012), antiviral (El-Gayar et al., 2016), antibacterial (Nascimento et al., 2015), immunomodulatory (Pavel et al., 2011), and antioxidant (Delkhoshe-Kasmaie et al., 2014) activities. Thus, it was hypothesized that this product may be used as a protective material to decrease side effects of molecules like inflammation. Nano-particles are very small materials, which increase the effects of the drugs and chemical drugs increasing their interaction with their target molecules (Song and Kim, 2009). Nano-silver (NS) is a famous molecule that is used routinely with several drugs to increase their effectiveness (Sharma et al., 2009). However, it was documented that NS is associated with some side effects, including oxidation of DNA (Klingelfus et al., 2019), and cell cytotoxicity (Nakkala et al., 2017), and is harmful to the cardiovascular system, skin, gastrointestinal tract, respiratory tract and immune cells (Wang et al., 2016). Therefore, it was hypothesized that the use of some tissue protective materials, like RJ, with NS, may be useful to reduce the side effects of the nano-particle. Thus, this project was designed to explore the protective effects of RJ on the inflammatory properties of NS in rats. Due to the fact that the liver and kidney are two important tissues for detoxification, the kidney and liver levels of interleukin-1 (IL-1), -2, -33 and -6, as the pro-inflammatory cytokines, were determined in rats treated with NS, RJ and a combination of NS and RJ in this project.

Materials and Methods

Nano-silver particle and royal jelly

In this project, the NS solution and RJ were obtained from Nanophishgaman Company, Mashhad, Iran and Pars Asal Company, Shiraz, Iran, respectively. The NS particles were at the concentration of 8000 ppm, less than 100 nm in size and of

99.98% purity, which was approved by the Company. RJ was prepared by solving of 20 g of RJ in 1 l of sterilized double-distilled water, as a previous investigation (Silici et al., 2009).

Animals

With respect to the ethics in animal experiments, monitoring nutritional status, standard light, and temperature and humidity conditions, 40 male Wistar rats, weighing 200-250 g, were divided into four groups randomly. Accordingly, 10 rats were considered controls, which did not receive any of the treatment materials; 10 rats were treated with 100 mg/kg RJ; 10 rats were treated with 30 mg/kg of NS and 100 mg/kg of RJ and 10 rats received 30 mg/kg NS. The NS particle solution, NS-RJ solution and RJ solution were daily prepared and given to the animals through gavage for 28 days. After 28 days of treatment with NS, NS-RJ, and RJ, the animals were killed by cervical amputation, under Ethical and standard conditions and their liver and kidneys were extracted under sterile conditions and transferred to the laboratory for cytokine assay. This project was granted by Rafsanjan University of Medical Sciences and approved by the related Ethical Committee (Ethical code: IR.RUMS.REC.1397.179).

Cytokine assay

The suspension of kidney and liver tissues were prepared in phosphate buffered saline (PBS) buffer and then, the kidney and liver levels of IL-1 β , IL-2, IL-6 and IL-33 were measured using Karmania Pars Gene ELISA kits (Kerman, Iran) using the kits' protocol.

Statistical analysis

The raw data were analyzed regarding their normal distribution and due to their normality, parametric tests were used to analyze them. Accordingly, the kidney and liver levels of IL-1 β , IL-2, IL-6 and IL-33 among the groups were analyzed using One-Way ANOVA test by SPSS version

18. A p value less than 0.05 was considered significant.

Results

The results demonstrated that IL-1 β was significantly higher in the kidney of the NS-RJ group than the NS (p=0.047) and RJ (p=0.002) groups and in the liver of the control group compared to the NS (p=0.025) and RJ (p=0.010) groups. Kidney levels of IL-1 β in the controls were not different from other groups, including NS-RJ (p=0.266), NS (p=0.995) and RJ (p=0.639) groups (Figure 1).

Kidney (p>0.1) and liver (p>0.1) levels of IL-2 were not different among the groups (Figure2). Kidney levels of IL-6 were significantly higher in the control (p=0.046) and NS-RJ (p=0.002) groups when compared to the RJ group. However, the liver levels of IL-6 did not vary among the groups (p>0.1) (Figure 3).

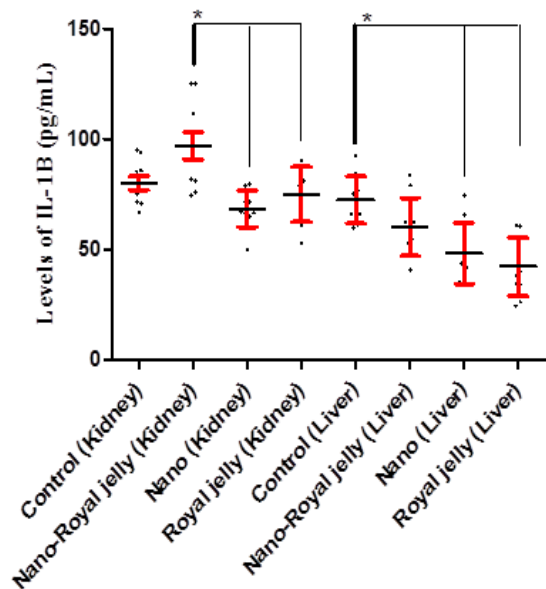


Figure 1. Kidney and liver levels of IL-1 β in the control, and NS, NS-RJ, and RJ treated rats. The Figure shows that IL-1 β was significantly higher in the kidney of the NS-RJ group compared to the NS (p=0.047) and RJ (p=0.002) groups and in the liver of the control group compared to the NS (p=0.025) and RJ (p=0.010) groups. *: p< 0.05

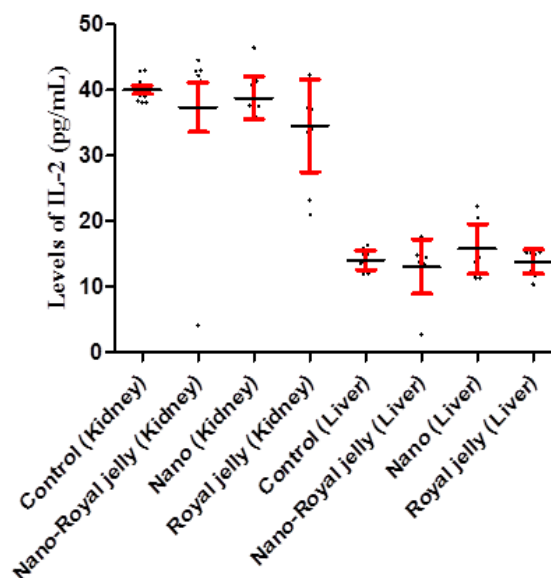


Figure 2. Kidney and liver levels of IL-2 in the control, and NS, NS-RJ, and RJ treated rats. Kidney (p>0.1) and liver (p>0.1) levels of IL-2 were not different among the groups.

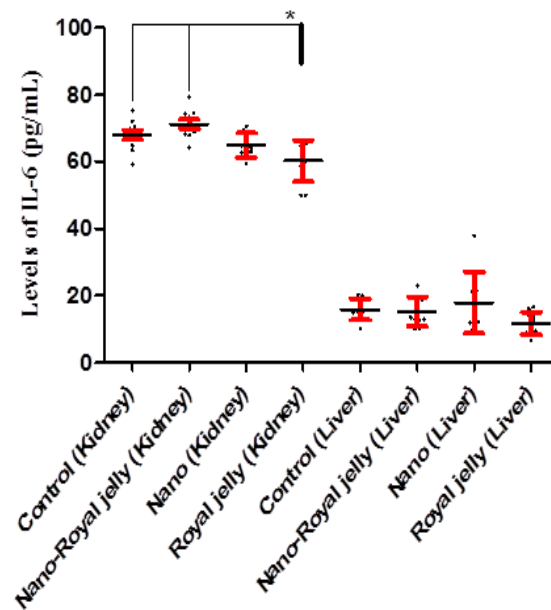


Figure 3. Kidney and liver levels of IL-6 in the control, and NS, NS-RJ, and RJ treated rats. Kidney levels of IL-6 were significantly higher in the control (p=0.046) and NS-RJ (p=0.002) groups compared to the RJ group. *: p<0.05

Kidney levels of IL-33 were higher in the NS-RJ group compared to the NS (p=0.006) and RJ (p<0.001) groups. But the liver levels of IL-33 did not vary among the groups (p>0.1) (Figure 4). As it is illustrated in Figures, kidney and liver

levels of IL-1 β , IL-2, IL-6 and IL-33 were significantly lower in the liver than kidney tissues (Table 1).

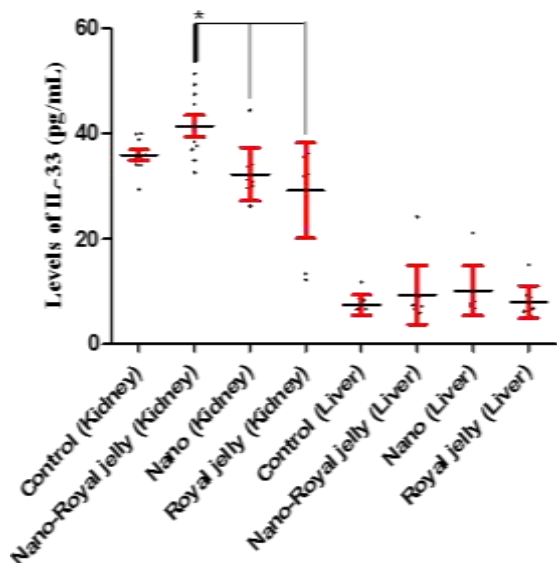


Figure 4. Kidney and liver levels of IL-33 in the control, and NS, NS-RJ, and RJ treated rats. Kidney levels of IL-33 were higher in the NS-RJ group compared to the NS ($p=0.006$) and RJ ($p<0.001$) groups.
*: $p<0.05$; **: $p<0.01$; ***: $p<0.001$

Discussion

The cytotoxic effects of NS were reported previously (Sharma et al., 2009). Therefore, it is plausible that NS suppresses the production of pro-inflammatory cytokines in the tissues, which are important to tissue repair and

defense against microbes. Our results demonstrated that, although NS and NS-RJ were unable to alter the expression of IL-6 in comparison to the controls, RJ significantly decreased the cytokine in the kidney. Additionally, RJ significantly decreased kidney and liver levels of IL-1 β and kidney levels of IL-33. Therefore, it appears that RJ has immunomodulatory effects in both the kidney and liver. IL-6 and IL-1 β are important molecules that participate in the innate immunity-related pro-inflammatory diseases (Rahmanzadeh-Shahi et al., 2018; Borthwick, 2016). Additionally, the roles played by IL-33 in the pro-inflammatory disorders and deterioration of cancers were previously reported (Tong et al., 2016). Thus, it appears that RJ may be considered a future immunomodulatory agent. Although NS had anti-inflammatory effects in the current study probably due to its cytotoxicity leading to decreased functions of the immune cells, its combination with RJ neutralized immune-modulatory effects of RJ and resulted in up-regulation of IL-1 β and IL-33 in the kidney and liver tissues, respectively. Due to the fact that IL-1 β is the cytokine which needs to be activated by inflammasomes (Sepehri et al., 2017), while IL-6 is a pre-activated cytokine, it may be hypothesized that NS and RJ are effective on the inflammations. However, it needs to be explored by further investigations.

Table 1. Liver and kidney levels of IL-1 β , IL-2, IL-6 and IL-33 among the evaluated groups.

Cytokine	Kidney				Liver			
	Control	NS-RJ((Nanosilver- Royal jelly)	NS (Nanosilver)	RJ (RoyalJelly)	Control	NS-RJ	NS	RJ
IL-1 β	80.19 \pm 3.06	97.17 \pm 6.11	74.75 \pm 4.42	67.52 \pm 7.08	72.44 \pm 3.36	60.29 \pm 4.16	48.37 \pm 4.34	46.20 \pm 6.27
IL-2	40.03 \pm .59	37.37 \pm 3.77	38.82 \pm 1.04	34.55 \pm 2.21	14.08 \pm .46	13.09 \pm 1.30	15.77 \pm 1.20	13.87 \pm .57
IL-6	67.99 \pm 1.45	71.18 \pm 1.36	64.85 \pm 1.14	58.33 \pm 4.42	15.90 \pm 1.00	15.23 \pm 1.37	17.89 \pm 2.90	11.76 \pm 076
IL-33	35.88 \pm 1.01	41.38 \pm 2.05	32.22 \pm 1.60	29.10 \pm 2.87	7.39 \pm .59	9.27 \pm 1.76	10.09 \pm 1.49	7.97 \pm .97

Shin and colleagues showed that NS has potential cytotoxic effects on the peripheral blood mononuclear cells (PBMCs) and, hence are associated with decreased production of TNF- α by the cells (Shin et al., 2007). However, it has been demonstrated that high concentrations of NS are responsible factor to induce liver cell swelling and vacuolar degeneration (Nakkala et al., 2018). Chronic exposure to NS is also another reason for neuroinflammatory effects of NS (Locht et al., 2011). Therefore, it may be proposed that higher concentrations of NS and its chronic exposure to the tissues may have different results in rats which needs to explore by further investigations. Moreover, several investigators proved the protective roles played by RJ in the tissues, such as the testis (Ahmed et al., 2018), skeletal muscles (Metwally Ibrahim and Kosba, 2018), adipose tissue (Metwally Ibrahim and Kosba, 2018) and macrophages (You et al., 2018). Thus, it appears that the roles of RJ is dependent on other pro-inflammatory cytokines. As it is presented in Figure 1, the liver cytokine levels were not changed in the groups except IL-1 β , which was decreased in the RJ and NS groups. Due to the fact that IL-2 is the main inducer of T lymphocyte clonal expansion (Au-Yeung et al., 2017), and considering to our results, it appears that neither NS-RJ component nor RJ or NS alone were able to affect adaptive immunity clonal expansion in both the kidney and liver.

According to this study, it may be imagined that RJ and NS together can play anti-inflammatory roles and may affect the function of immune cells. Therefore, using the RJ with NS may modulate NS suppressive effects on productions of key pro-inflammatory cytokines and may be considered for future studies. However, the function of RJ and its combination with NS on the immune cells needs to be explored by more investigations.

Acknowledgment

The study was supported by Rafsanjan University of Medical Sciences.

Conflicts of interest

The authors have declared that there is no conflict of interest.

References

- Ahmed MM, El-Shazly SA, Alkafafy ME, Mohamed AA, Mousa AA. 2018. Protective potential of royal jelly against cadmium-induced infertility in male rats. *Andrologia*, 50: e12996.
- Au-Yeung BB, Smith GA, Mueller JL, Heyn CS, Jaszczak RG, Weiss A, Zikherman J. 2017. IL-2 Modulates the TCR Signaling Threshold for CD8 but Not CD4 T Cell Proliferation on a Single-Cell Level. *J Immunol*, 198: 2445-2456.
- Borthwick LA. 2016. The IL-1 cytokine family and its role in inflammation and fibrosis in the lung. *Semin Immunopathol*, 38: 517-534.
- Delkhoshe-Kasmaie F, Malekinejad H, Khoramjouy M, Rezaei-Golmisheh A & Janbaze-Acyabar H. 2014. Royal jelly protects from taxol-induced testicular damages via improvement of antioxidant status and up-regulation of E2f1. *Syst Biol Reprod Med*, 60: 80-88.
- El-Gayar MH, Aboshanab KM, Aboulwafa M M, Hassouna NA. 2016. Antivirulence and wound healing effects of royal jelly and garlic extract for the control of MRSA skin infections. *Wound Med*, 13: 18-27.
- Kamakura M. 2011. Royalactin induces queen differentiation in honeybees. *Nature*, 473: 478-483.
- Klingelfus T, Disner G R, Voigt CL, Alle LF, Cestari MM, Leme DM. 2019. Nanomaterials induce DNA-protein crosslink and DNA oxidation: A mechanistic study with RTG-2 fish cell line and Comet assay modifications. *Chemosphere*, 215: 703-709.
- Locht LJ, Pedersen MO, Markholt S, Bibby B M, Larsen A, Penkowa M, Stoltenberg M Rungby J. 2011. Metallic silver fragments cause massive tissue loss in the mouse brain. *Basic Clin Pharmacol Toxicol*, 109: 1-10.
- Metwally Ibrahim SL, Kosba AA. 2018. Royal jelly supplementation reduces skeletal

- muscle lipotoxicity and insulin resistance in aged obese rats. *Pathophysiology*, 25: 307-315.
- Nakkala JR, Mata R, Raja K, Khub Chandra V, Sadras SR. 2018. Green synthesized silver nanoparticles: Catalytic dye degradation, in vitro anticancer activity and in vivo toxicity in rats. *Mater Sci Eng C Mater Biol Appl*, 91: 372-381.
- Nakkala JR, Mata R, Sadras SR. 2017. Green synthesized nano silver: Synthesis, physicochemical profiling, antibacterial, anticancer activities and biological in vivo toxicity. *J Colloid Interface Sci*, 499: 33-45.
- Nascimento AP, Moraes L. A, Ferreira NU, Moreno Gde P, Uahib FG, Barizon EA, Berretta AA. 2015. The Lyophilization Process Maintains the Chemical and Biological Characteristics of Royal Jelly. *Evid Based Complement Alternat Med*, 2015: 825068.
- Pavel CI, Mărghitaş L A, Bobiş O, Dezmirean DS, Şapcaliu A, Radoi I, Mădaş MN. 2011. Biological activities of royal jelly-review. *Sci Papers Anim Sci Biotech*, 44: 108-118.
- Rahmanzadeh-Shahi S, Golshiri-Isfahani A, Fathollahi MS, Rezayati M, Bahramabadi R, Afrooz M, Asadikaram G., Kennedy D, Arababadi MK. 2018. Interleukin-6 and Tumor Growth Factor-beta are Risk Factors for Idiopathic Epistaxis. *Lab Med*, 49: 329-341.
- Ramadan MF, Al-Ghamdi A. 2012. Bioactive compounds and health-promoting properties of royal jelly: A review. *J Funct Food*, 4: 39-52.
- Sepehri Z, Kiani Z, Afshari M, Kohan F, Dalvand A, Ghavami S. 2017. Inflammasomes and type 2 diabetes: An updated systematic review. *Immunol Lett*, 192: 97-103.
- Sharma VK, Yngard RA, Lin Y. 2009. Silver nanoparticles: green synthesis and their antimicrobial activities. *Adv Coll Interface Sci*, 145: 83-96.
- Shin SH, Ye MK, Kim HS, Kang HS. 2007. The effects of nano-silver on the proliferation and cytokine expression by peripheral blood mononuclear cells. *Int Immunopharmacol*, 7: 1813-8.
- Silici S, Ekmekcioglu O, Eraslan G, Demirtas A. 2009. Antioxidative effect of royal jelly in cisplatin-induced testes damage. *Urology*, 74: 545-51.
- Song JY, Kim BS. 2009. Rapid biological synthesis of silver nanoparticles using plant leaf extracts. *Bioprocess Biosystem Engineer*, 32: 79.
- Tong X, Barbour M, Hou K, Gao C, Cao S, Zheng J, Zhao Y, Mu R, Jiang HR. 2016. Interleukin-33 predicts poor prognosis and promotes ovarian cancer cell growth and metastasis through regulating ERK and JNK signaling pathways. *Mol Oncol*, 10: 113-25.
- Wang JJ, Xue YY, Tang M. 2016. [Antimicrobial applications and toxicity of nano-silver in the medical field]. *Zhonghua Shao Shang Za Zhi*, 32: 631-634.
- You MM, Chen YF, Pan Y M, Liu YC, Tu J, Wang K, Hu FL. 2018. Royal Jelly Attenuates LPS-Induced Inflammation in BV-2 Microglial Cells through Modulating NF-kappaB and p38/JNK Signaling Pathways. *Mediators Inflamm*, 2018: 7834381.