

Pathological lesions observed in chickens pre-infected with LP H7N1 A/CK/Italy/1279/99 avian influenza and challenged with homologous HP H7N1 A/ostrich/Italy/984/00

Nili, H.^{1*}; Essen, S.²; Nunez, A.³;
Banks, J.² and Brown, I. H.²

¹Department of Avian Medicine, School of Veterinary Medicine, Shiraz University, Shiraz, Iran;

²Department of Avian Virology, Veterinary Laboratory Agency, Weybridge, Surrey, KT15, 3NB, UK;

³Department of Pathology, Veterinary Laboratory Agency, Weybridge, Surrey, KT15, 3NB, UK

*Correspondence: H. Nili, Department of Avian Medicine, School of Veterinary Medicine, Shiraz University, Shiraz, Iran. nili@shirazu.ac.ir

(Received 12 Sept 2007; revised version 3 Feb 2008; accepted 4 Mar 2008)

Summary

Most highly pathogenic avian influenza viruses (AIV) emerge after field passage of non-pathogenic AIVs in birds. The outbreak of low-pathogenic H7N1 avian influenza virus in Italy during 1999-2000 followed by outbreak of highly pathogenic H7N1 avian influenza virus is one example in this regard. This experiment has been designed to investigate the effect of pre-infection of birds with LPAI on subsequent challenge with HPAI virus from the same outbreak. Chickens were inoculated intranasally with LP H7N1 A/CK/Italy/1279/99 avian influenza virus at 3 weeks of age and two groups of 10 birds were challenged at 18 and 24 weeks of age with homologous HP H7N1 A/ostrich/Italy/984/00 virus from the same outbreak. The overall mortality of birds was 60%; pre-infected challenged birds died 4-17 days post challenge (PC), while naive birds died 2 days PC. Pre-infected birds showed peritonitis, salpingitis and oophoritis in necropsy and histopathology showed very severe necrosis of the spleen, pancreas, moderate to severe necrosis of the liver and inconsistent degeneration and inflammation of the lung. Necropsy of the control bird showed petechial haemorrhage on the heart, caecal tonsils and the tracheal mucosa.

Key words: LP H7N1, HP H7N1, Pathology, Pre immunization, Avian

Introduction

Avian influenza (AI) is a viral infection of bird with variable clinical and pathological manifestations. The agent belongs to type A orthomyxoviruses and currently there are 16 haemagglutinin (H1-16) and 9 neuraminidase (N1-9) documented subtypes (Fouchier *et al.*, 2005). The severity of clinical signs and pathological lesions caused by the virus vary considerably in different organs. These depend on the pathogenic nature of the virus, adaptation of the virus to corresponding host of origin, environmental stressors, immune status of the bird, route of inoculation and age of the host (Brugh and Beard, 1986; Swayne *et al.*, 1994). Based on virulence for chickens, using an intravenous pathogenicity test, AI viruses are classified

into two pathotypes, low-pathogenic (LP) and high-pathogenic (HP) viruses. Highly virulent viruses are able to cause severe acute HPAI in chickens, turkeys and other gallinaceous birds and have generally been associated with the H5 and H7 subtypes (Alexander, 2000). Molecular genetic and epidemiological evidence suggest that most HP AIVs emerge in nature after field passage of non-pathogenic AIVs in a galliformes host and that they resulted from specific genomic mutations that altered the haemagglutinin surface glycoprotein (Garcia *et al.*, 1996). This phenomenon of pathogenicity shifts from low to high has been reproduced in the laboratory with *in vivo*, *in vitro* and *in ovo* modeling systems (Brugh, 1988; Brugh and Perdue, 1991). One of the recent examples of this phenomenon happened in Italy with

catastrophic consequences on poultry industry. During 1999-2000, Italy experienced an epidemic of highly pathogenic avian influenza virus H7N1. Various species of Anseriformes and Galinaformes were reported to be infected (Capua and Mutinelli, 2001). The outbreak started with low-pathogenic avian influenza virus (LPAI) and followed by high-pathogenic avian influenza (HPAI) resulted in death or culling over 13 million birds. In this study we investigated the effect of pre-infection of SPF chicken with LP H7N1 Italian virus 1279 (LPAI, CHO-ve) on the subsequent infection with HP antigenically homologous virus challenge from the same outbreak.

Materials and Methods

Birds

Twenty-four SPF White Leghorn chicken were individually wing-tagged and inoculated by the intranasal route with a viral dose of 10^6 EID₅₀ of LP H7N1 A/CK/Italy/1279/99 avian influenza virus at three weeks of age. At 18 and 24 weeks of age, 10 pre-immunized birds and two control birds were challenged with 10^6 EID₅₀ of HP H7N1 A/ostrich/Italy/984/00 Italian virus from the same outbreak. Buccal and cloacal swabs were taken at 24-h intervals from birds. Seven dead birds were subjected to necropsy (one from control and three from each of 18- and 24-week-old groups) and gross lesions were recorded. M gene real time PCR was used for evaluation of viral shedding.

Histopathology

Tissue samples from lung, trachea, liver, spleen, pancreas, oviduct and ovary were fixed in 10% neutral buffer formaldehyde and were routinely processed and embedded in paraffin wax. Five to seven micrometer sections were cut and stained with haematoxylin and eosin and were studied under light microscope. All experimental studies with viable virus were performed in certified biosafety level 3 facilities.

Results

All challenged birds became infected

and shed the virus. The overall mortality was 60% (6/10 in both 18 and 24 weeks of age birds). Control bird died 48 h post challenge (PC), and pre-immunized birds died 4 days PC, one bird from 24-week-old group survived 17 days PC and shed the virus intermittently from buccal cavity for 2-12 days and from cloaca for 5-13 days PC. This bird developed chronic salpingitis (Fig. 1).

Gross pathology

Dead birds from 18 and 24 weeks pre-immunized challenged groups showed dark thigh and pectoral muscles, excessive mucosal secretion from the trachea, air sacculitis (n = 6), peritonitis (n = 6), salpingitis (n = 2) (Fig. 1) and oophoritis (n = 2). The abdominal air sacs were cloudy and hyperaemic. In one of the birds from 24-week-old group, there were about 200 ml thick creamy exudates in peritoneal cavity and gelatinous exudates inside the oviduct; also there was adhesion between ovarian follicles. The control bird, showed excess respiratory secretion, oedema of the lung, renomegaly and petechial haemorrhage on the caecal tonsils, isthmus between proventriculus and gizzard and under the koilin layer of the gizzard (Fig. 2), cardiac fat and tracheal mucosa.

As indicated in Table 1, the most common postmortem finding has been peritonitis and inflammation of visceral organs. In histopathology, necrosis of the pancreas, spleen and liver and inflammation of the oviduct and ovary were the most consistent findings. In all birds, the reproductive system was functional and there were several large yolky follicles on the ovary. But in one of the birds from 24 weeks group which survived 17 days PC, the oviduct showed chronic salpingitis and was atrophied, there were thick inflammatory exudates inside the magnum, the ovary was functional and there were 2 medium-sized yolky follicles on the ovary (Fig. 1). This bird shed the virus from buccal cavity for 2-12 DPI and from cloaca for 5-13 DPI intermittently.

Histopathology

The results of gross and histopathological study are summarized in

Table 1: Results of gross and histopathology of SPF chicken inoculated with LP A/CK/Italy/1279/99 avian influenza at 3 weeks of age and challenged at 18 and 24 weeks post inoculation with HP H7N1 A/ostrich/Italy/984/00 virus

Wks PI	Bird number	Gross pathology	Histopathology
18	144	- Peritonitis (++++) - Enlarged spleen, with pin point hem (++) - Pin point hem between giz and provent (+++) - Liver 2 necrotic foci (size 2-3 mm)(+)	- Lung, multifocal necrosis (++) - Pancreatic degeneration (+) - Kidney, multifocal necrosis (+++) - Spleen, necrosis (+++++) - Trachea, heterophil infiltration and necrosis (+++) - Liver, necrosis (++) - Proventriculus (-) - Oviduct (-) - Ovary (-)
	168	- Peritonitis (+++)	- Lung (-) - Pancreatic necrosis (+++++) - Spleen, multifocal necrosis (++) - Liver hyperaemia and necrosis (++) - Chronic inflammation of peritoneal surface - Kidney (-) - Caecal tonsils (++)
	No number	Peritonitis (+++)	Not done
	Control	- Excess of mucoide respiratory secretion on tracheal mucosa (++) - Petechial haemorrhage on the cardiac fat junction between giz and the provent (+++) - Haemorrhage on tracheal mucosa (++) - Oedema of the lung (++) - Renomegaly (+++) - C. tonsil haemorrhage (++)	- Lung, consolidation and haemorrhage in bronchi (+++) - Pancreas, slight degeneration (+) - Testes, necrosis (+++) - Liver, necrosis (++) - Spleen, necrosis (++) - Kidney, haemorrhage between tubules (+) - Trachea, focal necrosis (++) - Trach. bifurcation, hyperaemia (+) - Proventriculus, haemorrhage (++)
24	132	- Oophoritis and air sacculitis (++)	- Lung (-) - Pancreas (-) - Chronic inflammation of peritoneal surface (++) - Liver, necrosis (+++) - Trachea (-) - Caecal tonsils (-) - Ovary (++)
	135	- Chronic salpingitis	- Lung, very severe oedema, rich in protein (++++) - Pancreas, chronic inflammation on serosal surface (++) - Chronic peritonitis (++) - Liver, degeneration (+) - Trachea, hyperaemia (+) - Spleen, heterophil infiltration and necrosis (++) - Ovary, hyperaemia (++) - Oviduct, chronic salpingitis (+++) - Caecal tonsils (+)
	158	- Peritonitis, air sacculitis, oophoritis and acute salpingitis (++++)	- Lung (-) - Pancreatic necrosis (++++/+) - Salpingitis (+++) - Liver, necrosis (++) - Spleen, necrosis and capsule inflammation (+++) - Kidney, necrosis and haemorrhage (++) - Proventriculus (-) - Ovary, oophoritis (++) - Oviduct, salpingitis (++++)

(-) no lesion, (+) slight, (++) moderate, (+++) severe, (+++++) very severe and (+++++) extensive

Table 1. All immunized challenged birds showed peritonitis and air sacculitis.

Lesions of the pancreas, spleen and liver, salpingitis and oophoritis were the most consistent histopathological findings. One of the birds from 18-week-old group showed acute lung necrosis (Fig. 3). In one of the birds from the 24 weeks group which

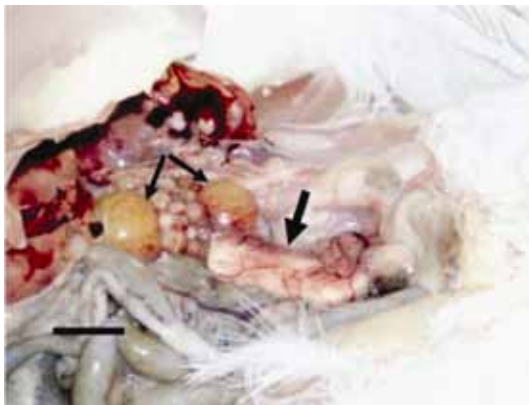


Fig. 1: A view of reproductive and visceral organs of a bird from 24 weeks group (wing tag No = 135), showing salpingitis, this bird shed the virus from buccal cavity for 2-12 DPI and from cloaca for 5-13 DPI intermittently, survived 17 days PI. There are two large yolky follicles (thin arrows) on the ovary and several medium-sized follicles at different stages of growth. The oviduct is atrophied and the magnum is occupied with a thick inflammatory exudates between 2 × 8 cm (thick arrow), (Scale bar = 2 cm)

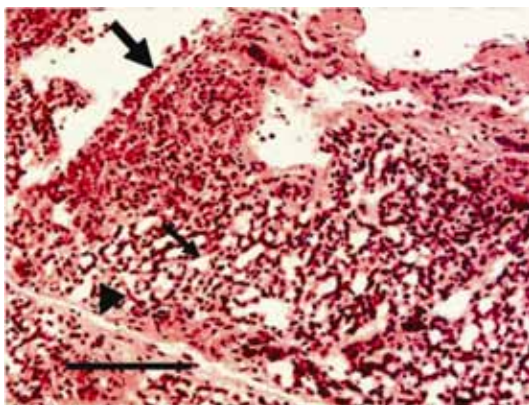


Fig. 3: Lung section of SPF chicken from 18-week-old group, showing acute lung necrosis (thick arrow), the rest of the lung tissue such as air capillaries (thin arrow) and the interparabronchial septa (arrow head) were normal. This bird shed the virus from buccal cavity for 1-3 DPI and from cloaca for 2-3 DPI and died 4 DPI, (H&E)

survived 17 days PC, the lung showed very severe oedema which was very rich in protein and affected air capillaries, interparabronchial septa and around blood vessels (Fig. 4). Acute multifocal necrosis was observed in the tubules of the kidney in the group of 18-week-old birds (Fig. 5). The bird with thick creamy exudates in

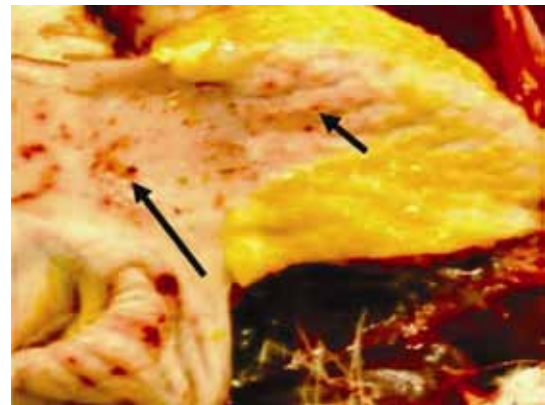


Fig. 2: The proventriculus and gizzard from a control bird, died 48 h PI, showing petechial haemorrhage on the papilla of proventricular glands (short arrow) and under the koilin layer of the gizzard (long arrow)

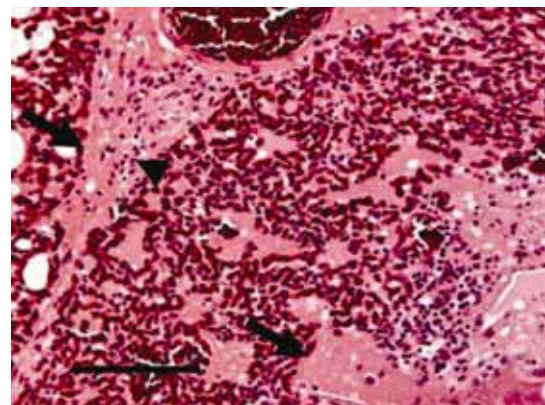


Fig. 4: Lung section of a bird from 24-week-old group, survived 17 days PI, showing moderate hyperaemia and very severe oedema of highly eosinophilic fluid in the interparabronchial septa, around blood vessels and inside air capillaries (arrows), there is some infiltration of inflammatory cells as well (arrow head). This bird shed virus intermittently from buccal cavity for 2-12 and from cloaca for 5-13 DPI, (H&E, Scales = 100 µm)

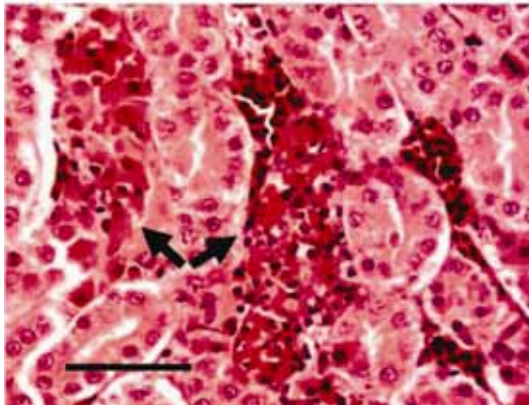


Fig. 5: Kidney section of SPF chicken (N = 144) from 18-week-old group, died 4 DPI, showing acute multifocal tubular necrosis of the kidney (arrows). This bird showed peritonitis at necropsy and extensive necrosis of the spleen in histology, (H&E, Scale = 50 μ m)

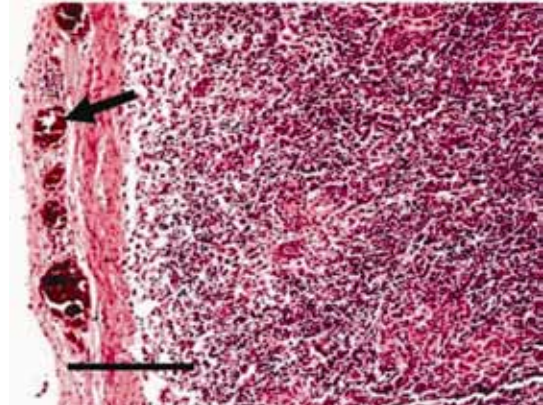


Fig. 6: Spleen section of a bird from 24-week-old group, showing necrosis in the parenchyma and very severe inflammation on the serosal surface of the spleen capsule (arrow). The peritoneal cavity of this bird contained about 200 ml mucoid whitish creamy exudates. There was adhesion of peritoneal organs as well, (H&E, Scale = 200 μ m)

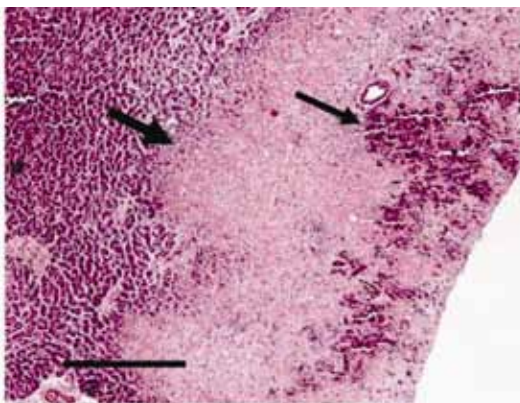


Fig. 7: Pancreas from the same bird in Fig. 2, showing very severe diffuse peripheral necrosis (thick arrow) and hemorrhage in necrotic tissue (thin arrow), (H&E, Scale = 500 μ m)

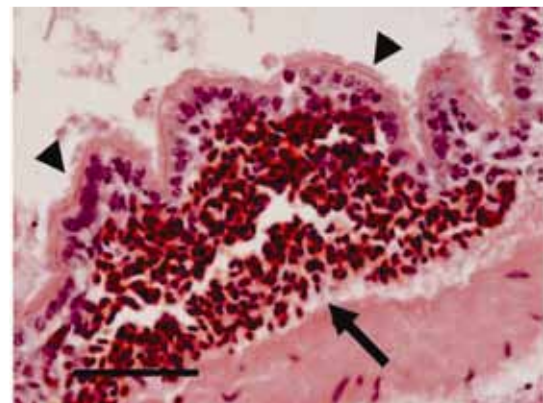


Fig. 8: Secondary bronchial epithelium from a control bird, showing severe focal haemorrhage under the epithelial cells (arrow), the cilia is still intact (arrow heads), (H&E, Scale = 50 μ m). Very severe spleen necrosis were observed in both groups

peritoneal cavity showed inflammation on the serosal surface of the spleen capsule and necrosis of the parenchyma of the spleen (Fig. 6). The most frequent histopathological finding was necrosis of the pancreas with variable severity which affected both endocrine and exocrine parts. Very severe diffuse pancreatic necrosis was observed in one bird from 18 and one from 24-week-old groups (Fig. 7). There was some haemorrhage in necrotic tissues. In a bird from the control group, the lung showed partial consolidation and submucosal haemorrhage in secondary bronchi (Fig. 8).

In some of the organs such as blood vessels of the kidney and lung some yolk globule particles could be seen.

Discussion

The fact that 60% of pre-immunized birds from both 18- and 24-week-old died almost within 4 days PC shows that the immunity level produced by initial inoculation with homologous LP H7N1 AIV has not been high enough to prevent mortality among these birds. Mortality of control birds during 48 h shows the

pathogenic nature of H7N1 A/ostrich/Italy/984/00 isolated from Italian outbreak. One of the most consistent necropsy findings in birds died due to HP AIV is the development of petechial haemorrhage on serosal surface, which was observed in the control bird. However in peracute cases of HP AIV infections, no lesion has been reported (Swayne and Halvorson, 2003). Development of purulent inflammatory lesions in the peritoneal membrane, air sacs and reproductive system show possible interruption of non-specific immune system, facilitating infection of air sacs, peritoneum and reproductive system. Distribution and severity of lesions in both groups which were challenged at 18 and 24 weeks post immunization with LP H7N1 A/CK/Italy/1279/99 avian influenza virus were almost the same.

Both 18 and 24 weeks groups showed a combination of necrosis of different organs such as pancreas, spleen, liver, kidney and inflammation of peritoneal surface, air sacs and reproductive system. These might be due to viral damage to specific and non-specific immune mechanisms.

Many strains of AI viruses are reported to be nephrotropic and cause acute renal tubular necrosis (Halvorson *et al.*, 1980), especially in White Leghorn chickens. In the recent outbreak of LP H7N3 avian influenza that occurred in Norfolk during early 2006, the only histopathological finding was multifocal acute necrosis of the renal tubules (Lister *et al.*, 2006). In this study, frequency of tubular necrosis of the kidney were 33%, only one bird from the 18 and one from 24 weeks groups showed renal tubular necrosis.

Presence of yolk globule in the blood vessels of the kidney and lung could be due to bursting atresia of large yolky follicles due to systemic effects of the virus on bird. In any disease and stressful condition, one of the first reactions of laying hen is to stop producing egg and large yolky follicles on the ovary start to undergo bursting atresia. During this process large amount of yolk escape from the follicular wall and enter the lacuna spaces in the ovary, where it is broken down to smaller particles and re-absorbed internally by the ovary. There are some possibilities that yolk globule can get access to the blood vessels (Nili and Kelly,

1996). It has been shown that laying hens can tolerate large amount of intravenously injected yolk to their circulation (Nili and Kelly, 2002).

During LPAI outbreak in Italy, the most striking postmortem finding was the presence of fibrinous clot in the sinus, in this study we observed hyper secretion of respiratory mucosa, but no fibrinous clot in the upper respiratory system. Haemorrhage in the trachea, epicardial fat and caecal tonsils were only observed in the control (non-immunized challenged) bird. One bird from 18-week-old group showed some haemorrhage between the gizzard and proventriculus. The involvement of reproductive organs and peritoneal cavity which were observed in this study has been reported in field cases during natural Italian outbreak of LPAI (Capua and Mutinelli, 2001). These could be either due to systemic effect of the virus on the bird specific and non-specific immune system, or as a result of functional damage to specific organ such as the oviduct or air sacs which both are connected with outside environment.

It is concluded from this study that pre-immunization of chicken with LPAI H7N1 A/CK/Italy/1279/99 has not been able to protect them from pathogenic nature of H7N1 A/ostrich/Italy/984/00 after 18 and 24 weeks.

References

- Alexander, DJ (2000). Highly pathogenic avian influenza. In: *OIE manual of standards for diagnosis tests and vaccines*. (4th Edn.), Paris: Office International des Epizooties. PP: 212-220.
- Brugh, M (1988). Highly pathogenic virus recovered from chickens infected with mildly pathogenic 1986 isolates of H5N2 avian influenza virus. *Avian Dis.*, 32: 695-703.
- Brugh, M and Beard, CW (1986). Influence of dietary calcium stress on lethality of avian influenza viruses for laying chickens. *Avian Dis.*, 30: 672-678.
- Brugh, M and Perdue, ML (1991). Emergence of highly pathogenic virus during selective chicken passage of the prototype mildly pathogenic chicken/Pennsylvania/83 (H5N2) influenza virus. *Avian Dis.*, 35: 824-833.
- Capua, I and Mutinelli, F (2001). A colour atlas and text on avian influenza. Filgraf, Forli-Italy.

- Fouchier, RA; Vincent, M; Wallensten, A; Bestebroer, TM; Harfst, S; Smith, D; Rimmelzwaan, GF; Olsen, B and Osterhaus, ADME (2005). Characterization of a novel influenza A virus hemagglutinin subtype (H16) obtained from Black-Headed gull. *J. Virol.*, 79: 2814-2822.
- Garcia, M; Crawford, JM; Latimer, JW; Rivera-Cruz, MVZE and Perdue, ML (1996). Heterogeneity in the hemagglutinin gene and emergence of the highly pathogenic phenotype among recent H5N2 avian influenza viruses from Mexico. *J. Gen. Virol.*, 77: 1493-1504.
- Halvorson, DA; Karuakaran, D and Newman, JA (1980). Avian influenza in caged laying chickens. *Avian Dis.*, 24: 288-294.
- Lister, S; Knott, C and Hammond, P (2006). Low pathogenic H7N3 avian influenza. *Vet. Rec.*, 158: 771.
- Nili, H and Kelly, WR (1996). Form and function of lacunae in the ovary of the laying hens. *Anat. Rec.*, 244: 165-174.
- Nili, H and Kelly, WR (2002). A study of the effects of intravenous injection of large amounts of homologous yolk in laying hens. *Iranian Journal of Veterinary Research*. 3: 163-168.
- Swayne, DE and Halvorson, DA (2003). Influenza. In: Saif, YM; Barnes, HJ; Glisson, JR; Fadly, AM; McDoughald, LR and Swayne, DE (Eds.), *Diseases of poultry*. (11th Edn.), Ames, Iowa, Iowa State University Press. PP: 135-160.
- Swayne, DE; Radin, MJ; Hoepf, TM and Slemons, RD (1994). Acute renal failure as the cause of death in chickens following intravenous inoculation with avian influenza virus A/chicken/Alabama/7395/75 (H4N8). *Avian Dis.*, 38: 151-157.