

Short Paper

Macro anatomical investigations of the cranial cervical ganglion of the sheep

Najafi, G.^{1*} and Nejati, V.²

¹Department of Basic Sciences, Faculty of Veterinary Medicine, Urmia University, Urmia, Iran; ²Department of Biology, College of Basic Sciences, Urmia University, Urmia, Iran

*Correspondence: G. Najafi, Department of Basic Sciences, Faculty of Veterinary Medicine, Urmia University, Urmia, Iran. E-mail: g.najafi2006@yahoo.com

(Received 30 Jan 2008; revised version 2 Dec 2008; accepted 10 Jan 2009)

Summary

In the present study, eight specimens of sheep (>1 year) of both sexes were dissected to provide a comprehensive description of the weight, allocation and nerve branches of the cranial cervical ganglion. The cranial cervical ganglion was found beneath the mandibular salivary gland. It was located ventromedial to tympanic bulla and ventrally to atlantic fossa. In three out of eight animals it was at the dorsal region of the base of epiglottic cartilage, medial to paramastoid process and medial of the external carotid and occipital arteries. The cranial cervical ganglion was fusiform and reddish in colour. The weight, length, width and thickness (Mean \pm SE) of the cranial cervical ganglion in sheep were 0.12 ± 0.01 g, 8.52 ± 0.34 mm, 2.31 ± 0.03 mm and 2.00 ± 0.03 mm, respectively. It was found that the branches of the cranial cervical ganglion were internal carotid, external carotid and jugular nerves.

Key words: Macroanatomical, Cranial cervical ganglion, Sheep

Introduction

The cranial cervical ganglion is an important pathway between central nervous system and visceral target organs. Postganglionic sympathetic fibers of the cranial cervical ganglion innervate smooth muscles and glands in the head region. The postganglionic fibers from the cranial cervical nerves are extended to the adventitia of all cranial arteries. Only postganglionic fibers leave the ganglion (Konig and Liebich, 2004; Junquera and Carnerio, 2005). The cranial cervical ganglion is a well-vascularized structure and consists of large cell bodies with prominent fine Nissl bodies surrounded by abundant small glial cells called satellite cells (Getty, 1975; Junquera and Carnerio, 2005). In the horse the cranial cervical ganglion is a fusiform grayish-pink ganglion and is about 2 to 3 cm in length and 3 mm to 1 cm in diameter. But in the calf, sheep and goat it is about 15. 15 - 8 mm rostrocaudally, 8. 5 - 3 mm dorsoventrally and 4. 3 - 3 mm

mediolaterally, respectively (Getty, 1975). In the horse the cranial cervical ganglion is located at the cranial extremity of each cervical sympathetic trunk, and lies closely opposite to the internal carotid artery. Each ganglion is related to caudal face of the guttural pouch and ventrally located to atlantoccipital articulation (Ozgel *et al.*, 2004). Cranial cervical ganglion in dog lies deeply in the tympanic bulla and in proximal portion of cranial nerves IX, X, XI and XII. A large portion of the postganglionic fibers leaving the ganglion and continued as plexuses along the arteries of the head region. For example, quite prominent bundles of fibers can be observed going to both external and internal carotid arteries (Evans and Christensen, 1979).

Nerves from each ganglion include internal carotid, external carotid, jugular nerves, branches to the thyroid gland, guttural branches joining the vagus, glossopharyngeal, hypoglossal and first cervical nerves and their accessories. In the domestic ruminants no branches of the

cranial cervical ganglion have been found innervating the heart (Getty, 1975).

The aim of the present study was to describe the macroanatomical structures of the cranial cervical ganglion of the sheep.

Materials and Methods

Eight sheep (>1 year, four male and four female) weighing between 20-30 kg were examined in this study. The cranial cervical ganglions were dissected and measured by a calipers compass and photographs were taken using a Sony w70 camera. Dissection was performed on the anatomical structures of the related area and the cranial cervical ganglion and related fibers were exposed. The results were expressed as mean \pm SE.

Results

In all dissected sheep, the cranial cervical ganglion was located cranio-ventrally to the atlas, at the medial of paramastoid process and dorsal base of epiglottic cartilage and medial to the internal carotid and occipital arteries. Finally, the cranial cervical ganglion was found caudal to the internal and external carotid arteries and superficial to the rectus capitis ventralis major muscle and deep to proximal part of the IX, X, XI and XII cranial nerves. The ganglion was fusiform in shape, slightly resembling a triangle and was reddish in colour (Fig. 1). The weight, length, width and thickness of the ganglion were 0.12 ± 0.01 g, 8.52 ± 0.34 mm, 2.31 ± 0.03 mm and 2.00 ± 0.03 mm, respectively.

The cranial cervical ganglion send three separate bundles of postganglionic fibers, all continuing as plexuses along the arteries of the head region. The internal carotid nerve was the direct prolongation of the ganglion, in cranial pole of ganglion and ascended beside the internal carotid artery and entered the cranial cavity. It lets out several bundles to form the internal carotid plexus. Second branch of the cranial cervical ganglion was jugular nerve originating from the caudal pole of the ganglion, mounted under the vagal and glossopharyngeal nerves.

This nerve splits into several branches near the jugular foramen. From the lateral outline of caudal part of the ganglion,

branches reached to the common carotid artery.

The external carotid nerve as a single branch ramified ventrally to the caudal part of cranial cervical ganglion. This branch originating from the external carotid plexus followed the smaller arteries arising from the external carotid artery and formed some smaller plexuses along those arteries (Figs. 1 and 2).

Discussion

The cranial cervical ganglion is functionally an important pathway between the central nervous system and visceral organs (Junquera and Carnerio, 2005;

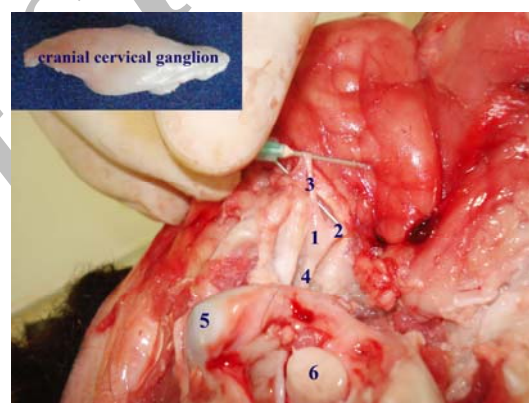


Fig. 1: Cranial cervical ganglion, 2. external carotid nerve, 3. jugular nerve, 4. internal carotid nerve, 5. condyloid process of the occipital bone and 6. spinal cord

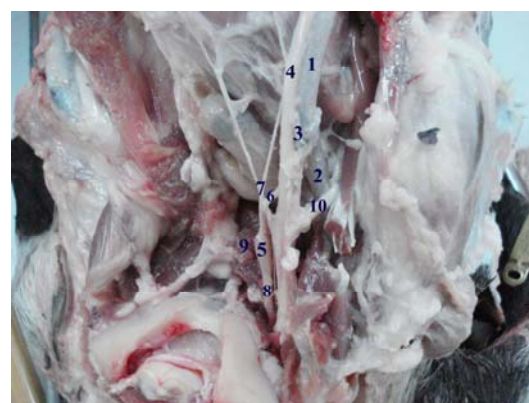

Fig. 2: 1. common carotid artery, 2. external carotid artery, 3. internal carotid artery, 4. vagal nerve, 5. cranial cervical ganglion, 6. external carotid nerve, 7. jugular nerve, 8. internal carotid nerve, 9. rectus capitis ventralis major muscle and 10. glossopharyngeal nerve

Kabak and Gultiken, 2006).

This study revealed that the cranial cervical ganglion in sheep is fusiform in shape and is similar to other domestic ruminants (Getty, 1975; Dyce *et al.*, 1996).

In the sheep cranial cervical ganglion was found to be located medial to paramastoid process and beneath the mandibular gland. The topography of the ganglion generally resembles to those of other ruminants (Getty, 1975; Dyce *et al.*, 1996).

Getty (1975) and Dyce *et al.* (1996) indicated that the length of the ganglion in calf is 15 mm and the width is 8 mm but in goat, the length and width are 3 and 8 mm, respectively. In camel, cranial cervical ganglion is 15-20 mm long, 4-6 mm wide and 3 mm thick (Sheng *et al.*, 1998). In the present study, the mean weight, length, width and thickness of the cranial cervical ganglion in young sheep were 0.12 ± 0.01 g, 8.52 ± 0.34 mm, 2.31 ± 0.03 mm and 2.00 ± 0.03 mm, respectively. The cranial cervical ganglion in this study was considerably smaller than in large ruminants.

There were no obvious differences in the topography of ganglions between left and right sides. The internal carotid nerve ramified to several branches from cranial part of the cranial cervical ganglion in horse, dog and young sheep. These branches form the internal carotid plexus, circumscribing the internal carotid artery and run along with this artery towards the cranial cervical ganglion (Getty, 1975; Howard and George, 1979). In this study, internal carotid nerve had several branches in all sheep. A nerve branch ramifies from cranial cervical ganglion to the cervical nerves in dog (Howard and George, 1979), horse (Getty, 1975), pig (Kabak *et al.*, 2005), and camel (Sheng *et al.*, 1998). In dog, this branch sends branches to the first, second and third cervical nerves (Howard and George, 1979). There is sometimes an additional branch in horse and dog, originating directly from the cranial cervical ganglion, extending to the second cervical nerve (Getty, 1975). In the present study, 2-3 branches of internal carotid nerve were originated from the central part of the ganglion and reached to

cervical nerves.

The jugular branch documented in the literature (Dyce *et al.*, 1996) was said to be either a single branch or two separate branches. In this study, the jugular nerve was a single branch originating from the caudal pole of the ganglion and passing upward under the vagus and glossopharyngeal nerves.

The external carotid nerve is another major nerve trunk originating from cranial cervical ganglion. In this study it was a single branch originating from the cranial cervical ganglion and followed smaller arteries.

References

- Dyce, KM; Sack, WO and Wensing, CJ (1996). *Textbook of veterinary anatomy*. 2nd Edn., W. B. Saunders Co., PP: 314-326.
- Evans, HE and Christensen, CG (1979). The digestive apparatus and abdomen. In: *Miller's anatomy of the dog*. 2nd Edn., Philadelphia, W. B. Saunders Co., PP: 1044-1045.
- Getty, R (1975). *The anatomy of the domestic animals*. 5th Edn., Vol. 1, W. B. Saunders. PP: 1151-1155.
- Howard, E and George, C (1979). *Anatomy of the Dog*. 2nd Edn., W. B. Saunders Co., PP: 1044-1045.
- Junquera, LC and Carnerio, J (2005). *Basic histology*. 11th Edn., McGraw-Hill. PP: 174-179.
- Kabak, M and Gultiken, ME (2006). Arterial supply of the superior cervical ganglion in the guinea-pig (*Cavia porcellus*). *Anat. Histol. Embryol.*, 35: 393-395.
- Kabak, M; Orhan, I and Hazirolu, R (2005). Macro anatomical investigations of the cranial cervical ganglion in domestic pig (*Sus scrofa domestica*). *Anat. Histol. Embryol.*, 34: 199-202.
- Konig, HE and Liebich, HG (2004). *Veterinary anatomy of domestic mammals*. 2nd Edn., Schattauer. PP: 530-533.
- Ozgel, O; Kurtul, I and Dursun, N (2004). On the gross anatomy of the cranial cervical ganglion of the donkey (*Equus asinus*) in Turkey. *Vet. Res. Commun.* 28: 261-266.
- Sheng, C; Jian-Ling, W and Zhen-Ming, X (1998). The gross anatomy of the cranial cervical ganglion and its branches in the bactrian camel (*Camelus bactrianus*). *Vet. Res. Commun.*, 22: 1-5.