

L-methionine attenuates gentamicin nephrotoxicity in male Wistar rat: pathological and biochemical findings

Derakhshanfar, A.^{1*}; Bidadkosh, A.² and Hashempour Sadeghian, M.³

¹Department of Pathobiology, Faculty of Veterinary Medicine, Shahid Bahonar University of Kerman, Kerman, Iran; ²Graduated from Faculty of Veterinary Medicine, Kazeroun Branch, Islamic Azad University, Kazeroun, Iran; ³Larestan Veterinary Office, Khonj, Iran

*Correspondence: A. Derakhshanfar, Department of Pathobiology, Faculty of Veterinary Medicine, Shahid Bahonar University of Kerman, Kerman, Iran. E-mail: damin@mail.uk.ac.ir

(Received 13 Jul 2008; revised version 24 May 2009; accepted 7 Jun 2009)

Summary

The clinical uses of gentamicin have so far been restricted due to nephrotoxicity and ototoxicity. The exact mechanism of nephrotoxicity is still unknown; however, it appears that free radicals may be involved. Methionine has previously been shown to alleviate oxidative stress involved in ototoxicity due to its antioxidant properties. Therefore, the effect of methionine supplementation on the gentamicin induced nephrotoxicity was examined in this study. Twenty eight male Wistar rats were randomly divided into 4 equal groups to receive a daily corresponding dose of either gentamicin (80 mg/kg B.W.; i.m.; group GN), L-methionine (100 mg/kg B.W.; i.p.; MT), combination thereof (MG), and normal saline as control (CT). After slaughtering the animals on day 11, values of blood urea nitrogen (BUN), serum creatinine concentration (SCr), urinary gamma glutamyl transpeptidase (GGT) activity, and renal cortical reduced glutathione (GSH) contents with histopathologic investigations were measured. In group GN, biochemical profiles showed a remarkable increase in BUN, SCr and urinary GGT concentration, and depletion of renal cortical of GSH. In addition, histopathologic studies revealed severe acute tubular necrosis, congestion and hyaline casts, verifying gentamicin-induced nephrotoxicity. In group MG, only mild epithelial changes and renal congestion were prominent findings. Moreover, these changes in rats given the combined therapy (MG) were significantly less than those of group GN, thereby suggesting that supplemented L-methionine ameliorate gentamicin nephrotoxicity in rat. In group MT, only medullary congestion was seen without change in the biochemical factors as was in the CT group with normal kidney structure. Generally, results of this study showed that methionine may significantly prevent gentamicin nephrotoxicity, removing the oxidative stress.

Key words: Gentamicin, Methionine, Nephrotoxicity

Introduction

Administration of gentamicin in a variety of clinical situations is restricted due to the fact that it may cause nephrotoxicity and ototoxicity. On average, 20 to 30% of patients develop renal failure after seven-day long therapy with the aminoglycoside (Ali, 1995; Mingeot-Leclercq and Tulkens, 1999). The exact mechanism by which gentamicin is thought to evoke these effects is somewhat controversial. However, reactive oxygen species (ROS) appear to be involved in this respect (Ali, 1995). Experimental gentamicin nephrotoxicity has been investigated in various animal models so far, and several approaches considering different

mechanisms have been attempted to reduce the nephrotoxicity of gentamicin and related aminoglycosides (Ali, 2003). Among these, the most consistent effect has been observed with the use of antioxidant agents such as vitamin C, vitamin E (Derakhshanfar *et al.*, 2007), N-acetyl cysteine, and S-allyl cysteine (Kavutcu *et al.*, 1996; Mazzon *et al.*, 2001; Maldonado *et al.*, 2003).

Methionine, as an essential sulfur-containing amino acid, possesses antioxidant activity on the basis of its sulfhydryl group, and is now being used clinically to decrease hepatic injuries after acetaminophen poisoning (Unnikrishnan and Rao, 1990; Kröger *et al.*, 1997). Sha and Schacht (2000) have also shown that methionine attenuates

gentamicin ototoxicity in guinea pigs and may be a potential agent for preventing hearing loss in clinical conditions. To our knowledge, there is no evidence reporting the protecting effect of methionine on gentamicin induced nephrotoxicity. In the present study, the authors have directed their endeavours to evaluate potential preserving properties of methionine against gentamicin-induced nephrotoxicity.

Materials and Methods

Animals

Twenty eight 9- to 10-week-old male Wistar rats, weighing initially 270 to 300 g, were randomly assigned to 4 equal groups and housed in metabolic cages with free access to commercial rodent diet and water. All rats were allowed 5 days of adaptation period in a room with controlled conditions (temperature: 22-25°C and humidity 60-70%) before starting the experiment. This protocol was performed in accordance with the international guiding principles for biomedical researchers involving laboratory animals at Kerman University of Medical Sciences.

Treatments

Animal in various group were assigned to receive a corresponding dose of either gentamicin (GN; 80 mg/kg B.W.; Merck Co., Darmstadt, Germany), L-methionine (MT; 100 mg/kg B.W.; Merck Co., Darmstadt, Germany), combination thereof (MG) or normal saline as control (CT) for 10 consequent days.

Sampling

On the day prior to killing (Day 10), all animals were kept individually in metabolic cages for 24-hours after last injection and urine samples were collected to monitor urinary enzyme activities. At the end of the experiments, blood samples were collected from tails and centrifuged to obtain an appropriate amount of serum. After that, all rats were sacrificed, and their kidneys were removed as soon as possible. Portions of the right and left kidneys were fixed for routine histopathologic evaluation and also placed in cold saline and frozen at -20°C for

measurement of reduced glutathione (GSH) content, respectively.

Markers of glomerular and tubular damage

Concentration of serum creatinine concentration (SCr) was measured by alkaline picrate method (Bartels *et al.*, 1972). Blood urea nitrogen (BUN) was measured with the commercial Kit developed by the Parsazmoon Company (Tehran, Iran) based on the method described by Talke and Schubert (1965) using commercial kits. Urinary gamma glutamyl transpeptidase (GGT) was measured with the method modified by Wallhofer *et al.* (1974) using RA1000 auto analyzer (Technicon Co., Bayer Tarrytown, NY, USA). The kit contained two solutions. According to the instruction, one proportion of the first tube was combined with 2 proportions of the second one, and 1000 µl of that mixture was added to 100 µl of urine sample. Optical density at a wave length of 405 nanometers was assessed for the first, second and third seconds. The average of these results was multiplied in 1158 to identify GGT concentration.

Marker of oxidative stress

Concentration of GSH was measured spectrophotometrically by the method of Jollow *et al.* (1974).

Histopathological examination

Kidney tissues, to be embedded in paraffin, were fixed in 10% neutral buffered formalin solution and dehydrated in graded anhydrous absolute ethanol and xylol. Sections of 5 µm of thickness were stained by hematoxylin-eosin and examined by a histopathologist unaware of the treatments.

Statistical analysis

Results were expressed as Means ± SEM. Data were analyzed by one-way ANOVA followed by Bonferroni's multiple comparison test, using the software SPSS 10 (Statistical Package for the Social Sciences, version 10.1, SPSS; Surrey, UK). P-value less than 0.05 was considered statistically significant.

Results

Administration of gentamicin to rats resulted in a significant increase in the SCr level when compared to controls ($P < 0.05$). Co-administration of methionine decreased the change induced by gentamicin in rats receiving the dual therapy. In rat treated only with methionine, no significant change was observed ($P > 0.05$; Table 1).

Gentamicin induced a considerable increase in BUN concentration ($P < 0.05$). Co-administration of methionine partially reversed this effect, while methionine per se did not change BUN compared to the control rats (Table 1).

Urinary GGT activity of rats receiving a 10 day therapeutic dose of gentamicin for 10 days (80 mg/kg BW) was remarkably increased ($P < 0.05$). Biochemical profile of rats co-administered with methionine revealed a significant increase in GGT activity compared to the CT group ($P < 0.05$). This change was significantly lower than those of the GT rats. In group MT, urinary GGT was not significantly altered throughout the study period (Table 1).

Kidney cortical concentration of GSH decreased significantly after 10 days of the gentamicin therapy ($P < 0.05$). However, in the MG group, this decrease in GSH was significantly lower than those of the gentamicin group ($P < 0.05$). As seen in Table 1, methionine-treated rats showed no significant alteration in GSH bioavailability compared to the controls.

Rats treated with gentamicin showed acute tubular necrosis, formation of hyaline and granular casts in proximal tubules and renal congestion. Methionine-treated rats showed only medullary congestion. Microscopic observations in group MG, revealed mild medullary congestion and mild necrosis without cast formation. In the CT rats, normal kidney structure was seen (Figs. 1, 2 and 3).

Discussion

Several hypotheses have been suggested to elucidate the possible mechanism(s) of gentamicin nephrotoxicity (Ali, 1995). Among them, oxidative stress has been

shown to be the main focus of interest by many workers (Walker and Shah, 1988; Shah and Walker, 1992; Cuzzocrea *et al.*, 2002). It may be expressed as formation of ROS, and decreased activity of antioxidant

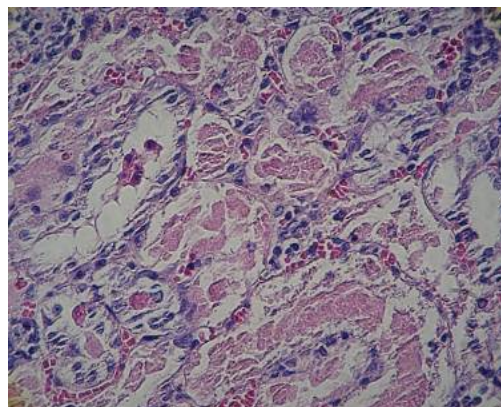


Fig. 1: Rats treated with gentamicin (GN) have revealed severe acute tubular necrosis, (H&E, $\times 400$)

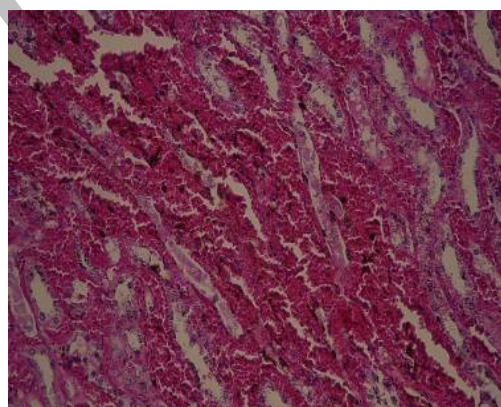


Fig. 2: In methionine-alone treated rats (MT), medullary congestion is seen, (H&E, $\times 400$)

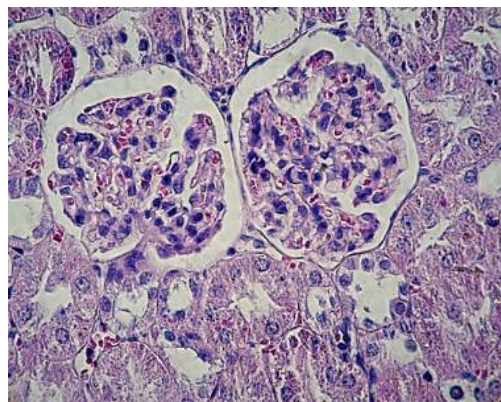


Fig. 3: In control (CT) group, no pathologic lesion can be seen, (H&E, $\times 400$)

Table 1: Biochemical profile in serum and urine of rats after 10 days of study. Data are expressed as mean \pm SEM

	GN	MT	MG	CT
SCr (mg/dL)	4.51 \pm 0.31 ^a	1.81 \pm 0.03 ^b	1.67 \pm 0.15 ^b	1.43 \pm 0.10 ^b
BUN (mg/dL)	128.14 \pm 1.21 ^a	16.00 \pm 0.30 ^b	54.43 \pm 1.90 ^c	16.01 \pm 0.91 ^b
GGT (IU/L)	4.79 \pm 0.19 ^a	2.53 \pm 0.06 ^b	3.83 \pm 0.11 ^c	2.42 \pm 0.10 ^b
GSH (μ mol/g tissue)	6.50 \pm 0.14 ^a	13.5 \pm 0.18 ^b	11.80 \pm 0.13 ^c	12.77 \pm 0.26 ^b

Abbreviations are defined in text; Means with different superscripts within each row shows significant difference (P<0.05)

enzymes (Cuzzocrea *et al.*, 2002; Maldonado *et al.*, 2003; Pedraza-Chaverri *et al.*, 2003).

The biochemical data presented in this study, as in our previous investigation (Derakhshanfar *et al.*, 2007), showed a decrease in glomerular filtration indicated by increased serum levels of creatinine and BUN after starting gentamicin administration, however histopathological evaluations showed no significant change in the kidney glomeruli. The histologic appearance of a kidney with acute tubular necrosis includes irregular necrosis of the proximal tubules, and hyaline and granular casts may be present (Maxie and Newman, 2007).

Enhanced urinary brush border enzyme, GGT, indicated direct toxic effect as pathologically confirmed by acute tubular necrosis and formation of hyaline casts in proximal tubules. Induction of tubular necrosis by gentamicin has already been reported by several studies (Maldonado *et al.*, 2003; Pedraza-Chaverri *et al.*, 2003). Urinary GGT excretion was reduced on dual therapy in the group MG, supporting the *in vitro*-based hypothesis that, methionine's antioxidative properties as well as vitamin E's were protecting oxidative stress involved in tubular toxicity (Derakhshanfar *et al.*, 2007).

Our study revealed that gentamicin decreases the concentration of GSH as previously shown by Ali *et al.* (1992). Moreover, an association between kidney GSH concentration and renal function has been well documented in some relevant literature (Brezis *et al.*, 1983; Torres *et al.*, 1987). In rat given gentamicin, GSH is oxidized by glutathione peroxidase, when inactivating free radicals inside cells (Walker and Shah, 1988). According to these studies, depletion of GSH and

increased cell peroxidation has been suggested to implicate the pathogenesis of renal damage (Ramsammy *et al.*, 1985; Walker and Shah, 1988; Shah and Walker, 1992). Similarly, Soejima *et al.* (2000) have shown that simultaneous inhibition of renal phospholipase A₂ and glutathione synthesis in rat induces an acute renal failure with similar characteristics to gentamicin-induced nephrotoxicity. Taken together, the protective effect of L-methionine has been known to be related to the amino acid's antioxidant activity, when serving as glutathione precursor, indicated by an increased GSH level (Garetz *et al.*, 1994; Sha and Schacht, 2000). In accordance with the results of the present study, various authors have so far demonstrated this capability of methionine for maintaining GSH concentration in the kidney cortices (Unnikrishnan and Rao, 1990; Sha and Schacht, 2000).

Two other mechanisms may likely play a role in the antioxidant activity of methionine: Methionine, like most amino acids, has metal chelating property and ameliorates gentamicin nephrotoxicity (Ali, 2003) as do iron chelators with oxidative stress caused by gentamicin. Methionine decreases the gentamicin-induced formation of ROS *in vitro* in the non-enzymatic system of antioxidants as well as in cell culture. So, methionine using its sulfhydryl group may additionally act as a potent scavenger of free radicals (Unnikrishnan and Rao, 1990; Priuska and Schacht, 1995).

Methionine administration seems to be well tolerated in animals (Jones and Basinger, 1989), and thus, would be a topic of further studies. Since methionine did not significantly alter the serum levels of gentamicin (Sha and Schacht, 2000), it could be considered as a potential protective agent associated with gentamicin administration.

Although congestion seen in group MT may show some interference between methionine administration and renal function, it must be mentioned that the dose of methionine used in this study (80 mg/kg body weight daily) was rather high and gentamicin could be combined with, at therapeutic doses.

Given the critical role of antioxidant in the kidney homeostasis, the combination therapy with L-methionine may prevent gentamicin-induced nephrotoxicity, preserving glutathione peroxidase activity in the cortex.

Acknowledgements

We thank Mrs. Nasrin Setoodeh (MS) and Mr. Mohammad Hosein Beheshti (MS) for checking the statistical analysis of the data.

References

- Ali, BH (1995). Gentamicin nephrotoxicity in humans and animals: some recent research. *Gen. Pharmacol.*, 26: 1477-1487.
- Ali, BH (2003). Agents ameliorating or augmenting experimental gentamicin nephrotoxicity: some recent research. *Food Chem. Toxicol.*, 41: 1447-1452.
- Ali, BH; Abdel Gayoum, AA and Bashir, AA (1992). Gentamicin nephrotoxicity in rat: some biochemical correlates. *Pharmacol. Toxicol.*, 70: 419-423.
- Bartels, H; Böhmer, M and Heierli, C (1972). Serum creatinine determination without protein precipitation. *Clin. Chim. Acta.* 37: 193-197.
- Brezis, M; Rosen, S; Silva, P and Epstein, FH (1983). Selective glutathione depletion on function and structure of the isolated perfused rat kidney. *Kidney Int.*, 24: 178-184.
- Cuzzocrea, S; Mazzon, E; Dugo, L; Serraino, I; Di Paola, R; Britti, D; De Sarro, A; Pierpaoli, S; Caputi, A; Masini, E and Salvemini, D (2002). A role for superoxide in gentamicin-mediated nephropathy in rats. *Eur. J. Pharmacol.*, 450: 67-76.
- Derakhshanfar, A; Bidakhosh, A and Kazemina, S (2007). Vitamin E protection against gentamicin-induced nephrotoxicity in rats: a biochemical and histopathologic study. *Iranian J. Vet. Res.*, 8: 231-238.
- Garetz, SL; Rhee, DJ and Schacht, J (1994). Sulfhydryl compounds and antioxidants inhibit cytotoxicity to outer hair cells of a gentamicin metabolite *in vitro*. *Hear Res.*, 77: 75-80.
- Jollow, DJ; Mitchell, JR; Zampaglione, N and Gillette, JR (1974). Bromobenzene-induced liver necrosis. Protective role of glutathione and evidence for 3,4-bromobenzene oxide as the hepatotoxic metabolite. *J. Pharmacol.*, 11: 151-169.
- Jones, MM and Basinger, MA (1989). Thiol and thioether suppression of cis-platinum-induced nephrotoxicity in rats bearing the Walker 256 carcinosarcoma. *Anticancer Res.*, 9: 1937-1941.
- Kavutcu, M; Canbolat, O; Oztürk, S; Olcay, E; Ulutepe, S; Ekinçi, C; Gökhan, IH and Durak, I (1996). Reduced enzymatic antioxidant defense mechanism in kidney tissues from gentamicin-treated guinea pigs: effects of vitamins E and C. *Nephron.* 72: 269-274.
- Kröger, H; Dietrich, A; Ohde, M; Lange, R; Ehrlich, W and Kurpysz, M (1997). Protection from acetaminophen-induced liver damage by the synergistic action of low doses of the poly (ADP-ribose) polymerase-inhibitor nicotinamide and the antioxidant N-acetylcysteine or the amino acid L-methionine. *Gen. Pharmacol.*, 28: 257-263.
- Maldonado, PD; Barrera, D; Medina-Campos, ON; Hernández-Pando, R; Ibarra-Rubio, ME and Pedraza-Chaverri, J (2003). Aged garlic extract attenuates gentamicin induced renal damage and oxidative stress in rats. *Life Sci.*, 73: 2543-2556.
- Maldonado, PD; Barrera, D; Rivero, I; Mata, R; Medina-Campos, ON; Hernández-Pando, R and Pedraza-Chaverri, J (2003). Antioxidant S-allylcysteine prevents gentamicin-induced oxidative stress and renal damage. *Free Radic. Biol. Med.*, 35: 317-324.
- Maxie, MG and Newman, SJ (2007). The urinary system. In: Maxie, MG (Ed.), *Jubb, Kennedy, and Palmer's pathology of domestic animals*. (5th Edn.), Vol. 2, Philadelphia, Elsevier Limited. P: 446.
- Mazzon, E; Britti, D; De Sarro, A; Caputi, AP and Cuzzocrea, S (2001). Effect of N-acetylcysteine on gentamicin-mediated nephropathy in rats. *Eur. J. Pharmacol.*, 424: 75-83.
- Mingeot-Leclercq, MP and Tulkens, PM (1999). Aminoglycosides: nephrotoxicity. *Antimicrob. Agents Chemother.*, 43: 1003-1012.
- Pedraza-Chaverri, J; González-Orozco, AE; Maldonado, PD; Barrera, D; Medina-Campos, ON and Hernández-Pando, R (2003). Diallyl disulfide ameliorates gentamicin-induced oxidative stress and

- nephropathy in rats. *Eur. J. Pharmacol.*, 473: 71-78.
- Priuska, EM and Schacht, J (1995). Formation of free radicals by gentamicin and iron and evidence for an iron/gentamicin complex. *Biochem. Pharmacol.*, 50: 1749-1752.
- Ramsammy, L; Ling, KY; Josepovitz, C; Levine, R and Kaloyanides, GJ (1985). Effect of gentamicin on lipid peroxidation in rat renal cortex. *Biochem. Pharmacol.*, 34: 3895-3900.
- Sha, SH and Schacht, J (2000). Antioxidants attenuate gentamicin-induced free radical formation *in vitro* and ototoxicity *in vivo*: D-methionine is a potential protectant. *Hear Res.*, 142: 34-40.
- Shah, SV and Walker, PD (1992). Reactive oxygen metabolites in toxic acute renal failure. *Ren. Fail.*, 14: 363-370.
- Soejima, A; Ishizuka, S; Miyake, N; Fukuoka, K; Suzuki, M; Kamiya, Y and Nagasawa, T (2000). Simultaneous inhibition of renal phospholipase A(2) and glutathione synthesis by monoalide and DL-buthionine sulfoximine induces acute tubular dysfunction in rats. *Exp. Nephrol.*, 8: 84-90.
- Talke, H and Schubert, GE (1965). Enzymatic urea determination in the blood and serum in the Warburg Optical Test. *Klin. Wochenschr.*, 43: 174-175.
- Torres, AM; Rodriguez, JV and Elias, MM (1987). Urinary concentrating defect in glutathione-depleted rats. *Can. J. Physiol. Pharmacol.*, 65: 1461-1466.
- Unnikrishnan, MK and Rao, MN (1990). Antiinflammatory activity of methionine, methionine sulfoxide and methionine sulfone. *Agents Actions.* 31: 110-112.
- Walker, PD and Shah, SV (1988). Evidence suggesting a role for hydroxyl radical in gentamicin-induced acute renal failure in rats. *J. Clin. Invest.*, 81: 334-341.
- Wallhofer, H; Schmidt, U and Schmidt, FW (1974). Synopsis der leberkrankheiten. *Dtsch. Med. Wschr.*, 99: 343.

Archive of SID