

# Evaluation of H9N2 avian influenza virus dissemination in various organs of experimentally infected broiler chickens using RT-PCR

Mosleh, N.<sup>1</sup>; Dadras, H.<sup>2\*</sup> and Mohammadi, A.<sup>3</sup>

<sup>1</sup>Ph.D. Student in Avian Medicine, Department of Avian Medicine, School of Veterinary Medicine, Shiraz University, Shiraz, Iran and Academic Staff of Yasudj Branch, Islamic Azad University (IAU), Yasudj, Iran;

<sup>2</sup>Department of Avian Medicine, School of Veterinary Medicine, Shiraz University, Shiraz, Iran;

<sup>3</sup>Department of Pathobiology, School of Veterinary Medicine, Shiraz University, Shiraz, Iran

\*Correspondence: H. Dadras, Department of Avian Medicine, School of Veterinary Medicine, Shiraz University, Shiraz, Iran. E-mail: dadras@shirazu.ac.ir

(Received 9 Jun 2008; revised version 22 Nov 2008; accepted 23 Nov 2008)

## Summary

Widespread occurrence of H9N2 low pathogenic avian influenza (LPAI) viruses in many Asian countries during the past decade has resulted in the need for evaluation of the pathogenesis of H9N2 virus infection. In this study, tissue tropism and dissemination of A/Chicken/Iran/772/1998(H9N2) virus throughout the body of broiler chickens were investigated. The clinical signs, gross lesions and antibody titer of the infected chicks were also monitored. Fifty one-day-old commercial broiler chicks were divided randomly into two groups (forty chicks in the experimental and ten chicks in the control group). At the age of five weeks the chicks in the experimental group were inoculated intranasally with the virus. The samples from various tissues were collected at 1, 3, 6 and 9 days post-inoculation (DPI). We used reverse transcriptase/polymerase chain reaction (RT-PCR) assay to evaluate the virus dissemination. Chickens exhibited mild respiratory signs, depression and 5% mortality. Viral RNA was detected in the kidneys on days 3, 6 and 9 PI. The virus was also found in the spleen, trachea and lungs on days 3 and 6 PI. Viral RNA was observed only on day 6 PI in feces. The most remarkable clinical signs and virus detection appeared on day 6 PI. Overall, out of 22 samples taken from each organ of the experimental (dead plus euthanized) birds, 4, 5, 11, 4, and 5 samples from trachea, lungs, kidneys, spleen and feces showed viral RNA, respectively. We could not trace the virus in the blood and pancreas. Data indicated that the number of infected chickens and viral RNA detection from tissues was reduced with increasing antibody titer on day 9 PI. Our findings suggest that the virus has tissue tropism for respiratory, urinary, lymphoid and digestive systems.

**Key words:** Avian influenza, H9N2, Tissue tropism, RT-PCR

## Introduction

H9N2 subtype of avian influenza viruses (AIV) is widespread in domestic poultry in many Asian countries (Naeem *et al.*, 1999; Lee *et al.*, 2000; Alexander, 2002; Li *et al.*, 2003; Liu *et al.*, 2004; Alexander, 2006). The virus was first reported in 1998 in a layer farm in Tehran (Vasfi Marandi and Bozorgmehrfard, 1999) and also caused widespread outbreaks in commercial broiler chickens in Iran (Nili and Asasi, 2003). The H9N2 is reported as LPAI virus but has caused severe economic losses due to decreased production, increased mortality and cost for vaccination in the commercial

poultry farms in Iran. Mortality of about 20-60% was reported in the affected broiler farms with clinical signs that were characterized as swelling of periorbital tissues and sinuses, typical respiratory discharge and severe respiratory distress (Nili and Asasi, 2002, 2003). However, H9N2 viruses isolated from chickens did not induce severe clinical signs and any mortality in experimentally infected specific pathogen free (SPF) chickens (Mo *et al.*, 1997; Pourbakhsh *et al.*, 2000; Lee *et al.*, 2007).

Due to the paradoxical behaviour of the virus, widespread occurrence of the disease, the potential of virus to mutate into highly

pathogenic (HP) form and transmission to mammalian species including humans, it is essential to investigate the virus pathogenesis. The basis of the virus pathogenesis, its tissue tropism and distribution in chickens is not well defined. Briefly, LPAI viruses often require trypsin-like proteases to cleave the hemagglutinin (HA) into HA1 and HA2 proteins to form the infectious virus particle. Therefore, efficient replication of LPAI viruses is believed to be largely confined to respiratory and gastrointestinal epithelia which contain these kinds of enzymes (Swayne and Halvorson, 2008).

In previous studies on the pathogenesis of Korean H9N2 virus, the virus was detected in oropharyngeal and cloacal swabs and also from various tissues of infected three-week-old SPF chickens (Kwon *et al.*, 2008). Lee *et al.* (2007) reported that H9N2 LPAI virus was recovered from kidney and spleen of experimentally infected commercial layers. Shamseddini *et al.* (2002) detected H9N2 AI virus in the trachea, lung and kidney using indirect immunoperoxidase assay. Shalaby *et al.* (1994) revealed that H4N8 LPAI virus has tissue tropism and pathogenicity for the respiratory and urogenital systems of laying hens. However, the rout of virus spread into these organs remains unclear and it needs to be investigated.

Virus isolation (VI) in SPF chickens is considered the most reliable test for isolation and identification of AI viruses, but it is time consuming and laborious assay and might not be sensitive especially when the quantity of virus is low in the samples. RT-PCR is a rapid diagnostic test for detection of AI virus (Lee *et al.*, 2001) and it can detect very small amount of the virus (Pregliasco *et al.*, 1998; Fouchier *et al.*, 2000). Cattoli *et al.* (2004) compared three virus detection methods with VI and found at the relative sensitivity and specificity of RT-PCR is 95.6 and 96.3%, respectively. They recommended this test as a rapid diagnostic and an alternative test to virus isolation.

The objective of the present study was to assess the H9N2 virus dissemination in various organs of the infected broiler chickens. RT-PCR test was performed to detect the presence of the virus in body

tissues and samples. The clinical signs and gross lesions of the affected chicks were also monitored.

## Materials and Methods

### Virus

The virus isolate used in this study was A/Chicken/Iran/772/1998(H9N2). It was obtained from Razi Vaccine and Serum Research Institute and was propagated two times in 9- to 11-day-old embryonated chicken eggs. The embryo infective dose (EID<sub>50</sub>) was calculated according to the Reed and Muench (1938) formula.

### Experimental design

Fifty one-day-old commercial broiler chicks were divided randomly into two groups (forty chicks in the experimental and ten chicks in the control group). They were reared separately in Animal Research Unit of Veterinary School of Shiraz University and received feed and water *ad libitum* during the experiment.

Prior to challenge, all birds were serologically tested using hemagglutination inhibition test (HI) and they were negative for antibodies to H9N2 influenza virus antigens. Furthermore, five birds from the experimental group were killed and their organs, feces and blood were investigated for virus detection. All of these samples were also negative for virus detection. At the age of 35 days, all birds in the experimental group were challenged intranasally with allantoic fluid containing 10<sup>6.5</sup> EID<sub>50</sub>/100 µl of the H9N2 virus. The remaining 10 birds were left as unchallenged control. All the chickens were monitored daily for 15 days for clinical signs, antibodies to H9N2 and mortality. On days 1, 3, 6 and 9 post-inoculation (PI) five chickens from the experimental group and two chickens from the control group were randomly selected and used for sample collection. All were bled before euthanasia. Gross lesions were recorded and their trachea, lungs, spleen, kidneys, pancreas and feces were aseptically collected for virus detection and RT-PCR assay. Blood samples were collected in EDTA tubes for virus detection. Sera of the birds were collected at the above mentioned days and also day 15 PI for HI test.

### Extraction of viral RNA

All samples except blood, were immediately stored at  $-70^{\circ}\text{C}$  until used. RNA of blood samples was extracted immediately after collection using the RNXTM (-Plus) kit (CinnaGen Inc.) according to the manufacturer's protocol. Briefly, one ml of RNX solution was added to 100  $\mu\text{l}$  of blood. After addition of 200  $\mu\text{l}$  chloroform, the mixture was centrifuged at 12000 rpm at  $4^{\circ}\text{C}$  for 15 min. The upper phase was added to equal volume of isopropanol and centrifuged at 12000 rpm at  $4^{\circ}\text{C}$  for 15 min. After washing step, the pellet was dissolved in a final volume of 50  $\mu\text{l}$  distilled water (DW) and stored at  $-70^{\circ}\text{C}$  until used.

RNA isolation of tissue samples was performed using Tissue RNA PrepMate™ kit (BioNeer Corporation, South Korea). Appropriate tissue was homogenized with 1 ml of lysis buffer and then 200  $\mu\text{l}$  chloroform was added into the mixture and centrifuged at 12000 rpm at  $4^{\circ}\text{C}$  for 10 min. Then phenol:chloroform (5:1) was added to the supernatant and centrifuged at 14000 rpm at  $4^{\circ}\text{C}$  for 5 min. In the case of RNase-rich tissues, treating with phenol:chloroform was repeated three times. The supernatant was added to equal volume of isopropanol and centrifuged at 12000 rpm at  $4^{\circ}\text{C}$  for 10 min. After washing step, RNA pellet was completely suspended in 50  $\mu\text{l}$  DW and stored at  $-70^{\circ}\text{C}$ .

Viral RNA was extracted from 140  $\mu\text{l}$  of the supernatants of 10% fecal suspensions using the QIAamp® Viral RNA kit (Qiagen, Germany) according to the manufacturer's protocol. Viral RNA was stored at  $-70^{\circ}\text{C}$  until used.

### RT-PCR

The cDNA was synthesized using AccuPowder® RT PreMix kit (BioNeer Corporation, South Korea) according to the manufacturer's instruction. The primers were specific for H9 protein gene and are shown in Table 1 (Lee *et al.*, 2001). Five  $\mu\text{l}$  of total RNA and 20 pmol of each H9-specific primers were used for cDNA preparation.

PCR was performed to amplify 488-bp fragment of H9 protein gene of avian influenza virus using the AccuPower PCR

**Table 1: RT-PCR primer sequences**

	Sequence
Forward primer	5'-CTY CAC ACA GAR CAC AAT GG-3'
Reverse primer	5'-GTC ACA CTT GTT GTT GTR TC-3'

PreMix kit (BioNeer Corporation, South Korea) in a 20  $\mu\text{l}$  reaction mixture containing 5  $\mu\text{l}$  cDNA and 10 pmol of each primers. The reaction mixture was subjected to 35 cycles of  $94^{\circ}\text{C}$ ,  $53^{\circ}\text{C}$  and  $72^{\circ}\text{C}$  each for 1 min, followed by a final extension at  $72^{\circ}\text{C}$  for 10 min (Tajmanesh *et al.*, 2006). The PCR products were separated in 1% agarose gel and visualized under ultraviolet light (Fig. 1).

### Serology

Serum samples were tested for the presence of antibodies to the challenge virus antigen using the HI test (Burleson *et al.*, 1992).

### Results

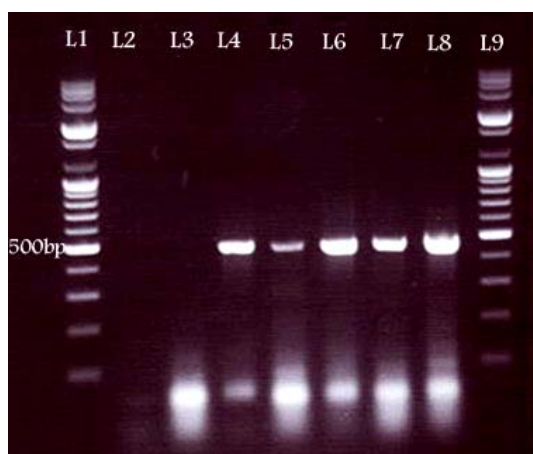
#### Virus detection in tissues at different days post-infection

The presence of the virus was checked in all samples obtained from the inoculated and control chickens at different DPI. The RT-PCR test was performed for virus detection (Fig. 1). The results of virus detection are shown in Table 2. All Samples that had been taken before inoculation were negative for virus detection. The virus was not detected at 1 DPI, too, but it was detected in the trachea, lungs, spleen, kidneys and feces of the infected chickens during the course of the experiment. On day 3 PI, two out of five and on day 6 PI, one out of five samples which had been taken from the trachea were positive for virus detection. The lungs of the infected chickens showed viral RNA on days 3 (1/5) and 6 (3/5) PI. The positive samples from the spleen were 1/5 on day 3 and 2/5 on day 6 PI. On days 3, 6 and 9 PI, the virus was detected from two, three and five out of five kidney samples, respectively. In the fecal samples the virus was only detected on day 6 (4/5) after inoculation. The results showed that H9N2 AI virus was detected in most of the affected organs on day 6 PI. All pancreas and blood samples

were negative for virus detection during the experiment.

Two chickens from the inoculated group died on days 2 and 6 after challenge. Except the kidneys, all other organs of the bird died on day 2 PI were negative for viral RNA isolation (Table 2). Viral RNA was recovered from the trachea, lungs, spleen and feces of the bird died on day 6 PI.

No virus was detected in any tissue of the uninfected control group.



**Fig. 1: Results of the PCR assay. Amplifying 488-bp segment of H9 gene of AIV. Lane L1 and L9: DNA marker (100-bp), L2: negative control (RNA of negative chicken), L3: negative sample, L4: positive control (RNA of the challenged AI virus), L5, L6, L7 and L8: positive samples**

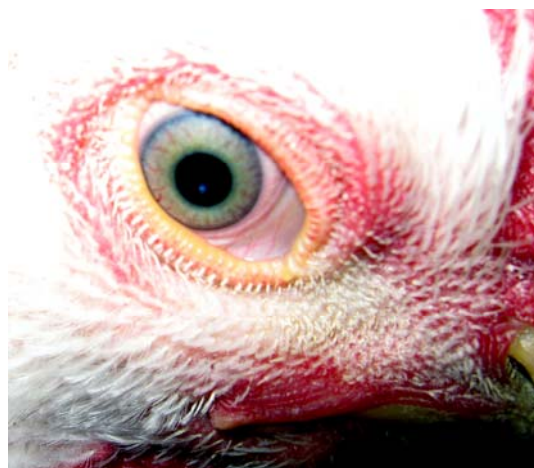### Serological findings

HI test was used to measure the antibody titer against H9N2 in the blood samples collected on days 0, 1, 3, 6, 9 and 15 PI. As shown in Table 3, the mean antibody titer was increased at 6 DPI and reached to  $2^{-9}$  at 15 DPI in the experimental group. There was no indication of any change in the antibody titer against H9N2 AI virus in the control chickens.

### Clinical signs, gross lesions and mortality

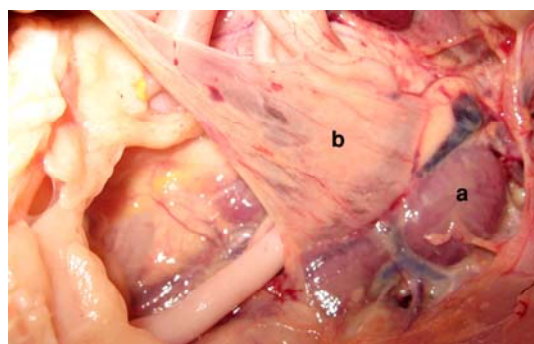
The clinical signs observed in the inoculated chickens were facial edema, conjunctivitis, depression, excessive lacrimation, ruffled feathers, decreased feed and water consumption, coughing, sneezing and swelling of infraorbital sinuses (Fig. 2). These signs were visible from day 3 PI (Table 3). Two birds showed cyanosis of

wattles and combs in this day. Diarrhea was also observed in a few birds. The most remarkable clinical signs were observed on day 6 PI. But on day 9 PI the number of chickens showing clinical signs reduced. The clinical signs disappeared at 15 DPI.



**Fig. 2: Swelling of the infraorbital sinuses and mild conjunctivitis in an infected chicken**

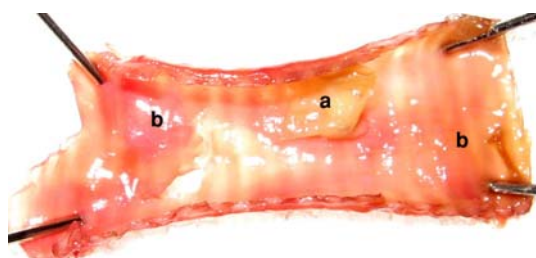
The lesions such as hemorrhage in small intestine, airsacculitis and swollen kidneys were observed in birds in the experimental group (Fig. 3). These lesions were most prominent at 6 DPI. The lesions in different organs at different DPI were shown in details in Table 3.



**Fig. 3: Swelling of the kidneys (a) and airsacculitis (b) of an infected chicken at 6 DPI**

The lesions such as congestion and hemorrhage in the tracheal mucosa, congestion of the lung, subcutaneous hemorrhage and hemorrhage in the pancreas, intestine and cloacal bursa were observed in bird died on day 2 PI. Gross lesions in bird died on day 6 PI were congestion of the trachea and fibrinous cast formation in this

organ (Fig. 4) which was extended into the primary bronchi. Fibrinopurulent air sacculitis and hemorrhage in Peyer's patches of the small intestine were also observed in this bird.



**Fig. 4: Fibrinonecrotic cast formation in the trachea (a) and diffuse congestion of tracheal mucosa (b) in the bird died on day 6 PI**

No clinical signs, gross lesions and mortality were observed in the uninfected control chickens.

## Discussion

The intra or extra cellular cleavage of the surface HA protein into the HA1 and HA2 subunit proteins, is essential for the AI viruses to be infectious and to produce multiple replication cycles. The HA protein of LPAI viruses is cleaved by trypsin-like enzymes found in restricted anatomical sites, especially respiratory and gastrointestinal (GI) tracts. As a result, LPAI viruses produce infections that are localized to the respiratory and GI tracts of chickens (Swayne and Halvorson, 2008).

In this study, the pathogenesis of the Iranian LPAI virus (H9N2), tissue tropism and dissemination of the virus throughout the body were evaluated following intranasal (IN) inoculation of commercial broiler chickens.

**Table 2: The results of virus detection from various organs of broiler chickens at different days post-inoculation with H9N2 AI virus**

Days post-inoculation(DPI)	Groups	Samples from euthanized birds						
		Trachea	Lungs	Kidneys	Spleen	Feces	Pancreas	Blood
1	E <sub>eu</sub>	0/5*	0/5	0/5	0/5	0/5	0/5	0/5
	C	0/2	0/2	0/2	0/2	0/2	0/2	0/2
3	E <sub>eu</sub>	2/5	1/5	2/5	1/5	0/5	0/5	0/5
	C	0/2	0/2	0/2	0/2	0/2	0/2	0/2
6	E <sub>eu</sub>	1/5	3/5	3/5	2/5	4/5	0/5	0/5
	C	0/2	0/2	0/2	0/2	0/2	0/2	0/2
9	E <sub>eu</sub>	0/5	0/5	5/5	0/5	0/5	0/5	0/5
	C	0/2	0/2	0/2	0/2	0/2	0/2	0/2
Total (days 1-9)	E <sub>eu</sub>	3/20	4/20	10/20	3/20	4/20	0/20	0/20
DPI		Samples from dead birds						
2	E <sub>d</sub>	0/1	0/1	1/1	0/1	0/1	0/1	ND
6	E <sub>d</sub>	1/1	1/1	0/1	1/1	1/1	0/1	ND
Total	E <sub>eu</sub> +E <sub>d</sub>	4/22	5/22	11/22	4/22	5/22	0/22	0/20

\* = No. of positive samples/total samples taken. E = Experimental group (the subscripts "eu" and "d" stands for euthanized and dead birds, respectively), C = Control group and ND = Not done

**Table 3: Clinical signs, gross lesions and antibody titer to H9N2 virus antigen in broiler chickens at different days post-inoculation with H9N2 AI virus**

	Days post-inoculation				
	1	3	6	9	15
Clinical signs	None	Mild	Moderate to severe	Mild	None
Gross lesions	None	H + C in T, C in L and As (1/5)* H in I (1/5) S of K (2/5)	H + C in T, C in L, and As (2/5) H in I (3/5) S of K (2/5) H in P (1/5)	As (1/5) S of K (3/5) H in I (1/5)	None
HI test (Log 2)	2	2	4	8	9

T = trachea, L = lung, K = kidney, I = intestine, P = pancreas, H = hemorrhage, C = congestion, As = air sacculitis, S = swelling. \* No. of positive samples/total samples

The clinical signs and gross lesions in this study were similar to lesions reported in naturally infected chickens with H9N2 (Naeem *et al.*, 1999; Pourbakhsh *et al.*, 2000; Nili and Asasi, 2002).

Previous laboratory experiments indicated that inoculation of chicken with waterfowl-origin influenza virus isolates has produced mortality and kidney lesions in chickens and adult hens (Slemons *et al.*, 1990b; Swayne *et al.*, 1994a; Swayne and Slemons, 1994b; Slemons and Swayne, 1995, 1990a). In another study no mortality was observed (Shalaby *et al.*, 1994), but mortality between 20 and 60% in the natural outbreaks of H9N2 in Iran was reported. However, in the experimental study, mortality was less than 20% (Nili and Asasi, 2003). In the current study 5% mortality was occurred in the experimental group. The necropsy findings in the chicken died at 6 DPI, were similar to the findings that have been described previously (Nili and Asasi, 2002).

We observed predominant infection in the respiratory tract between days 3 and 6 PI. In the urinary tract, predominant infection was observed between days 3 and 9 PI. Detection of the virus from the trachea, lungs and kidneys indicates that H9N2 AI virus is pneumotropic and nephrotropic following IN inoculation. Virus detection in the spleen could indicate virus tropism for the immune system. On day 6 PI the number of infected birds and also their organs with positive virus detection were more than the other experimental days. Kwon *et al.* (2008) reported that A/Chicken/HS/K5/01(H9N2) viral antigens were detected in the kidneys, spleen, trachea, lungs, thymus, bursa and cecal tonsils of three-week-old SPF chickens on day 5 post-inoculation. It has also been noted that H9N2 LPAI virus was detected and recovered from kidneys and spleen of experimentally infected 35-week-old commercial layers (Lee *et al.*, 2007). Shamseddini *et al.* (2002) detected Iranian H9N2 virus antigen in the trachea, lungs, and kidneys of experimentally infected 6-week-old Aryan broiler chickens using immunoperoxidase assay. In immunohistopathological study of experimentally infected 5-week-old SPF chickens with A/Chicken/Iran/259/1998(H9N2) virus, the

nucleoproteins of the virus were detected in the trachea, lungs and cecal tonsils of inoculated chickens (Hablolvarid *et al.*, 2004). In current study, the highest frequency of viral RNA detection from trachea was observed at 3 DPI (2/5) and from lung on day 6 PI (3/5).

Hablolvarid *et al.* (2003) identified nucleoproteins of A/Chicken/Iran/259/1998 (H9N2) virus in the pancreas following intravenous (IV) inoculation of 5-week-old chickens. Positive immunoreaction to AIV antigen and pathological changes was reported in the pancreas of chicks inoculated with H5N3 (Shinya *et al.*, 1995). However, in this study we did not recover the viral RNA in the pancreas following IN inoculation. It seems that IV challenge is necessary for LPAI viruses to distribute in pancreas.

Some chickens that had been infected by avian influenza viruses of low pathogenicity, isolated from wild birds, showed significant pathological changes confined to the kidneys (Swayne and Slemons, 1990; Hooper *et al.*, 1995). Other researchers recovered non pathogenic AI viruses from kidney tissues of chickens infected via intranasal/intraoral routes (Bosch *et al.*, 1979; Tsubokura *et al.*, 1981; Otsuki *et al.*, 1982) indicating that IV challenge is not necessary for strains of LPAI viruses to gain access to kidney tissues. Other natural infections or experimental IN studies in chickens have shown that some LPAI viruses could produce lesions in the kidneys of hens (Alexander and Gough, 1986; Ziegler *et al.*, 1999).

Shalaby *et al.* (1994) showed that A/Chicken/Alabama/7395/7(H4N8) had tissue tropism and pathogenicity for the respiratory and urogenital systems of laying hens. In their study, IN inoculation produced infection and lesion in respiratory system but they found systemic infection with major lesions in kidney following IV inoculation. Swayne and Slemons (1994b) reported that low-virulence avian-origin influenza viruses were nephrotropic during IV inoculation and pneumotropic during intratracheal (IT) and IN inoculation, but they did not find the virus antigens in the parenchyma of the kidney using immunohistochemistry technique. In another IN inoculation study in

chickens, LPAI virus was not identified in parenchymal cells of the kidneys (Swayne and Beck, 2005). In the current study, the frequency of virus recovery was generally higher for kidney tissues. All kidneys sampled on day 1 PI lacked the viral RNA but viral RNA was identified on days 2, 3, 6 and 9 PI (Table 2). We recovered the viral RNA from all of the kidney samples (5/5) on day 9 PI. However, the viral RNA was not found in any other tissues or samples at the same day. These data indicate that H9N2 has nephrotropic properties similar to previous reports (Shalaby, 1994; Swayne and Slemons, 1990, 1992b, 1994b; Swayne *et al.*, 1994a; Slemons and Swayne, 1992a, 1995). The most interesting observation was the ability of the virus to replicate in the kidney tissues while the antibody titers increased and most of the chickens became clinically normal. It seems that it would be necessary to collect the samples from kidney for longer time to evaluate the persistence of the virus in this organ.

In this study, viral RNA was not found in the blood of the inoculated chickens. Kwon *et al.* (2008) did not also detect the virus (K5/01) from peripheral blood mononuclear cells. Swayne and Beck (2005) reported that the LPAI viruses were not detected in blood and bone marrow of the infected birds. According to Shalaby *et al.* (1994), the respiratory tract can allow communication and transportation of infectious agents from outside of the body into the coelomic cavity. Therefore, isolation of the virus from kidneys may indicate that presumably, virus presentation in the kidney was resulted from a localized infection of the respiratory tract. However, detection of viral RNA from spleen on day 3 and 6 PI might be resulted from transient viremia. More frequent blood sampling after inoculation would be necessary to investigate the hematogenic spread of H9N2 virus. If this is true, a systemic infection could be hypothesized for this H9N2 AI virus and this could partly explain the reason of its high mortality in the field. To prove this hypothesis, the ability of replication of the virus in the organ with no trypsin-like enzymes must be investigated and the presence of the virus in the visceral organs must be quantified.

Kwon *et al.* (2008) detected virus antigens in cloacal swabs following IN inoculation on days 5 and 7 PI. Also, in other studies the virus was recovered from cloacal swabs following IV inoculation (Swayne *et al.*, 1994a; Slemons and Swayne, 1990a, 1992a, 1995). The possible source for the virus in the feces is viral replication in the kidney (Slemons and Swayne, 1990a). Although viral RNA was recovered from the kidneys (5/5) on 9 DPI, it was not detected in feces at the same day. Therefore, presence of the virus in feces only on day 6 (4/5) PI may be resulted from transient replication of the virus in GI tract.

On day 9 PI the virus was not detected from any organs except the kidneys and it might be resulted from increasing of the antibody titer in the blood.

This study revealed that H9N2 virus has tropism for the respiratory system (lung and trachea), immune system (spleen), urinary system (kidneys) and digestive system.

## Acknowledgement

This research was financially supported by Shiraz University Research Council.

## References

- Alexander, DJ (2002). Report on avian influenza in the Eastern hemisphere during 1997-2002. *Avian Dis.*, 47: 792-797.
- Alexander, DJ (2006). Summary of avian influenza activity in Europe, Asia, Africa and Australasia 2002-2006. *Avian Dis.*, 51: 161-166.
- Alexander, DJ and Gough, RE (1986). Isolation of influenza virus from birds in Great Britain. *Vet. Rec.*, 118: 537-538.
- Bosch, FX; Orlich, M; Klenk, HD and Rott, R (1979). The structure of the hemagglutinin, a determinant for the pathogenicity of influenza viruses. *Virology*. 95: 197-207.
- Burleson, FG; Chambers, TM and Wiedbrauk, DL (1992). *Virology, a laboratory manual*. London, United Kingdom, Academic Press, Inc., PP: 86-92.
- Cattoli, G; Drago, A; Maniero, S; Toffan, A; Bertoli, E; Fassina, S; Terregino, C; Robbi, C; Vicenzoni, G and Capua, I (2004). Comparison of three rapid detection systems for type A influenza virus on tracheal swabs for experimentally and naturally infected birds. *Avian Pathol.*, 33: 432-437.

- Fouchier, RA; Bestebroer, TM; Herfst, S; Van Der Kemp, L; Rimmelzwaan, GF and Osterhaus, AD (2000). Detection of influenza A viruses from different species by PCR amplification of conserved sequences in the matrix gene. *J. Clin. Microbiol.*, 38: 4096-4101.
- Hablolvarid, MH; Sohraby Haghdst, I; Pourbakhsh, SA and Gholami, MR (2003). A study on histopathologic changes in chicken following intravenous inoculation with avian influenza virus A/Chicken/Iran/259/1998 (H9N2). *Arch. Razi Inst.*, 55: 41-54.
- Hablolvarid, MH; Sohraby Haghdst, I; Pourbakhsh, SA and Gholami, MR (2004). Histopathological study of intranasally inoculated A/Chicken/Iran/259/1998(H9N2) influenza virus in chicken. *Arch. Razi Inst.*, 58: 51-62.
- Hooper, PT; Russell, PW; Selleck, PW and Stainislawek, WI (1995). Observation on relationship in chickens between the virulence of some avian influenza viruses and their pathogenicity for various organs. *Avian Dis.*, 39: 458-465.
- Kwon, JS; Lee, HJ; Lee, DH; Lee, YJ; Mo, IP; Nahm, SS; Kim, MJ; Lee, JB; Park, SY; Choi, IS and Song, ChS (2008). Immune responses and pathogenesis in immunocompromised chickens in response to infection with H9N2 low pathogenic avian influenza virus. *Virus Res.*, 133: 187-194.
- Lee, MS; Chang, PC; Shien, JH; Cheng, MC and Shien, HK (2001). Identification and subtype of avian influenza viruses by reverse transcription-PCR. *J. Virol. Methods.* 97: 13-22.
- Lee, YJ; Shin, JY; Song, MS; Lee, YM; Choi, JG; Lee, EK; Jeong, OM; Sung, HW; Kim, JH; Kwon, YK; Kwon, JH; Kim, CJ; Webby, RJ; Webster, RG and Choi, YK (2007). Continuing evolution of H9 influenza viruses in Korean poultry. *Virology.* 359: 313-323.
- Lee, CW; Song, CS; Lee, YJ; Mo, IP; Garcia, M; Suarez, DL and Kim, SJ (2000). Sequence analysis of the hemagglutinin gene of H9N2 Korean avian influenza viruses and assessment of the pathogenic potential of isolate Ms96. *Avian Dis.*, 44: 527-535.
- Li, KS; Xu, KM; Peiris, JS; Poon, LL; Yu, KZ; Yuen, KY; Shortridge, KF; Webster, RG and Guan, Y (2003). Characterization of H9 subtype influenza viruses from the ducks of southern China: a candidate for the next influenza pandemic in humans? *J. Virol.*, 77: 6988-6994.
- Liu, JH; Okazaki, K; Mweene, A; Shi, WM; Wu, QM; Su, JL; Zhang, GZ; Bai, GR and Kida, H (2004). Genetic conservation of hemagglutinin gene of H9 influenza virus in chicken population in Mailand China. *Virus Genes.* 29: 329-334.
- Mo, IP; Song, CS; Kim, KS and Rhee, JC (1997). An occurrence of non-highly pathogenic avian influenza in Korea. In: Swayne, D and Slemmons, R (Eds.), *Proceeding of the fourth international symposium on avian influenza (United States Animal Health Association)*. Rose Printing Company, Tallahassee, FL. PP: 379-383.
- Naeem, K; Ullah, A; Manvell, RJ and Alexander, DJ (1999). Avian influenza A subtype H9N2 in poultry in Pakistan. *Vet. Rec.*, 145: 560.
- Nili, H and Asasi, K (2002). Natural cases and an experimental study of H9N2 avian influenza in commercial broiler chickens of Iran. *Avian Pathol.*, 31: 247-252.
- Nili, H and Asasi, K (2003). Avian influenza (H9N2) outbreak in Iran. *Avian Dis.*, 47: 828-831.
- Otsuki, K; Kawaoka, Y; Nakamura, T and Tsubokura, M (1982). Pathogenicity for chickens of avian influenza viruses isolated from whistling swans and black-tailed gull in Japan. *Avian Dis.*, 26: 314-320.
- Pourbakhsh, SA; Khodashenas, M; Kianizadeh, M and Goodarzi, H (2000). Isolation and identification of avian influenza virus H9N2 subtype. *Arch. Razi Inst.*, 51: 27-38.
- Pregliasco, F; Mensi, C; Camorali, L and Anselmi, G (1998). Comparison of RT-PCR with other diagnostic assays for rapid detection of influenza viruses. *J. Med. Virol.*, 56: 168-173.
- Reed, LJ and Muench, H (1938). A simple method of estimating fifty percent endpoint. *Am. J. Hyg.*, 27: 493-497.
- Shalaby, AA; Slemmons, RD and Swayne, DE (1994). Pathological studies of A/Chicken/Alabama/7395/75(H4N8) influenza virus in specific pathogen free laying hens. *Avian Dis.*, 38: 22-32.
- Shamseddini, M; Vasfi Marandi, M; Pourbakhsh, SA; Gharagozlo, M; Bahmani-Nejad, M and Khazraee-Nia, P (2002). The use of indirect immunoperoxidase assay in diagnosis of type A (H9N2) avian influenza virus antigen on frozen tissue sections. *Arch. Razi Inst.*, 53: 11-21.
- Shinya, K; Awakura, A; Shimada, A; Silvano, FD; Umemura, T and Otsuka, K (1995). Pathogenesis of pancreatic atrophy by avian influenza A virus infection. *Avian Pathol.*, 24: 623-632.
- Slemmons, RD and Swayne, DE (1990a). Replication of a waterfowl-origin influenza virus in the kidney and intestine of chicken. *Avian Dis.*, 34: 227-284.



- Slemons, RD; Locke, LN; Sheerer, MG; Duncan, RM; Hishaw, VS and Easterday, BC (1990b). Kidney lesions associated with mortality in chickens inoculated with waterfowl influenza viruses. *Avian Dis.*, 34: 120-128.
- Slemons, RD and Swayne, DE (1992a). Nephrotropic properties demonstrated by A/Chicken/Alabama/75(H4N8) following intravenous challenge of chickens. *Avian Dis.*, 36: 926-931.
- Slemons, RD and Swayne, DE (1995). Tissue tropism and replicative properties of water fowl-origin influenza viruses in chickens. *Avian Dis.*, 39: 521-527.
- Swayne, DE and Beck, JR (2005). Experimental study to determine if low-pathogenicity and high-pathogenicity avian influenza viruses can be present in chicken breast and thigh meat following intranasal virus inoculation. *Avian Dis.*, 49: 81-85.
- Swayne, DE and Halvorson, DA (2008). Influenza. In: Saif, YM; Barnes, HJ; Fadl, AM; Glisson, JR; McDougald, LR and Swayne, DE (Eds.), *Disease of poultry*. (12th Edn.), Ames. Iowa, Iowa State University Press. PP: 153-184.
- Swayne, DE; Radin, MJ; Hoepf, TM and Slemons, RD (1994a). Acute renal failure as the cause of death in chickens following intravenous inoculation with avian influenza virus A/Chicken/Alabama/7395/75(H4N8). *Avian Dis.*, 38: 151-157.
- Swayne, DE and Slemons, RD (1994b). Comparative pathology of a chicken origin and two duck origin influenza virus isolated in chickens, the effect of route of inoculation. *Vet. Pathol.*, 31: 237-245.
- Swayne, DE and Slemons, RD (1990). Renal pathology in specific-pathogen-free chickens with a waterfowl-origin type A influenza virus. *Avian Dis.*, 34: 285-297.
- Swayne, DE and Slemons, RD (1992b). Evaluation of the kidney as a potential site of avian influenza virus persistence in chickens. *Avian Dis.*, 36: 937-944.
- Tajmanesh, S; Toroghi, R; Momayez, R; Pourbakhsh, SA (2006). Establishment of RT-PCR for detection of avian influenza virus (H9N2) in field cases compared to virus isolation method. *Arch. Razi Inst.*, 61: 111-116.
- Tsubokura, M; Otsuki, K and Yamamoto, H (1981). Isolation of Hswl Nav4 influenza virus from tufted duck (*Aythya fuligula*) in Japan. *Microbiol. Immunol.*, 25: 819-825.
- Vasfi Marandi, M and Bozorgmehrifard, MH (1999). An outbreak of non-highly pathogenic avian influenza in chickens in Iran. *Proceedings 61st meeting of world veterinary association*. France. CD-ROM.
- Ziegler, AF; Davison, S; Acland, H and Eckroade, RJ (1999). Characteristics of H7N2 (non pathogenic) avian influenza virus infections in commercial layers in Pennsylvania, 1997-98. *Avian Dis.*, 43: 142-149.