

Scientific Report

Fatal splenic rupture caused by an atypical malignant lymphoma in a Holstein cow

Movassaghi, A. R.^{1*} and Taghipour Bazargani, T.²

¹Center of Excellence in Ruminant Abortion and Neonatal Mortality, Department of Pathobiology, Faculty of Veterinary Medicine, Ferdowsi University of Mashhad, Mashhad, Iran; ²Department of Clinical Sciences, Faculty of Veterinary Medicine, University of Tehran, Tehran, Iran

***Correspondence:** A. R. Movassaghi, Center of Excellence in Ruminant Abortion and Neonatal Mortality, Department of Pathobiology, Faculty of Veterinary Medicine, Ferdowsi University of Mashhad, Mashhad, Iran. E-mail: armov@ferdowsi.um.ac.ir

(Received 24 Oct 2007; revised version 8 Jun 2008; accepted 31 Aug 2008)

Summary

Postmortem examination of a 5.5-year-old Holstein cow with history of sudden death showed a very huge spleen (120 × 45 × 10 cm) associated with severe haemoperitoneum. Histopathological findings included extensive infiltration of medium to large sized lymphocytic and lymphoblastic cells with small amounts of cytoplasm, round nuclei with coarsely granular chromatin in the spleen, and limited foci of similar cellular infiltration in the liver. This case was diagnosed as a fatal splenic rupture caused by an atypical malignant lymphoma.

Key words: Spleen, Malignant lymphoma, Haemoperitoneum, Cow

Introduction

Pathologic rupture of the spleen in haematologic malignancies is rare (Giagounidis *et al.*, 1996) and may occur in any species with only minor trauma if the spleen is enlarged and the capsule thinned. The latter pathogenesis may occur in splenomegaly with any cause including congestive, haemolytic, infectious, or neoplastic types (Valli, 1993). Splenic rupture has been reported in salmonellosis and amyloidosis (Rest *et al.*, 1985; Khan *et al.*, 2003). The spleen is expected to be involved in systemic malignancies of the lymphoid system, but this is not always the case. Although the spleen may not be involved in lymphoma, it is much more likely to be involved in lymphoid and myeloid leukaemia (Valli, 1993). In this paper, we describe a case of fatal splenic rupture due to an atypical malignant lymphoma in a Holstein cow.

Case history and histopathological findings

The carcase of a 5.5-year-old Holstein cow was presented for postmortem examination because of sudden death. The animal had not showed any signs of disease or abnormality in her recent history.

The mucous membranes were pale at necropsy. There was large amount of haemoperitoneum in the abdominal cavity, and the spleen was markedly and diffusely enlarged with oozing blood when incised. The huge spleen was located between diaphragm and pelvic region. The size of the spleen (120 × 45 × 10 cm) was about 25 times its normal size. There were subcapsular splenic ruptures and splenic parenchyma showed bulging at the cut surface (Fig. 1). The liver was firm with three pale grey-white nodules (approximately 6 cm in diameter) on the diaphragmatic surface. No other gross

abnormalities were found. Samples of lung, spleen, kidney, liver, heart, colon, urinary bladder, mesenteric lymph nodes, small intestine, abomasum, and uterus were fixed in 10% buffered formalin, embedded in paraffin, and 6- μ m sections were stained with haematoxylin and eosin. The samples were then examined histologically.

Histopathological examination revealed extensive infiltration of medium to large sized lymphocytic and lymphoblastic cells with small amounts of cytoplasm, round nuclei with coarsely granular chromatin in the spleen (Fig. 2). There was diffuse infiltration of the red pulp with a dense population of neoplastic lymphoid cells resulted in the complete derangement of the normal architecture of the spleen. Infiltration of neoplastic lymphocytes was found in the sample of liver. There were approximately 1-2 mitoses per high power field. The histopathologic diagnosis was atypical malignant lymphoma.

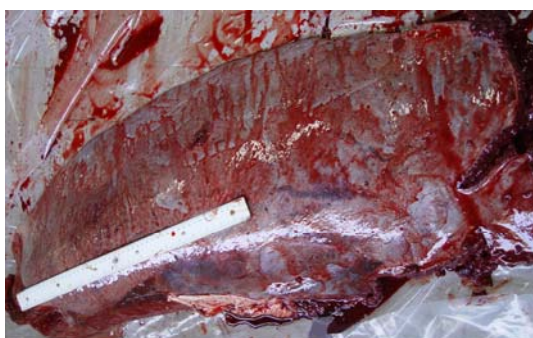

Fig. 1: Remarkable splenic enlargement led to fatal internal haemorrhage

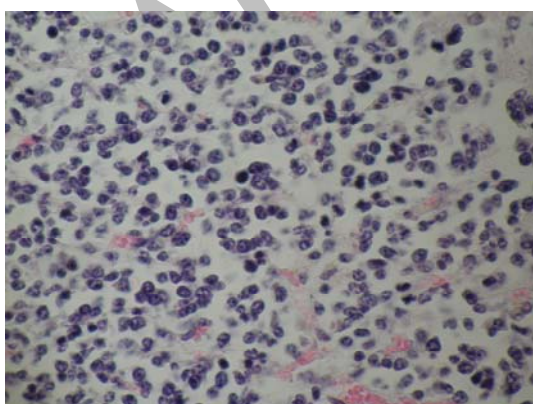


Fig. 2: Diffuse infiltration of neoplastic cells with hyperchromatic nuclei and small amount of cytoplasm. Nucleoli are prominent associated with atypical mitoses, (H&E, \times 640)

Discussion

Pathological or spontaneous rupture of the spleen has been described in a variety of diseases affecting the spleen, with infections being cited as the cause in most cases. It is a rare event in haematological malignancies despite the frequent involvement of the spleen in these diseases as a lymphoproliferative disorder. It has, however, been described in patients with acute and chronic leukaemia, Hodgkin's disease, non-Hodgkin's lymphoma of B-cell origin, mycosis fungoides, and so-called histiocytic lymphoma (Schiodt *et al.*, 2000; Strickland *et al.*, 2001; Mason and Juneja, 2003). Lymphatic cancer also known as several terms, including leukaemia, leukosis, lymphosarcoma, and malignant lymphoma, is a malignant neoplastic disease of the lymphoreticular system in cattle (Evermann *et al.*, 1987; Johnson and Kaneene, 1992; Howard and Smith, 1999). Lymphosarcoma in cattle is classified into 2 major epidemiological and aetiological subgroups: enzootic bovine leukosis and sporadic bovine leukosis.

Enzootic bovine leukosis affects primarily adult cattle (3-7 years old) and is virally induced (Radostits *et al.*, 2000; Hendrick, 2002). Bovine leukaemia virus (BLV) is an oncogenic type C retrovirus that integrates as a provirus into the host DNA. The disease is characterized by chronic low-grade viraemia and a long latency period (Evermann *et al.*, 1987; Johnson and Kaneene, 1992; Radostits *et al.*, 2000). It is transmitted horizontally by direct contact, including natural breeding and accidental transmission by contaminated needles, ear-tagging and dehorning equipment, and by the use of whole-blood vaccines (Valli, 1993).

The location of tumors is unpredictable, but frequent sites are lymph nodes, heart, abomasum, kidney, spleen, uterus, lumbar spinal cord, and retrobulbar lymphatic tissue. The most obvious clinical signs of lymphosarcoma are enlargement of peripheral lymph nodes or exophthalmus due to tumors in the posterior orbit (Howard and Smith, 1999). Superficial lymph node enlargement occurs in 75 to 90% of cases,

and rectal palpation often reveals visceral node involvement (Malatestinic, 2003). The unusual findings in this case of malignant lymphoma were remarkable enlargement of the spleen and the absence of lesions in peripheral lymph nodes and other organs. Some cows die rapidly because of splenomegaly with rupture and abdominal haemorrhage (Valli, 1993). A case of *Salmonella dublin* infection presenting as pathologic rupture of the spleen has been reported. Because the incidence of salmonellosis is increasing, the importance of operative and tissue cultures in cases with subcapsular splenic haemorrhage and splenic rupture is stressed (Rest *et al.*, 1985). Spontaneous rupture is the main, potentially lethal complication found in 25% of the diffuse splenic angiomatosis (Neumann *et al.*, 1999). Splenic rupture occurs at different stages of splenic infiltration by Hodgkin's disease in human (Brissette and Dhru, 1992). It seems that, apart from splenic infiltration by a haematologic disease, splenic infarcts and coagulation disorders (which have been previously advanced as the most important pathophysiologic factors leading to rupture), male sex, adulthood, severe splenomegaly, and cytoreductive chemotherapy may increase the risk of pathologic splenic rupture (Giagounidis *et al.*, 1996).

In conclusion, malignant lymphoma should be considered as a potential cause of splenic rupture and sudden death, particularly in areas with endemic leukosis. The authors believe, this is the first reported case of such splenic enlargement and rupture in cattle caused by an atypical malignant lymphoma.

Acknowledgements

This study was supported by Excellence Centre for Ruminant Abortion and Neonatal Mortality, Faculty of Veterinary Medicine, Ferdowsi University of Mashhad, Mashhad, Iran.

References

Brissette, M and Dhru, RD (1992). Hodgkin's disease presenting as spontaneous splenic rupture. *Arch. Pathol. Lab. Med.*, 116: 1077-

- 1079.
- Evermann, JF; DiGiacom, RF and Hopkins, SG (1987). Bovine leukosis virus: understanding viral transmission and method of control. *Vet. Med.*, 82: 1051-1058.
- Giagounidis, AA; Burk, M; Meckenstock, G; Koch, AJ and Schneider, W (1996). Pathologic rupture of the spleen in hematologic malignancies: two additional cases. *Ann. Hematol.*, 73: 297-302.
- Hendrick, SH (2002). Atypical sporadic bovine leukosis in a feedlot heifer. *Can. Vet. J.*, 43: 617-619.
- Howard, JL and Smith, RA (1999). *Current veterinary therapy 4, Food animal practice*. 4th. Edn., Philadelphia, W. B. Saunders Co., PP: 296-299.
- Johnson, R and Kaneene, JB (1992). Bovine leukemia virus and enzootic bovine leukosis. *Vet. Bull.*, 62: 287-288.
- Khan, AZ; Escofet, X; Roberts, KM and Salman, AR (2003). Spontaneous splenic rupture-a rare complication of amyloidosis., *Swiss Surg.*, 9: 92-94.
- Mason, KD and Juneja, SK (2003). Spontaneous rupture of the spleen as the presenting feature of the blastoid variant of mantle cell lymphoma. *Clin. Lab. Haematol.*, 25: 263-265.
- Malatestinic, A (2003). Bilateral exophthalmus in a Holstein cow with lymphosarcoma. *Can. Vet. J.*, 44: 664-666.
- Neumann, J; Ambrosius, C and Zirngibl, H (1999). Spontaneous splenic rupture with diffused angiomatosis of the spleen. *Chirurg.*, 70: 800-802.
- Radostits, OM; Gay, CC; Blood, DC and Hinchcliff, KW (2000). *Veterinary medicine. A textbook of the diseases of cattle, sheep, pigs, goats and horses*. 9th Edn., London, W. B. Saunders Co, PP: 1046-1058.
- Rest, JG; Seid, AS; Rogers, D and Goldstein, EJ (1985). Pathologic rupture of the spleen due to *Salmonella dublin* infection. *J. Trauma*. 25: 366-368.
- Schioldt, I; Duun, E; Fischer, TK; Christiansen, AP and Ralfkiaer, E (2000). Fatal rupture of the spleen caused by infiltration of T-cell lymphoma. *Ann. Hematol.*, 79: 158-160.
- Strickland, AH; Marsden, KA; McArdle, J and Lowenthal, RM (2001). Pathologic splenic rupture as the presentation of mantle cell lymphoma. *Leukemia and Lymphoma*. 41 (1-2): 197-201.
- Valli, VEO (1993). The hematopoietic system. In: Jubb, KVF; Kennedy, PC and Palmer, N (Eds.), *Pathology of domestic animals*. (4th Edn.), Vol. 3, San Diego, Academic Press, Inc., PP: 232-233.