

## Short Paper

# Histopathological study of naturally occurring ovine pulmonary adenocarcinoma in native goat in Khuzestan, Iran

Sayyari, M.<sup>1\*</sup> and Mohamadian, B.<sup>2</sup>

<sup>1</sup>Department of Pathobiology, School of Veterinary Medicine, Shiraz University, Shiraz, Iran; <sup>2</sup>Department of Pathobiology, Faculty of Veterinary Medicine, Shahid Chamran University of Ahvaz, Ahvaz, Iran

\*Correspondence: M. Sayyari, Department of Pathobiology, School of Veterinary Medicine, Shiraz University, Shiraz, Iran. E-mail: sayyari@shirazu.ac.ir

(Received 25 Dec 2011; revised version 19 Jun 2012; accepted 14 Aug 2012)

## Summary

Sheep (ovine) pulmonary adenocarcinoma (SPA), also known as ovine pulmonary adneomatosis (OPA), jaagsiekte and ovine pulmonary carcinoma (OPC) is a contagious lung tumor in sheep and, more rarely, in goats. This study was carried out in Khuzestan, in the southwest of Iran for a period of six months. A total number of 3985 native breed goats were clinically inspected and postmortem examination was recorded at the abattoir in Ahvaz. In necropsy 4 of these goats showed gross pulmonary lesions characteristic of classical pulmonary adenomatosis. The lungs were usually heavy and appeared "waterlogged", but affected areas of the lungs were solid and light grey in color, and tissue looked slightly translucent. The cut surface showed numerous small, slightly-elevated white-grey nodules in each section. The affected alveoli in these areas were lined by proliferating cuboidal cells forming irregular folds and papillary projections. The bronchi and the bronchioles exhibited moderate epithelial hyperplasia and metaplasia. The bronchial associated lymphoid tissue and the smooth muscles of terminal and respiratory bronchioles were hyperplastic. The affected areas were essentially the same and also nearly similar to previous reports.

**Key words:** Ovine pulmonary adneomatosis, Goats, Lymphoid hyperplasia, Lung, Iran

## Introduction

Sheep (ovine) pulmonary adenocarcinoma (SPA), also known as ovine pulmonary adneomatosis (OPA), jaagsiekte (driving sickness), and ovine pulmonary carcinoma (OPC) is a contagious lung tumor in sheep, and more rarely, in goats. Reports of lesions of adenomatosis in goat are few. The first description of the disease came from South Africa in 1837 (MacFadyean, 1938; Tustin, 1969). Since then it has been reported in most European countries, as well as the Asian and American continents (McGavin and Zachary, 2007). It has been clearly demonstrated that OPA is caused by a beta-retrovirus, jaagsiekte sheep retrovirus (JSRV), which cannot be cultured *in vitro* yet, but the virus has been cloned and sequenced (Palmarini and Fan, 2001;

Griffiths *et al.*, 2010). Jaagsiekte sheep retrovirus has constantly been detected in the lung fluid, tumor, peripheral blood mononuclear cells, and lymphoid tissues of sheep affected by OPA or those unaffected but in contact with flock mates (De Martini *et al.*, 1985; Palmarini and Fan, 2001). Sheep at all ages are susceptible, but clinical signs are generally seen in mature sheep between 2- and 4-year-old because of the long incubation period (Tustin, 1969; Griffiths *et al.*, 2010). In affected animals a quantity of copious, thin mucoid fluid (up to 200 ml), presumably produced by the neoplastic cells in the lung, pours from the nostrils. Early gross lesions are enlarged, heavy (two to three times more than normal), and wet lungs which contain several firm, gray or light purple, variably-sized nodules that are separated from normal

parenchyma by a narrow zone of emphysema (Sharp and De las Heras, 2002; Wootton *et al.*, 2005). Two pathological forms of OPA are currently recognized: classical and atypical. In the classical forms, the neoplastic lesions occur particularly in the cranioventral parts of all lung lobes. Atypical forms tend to be more nodular in both early and advanced tumors (De las Heras *et al.*, 2003; García-Goti *et al.*, 2000). Few studies have been carried out on OPA in Iran. Kojouri and Karimi (2002) reported an occurrence of OPA in about 3% of sheep of more than 3-year-old. Khodakaram-Tafti and Razavi (2010) reported OPA in 0.22% of 9400 sheep killed at abattoir in Fars province. The present investigation was undertaken to study the pathological lesions of two classical and atypical forms of naturally occurring PA in goat in Khuzestan, Iran.

## Materials and Methods

An abattoir survey was conducted on 3985 clinically healthy goats slaughtered in Ahvaz municipality, Khuzestan. Routine meat inspection procedures were used to detect the presence of the pathological lesions. The animals were mostly between 5 months to 6-year-old. Macroscopic lesions of 100 (39.85%) suspected lungs were recorded. Macroscopic examination was a superficial observation of the lungs, especially on the visceral and diaphragmatic surfaces. Four out of 100 lungs were diagnosed as pulmonary adenomatosis. Gross appearance of lesions, particularly in cross section was atypical form of OPA. Samples about 0.5-1.5 cm in diameter from each lung were taken for microscopic examination. The samples were fixed by formalin (10%) and sections of 3-5 mm thickness were processed to prepare 7 micron sections. Paraffin method was used and followed by Haematoxylin and eosin staining (H&E) and the sections were examined under microscope (Bancroft and Marilyn, 2007).

## Results

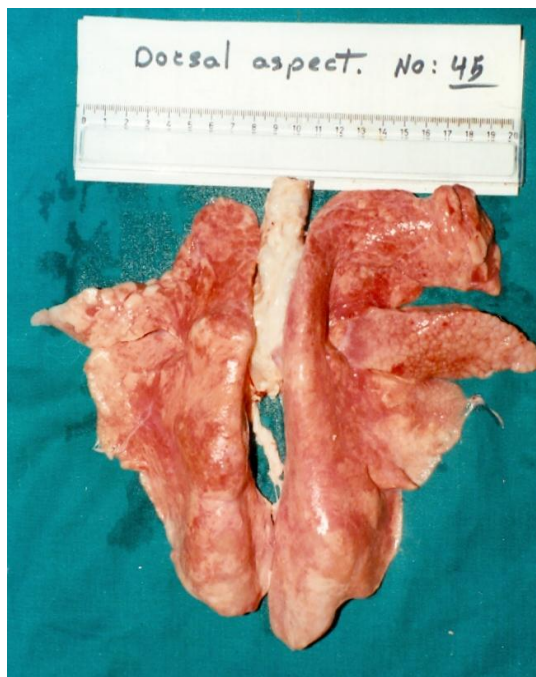The lungs were usually very heavy and

appeared “waterlogged”, but the affected areas of the lungs were solid and light grey in color, and the tissues looked slightly translucent. The lungs, particularly the ventral portion or diaphragmatic lobes, were often enormously enlarged. Histopathological changes in the affected areas were essentially the same in all 4 goats. Consolidated foci with a diameter of 0.5 to 3 cm were observed on the lung surface (Fig. 1). The cut surface showed numerous small, slightly-elevated white-grey nodules in each section. The gross lesions in the affected areas were essentially the same in all 4 goats. The nodules were surrounded by narrow emphysematous zones which were infiltrated by tiny translucent grey or reddish-grey foci of about 2-5 cm in size. Histologically, lesions were categorized into ten types: interstitial pneumonia 21 (2.1%), parasitic pneumonia 19 (1.9%), purulent pneumonia 5 (0.5%), bronchopneumonia 13 (1.3%), pulmonary adenomatosis 4 (0.4%), hydatid cyst 27 (2.7%), pleurisy 3 (0.3%), pigmentation 6 (0.6) and hemorrhage 2 (0.2%). The affected alveoli in these areas were lined by proliferating cuboidal cells forming irregular folds and papillary projections. The alveoli contained few macrophages and lymphocytes (Figs. 2 and 3). The bronchi and the bronchioles exhibited moderate epithelial hyperplasia and metaplasia. The bronchial associated lymphoid tissue and the smooth muscles of terminal and respiratory bronchioles were hyperplastic. The alveolar septa were diffusely expanded by lymphocytes, which occasionally formed multifocal interstitial and perivascular aggregates.

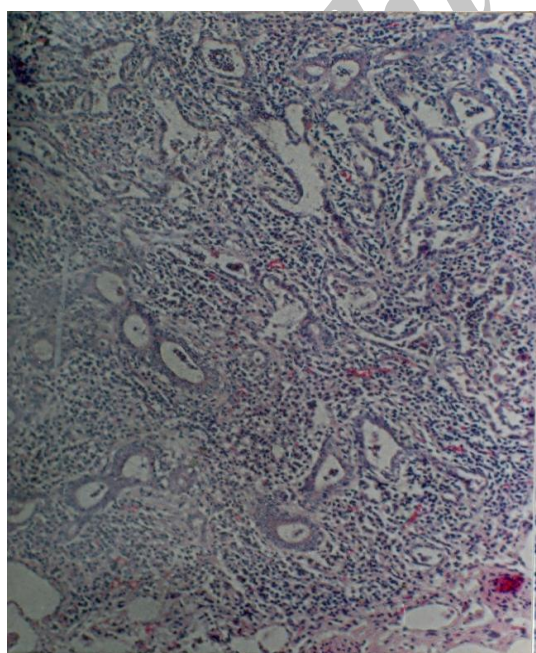
## Discussion

In Khuzestan there are 2.9 million sheep, and 1.7 million goats (Iranian Veterinary Organization, 2009). Previous serological and pathological investigation showed that pneumonia is an important sheep disease in Khuzestan (Sayyari and Lotfi, 2001). This report is the first report about pulmonary adenomatosis in goat in Khuzestan. In Iran, Kojouri and Karimi (2002) have reported ovine pulmonary adenomatosis in Chahar-Mohal Bakhtiari province. On the basis of

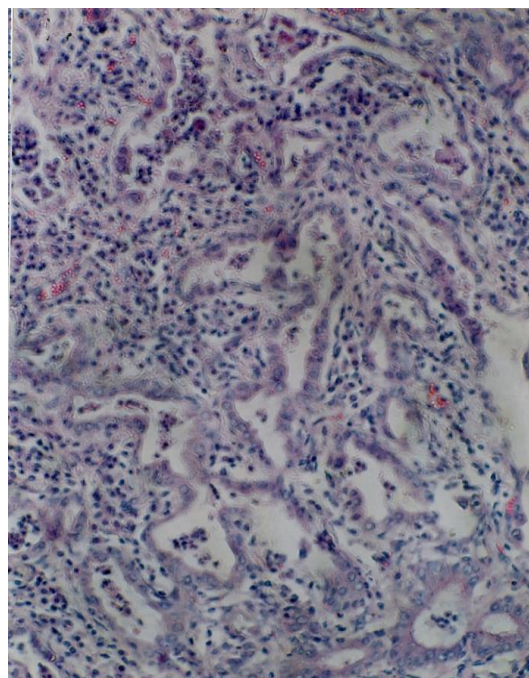
abattoir survey in Fars province Khodakaram-Tafti and Razavi (2010) reported two forms of the disease occurrence of about 0.22%. The form of classical



**Fig. 1:** Pulmonary adenomatosis, dorsal view of goat lung (enlarged, light grey, edematous). Affected by classical form of diaphragmatic, middle and apical lobes shows grayish-white nodules



**Fig. 2:** Metaplasia of epithelial cell to columnar, peribronchiolar lymphocytic tissue associated with thickened alveolar septa, (H&E, ×50)



**Fig. 3:** Atypical form of pulmonary adenomatosis, typical columnar epithelial cells lining affected alveoli with acinar and papillary growth, (H&E, ×250)

disease was reported in many other countries (Dungal *et al.*, 1938; Cuba-Caparo *et al.*, 1961; Cultip and Young, 1982; De Martini *et al.*, 1985; Sharp and Angus, 1990; Al-Hizab and Abdelsalam, 2005; Woldemeskel and Tibbo, 2010). In the reports, the classical form of pulmonary adenomatosis has been well-recognized. Unlike the classical form of PA, there are few reports of atypical PA in the literature. Results from our study are similar to findings of other researchers (De las Heras *et al.*, 1995; García-Goti *et al.*, 2000; Khodakaram-Tafti and Razavi, 2010). According to De las Heras *et al.* (1992), these neoplastic forms constitute “atypical” OPA. The histopathological features of these tumors are essentially the same as those of the classical ones, but the stroma of the tumors usually appears heavily infiltrated by mononuclear inflammatory cells and connective tissues. The authors indicated that the distinction between classical and atypical OPA cases is not always clear. Sometimes both forms are present in the same lung and some cases apparently represent intermediate stages between the classical and atypical tumors (Al-Hizab and Abdelsalam, 2005; García-Goti *et al.*, 2000; Khodakaram-Tafti and

Razavi, 2010). It is apparent that early tumor lesion develops close to the bronchioles. In this area both the epithelial lining of the bronchioli and the alveolar septa seem to be affected simultaneously. In the present study, the inflammatory cells were monocyte macrophage, lymphocyte, and polymorphonuclear leukocytes. The prominent reaction found in the affected lungs was the hyperplasia of the peribronchiolar lymphatic tissue aggregates. Because of the lymphatic aggregation around bronchiole, the size of bronchi had decreased and, due to the hyperplasia induced pressure, the alveoli around bronchi had disappeared. However, an interesting finding was the hyperplasia of smooth muscle cells in the interstitial tissues. In the present study, distinctive histopathological lesions typical of OPA were found in the lungs of the 4 goats. The affected areas were essentially the same and also nearly similar to previous reports (Sharp and Angus, 1990; Kojouri and Karimi, 2002; Khodakaram-Tafti and Razavi, 2010; Woldemeskel and Tibbo, 2010). The affected alveoli in these areas were lined by proliferating cuboidal cells forming irregular fold and papillary projections. According to Sharp and Angus (1990), and Palmarini and Fan (2001), no differences have been observed between the macroscopic and microscopic lung lesions in goats and sheep so far. Robert *et al.* (1996), Al-Dubaib (2005), and Al-Hizab and Abdelsalam (2005) also reported similar histological findings (nodular lesions, papilliform projection, peribronchiolar lymphid). The result of gross and histological examination in the present study is in line with the abattoir observations reported by Kojouri and Karimi (2002), and Khodakaram-Tafti and Razavi (2010). Distinctive histopathological lesions typical of PA were found in the lung of the 4 goats. These animals originated from different locations in Khuzestan. The high percentage of lesions due to pneumonia lesions observed in the other ruminants warrant further study to elucidate the causative factors (Sayyari and Sharma, 2011). Factors such as insufficient feed intake, hot and humid weather conditions and gas emissions from oil rigs might be influential.

In conclusion, this study showed no

differences between sheep and goat cases with regards to clinical signs, gross and histopathologic lesions.

## Acknowledgements

The authors appreciate the financial support of Shahid Chamran University of Ahvaz, Iran. We also would like to thank Mrs Masbogh and Mr Zalaky for their technical assistance.

## References

- Al-Dubaib, MA (2005). Renal and cardiac metastases of jaagsiekte-like tumor in a goat. *Small Rum. Res.*, 58: 75-78.
- Al-Hizab, FA and Abdelsalam, EB (2005). Adenomatous lesion in a pneumonic lung of a local indigenous Saudi goat. *Pak. J. Biol. Sci.*, 4: 542-545.
- Bancroft, JD and Marilyn, G (2007). *Theory and practice of histological techniques*. 6th Edn., UK, Elsevier-Health Sciences Division. PP: 250-260.
- Cuba-Caparo, A; Delavega, E and Copaira, H (1961). Pulmonary adenomatosis of sheep: metastazing bronchiolar tumors. *Am. J. Vet. Res.*, 22: 673-682.
- Cutlip, RC and Young, S (1982). Sheep pulmonary adenomatosis (Jaagsiekte) in the United State. *Am. J. Vet. Res.*, 43: 2108-2113.
- De las Heras, M; Calafat, JJ; Jaime, JM; Garcia de Jalon, JA; Ferrer, LM; García-Goti, M and Minguijon, E (1992). Sheep pulmonary adenomatosis (jaagsiekte) in slaughtered sheep: variation in pathological characteristics. *Med. Vet.*, 9: 52-53.
- De las Heras, M; González, L and Sharp, JM (2003). Pathology of ovine pulmonary adenocarcinoma. *Curr. Top. Microbiol. Immunol.*, 275: 25-45.
- De las Heras, M; Minguinjón, E; Ferrer, LM; Perez, V and Bolea, R (1995). Adenomatosis pulmonary ovina (jaagsiekte): células que infiltran el tumor y modificaciones en ganglios linfáticos regionales. *Med. Vet.*, 12: 32-38.
- De Martini, JC; Snyder, SP and Ameghino, EF (1985). Sheep pulmonary adenomatosis in Peru: epidemiological and ultrastructural studies. In: Sharp, JM and Hoff-Jorgensen, R (Eds.), *Slow virus in sheep, goat, cattle*. (1st Edn.), Luxembourg, Commission of the European Communities. PP: 333-343.
- Dungal, N; Gislason, G and Taylor, EL (1938).

- Epizootic adenomatosis in the lungs of sheep: comparisons with jaagsiekte, verminous pneumonia and progressive pneumonia. *J. Comp. Pathol. Therap.*, 51: 46-68.
- García-Goti, M; González, L; Cousens, C; Cortabarría, N; Extramiana, AB; Minquijón, E; Ortín, A; De las Heras, M and Sharp, JM (2000). Sheep pulmonary adenomatosis: characterization of two pathological forms associated with jaagsiekte retrovirus. *J. Comp. Pathol.*, 122: 55-65.
- Griffiths, DJ; Martineau, HM and Cousens, C (2010). Pathology and pathogenesis of ovine pulmonary adenocarcinoma. *J. Comp. Pathol.*, 142: 260-283.
- Iranian Veterinary Organization (2009). Diseases report. Chapter 3. PP: 12-18.
- Khodakaram-Tafti, A and Razavi, Z (2010). Morphopathological study of naturally occurring ovine pulmonary adenomatosis in sheep in Fars province, Iran. *Iranian J. Vet. Res.*, 13: 134-138.
- Kojouri, GHA and Karimi, I (2002). Sheep pulmonary adenomatosis: a study on prevalence and pathological findings. *Pajouhesh-va-Sazandegi*. 53: 64-67 (in Persian).
- MacFadyean, J (1938). Jaagsiekte. *J. Comp. Pathol.*, 51: 78-87.
- McGavin, MD and Zachary, IF (2007). *Pathologic basis of veterinary disease*. 4th Edn., St. Louis, Missouri, Mosby-Elsevier Inc., PP: 551-552.
- Palmarini, M and Fan, H (2001). Retrovirus-induced ovine pulmonary adenocacinoma, an animal modle for lung cancer. *J. Natl. Cancer Inst.*, 93: 1603-1614.
- Robert, G; Tamas, M; Vilmos, P and Miklos, T (1996). Pulmonary adenomatosis in a goat (Hungry). *Magyar Allatorvosok Lapia.*, 10: 582-584.
- Sayyari, M and Lotfi, M (2001). Serological and pathological study of maedi in sheep's lung in Ahwaz. *J. Vet. Med.*, 56: 91-94.
- Sayyari, M and Sharma, M (2011). Pathological and bacteriological study of lobe distribution of lesions in buffalo (*Bubalus bubalis*). *Int. J. Vet. Res.*, 2: 124-128.
- Sharp, JM and Angus, KW (1990). Sheep pulmonary adenomatosis: clinical pathological and experimental aspect. In: Petursson, G and Hoff-Jorgensen, R (Eds.), *Maedi-Visna and related diseases*. Boston, Kluwer Academic Publishers. PP: 157-175.
- Sharp, JM and De las Heras, M (2002). Contagious respiratory tumors. In: Martin, WB and Aitken, ID (Eds.), *Diseases of sheep*. (2nd Edn.), Oxford, Blackwell Scientific Publications. PP: 143-150.
- Tustin, RC (1969). Ovine jaagsiekte. *J. Sout. Afr. Vet. Med. Assoc.*, 40: 2-23.
- Woldemeskel, M and Tibbo, M (2010). Pulmonary adenomatosis and maedi-visna in Ethiopian central highland sheep: a microscopic study. *Trop. Anim. Heath Prod.*, 42: 995-999.
- Wootton, SK; Halbert, CL and Miller, AD (2005). Sheep retrovirus structural protein induces lung tumours. *Nature*. 434: 904-907.