

Scientific Report

First detection of *Sarcocystis hirsuta* from cattle in Iran

Shekarforoush, S. S.^{1*}; Razavi, S. M.²
and Abbasvali, M.³

¹Department of Food Hygiene and Public Health, School of Veterinary Medicine, Shiraz University, Shiraz, Iran; ²Department of Pathobiology, School of Veterinary Medicine, Shiraz University, Shiraz, Iran; ³Department of Food Hygiene, Faculty of Veterinary Medicine, Shahrekord University, Shahrekord, Iran

*Correspondence: S. S. Shekarforoush, Department of Food Hygiene and Public Health, School of Veterinary Medicine, Shiraz University, Shiraz, Iran. E-mail: shekar@shirazu.ac.ir

(Received 16 Apr 2012; revised version 19 Jan 2013; accepted 6 Mar 2013)

Summary

Although the high infection rate of microscopic sarcocyst occurs in cattle, to the best of our knowledge, there is no report about the identification of macroscopic sarcocyst in Iran. In this work, *Sarcosystis hirsuta* was first isolated from slaughtered cattle. In a 2-year-old slaughtered cattle, morphological examination revealed 3-5 mm in length cysts distributed in different striated muscles, particularly intercostalis and diaphragm. In electron microscopy study, ultramicroscopic structure of primary cyst wall based on the presence of cone-shaped villar protrusions confirmed the occurrence of *S. hirsuta*.

Key words: *Sarcosystis hirsute*, Cattle, Iran

Introduction

Sarcocystis species are widely distributed in a variety of mammals and birds (Neva and Brown, 1994). All species have a two-host life cycle with carnivores as definitive hosts and herbivores as intermediate hosts (Soulsby, 1982).

Different species of *Sarcocystis* such as *S. bovi hominis* (*S. hominis*), *S. bovicanis* (*S. cruzi*) and *S. bovifelis* (*S. hirsuta*) have been reported in cattle, elsewhere (Dubey *et al.*, 1989a). Several attempts have been directed at studying the prevalence rate of infection in different food animal species such as cattle (Shekarforoush *et al.*, 2004; Bonyadian and Meshki, 2006; Hamidinejat *et al.*, 2010), goat (Shekarforoush *et al.*, 2005; Mirzaei Dehaghi *et al.*, 2011), sheep (Oryan *et al.*, 1996; Razavi *et al.*, 2003) and camel (Shekarforoush *et al.*, 2006) and a few studies identified different species of *Sarcocystis* in food animals in Iran (Oryan *et al.*, 1996; Dalimi *et al.*, 1999; Nourani *et al.*, 2010).

Several methods have been conducted

for species identification of *Sarcocystis*, from which, ultrastructure of primary cyst wall has been developed in detail (Dubey *et al.*, 1989b).

To the best of our knowledge, there is no report about occurrence of *S. hirsuta* from cattle in Iran.

Materials and Methods

In a 2-year-old cow slaughtered at Shiraz slaughterhouse, in the southern part of Iran, numerous unusual macroscopic cysts were identified. The cysts were 3-5 mm in length and distributed in different striated muscles particularly intercostalis and diaphragm.

The muscle cysts were examined using impression smear method by pressing cut surfaces on a slide, fixing with absolute methanol and staining by giemsa (10% v/v stock solution) to observe free bradyzoites under light microscope.

A part of the tissue samples including cysts and surrounding tissues were fixed in 2.5% glutaraldehyde. The specimens were washed in 0.1% phosphate buffer, post fixed

in 1% osmium tetroxide, dehydrated through a graded ethanol series and epoxy propane and embedded in TAAB resin. The ultra thin sections were cut in transverse and longitudinal, stained with uranyl acetate and lead citrate. The electron micrographs were carefully observed under transmission electron microscope (Philips CM10).

Results and Discussion

Several macroscopic sarcosysts in diaphragm were shown in Fig. 1. The cysts contained numerous banana-shaped bradyzoites in light microscopic examination. In the ultra structural view, the inner cyst wall thickness varies 1.56-1.78 μm , formed by continuous line of osmiophilic granules. The conical-shaped villar protrusions arise from a constricted base (0.37-0.66 μm) from the interior envelope with 1.94-2.82 μm length, obviously tapering distally. Several long microfilaments are present in protrusions core (Figs. 2 and 3). All the above criteria confirmed the occurrence of *S. hirsute* based on the keys presented by Dubey *et al.* (1989a, b) and Odening *et al.* (1994).

A high prevalence of microscopic sarcocysts was previously reported in cattle from Iran (Shekarforoush *et al.*, 2004; Nourani *et al.*, 2010).

The present study reports the first occurrence of macroscopic sarcocyst (*S. hirsuta*) in cattle from Iran. The microscopic ones (*S. cruzi* and *S. hominis*) are transmitted to cattle by ingesting infective sporocyst shed by dogs and human beings, respectively. Several factors such as

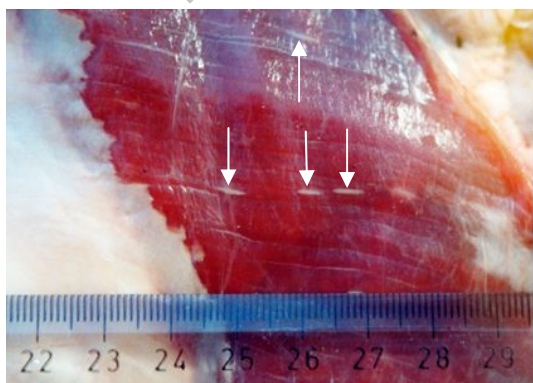


Fig. 1: Multiple-sized sarcocysts (arrows) in diaphragm of 2-year-old Iranian cow

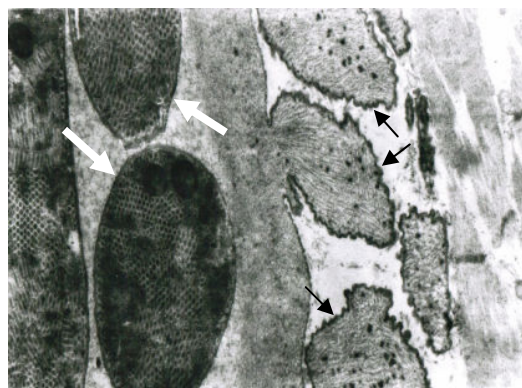


Fig. 2: TEM photograph of primary cyst wall of *S. hirsuta*. Conical-shaped villar protrusions (black arrows) with constricted base are visible. Sections from bradyzoites within the cyst (white arrows) are also illustrated, ($\times 180,000$)

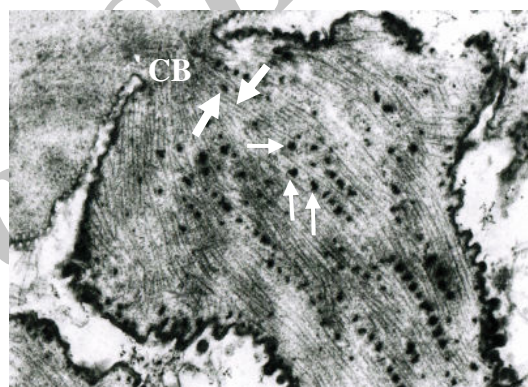


Fig. 3: TEM photograph of the primary cyst wall of *S. hirsuta*. A conical-shaped villar protrusion with constricted base (CB), electron-dense granules (thin arrows) and microfilaments (thick arrows) are visible, ($\times 300,000$)

husbandry system, frequency of final hosts, age of intermediate hosts (Valinezhad *et al.*, 2008), anatomic location, and multiple tissue types for sampling (Woldemeskel and Gumi, 2001; Ghisleni *et al.*, 2006) may be associated with the prevalence variation of *Sarcocystis* spp. infection.

The high prevalence of microscopic sarcocysts in cattle may be related to the farm management in the case of using dog (the final host) as guard. A high infection rate of *S. cruzi* cyst (89%) compared to the thick-walled cysts (21%) may be due to the cattle husbandry fields, where sentinel dogs can contaminate cattle pasture, food, drinking water, and bedding with the sporocysts (Nourani *et al.*, 2010).

Compared with other food animals, particularly goat and sheep, with high prevalence of macroscopic species (such as *S. medusiformis*) in this region, no reports on macroscopic sarcocyst (*S. hirsuta*) have been found in cattle. Despite the presence of cats in our farms, the macroscopic sarcocysts are not common in cattle, which may be due to the absence of the species in this area.

The present report indicates a need for performing some studies on epizootologic aspects and also systematic surveillance of *S. hirsuta* in our country.

Acknowledgement

The authors are grateful to Mr. Safavi for his assistance in taking electron micrographs.

References

- Bonyadian, M and Meshki, B (2006). Study on infestation of cow carcasses to *Sarcocyst* spp in slaughtered cows in Shahrekord by impression method. Pajouhesh and Sazandegi. 72: 14-18 (in Persian).
- Dalimi, A; Khodashenas, M; Noori, A and Morovati, M (1999). Ultrastructural study of sarcocysts isolated from water buffalo (*Bubalus bubalis*) in Khuzestan province, in Iran. Pajouhesh and Sazandegi. 43: 47-49 (in Persian).
- Dubey, JP; Speer, CA and Charleston, WAG (1989b). Ultrastructural differentiation between *Sarcocystis* of *Sarcocystis hirsuta* and *S. hominis*. Vet. Parasitol., 34: 153-157.
- Dubey, JP; Speer, CA and Fayer, R (1989a). *Sarcocystosis of animals and man*. Boca Raton, Florida, CRC Press. PP: 105-112.
- Ghisleni, G; Robba, S; Germani, O and Scanziani, E (2006). Identification and prevalence of *Sarcocystis* spp. cysts in bovine canned meat. Food Control. 17: 691-694.
- Hamidinejat, H; Razi Jalali, MH and Nabavi, L (2010). Survey on *Sarcocystis* infection in slaughtered cattle in south-west of Iran, emphasized on evaluation of muscle squash in comparison with digestion method. J. Anim. Vet. Adv., 9: 1724-1726.
- Mirzaei Dehaghi, M; Fathi, S and Norouzi Asl, E (2011). Survey of sarcocystis infection in slaughtered goats in Kerman abattoir, southeast of Iran. J. Anim. Vet. Adv., 10: 1205-1208.
- Neva, FA and Brown, HW (1994). *Basic clinical parasitology*. 6th Edn., London, Prentice Hall International Inc., PP: 51-52.
- Nourani, H; Matin, S; Nouri, A and Azizi, HR (2010). Prevalence of thin-walled *Sarcocystis cruzi* and thick-walled *Sarcocystis hirsuta* or *Sarcocystis hominis* from cattle in Iran. Trop. Anim. Health Prod., 42: 1225-1227.
- Odening, K; Wesemeier, HH; Walter, G and Bockhardt, I (1994). The wisent (*Bison bonasus*, Bovidae) as an intermediate host of three *Sarcocystis* species (Apicomplexa: Sarcocystidae) of cattle. Folia Parasitologica. 41: 115-121.
- Oryan, A; Moghaddar, N and Gaur, SNS (1996). The distribution pattern of *Sarcocystis* species, their transmission and pathogenesis in sheep in Fars province of Iran. Vet. Res. Commun., 20: 243-253.
- Razavi, SM; Shekarforoush, SS; Farahani, M and Sarihi, K (2003). Prevalence of sarcocyst in slaughtered sheep in Shiraz, Iran. J. Vet. Parasitol., 17: 139-141.
- Shekarforoush, SS; Razavi, SM; Ahmadi, H and Sarihi, K (2004). Study on prevalence of *Sarcocystis* in slaughtered cattle in Shiraz. J. Fac. of Vet. Med., University of Tehran. 59: 33-37 (in Persian).
- Shekarforoush, SS; Razavi, SM; Dehghan, SA and Sarihi, K (2005). Prevalence of *Sarcocystis* species in slaughtered goats in Shiraz, Iran. Vet. Rec., 156: 418-420.
- Shekarforoush, SS; Shakerian, A and Hasanpoor, MM (2006). Prevalence of *Sarcocystis* in slaughtered one-humped camel (*Camelus dromedarius*) in Iran. Trop. Anim. Health Prod., 38: 301-303.
- Soulsby, EJJ (1982). *Helminths, arthropods and protozoa of domesticated animals*. 7th Edn., Oxford, Bailliere Tindal. PP: 625-630.
- Valinezhad, A; Oryan, A and Ahmadi, N (2008). *Sarcocystis* and its complications in camels (*Camelus dromedarius*) of eastern provinces of Iran. Korean J. Parasitol., 46: 229-234.
- Woldemeskel, M and Gumi, B (2001). Prevalence of sarcocysts in one-humped camel (*Camelus dromedarius*) from southern Ethiopia. J. Vet. Med. B., 48: 223-226.