

The effect of alphamune and biomin on histomorphological structure of small intestine and caecal tonsil lymphoid tissue in broiler chicken

Erfani Majd, N.^{1*}; Mayahi, M.² and Sadeghi Moghadam, A.²

¹Department of Basic Sciences, Faculty of Veterinary Medicine, Shahid Chamran University of Ahvaz, Ahvaz, Iran; ²Department of Clinical Sciences, Faculty of Veterinary Medicine, Shahid Chamran University of Ahvaz, Ahvaz, Iran

*Correspondence: N. Erfani Majd, Department of Basic Sciences, Faculty of Veterinary Medicine, Shahid Chamran University of Ahvaz, Ahvaz, Iran. E-mail: naeemalbo@yahoo.com

(Received 11 Aug 2012; revised version 11 Aug 2013; accepted 30 Sept 2013)

Summary

This study was conducted because of influence of prebiotics (alphamune) and symbiotic (biomin) on histometrical development of small intestine and lymphatic tissue of caecal tonsil have been not reported on broiler chicken. In this study, different parts of small intestine and caecal tonsil, which is a major area of gut associated lymphatic tissue (GALT) in chicken were selected. One hundred and twenty-five 1-day-old broiler chicks were divided into 3 groups: 1) Control group which were fed only by basal diet, 2) Alphamune group which were fed basal diet supplemented with prebiotic (0.5 kg/ton alphamune), and 3) Biomin group, fed basal diet supplemented with symbiotic (1 kg/ton biomin). At the end of 42 days, 15 chicks (5 chicks from each group) were selected for histomorphometrical study. The samples were taken from different parts of small intestine (duodenum, jejunum and ileum) and caecal tonsils and fixed in 10% formalin. The 5-6 μ sections were made by paraffin embedding method and stained by H&E. The results showed that although alphamune and biomin have a significant improvement on histomorphological structure of small intestine (more significant changes were seen in duodenum) and lymphatic tissue of caecal tonsil, the biomin has a more significant improvement. Villous height and thickness, the number of goblet cells, number and depth of intestinal crypt, density and area of aggregated lymphatic tissue were increased more significantly in biomin group ($P < 0.05$). The knowledge obtained from this study showed that alphamune and biomin are considerable feed additives instead of antibiotic for improvement of histomorphological structure of small intestine and its associate lymphatic tissue.

Key words: Prebiotic, Symbiotic, Histomorphometrical, Broiler chicken

Introduction

In the poultry industry, antibiotics are used worldwide to prevent poultry pathogens and disease so as to improve meat and egg production. However, the use of dietary antibiotics resulted in common problems such as development of drug-resistant bacteria (Sorum and Sunder, 2001), drug residues in the body of the birds (Burgat, 1999), and imbalance of normal micro flora (Andrement, 2000). As a consequence, it has become necessary to develop alternatives using either beneficial microorganisms or nondigestible ingredients that enhance microbial growth. A probiotic is defined as a live microbial feed supplement that beneficially affects the host animal by improving its microbial intestinal balance (Fuller, 1989). On the other hand, a prebiotic is defined as nondigestible food ingredient that beneficially affects the host, selectively stimulating the growth or activity, or both, of one or a limited number of bacteria in the colon (Gibson and Roberfro, 1995). *Lactobacilli* and *enterococci* are among the wide variety of microbial species that have been used extensively as probiotics (Patterson and Burkholder, 2003). After feeding of probiotics, improvements in growth performance and feed efficiency have been reported in broiler chickens (Cavazzoni *et al.*, 1998; Jin *et al.*, 1998; Zulkifli *et al.*,

2000; Kabir *et al.*, 2004; Mountzouris *et al.*, 2007; Samli *et al.*, 2007).

Recently, Chichlowski *et al.* (2007) reported that a probiotic containing *Lactobacilli bifidobacterium thermophilum* and *Enterococcus faecium* increased the jejunal villous height and decreased the villous crypt depth compared with salinomycin and control. Moreover, shorter and thinner villi were associated with toxins (Yason *et al.*, 1987; Awad *et al.*, 2006). In contrast, longer villi were found in the ileum of adult male layers with slight improvement in feed efficiency after dietary addition of *Bacillus subtilis* var. *natto* (Samanya and Yamauchi, 2002) and in broilers after addition of *E. faecium* (Samli *et al.*, 2007) or *Eubacterium* sp. (Awad *et al.*, 2006). Inulin and fructooligosaccharides are probably the most commonly used prebiotics; several typical probiotics contain either of these oligosaccharides, thereby comprising a synbiotic. A way of potentiating the efficacy of probiotic preparations may be the combination of both probiotics and prebiotics as synbiotics. The combination of a prebiotic and probiotic in 1 product has been shown to confer benefits beyond those of either on its own (Gallaher and Khil, 1999). When evaluating the efficacy of potential antibiotic alternatives on bird health and productivity, it is also important to analyse the

competence of the immune cells in the gut associated lymphoid tissue (GALT), because it is routinely involved in the surveillance of colonizing microbes as well as in interacting with the ingested feed antigens. The effects of a synbiotic and a probiotic on the development of intestinal histomorphology in association to their improvement on GALT in broilers chick is still not completely clear. Therefore, the present study was conducted to investigate the effects of a synbiotic (biomin_{imbo}) and a probiotic (alphamune) on broiler histomorphometrical of developing small intestinal mucosa and caecal tonsil (CT) lymphoid tissue, which is a major GALT in poultry.

Materials and Methods

One hundred and twenty-five 1-day-old broiler chicks were obtained from commercial hatchery. The birds were randomly divided into 3 groups: 1) Control group which were fed only by basal diet, 2) Alphamune group which were fed basal diet supplemented with prebiotic (0.5 kg/ton alphamune which is a yeast extract antibiotic alternative, mannan-oligosaccharide), and 3) Biomin group, which were fed basal diet supplemented with synbiotic (1 kg/ton biomin which is a combination of the probiotic strain *Enterococcus faecium* (DSM 3530), a prebiotic (derived from chicory), and immune-modulating substances (derived from sea algae).

At the end of 42 days, 15 chicks (5 chicks from each group) were selected for histomorphometrical study. The samples were taken from different parts of small intestine (duodenum, jejunum and ileum) and caecal tonsil and were fixed in 10% formalin. The 5-6 μ sections were made by paraffin embedding method and stained by H&E. The micrometrical analysis was done

using Dino-Lite Digital Microscope, Digital Dino-Lite Eye-Piece and Dino-Capture 1 software on microphotographs.

Statistical analysis

One way analysis of variance (ANOVA) was performed for data analyses. Differences between groups were considered to be significant in $P < 0.05$.

Results

The histomorphometrical measurement results of different parts of small intestine and lymphoid tissue of caecal tonsil are shown in Tables 1 and 2.

Small intestine

Duodenum

As shown in Table 1, the height and thickness of villous, the number and depth of liberkuhn glands and goblet cells number of chicken duodenum were increased significantly in biomin group compared to control groups ($P < 0.05$), but height and depth of liberkuhn glands were only increased in alphamune group. These differences are also observable in Fig. 1.

Jejunum and ileum

No significant changes were seen on jejunum and ileum villous height and thickness in different groups. The number of jejunal and ilial liberkuhn glands and goblet cells number were increased significantly in biomin and alphamune groups compared to control group ($P < 0.05$). The depth of liberkuhn glands increased in biomin group significantly ($P < 0.05$). These differences are also observable in Fig. 2.

Table 1: The mean \pm SD of small intestine histomorphometrical results in different groups

Group	Factors					
	Intestinal parts	Villi height (mm)	Villus thickness (mm)	Intestinal crypt depth (mm)	Intestinal crypt number in $\times 4$	Goblet cells number in 1 mm length
Duodenum	Biomin	1.445 \pm 0.046 ^a	0.302 \pm 0.64 ^a	0.163 \pm 0.006 ^a	29.8 \pm 0.734 ^a	121.2 \pm 4.81 ^a
	Alphamune	1.375 \pm 0.044 ^a	0.266 \pm 0.059 ^b	0.173 \pm 0.017 ^a	24.4 \pm 0.4 ^b	96 \pm 3.53 ^b
	Control	0.817 \pm 0.123 ^b	0.259 \pm 0.039 ^b	0.105 \pm 0.001 ^b	24 \pm 1.08 ^b	100.25 \pm 1.11 ^b
Jejunum	Biomin	1.015 \pm 0.116	0.287 \pm 0.039 ^a	0.171 \pm 0.013 ^a	28.4 \pm 1.122 ^a	135 \pm 4.183 ^a
	Alphamune	0.957 \pm 0.146	0.191 \pm 0.011 ^b	0.175 \pm 0.029 ^a	21.6 \pm 0.678 ^b	99 \pm 3.535 ^b
	Control	0.926 \pm 0.019	0.216 \pm 0.001 ^b	0.150 \pm 0.013 ^b	19.25 \pm 0.478 ^b	104.75 \pm 8.34 ^b
Ileum	Biomin	0.600 \pm 0.048 ^b	0.251 \pm 0.017	0.204 \pm 0.030 ^a	30.4 \pm 4.273 ^a	540.2 \pm 24.854 ^a
	Alphamune	0.708 \pm 0.13 ^a	0.218 \pm 0.018	0.169 \pm 0.018 ^b	23 \pm 1.095 ^b	225 \pm 26.496 ^b
	Control	0.586 \pm 0.074 ^b	0.222 \pm 0.020	0.147 \pm 0.016 ^b	20.75 \pm 1.03 ^b	165 \pm 12.416 ^c

Different letters in each column indicates significant difference ($P < 0.05$)

Table 2: The mean \pm SD of caecal tonsil (CT) histomorphometrical results in different groups

Group	Factors		
	The relative of lymphoid area of CT to entire CT circumference	Height of nodular unit fold (μ)	Thickness of nodular unit fold (μ)
Biomin	0.983 \pm 179 ^a	1.088 \pm 0.361 ^a	0.899 \pm 0.064 ^a
Alphamune	0.434 \pm 0.11 ^b	0.709 \pm 0.066 ^b	0.540 \pm 0.087 ^b
Control	0.286 \pm 0.07 ^c	0.568 \pm 0.1 ^c	0.291 \pm 0.07 ^c

Different letters in each column indicates significant difference ($P < 0.05$)

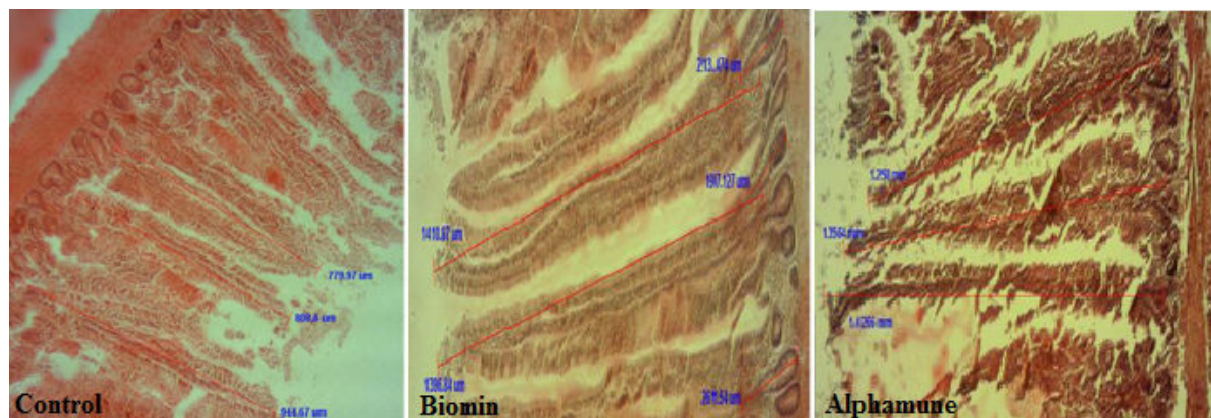


Fig. 1: The increasing of duodenal villus height and thickness in biomin and alphamune compared to control group are considerable (H&E, ×4)

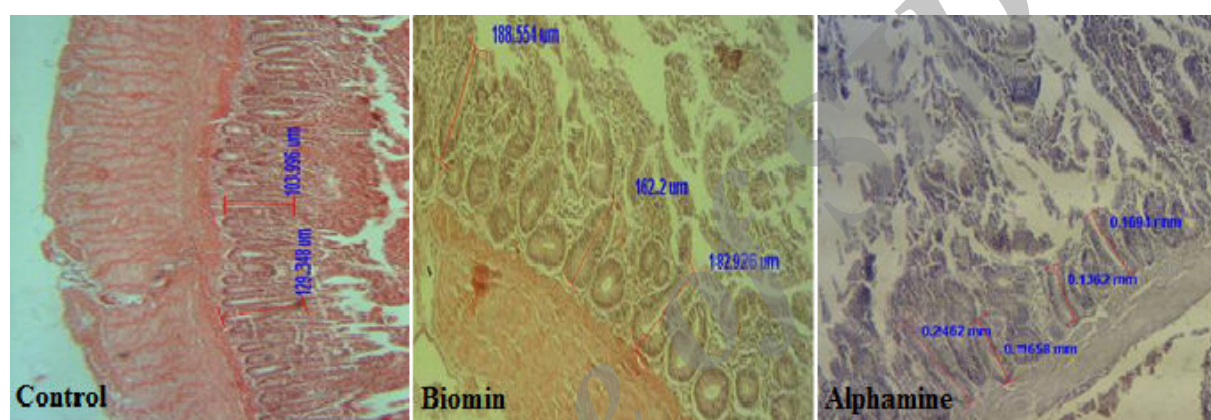


Fig. 2: The increase of the duodenal crypt depth in biomin and alphamune compared to control group is considerable (H&E, ×4)

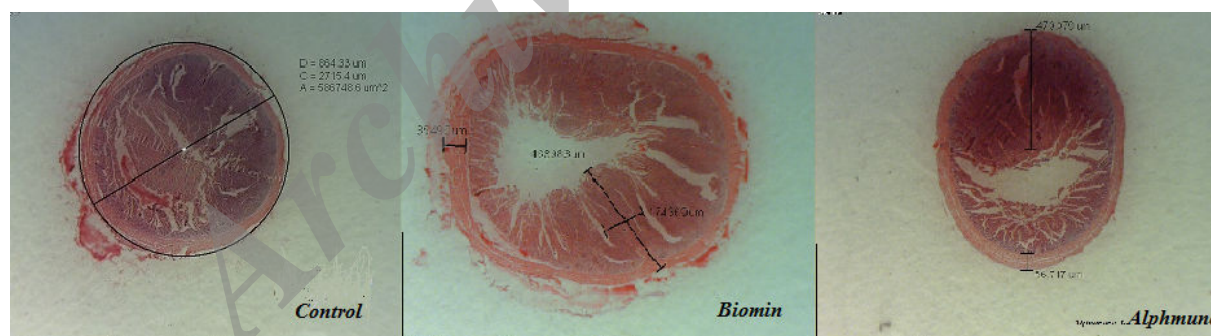


Fig. 3: The significant increase of lymphoid tissue, relative lymphoid area of CT to entire CT circumference, height and thickness of nodular units in biomin group are considerable (Dino-Lite Digital Microscope Photograph)

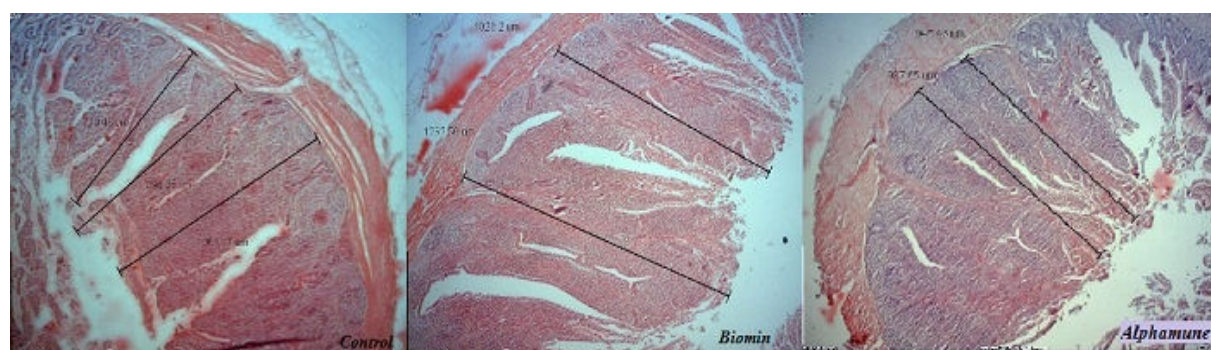


Fig. 4: The density of caecal tonsil lymphoid tissue increased in biomin group which is associated with increasing of height and thickness of nodular unit (Micrograph by Dino-Lite Digital Eye-Piece and Dino-Capture 1 software)

Caecal tonsil

A paired caeca were seen in large intestine in which a paired caecal tonsil was situated in the basal part of each one. They were recognized easily from other parts by more wall thickness and diameter. Caecal tonsil mucosa has a different structure; a part of it which contains accumulated mass of lymphoid tissue (tonsil) avoids villous but instead has thick and high folds containing nodular units, so that this part has a thicker wall than other parts. The facing wall which is without tonsil is covered by long villous, similar to those in small intestine and its thickness is less than the tonsil part (Figs. 3 and 4).

The caecal tonsil lumen is almost closed completely by villous and mucosa-submucosa folds of nodular units. Nodular units are tonsil like structures formed by mucosal-submucosal folds and surrounded by a delicate layer of smooth muscle branching out of an inner circular muscle layer and muscularis mucosa. Surface epithelium has made a deep crypt into the nodular unit, mostly covered by short villous. Diffuse and nodular lymphatic tissue fills the lamina propria.

A more interesting finding is increasing and improvement of density and area of aggregated lymphoid tissue and the relationship of lymphoid area of CT to the entire CT circumference in biomin and alphamune groups compared to control group ($P < 0.05$), which caused the diameters and wall thickness of CT, height and thickness of nodular unit to increase (Table 2). The biomin has more significant improvement on lymphatic tissue of caecal tonsil compared to alphamune groups. The diffuse lymphatic tissue and lymph nodules in lamina propria-submucosa were also increased in different parts of caecal tonsil.

Discussion

The results of the present study showed that although the alphamune and biomin improved the development of histomorphological structure of small intestine and caecal tonsil lymphoid tissue of broiler chicken, the biomin has more significant improvement which is in agreement with Awad *et al.* (2006). The improvement was more effective on duodenum than other parts of small intestine. Increasing the villous height suggests an increased surface area capable of greater absorption of available nutrients (Caspary, 1992). The villous crypt is considered as the villous factory and deeper crypts indicate fast tissue turnover to permit renewal of the villous as needed in response to normal sloughing or inflammation from pathogens or their toxins and high demands for tissue (Yason *et al.*, 1987) and Anonymous (1999). The intestinal epithelial cells originating in the crypt migrate along the villous surface upward to the villous tip and are extruded into the intestinal lumen within 48 to 96 h (Imondi and Bird, 1966; Potten, 1998). A shortening of the villi and deeper crypts may lead to poor nutrient absorption, increased secretion in the gastrointestinal tract, and lower performance (Xu *et al.*, 2003). In contrast, increases in the villous height and

crypt depth ratio is directly correlated with increased epithelial cell turnover (Fan *et al.*, 1997) and longer villi are associated with activated cell mitosis (Samanya and Yamauchi, 2002). Longer villi were found in the ileum of chicks and turkeys treated with *Lactobacillus reuteri* (Dunham *et al.*, 1993) and in the ileum of adult male layers with slight improvement in feed efficiency after dietary addition of *Bacillus subtilis* var. *natto* (Samanya and Yamauchi, 2002). Feeding of probiotics has been shown to induce gut epithelial cell proliferation in rats (Ichikawa *et al.*, 1999). In addition, longer villi were induced by dietary amylase (Ritz *et al.*, 1995). The concentrations of amylase in broiler intestine were increased after supplementation of diet with either a single strain of *Lactobacillus acidophilus* or a mixture of *Lactobacillus* strains (Jin *et al.*, 2000). Awad *et al.* (2006) reported that the crypt depth was not affected by dietary treatment (alphamune and biomin) and synbiotic and probiotic supplementations increased villous height: crypt depth ratio significantly and the villous height numerically compared with the control. However, the villous height and crypt depth were increased significantly in the present study, particularly in duodenum. It is assumed that an increased villous height is paralleled by an increased digestive and absorptive function of the intestine due to increased absorptive surface area, expression of brush border enzymes, and nutrient transport systems (Pluske *et al.*, 1996). It is understood that greater villous height is an indicator that the function of intestinal villi is activated (Langhout *et al.*, 1999; Yasar and Forbes, 1999; Shamoto and Yamauchi, 2000). This fact suggests that the villous function is activated after feeding of dietary synbiotic or probiotic. Moreover, increased passive absorption of glucose and proline was reported in broiler chickens fed a probiotic containing *Lactobacilli*, *B. thermophilum*, and *E. faecium* (Chichlowski *et al.*, 2007). The density and area of aggregated lymphoid tissue was improved significantly also in biomin group, which caused an increase in the diameters and wall thickness of CT, height and thickness of nodular unit. Spring *et al.* (2000) reported that although mannan oligosaccharides (MOS) have been used as the prebiotics they do not selectively enrich for beneficial bacterial populations. Instead, they are thought to act by binding and removing pathogens from the intestinal tract and stimulation of the immune system. Other studies have demonstrated positive effects of biomin on immune system effectiveness and newly described prebiotics can modulate various properties of the immune system, including those of the gut-associated lymphoid tissues (GALT). Changes in the intestinal micro flora that occur with the consumption of prebiotic fibres may potentially mediate immune changes via the direct contact of lactic acid bacteria or bacterial products (cell wall or cytoplasmic components) with immune cells in the intestine; the production of short-chain fatty acids from fiber fermentation; or by changes in mucin production (Schley and Field, 2000). However, Janardhana *et al.* (2009) reported that the addition of prebiotics to diet resulted in a significant reduction in the

proportion of B cells and in mitogen responsiveness of lymphocytes in caecal tonsil. The prebiotic maintain a beneficial microbial population by competitive exclusion and antagonism (Fuller, 1989). Alphamune, a yeast extract antibiotic alternative, has been shown to stimulate the immune system increased BW in pigs, and reduce *Salmonella* colonization in chickens (Solis de los Santos *et al.*, 2007). Hosseini (2011) reported that *Saccharomyces cerevisiae* has significant effects on visceral and immune organs. *Lactobacilli* and *enterococci* are among the wide variety of microbial species that have been used extensively as probiotic enhanced concentrations of circulating immunoglobulin A (IgA), (Kaila *et al.*, 1992; Akinleye, 2000). Inhibition of pathogens by the intestinal microbiota has been called bacterial antagonism, bacterial interference, barrier effect, colonization resistance, and competitive exclusion. Mechanisms by which the indigenous intestinal bacteria inhibit pathogens include competition for colonization sites, competition for nutrients, production of toxic compounds, or stimulation of the immune system (Patterson and Burkholder, 2003). These findings emphasize the need for the analyses of the gut immune function following treatment with novel feed additives. The knowledge obtained from such study may aid in understanding the mechanisms underlying the immune competence of the birds, which needs consideration when selecting and optimizing new feed additives instead of antibiotics for poultry production. Although further work is needed to better define the changes, mechanisms for immunomodulation, and the ultimate impact on immune health, there is convincing preliminary data to suggest that the consumption of prebiotics can modulate immune parameters in GALT and secondary lymphoid tissues.

Alphamune and biomin treatment showed that biomin significantly improved and increased the small intestine (more significantly in duodenum) histomorphological structure and caecal tonsil lymphatic tissue. Furthermore, the dietary supplementations resulted in an increase in the villous height and crypt depth of intestinal mucosa of broilers, and increasing the lymphoid tissue in caecal tonsil might be a promising alternative for antibiotic growth promoters as pressure to eliminate antibiotic growth promoters in animal feed increases. The synbiotic offers a good alternative to improve poultry production.

Acknowledgement

The authors wish to express their gratitude to the research council of Shahid Chamran University for their financial support.

References

- Akinleye, SB; Iyayi, EA and Afolabi, KD (2000). The performance, haematology and carcass traits of broilers as affected by diets supplemented with or without biomin a natural growth promoter. *World J. Agric. Sci.*, 4: 467-470.
- Andremont, A (2000). Consequences of antibiotic therapy to the intestinal ecosystem. *Ann. Fr. Anesth. Reanim.*, 19: 395-402.
- Anonymous, S (1999). How do mannanoligosaccharides work? *Feed. Times*. 1: 7-9.
- Awad, WA; Böhm, J; Razzazi-Fazeli, E; Ghareeb, K and Zentek, J (2006). Effect of addition of a probiotic microorganism to broiler diets contaminated with deoxynivalenol on performance and histological alterations of intestinal villi of broiler chickens. *Poult. Sci.*, 85: 974-979.
- Burgat, V (1999). Residues of drugs of veterinary use in food. *Rev. Prat.*, 41: 985-990.
- Caspary, WF (1992). Physiology and pathophysiology of intestinal absorption. *Am. J. Clin. Nutr.*, 55: 299-308.
- Cavazzoni, V; Adami, A and Cstrivilli, C (1998). Performance of broiler chickens supplemented with *Bacillus coagulans* as probiotic. *Bri. Poult. Sci.*, 39: 526-529.
- Chichlowski, M; Croom, WJ; Edens, FW; MacBride, BW; Qiu, R; Chiang, CC; Daniel, LR; Havenstein, GB and Koci, MD (2007). Microarchitecture and spatial relationship between bacteria and ileal, cecal and colonic epithelium in chicks fed a direct-fed microbial, PrimaLac, and salinomycin. *Poult. Sci.*, 86: 1121-1132.
- Dunham, HJ; Williams, C; Edens, FW; Casas, IA and Dobrogosz, WJ (1993). *Lactobacillus reuteri* immunomodulation of stressor-associated diseases in newly hatched chickens and turkeys. *Poult. Sci.*, (Suppl. 1), 72: 103.
- Fan, Y; Croom, J; Christensen, V; Black, B; Bird, A; Daniel, L; McBride, B and Eisen, E (1997). Jejunal glucose uptake and oxygen consumption in turkey poults selected for rapid growth. *Poult. Sci.*, 76: 1738-1745.
- Fuller, R (1989). Probiotic in man and animal. *J. Appl. Bacteriol.*, 66: 365-378.
- Gallaher, DD and Khil, J (1999). The effect of synbiotics on colon carcinogenesis in rats. *J. Nutr.*, (Suppl. 7), 129: 1483-1487.
- Gibson, GR and Roberfrois, MB (1995). Dietary modulation of human colonic microbiota: introducing the concept of prebiotic. *J. Nutr.*, 125: 1401-1412.
- Hosseini, SM (2011). Study on the effects of *Saccharomyces cerevisiae* SC47 on visceral and immune organs of broiler chickens. *Global Vet.*, 7: 297-300.
- Ichikawa, H; Kuroiwa, T and Inagaki, A (1999). Probiotic bacteria stimulate epithelial cell proliferation in rat. *Dig. Dis. Sci.*, 44: 2119-2123.
- Imondi, AR and Bird, FR (1966). The turnover of intestinal epithelium in the chick. *Poult. Sci.*, 45: 142-147.
- Janardhana, V; Broadway, MM; Bruce, MP; Lowenthal, JW; Geier, MS; Hughes, RJ and Bean, A (2009). Prebiotics modulate immune responses in the gut-associated lymphoid tissue of chickens. *J. Nutr.*, 139: 1404-1409.
- Jin, LZ; Ho, YW; Abdullah, N and Jalaludin S (1998). Growth performance, intestinal microbial populations and serum cholesterol of broilers fed diets containing *Lactobacillus* cultures. *Poult. Sci.*, 77: 1259-1265.
- Jin, LZ; Ho, YW; Abdullah, N and Jalaludin, S (2000). Digestive and bacteria enzyme activities in broilers fed diets supplemented with *Lactobacillus* cultures. *Poult. Sci.*, 79: 886-891.
- Kabir, SML; Rahman, MM; Rahman, MB; Rahman, MM and Ahmed, SU (2004). The dynamics of probiotics on growth performance and immune response in broilers. *Int. J. Poult. Sci.*, 3: 361-364.
- Kaila, M; Isolauri, E; Soppi, E; Virtanen, E; Laine, S and

- Arvilommi, H** (1992). Enhancement of the circulating antibody secreting cell response in human diarrhea by a human *Lactobacillus* strain. *Pediatr. Res.*, 32: 141-144.
- Langhout, DJ; Schutte, JB; Van, LP; Wiebenga, J and Tamminga, S** (1999). Effect of dietary high and low methylated citrus pectin on the activity of the ileal microflora and morphology of the small intestinal wall of broiler chickens. *Bri. Poult. Sci.*, 40: 340-347.
- Mountzouris, KC; Tsistsikos, P; Kalamara, E; Nitsh, S; Schatzmayr, G and Fegeros, K** (2007). Evaluation of the efficacy of a probiotic containing *Lactobacillus*, *Bifidobacterium*, *Enterococcus*, and *Pediococcus* strains in promoting broiler performance and modulating cecal microflora composition and metabolic activities. *Poult. Sci.*, 86: 309-317.
- Patterson, JA and Burkholder, KM** (2003). Application of prebiotics and probiotics in poultry production. *Poult. Sci.*, 82: 627-631.
- Pluske, JR; Tompson, MJ; Atwood, CS; Bird, PH; Williams, IH and Hartmann, PE** (1996). Maintenance of villus height and crypt depth, and enhancement of disaccharide digestion and monosaccharide absorption, in piglets fed on cows' whole milk after weaning. *Bri. J. Nutr.*, 76: 409-422.
- Potten, CS** (1998). Stem cells in the gastrointestinal epithelium: numbers, characteristics and death. *Philos. Trans. R. Soc. Lond. B. Biol. Sci.*, 353: 821-830.
- Ritz, CW; Hulet, RM; Self, BB and Denbow, DM** (1995). Growth and intestinal morphology of male turkeys as influenced by dietary supplementation of amylase and xylanase. *Poult. Sci.*, 74: 1329-1334.
- Samanya, M and Yamauchi, K** (2002). Histological alterations of intestinal villi in chickens fed dried *Bacillus subtilis* var. natto. *Comp. Biochem. Physiol.*, 133: 95-104.
- Samli, HE; Senkoylu, N; Koc, F; Kanter, M and Agma, A** (2007). Effects of *Enterococcus faecium* and dried whey on broiler performance, gut histomorphology and microbiota. *Arch. Anim. Nutr.*, 61: 42-49.
- Schley, PD and Field, CJ** (2000). The immune-enhancing effects of dietary fibers and prebiotic. *Bri. J. Nutr.*, (Suppl. 2), 87: 221-230.
- Shamoto, K and Yamauchi, K** (2000). Recovery responses of chick intestinal villus morphology to different refeeding procedures. *Poult. Sci.*, 79: 718-723.
- Solis de los Santos, F; Donoghue Farnell, MB; Huff, GR; Huff, WE and Donoghue, DJ** (2007). Gastrointestinal maturation is accelerated in Turkey poult supplemented with a mannan-oligosaccharide yeast extract (alphanune). *Poult. Sci.*, 86: 921-930.
- Sorum, H and Sunder, M** (2001). Resistance to antibiotics in the normal flora of animals. *Vet. Res.*, 32: 227-241.
- Spring, C; Wenk, P; Dawson, KA and Newman, KE** (2000). The effect of dietary mannanoligosaccharides on cecal parameters and the concentrations of enteric bacteria in the ceca of *Salmonella*-challenged broiler chicks. *Poult. Sci.*, 79: 205-211.
- Xu, ZR; Hu, CH; Xia, MS; Zhan, XA and Wang, MQ** (2003). Effects of dietary fructooligosaccharide on digestive enzyme activities, intestinal microflora and morphology of male broilers. *Poult. Sci.*, 82: 1030-1036.
- Yasar, S and Forbes, JM** (1999). Performance and gastrointestinal response of broiler chicks fed on cereal grain based foods soaked in water. *Bri. Poult. Sci.*, 40: 65-76.
- Yason, CV; Summers, BA and Schat, KA** (1987). Pathogenesis of rotavirus infection in various age groups of chickens and turkeys: pathology. *Am. J. Vet. Res.*, 6: 927-938.
- Zulkifli, I; Abdullah, N; Azrin, NM and Ho, YW** (2000). Growth performance and immune response of two commercial broiler strains fed diets containing *Lactobacillus* cultures and oxytetracycline under heat stress conditions. *Bri. Poult. Sci.*, 41: 593-597.

مقاله کامل: تاثیر آلفامیون و بیومین بر روی ساختار هیستومورفومتريک روده کوچک و بافت لنفوئیدی لوزه سکومی مرغ گوشتی

نعیم عرفانی مجد¹، منصور میاحی² و علی صادقی مقدم²

¹گروه علوم پایه، دانشکده دامپزشکی دانشگاه شهید چمران اهواز، اهواز، ایران؛ ²گروه علوم درمانگاهی، دانشکده دامپزشکی دانشگاه شهید چمران اهواز، اهواز، ایران

(دریافت مقاله: 21 مرداد 1391، پذیرش نهایی: 8 مهر 1392)

تاثیر آلفامیون و بیومین بر روی ساختار هیستومورفومتريک روده کوچک و بافت لنفوئیدی لوزه سکومی مرغ گوشتی امروزه مواد پریوتیک و سین بیوتیک به عنوان جایگزینی برای آنتی بیوتیک جهت افزایش رشد، به طور گسترده‌ای در مرغداری‌های مدرن استفاده می‌شوند. یکی از راه‌های افزایش اثرات پریبیوتیک‌ها ترکیب دو پریبیوتیک و پریبیوتیک به عنوان سین بیوتیک می‌باشد که به وسیله بهبود بقاء و جایگزین نمودن میکروب‌های مکمل جیره در لوله گوارش، اثرات مفیدی در میزبان دارد. به این منظور در این مطالعه 125 جوجه گوشتی یک روزه در 3 گروه تقسیم شدند: (1) گروه کنترل، فقط با جیره پایه تغذیه شدند، (2) گروه آلفامیون، علاوه بر جیره پایه به میزان 0/5 کیلوگرم در یک تن آلفامیون دریافت کردند و (3) گروه بیومین، علاوه بر جیره پایه به میزان 1 کیلوگرم در یک تن بیومین دریافت کردند. در انتهای 42 روزگی، برای مطالعات هیستومورفومتريک، 15 جوجه (5 جوجه از هر گروه) به طور تصادفی انتخاب گردیدند. نمونه‌گیری از قسمت‌های مختلف روده کوچک (دوازدهه، تهی روده و ایلئوم) و لوزه سکومی انجام و جهت ثبوت در ماده ثبوتی فرمالین 10٪ قرار داده شدند. سپس به روش معمول تهیه مقاطع پارافینی، برش‌هایی به ضخامت 5 تا 6 میکرومتر تهیه و مورد رنگ‌آمیزی هماتوکسیلین و ائوزین قرار گرفتند. نتایج به دست آمده نشان داد که هر چند آلفامیون و بیومین اثرات بهبودی معنی‌داری بر ساختار هیستومورفومتريک روده کوچک (به ویژه دوازدهه) و بافت لنفوئیدی لوزه سکومی دارند، لیکن بیومین دارای اثرات بهبودی معنی‌داری می‌باشد. به طوری که ارتفاع و ضخامت کرک‌ها، تعداد سلول‌های جامی شکل، تعداد و عمق کریپت‌های روده‌ای، تراکم و وسعت بافت لنفوئیدی لوزه سکومی در گروه بیومین به طور معنی‌داری افزایش می‌یابد ($P < 0.05$). نتایج به دست آمده از این مطالعه نشان می‌دهد که می‌توان آلفامیون و بیومین به عنوان مکمل‌های غذایی جانشین آنتی بیوتیک‌ها جهت بهبود ساختار هیستومورفومتريک روده کوچک و بافت لنفوئیدی ضمیمه آن مورد توجه قرار گیرند.

واژه‌های کلیدی: پریبیوتیک، سیمبیوتیک، هیستومورفومتريک، مرغ گوشتی