

## Scientific Report

# Avulsion of the greater trochanter and craniodorsal luxation of the hip joint in a cat: importance of precise radiographic evaluation

Pinna, S. \* and Cella, V.

Department of Veterinary Medical Sciences, School of Agriculture and Veterinary Medicine, University of Bologna, 40064 Ozzano dell'Emilia, Bologna, Italy

\*Correspondence: S. Pinna, Department of Veterinary Medical Sciences, School of Agriculture and Veterinary Medicine, University of Bologna, 40064 Ozzano dell'Emilia, Bologna, Italy. E-mail: stefania.pinna@unibo.it

(Received 6 Jun 2013; revised version 23 Feb 2014; accepted 2 Jul 2014)

## Summary

A traumatic coxofemoral luxation was diagnosed in a 15-month-old European neutered male cat, and on the basis of the radiographic evaluation a closed reduction was performed. Consequently, the cat was presented at the University of Bologna because of the failure of the treatment. A supplementary radiographic exam revealed the concomitant avulsion of the greater trochanter, consequently surgical management of the coxofemoral luxation was attempted successfully. Therefore, correct planning of the radiographic examination should be considered to prevent possible mistakes.

**Key words:** Coxofemoral luxation, Avulsion fracture, Greater trochanter, Radiograph, Cat

## Introduction

Coxofemoral luxation is a common injury in small animal practice, accounting for as many as 90% of all luxations (McLaughlin, 1995). The majority of coxofemoral luxations are represented by unilateral injuries, and because of the massive forces required to produce dislocation, about 50% are associated with major injuries (Piermattei *et al.*, 2006; Witte and Scott, 2012). Luxation most frequently occurs in the craniodorsal direction since forces applied during trauma produce a vector force that makes the femoral head dislocate in this direction. The strong pull of the gluteal muscles also helps to pull the femoral head to that position (Wadsworth, 1993). The orthopaedic examination is not enough to diagnose the hip luxation, and radiographic evaluation is imperative to confirm the injury.

The aim of this report is to describe a case of inaccurate radiographic assessment, and the consequent failure of the treatment of coxofemoral luxation due to the greater trochanter avulsion in a cat.

## Case presentation

A 15-month-old, neutered male European cat, weighing 4.2 kg, was referred to the Department of Veterinary Medical Sciences of the University of Bologna. The cat had probably undergone a trauma. The cat had already been evaluated the day before consultation as he was found in lateral recumbency and

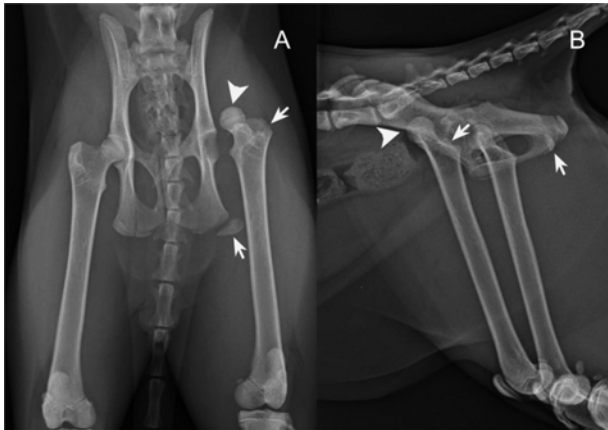
with sharp pain in the left hind limb. It was referred that on physical examination, inability to stand and walk had been revealed and manipulation of the pelvis and of the left hind limb had elicited pain. Furthermore, palpation under moderate sedation had suggested the presence of slight swelling and crepitus of the left hip joint. Finally, orthogonal radiographic views of the pelvis had been obtained, and craniodorsal luxation of the left hip joint accompanied by the ipsilateral tuber ischii fracture had been diagnosed. Closed reduction of the hip joint luxation had been performed unsuccessfully.

A further orthopaedic examination was carried out and revealed a non-weight bearing lameness on the left hind limb. On palpation, the distance between the greater trochanter and the ipsilateral tuber ischii appeared increased on the affected side, and the left limb was shorter than the opposite one when extended caudally.

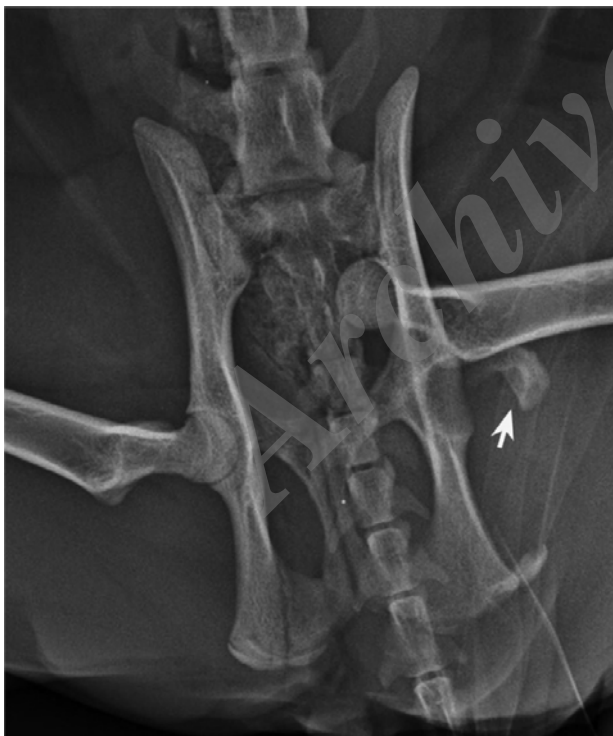The cat was sedated with butorphanol 0.1 mg/kg and medetomidine 10 µg/kg IM. The radiographic images were reevaluated and the craniodorsal displacement of the left femoral head relative to the acetabulum, and the fracture of the ischiatic tuberosity were confirmed. Furthermore, irregularity of the top of the greater trochanter was present (Figs. 1A-B). A supplementary flexed ventrodorsal view was obtained which revealed avulsion of the left greater trochanter (Fig. 2). The avulsed bone fragment was hardly detectable on ventrodorsal and lateral projections as it was superimposed both on the ipsilateral femoral neck and on the body of ilium (Figs. 1A-B).

General anesthesia was induced with butorphanol 0.1

mg/kg and midazolam 0.2 mg/kg IM and maintained with isoflurane and oxygen. After surgery, the cat was given cephazolin sodium (20 mg/kg), and carprofen (4 mg/kg) for postoperative pain.



**Fig. 1:** Extended ventrodorsal (A) and right lateral (B) radiographic views of the pelvis of 15-month-old European cat referred because of the unsuccessful closed reduction of the coxofemoral luxation. The left femoral head is displaced craniodorsally to the acetabulum (arrowheads). Fracture of the ipsilateral tuber ischii and irregularity of the top of the left greater trochanter are also evident (arrows)

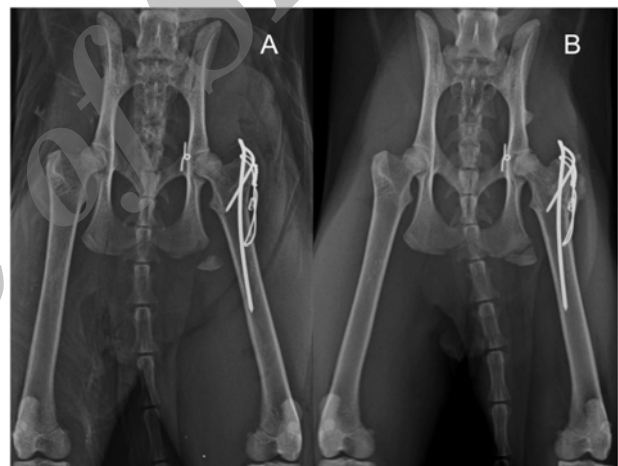


**Fig. 2:** Flexed ventrodorsal radiographic view of the pelvis of the same cat as in Figs. 1A-B. This projection detects the bone fragment of the left greater trochanter (arrow)

Therefore, surgical management of the left hip joint luxation was performed. After the open reduction through a craniodorsal approach, the toggle-pin fixation was attempted in order to stabilize the joint. A 2.0 mm hole was drilled from the fovea capitis through the

femoral head and neck with lateral exit at the proximal third of the femur. A 2.0 mm hole was drilled through the acetabular wall at the site of the original attachment of the round ligament. A toggle-pin, previously manufactured from a 1.5 mm Kirchner wire, was connected to a braided nonabsorbable nylon (Surgilon 1) double suture (Piermattei *et al.*, 2006). The implant was passed through the femoral head and neck tunnel, and pushed through the acetabular hole. The ends of the suture were pulled taut, and the hip reduced. The laterally emerged ends of the suture were anchored to a double washer made with a 1.0 mm K-wire.

Finally, two K-wires and a tension band were utilized to repair trochanteric avulsion, and the fracture of the tuber ischii was treated conservatively (Fig. 3A). At 15 days after surgery, the patient exhibited a slight weight bearing lameness, mild signs of pain on palpation and muscle atrophy. At 30 days, lameness was no longer present, and full recovery was reported at 60 days (Fig. 3B).



**Fig. 3:** Ventrodorsal projection of the pelvis taken immediately after surgery (A) and 60 days later (B). The toggle-pin is correctly placed on the medial acetabular cortex and the washer is positioned close to the hole of the lateral femoral cortex. Moreover, two K-wires are respectively inserted along the femoral diaphysis and diagonally towards the medial femoral cortex, and the tension band wire is in right figure-of-8 fashion. The correct positioning of implants has been maintained at 60 days after surgery

## Discussion

Even though the presence of coxofemoral luxation can usually be determined on the basis of clinical signs, it is vital that radiographs always be taken. Radiography is essential to confirm the diagnosis and to rule out other injuries that present similar clinical signs, such as fractures of the proximal femur. Moreover, radiography provides the opportunity to assess the direction of the luxation, and to check for the presence of other injuries that might lead to unsuccessful closed reduction or contribute to coxofemoral instability. These injuries include chip fractures of the dorsal acetabular rim, avulsion of the teres ligament insertion on the femoral

head, and trochanteric fractures. All these conditions require an open approach and specific treatment (Denny and Butterworth, 2000). Laterolateral radiographs are the best views to confirm the coxofemoral luxation, but extended ventrodorsal and supplementary radiographs should also be taken in order to detect concomitant abnormalities (Voss *et al.*, 2009).

In this case, a careful radiographic examination of the affected hip joint was required in order to obtain definitive diagnosis that was made difficult by the critical interpretation of standard orthogonal views. Initially, the bone fragment of the greater trochanter was not identified on standard projections and the choice of treatment proved to be inadequate. After that, supplementary flexed ventrodorsal view made it possible to detect the avulsion fracture of the greater trochanter and afterwards to plan the most appropriate treatment.

As far as therapy is concerned, a closed reduction and subsequent application of Ehmer sling are suggested in the treatment of recent and uncomplicated craniodorsal hip luxations. Open reduction and internal stabilization of the femoral head in the acetabulum are recommended, especially in case of multiple orthopaedic injuries like the avulsion of greater trochanter described in the present case report (Piermattei *et al.*, 2006; Venturini *et al.*, 2010; Ash *et al.*, 2012). Several surgical techniques have been described for small animals including “intra” and “extra” articular procedures, e.g. capsulorrhaphy, various peri-articular stabilization techniques made with non-absorbable or absorbable materials, transposition of the trochanter major, De Vita pinning and external fixation, toggle-pin fixation, fascia lata loop stabilization, transarticular pinning (Lubbe and Verstraete, 1990; McLaughlin and Tillson, 1994; Douglas, 2000; Martini *et al.*, 2001; Pozzi *et al.*, 2004; Piermattei *et al.*, 2006; Sissener *et al.*, 2009; Venturini *et al.*, 2010; Pratesi *et al.*, 2012). Not all of them are suitable for the cat. In this particular case, the most common toggle-pin fixation with the cranio-dorsal approach was chosen from all these techniques, because the greater trochanter was already avulsed.

In conclusion, this paper demonstrates that radiographs should be evaluated carefully; otherwise misleading diagnosis and failure therapy could occur, in spite of the chosen surgery.

## Acknowledgement

The authors thank Dr. R. Raduc for her assistance with English editing.

## References

- Ash, K; Rosselli, D and Danielski, A (2012). Correction of craniodorsal coxofemoral luxation in cats and small breed dogs using a modified Knowles technique with the braided polyblend TightRope system. *Vet. Comp. Orthop. Traumatol.*, 25: 54-60.
- Denny, HR and Butterworth, SJ (2000). The hip. In: Denny, HR and Butterworth, SJ (Eds.), *A guide to canine and feline orthopaedic surgery*. (4th Edn.), Oxford, Blackwell Science. PP: 455-494.
- Douglas, IH (2000). Modified De Vita pinning technique for the management of canine hip luxation: preliminary findings. *Aust. Vet. J.*, 8: 538-542.
- Lubbe, AM and Verstraete, FJM (1990). Fascia lata loop stabilisation of the coxofemoral joint in the dog and cat. *J. Small Anim. Pract.*, 31: 234-238.
- Martini, FM; Simonazzi, B and Del Bue, M (2001). Extra-articular absorbable suture stabilization of coxofemoral luxation in dogs. *Vet. Surg.*, 30: 568-475.
- McLaughlin, RM (1995). Traumatic joint luxations in small animals. *Vet. Clin. North Am. Small Anim. Pract.*, 25: 1175-1196.
- McLaughlin, RM and Tillson, DM (1994). Flexible external fixation for craniodorsal coxofemoral luxation in dogs. *Vet. Surg.*, 23: 21-30.
- Piermattei, DL; Flo, GL and Decamp, CE (2006). The hip joint. In: *Brinker, Piermattei, DL and Flo's Handbook of small animal orthopedics and fracture repair*. (4th Edn.), Philadelphia, Saunders Elsevier. PP: 461-511.
- Pozzi, A; Kowaleski, P; Dyce, J and Johnson, KA (2004). Treatment of traumatic coxo-femoral luxation by cemented total hip arthroplasty. *Vet. Comp. Orthop. Traumatol.*, 17: 198-203.
- Pratesi, A; Grierson, J and Mores, P (2012). Toggle rod stabilization of coxofemoral luxation in 14 cats. *J. Small Anim. Pract.*, 53: 260-266.
- Sissener, TR; Whitelock, RG and Langley-Hobbs, SJ (2009). Long-term results of transarticular pinning for surgical stabilisation of coxofemoral luxation in 20 cats. *J. Small Anim. Pract.*, 50: 112-117.
- Venturini, A; Pinna, S and Tamburro, R (2010). Combined intra-extra-articular technique for stabilisation of coxofemoral luxation. Preliminary results in two dogs. *Vet. Comp. Orthop. Traumatol.*, 23: 182-195.
- Voss, K; Langley-Hobbs, SJ and Montavon, PM (2009). Hip joint. In: Montavon, PM; Voss, K and Langley-Hobbs, SJ (Eds.), *Feline orthopedic surgery and musculoskeletal disease*. (1st Edn.), Edinburg, Mosby Elsevier. PP: 443-454.
- Wadsworth, PL (1993). Biomechanics of luxations. In: Bojrab, MJ (Ed), *Disease mechanisms in small animal surgery*. (2nd Edn.), Philadelphia, Lea and Febiger. PP: 1048-1057.
- Witte, P and Scott, H (2012). Conditions of the feline pelvic region. In *Practice*. 34: 498-511.

گزارش علمی: جدا شدگی تروکانتر بزرگ و در رفتگی قدامی-پشتی مفصل هیپ در یک قلاده گربه:  
*Archive of SID*

## اهمیت ارزیابی دقیق رادیوگرافی

استفانیا پینا و والنتینا سلا

گروه علوم دامپزشکی، دانشکده کشاورزی و دامپزشکی دانشگاه بولونیا، ازانو دل امیلیا ۴۰۰۶۴، بولونیا، ایتالیا

(دریافت مقاله: ۱۶ خرداد ۱۳۹۲، پذیرش نهایی: ۱۱ تیر ۱۳۹۳)

یک در رفتگی تروماتیک مفصل هیپ-ران در یک گربه نر اخته شده اروپایی ۱۵ ماهه تشخیص داده شد، و بر اساس ارزیابی رادیوگرافی جا اندازی بسته انجام گرفت. بنابراین، گربه به دلیل شکست درمان به دانشگاه بولونیا ارجاع داده شد. آزمایش رادیوگرافیک تکمیلی جدا شدگی پیوسته تروکانتر بزرگ را تایید کرد، بنابراین مدیریت جراحی در رفتگی کفل-رانی با موفقیت انجام شد. از اینرو، جهت جلوگیری از اشتباهات احتمالی بایستی به برنامه‌ریزی صحیح ارزیابی رادیوگرافی توجه شود.

واژه‌های کلیدی: در رفتگی کفل-رانی، شکستگی جدا شدگی، تروکانتر بزرگ، رادیوگراف، گربه

[www.SID.ir](http://www.SID.ir)