

Scientific Report

Treatment of ophidism-induced bilateral canine cataract by extracapsular lens extraction and intraocular lens implantation

Kibar, M.^{1,2*}; Evereklioglu, C.³ and Doğan, Z.¹

¹Department of Surgery, Faculty of Veterinary Medicine, Erciyes University, Kayseri, Turkey; ²Department of Surgery, Faculty of Veterinary Medicine, Kyrgyzstan Turkey Manas University, Bishkek, Kyrgyzstan; ³Department of Ophthalmology, Faculty of Medicine, Erciyes University, Kayseri, Turkey

*Correspondence: M. Kibar, Department of Surgery, Faculty of Veterinary Medicine, Erciyes University, Kayseri, Turkey. E-mail: muratkibartr@yahoo.com

(Received 2 Nov 2013; revised version 7 Jun 2014; accepted 2 Jul 2014)

Summary

The aim of this study was to report a new cause of cataract, namely snake bite induced cataract in a dog. A 3-year-old male mongrel dog was referred to our clinic for the assessment of cataract in both eyes. The dog was bitten by a snake nearly 4 months ago. A 40 dioptre acrylic lens with 13 mm haptics was implanted into the lens capsule. In the left eye, posterior synechia was detected in the temporal part of the iris, but decentration of the intraocular lens was not observed. To the best of our knowledge, this is the first report of bilateral cataract caused by ophidism and treated by surgical intervention in a dog.

Key words: Cataract, Intraocular lens, Extra-capsular extraction, Dog

Introduction

Snake bite is a medical emergency. Systemic manifestations of snake envenomation are varied (Perez, 2012). Ophthalmic manifestations of snakebite are rarely reported in literature (Sinirivasan *et al.*, 2005). Ptosis, ophthalmoplegia, optic neuritis including uveitis have been described in human medicine.

The lens has a protein concentration of 33% of its total weight; and most of these proteins are transparent and water-soluble (Hart, 1992; Shahzad *et al.*, 2012). A cataract is the clouding of an otherwise clear ocular lens, with disturbance in the passage of light (Davson, 1980). This can make vision hazy. Advanced cataracts, which impair vision, may require surgical intervention and a plastic, intraocular lens replacement to restore eyesight. The aim of this study was to report a new cause of cataract, namely snake bite induced cataract in a dog. As far as we know, this is the first report of bilateral cataract in a dog caused by ophidism.

Case report

A 3-year-old, 36 kg male mongrel dog was referred to our clinic for the assessment of cataract in both eyes. The owner observed that the dog had no visual acuity with an opaque lens in both eyes for 1 month. The dog was bitten by a snake and treated at a veterinary clinic nearly 4 months ago. The dog presented with mild conjunctival and scleral hyperaemia. Both the direct and

indirect pupillary light reflexes and the menace response had decreased in both eyes. Pharmacological mydriasis was achieved with 1% cyclopentolate hydrochloride (Sikloplejin, Abdi Ibrahim, Turkey), and direct ophthalmoscopy revealed mature cataract in both eyes. Fundus examination could not be performed due to mature cataract in both eyes (Fig. 1). Transocular ultrasonography was performed to evaluate the posterior segment with a 7.5 MHz transducer (SonoSite 180, SoniSite, USA). Both eyes had mature cataract with hyperechogenicity in the lens capsule (Fig. 2). Ultrasonography revealed normal echoic areas in the posterior segment of the eye with no vitreous degeneration. The dog was administered 2 drops of 1% cyclopentolate hydrochloride and 2 drops of 1% tropicamide (Tropamid, Bilim, Turkey) 1 h before surgery. It was premedicated with xylazine, 2 mg/kg body weight (BW), IM, and atropine, 0.04 mg/kg BW, SC; anaesthesia was induced with ketamine, 10 mg/kg BW, IM. Fixation sutures were placed to keep the globe centred and to prevent any ocular movement during the surgery, using 5/0 non-capillary silk (Sterisilk, SSM Co., Turkey). A 2 mm step-shaped corneal incision was made using a 3-mm keratome adjacent to the limbus. The anterior chamber was inflated with hydroxypropyl methylcellulose solution (Appavisc HV PFS, Appasamy, India). Anterior capsulotomy was performed with an irrigating cystotome and an Utrata forceps. The lens cortex and nucleus were removed with a lens loop. A 40 dioptre acrylic lens (Appasamy, India) with 13 mm

haptics was implanted into the lens capsule (Fig. 3A). The corneal incision was sutured with 10/0 monofilament nylon using 3 interrupted sutures (Fig. 3B), and the viscoelastic material was removed from the eye. The right eye was operated on 4 weeks after the surgery on the left eye. Postoperative controls were performed and no postsurgical complications were observed (Table 1). The intraocular lens implant was centred and there was only slight posterior capsular opacity and no vitreous degeneration. The dog was discharged with instructions to the owner that an Elizabeth's collar was to be worn for 4 weeks and exercise was to be limited to leash walks. The dog was to receive 1 drop each of 0.1% dexamethasone suspension, 0.5% ketorolac tromethamine solution, 0.3% ofloxacin solution and tear replacement gel topically in both eyes, q6h, for 4 weeks. After surgery, 20 mg of triamcinolone was injected subconjunctivally. Additionally, 0.5% tropicamide and 0.1% cyclopentolate HCl were administered to both eyes. Subsequently, the dog received 1 drop, q12h, for 4 weeks. The dog was re-examined 4 weeks after surgery; both eyes had focal sutures, a scar where the corneal incision had been made, and pseudophakia with mild capsular fibrosis. In the left eye, posterior synechia was detected in the temporal part of the iris but decentration of the IOL was not observed (Fig. 4). The medication was revised. Direct ophthalmoscopy, maze testing, ability to follow thrown cotton balls and the owner's observations were used to evaluate postoperative restoration and potential complications. No complications were noted within the first year post-surgery.

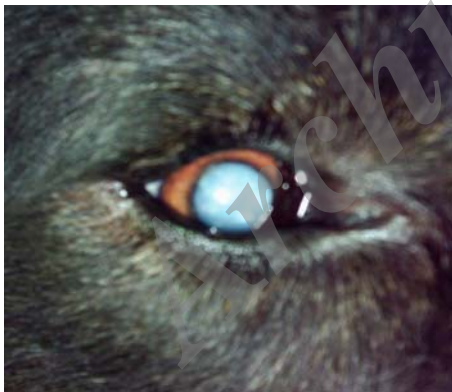

Fig. 1: View of mature cataract in the right eye

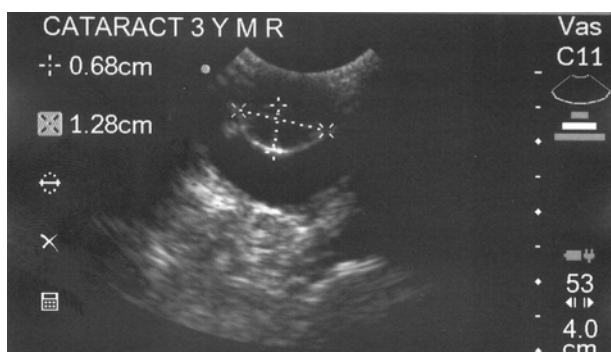


Fig. 2: Ultrasonographic view of mature cataract in the right eye. Note the hyperechoic areas in the lens capsule

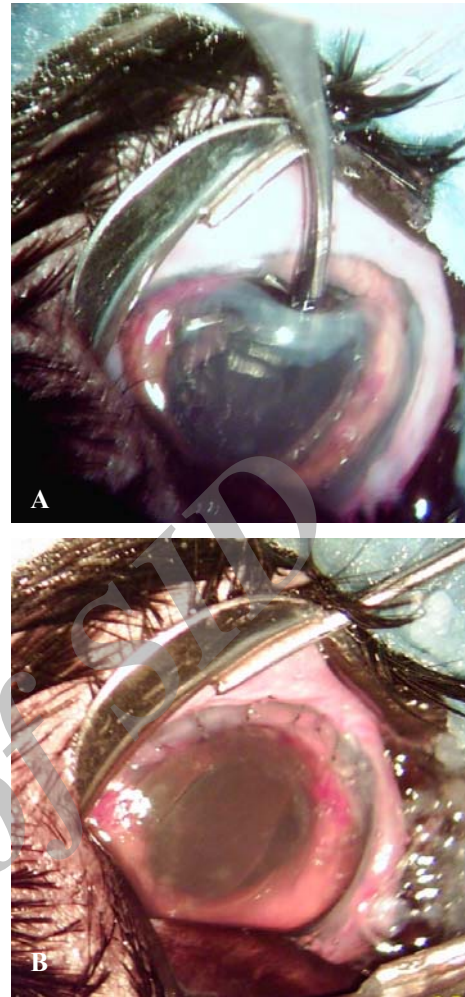


Fig. 3: Photograph of the IOL implantation and pseudophakic eye after ECCE. (A) An IOL was inserted into the capsular bag through a 10-mm corneal incision. (B) After surgery, a properly positioned IOL in the capsular bag can be seen in the left eye

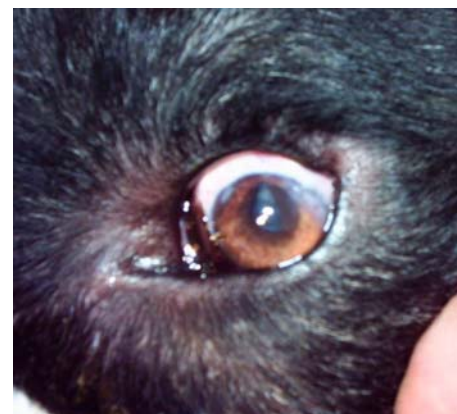

Fig. 4: Posterior synechia in the temporal part of the iris in the left eye 15 days after surgery

Discussion

Many purebred dogs and their crosses are predisposed to juvenile and senile cataracts (Glover and Constantinescu, 1977; Özgencil, 2005). In this study, the dog was of the Newfoundland breed. Most cataracts that

Table 1: Clinical findings of the dog that underwent surgery according to the follow-up periods

Clinical finding	0		3rd day		15th day		30th day		60th day	
	OS	OD	OS	OD	OS	OD	OS	OD	OS	OD
IOP (mmHg)	17	16	15	16	15	16	16	17	17	16
Schirmer Tear Test (mm/min)	16	15	17	20	12	9	13	15	8	12
Aqueous flare	N	N	M	M	M	N	N	N	N	N
Corneal opacity	N	N	M	M	N	N	N	N	N	N
Posterior capsular opacity	-	-	N	N	M	N	M	N	N	N

IOP: Intraocular pressure, OS: Left eye, OD: Right eye, N: Normal, and M: Mild

develop secondary to trauma and toxins are initially cortical in location (Davidson and Nelms, 1998; Grahn *et al.*, 2003). Anamnesis revealed that the dog had been bitten by a snake 4 months ago. Toxic aetiology was considered likely based on the nuclear location of the cataract, the anamnesis, and the age of the dog. Based on our knowledge, there is no literature report on cataract caused by snake bite in dogs. Most snake venoms can include many toxins such as cytotoxin, haematoxin, neurotoxin, and myotoxin (Gold *et al.*, 2002). The developing cataracts are characterised by increased hydration, loss of dry weight, progressive increases in Na⁺ concentration, and progressive decreases in K⁺ concentration (Findlay, 1980). In this case, development of cataract formation depend on the effect of cytotoxin on Na⁺-K⁺ pump in the cell membrane. Cataract formation, especially in nuclear cataracts, is caused by oxidative stress that occurs in all biological systems and particularly in the lens. Oxidative stress and the generation of free radicals result from the normal activity of the mitochondria and other metabolic processes. Oxidation is controlled by an environment of reducing agents. Reducing agents produced in the mitochondria neutralise free radicals (Sanders *et al.*, 1974). A decrease in reducing agents may be related to the toxic effects of snake venom on the mitochondria. Vision threatening complications rarely occur following snakebite. Incidence of ghost cell glaucoma after snakebite has been reported. Venom ophthalmia is an acute and severe form of conjunctivitis and anterior uveitis following ocular exposure (Sinirivasan *et al.*, 2005). Components of various venoms alter transport barrier properties, with the blood-vitreous barrier being most susceptible to damage has been reported (DiMattio *et al.*, 1985). Some venoms have been shown for proteolytic activity against casein and hemoglobin at a number of pH values (Delpierre, 1968). In the dog developed lens opacification occurred in the third month following the bite. We believe that the venom induced barrier damage and showed proteolytic activity on lens. Ultrasonography for posterior segment evaluation is an important presurgical screening tool when posterior segment examination cannot be performed due to lens opacity (Van der Woerd *et al.*, 1993; Gemensky-Metzler and Wilkie, 2004; Kopala, 2008). In this case, ultrasonography revealed normal echoic areas in the posterior segment and there was no vitreous degeneration. It has been reported that 23% of eyes with cataract have vitreous degeneration, based on ultrasonographic examination results (Davidson and

Nelms, 1998; Pennick, 2001; Kopala, 2008). Five stages of cataract maturity have been described (Van der Woerd *et al.*, 1993; Kail and Davidson, 2001). The cataract of the dog examined in this study was classified as mature at the time of diagnosis, as tapetal reflection and details of the fundus were not visible. A mature cataract is characterised by totally opaque lens fibres. The time period required for the development of lens opacity varies from case to case, ranging from a few months to a few years (Van der Woerd *et al.*, 1993; Kail and Davidson, 2001; Kopala, 2008). As reported by the owner, the opacification of the dog's lens developed within a few months after a snake bite. There was no evidence of trauma, chronic uveitis or metabolic disease. Several intraoperative complications may develop, such as rupture of the posterior lens capsule, prolapse of the vitreous into the capsular bag or anterior chamber, anterior capsule fibrosis, tearing of the Descemet's membrane, miosis, iris herniation through the incision, radial tears in the anterior capsule, displacement of lens fragments into the vitreous cavity, posterior capsule opacification, cavitation bubbles, and persistent corneal oedema (Glover and Constantinescu, 1977; Bagley and Lavach, 1994; Williams *et al.*, 1996; Nassie and Davidson 1999; Özgencil, 2005). In the present study, a viscoelastic agent was used to protect the endothelial cells, and no intraoperative complication developed in the eyes. Several postoperative complications have been reported such as corneal wound dehiscence, aqueous leakage, posterior capsule opacification, corneal oedema, glaucoma, uveitis, bacterial endophthalmitis, retinal detachment, retinal haemorrhage, and optic neuritis (Glover and Constantinescu, 1977; Bagley and Lavach, 1994; Nassie and Davidson, 1999; Özgencil, 2005). Extracapsular lens removal appears to produce similar, but possibly more severe endothelial cell trauma related to contact of the lens with the back of the cornea during removal and surgical manipulation. The dog eye reacts strongly to extracapsular lens removal, and postoperative inflammation is much more intense than phacoemulsification. The inflammatory response, along with a greater degree of surgical wound trauma and corneal manipulation, may account for this phenomenon (Glover and Constantinescu, 1977; Gemensky-Metzler and Wilkie, 2004; Kopala, 2008). We determined bilateral mild corneal postoperative opacification and mild aqueous flare 3 days after the operation. In the left eye, we detected mild aqueous flare and posterior synechia without decentration of the IOL 15 days after surgery. In conclusion, this is the first canine case of

bilateral cataract caused by ophidism and treated by surgical intervention, reported in the literature.

References

- Bagley, LH and Lavach, JD** (1994). Comparison of post-operative phacoemulsification results in dogs with and without diabetes mellitus: 153 cases (1991-1992). *J. Am. Vet. Med. Assoc.*, 205: 1165-1168.
- Davidson, MG and Nelms, SR** (1999). Diseases of the lens and cataract formation. In: Gelatt, KN (Ed.), *Veterinary ophthalmology*. (3rd Edn.), Philadelphia, Pennsylvania, Williams and Wilkins. PP: 797-825.
- Davson, H** (1980). *Physiology of the eye*. 4th Edn., New York, USA, Churchill Livingstone, Elsevier. PP: 123-140.
- Delpierre, GR** (1968). Studies on African snake venoms-I. The proteolytic activities of some African viperidae venoms. *Toxicon*. 5: 233-238.
- DiMattio, J; Weinstein, S and Streitman, S** (1985). *In vivo* effects of snake venoms on passive and facilitated glucose transport across blood-ocular and blood-CSF barriers of the rat. *Toxicon*. 23: 63-71.
- Findlay, RE** (1980). Snake venom poisoning in the United States. *Ann. Rev. Med.*, 31: 247-259.
- Gemensky-Metzler, AJ and Wilkie, DA** (2004). Surgical management and histologic and immunohistochemical features of a cataract and retrolental plaque secondary to persistent hyperplastic tunica vasculosa lentis/persistent hyperplastic primary vitreous (PHTVL/PHPV) in a Bloodhound puppy. *Vet. Ophthalmol.*, 7: 369-375.
- Glover, TD and Constantinescu, GM** (1977). Surgery for cataracts. *Vet. Clin. N. Am. Small Anim. Pract.*, 27: 1143-1173.
- Gold, BS; Dart, RC and Barish, RA** (2002). Bites of venomous snakes. *New Eng. J. Med.*, 347: 347-356.
- Grahn, BH; Storey, E and Cullen, CL** (2003). Diagnostic ophthalmology. *Can. Vet. J.*, 44: 603-604.
- Hart, W** (1992). *Adler's physiology of the eye*. 9th Edn., St Louis, USA, CV Mosby. PP: 131-164.
- Kopala, RL** (2008). Unilateral phacoemulsification and intra-ocular lens implantation in a dachshund. *Can. Vet. J.*, 49: 1031-1036.
- Nassie, MP and Davidson, MG** (1999). Surgery of the lens. In: Gelatt, KN (Ed.), *Veterinary ophthalmology*. (3rd Edn.), Philadelphia, PA, USA, Williams and Wilkins. PP: 827-856.
- Özgencil, FE** (2005). The results of phacofragmentation and aspiration surgery for cataract extraction in dogs. *Turk. J. Vet. Anim. Sci.*, 29: 165-173.
- Pennick, D; Daniel, GB; Brawer, R and Tidwell, AS** (2001). Cross-sectional imaging techniques in veterinary ophthalmology. *Clin. Tech. Small Anim. Pract.*, 16: 22-39.
- Perez, ML; Fox, K and Schaer, M** (2012). A retrospective evaluation of coral snake envenomation in dogs and cats: 20 cases (1996-2011). *J. Vet. Emerg. Crit. Care*. 22: 682-689.
- Sanders, D; Cotlier, E; Wyhinny, G and Millman, L** (1974). Cataracts induced by surface active agents. *Exp. Eye Res.*, 19: 35-42.
- Shahzad, S; Suleman, MI; Shahab, H; Mazour, I; Kaur, A; Rudzinskiy, P and Lippmann, S** (2012). Cataract occurrence with antipsychotic drugs. *Psychosomatics*. 43: 354-359.
- Van der Woerdt, A; Wilkie, DA and Myer, W** (1993). Ultrasonographic abnormalities in the eyes of dogs with cataracts: 147 cases (1986-1992). *J. Am. Vet. Med. Assoc.*, 203: 838-841.
- Williams, DL; Boydell, IP and Long, RD** (1996). Current concepts in the management of canine cataract: a survey of techniques used by surgeons in Britain, Europe and the USA and a review of recent literature. *Vet. Rec.*, 138: 347-353.

Archive

*Archive of SID***گزارش علمی: درمان کاتاراکت دو طرفه سگ سانان القا شده توسط افیدیسم با خارج ساختن عدسی خارج کپسولی و کاشت عدسی داخل چشمی****مورات کیبر^۱، سم اورک لیوگلو^۲ و ظفر دوغان^۱**

^۱بخش جراحی، دانشکده دامپزشکی دانشگاه ارسیس، کایسری، ترکیه؛ ^۲بخش جراحی، دانشکده دامپزشکی دانشگاه قرقیز-ترکی ماناس، بیشکک، قرقیزستان؛ ^۳بخش چشم پزشکی، دانشکده پزشکی دانشگاه ارسیس، کایسری، ترکیه

(دریافت مقاله: ۱۱ آبان ۱۳۹۲، پذیرش نهایی: ۱۱ تیر ۱۳۹۳)

هدف از این مطالعه، گزارش یک عامل جدید کاتاراکت، به نام کاتاراکت القا شده توسط نیش مار در یک قلابه سگ بود. یک قلابه سگ نر سه ساله نژاد مونگرل برای بررسی کاتاراکت در دو چشم به کلینیک ما ارجاع داده شد. این سگ حدود ۴ ماه قبل توسط یک مار نیش زده شده بود. یک عدسی اکریلیک ۴۰ دیوپتری همراه با لامسه ۱۳ میلی متری به داخل کپسول عدسی پیوند زده شد. در چشم چپ، سینشی خلفی در بخش گیجگاهی عنبیه شناسایی شد، اما پایین آمدن عدسی داخل چشمی مشاهده نشد. بر اساس آگاهی ما، این اولین گزارش کاتاراکت دو طرفه ایجاد شده توسط افیدیسم و درمان شده با دخالت جراحی در یک قلابه سگ می باشد.

واژه‌های کلیدی: کاتاراکت، عدسی داخل چشمی، خارج ساختن خارج کپسولی، سگ