

## TOXICOPATHOLOGICAL IMPACT OF SUB-LETHAL CONCENTRATION OF LEAD NITRATE ON THE AERIAL RESPIRATORY ORGANS OF 'MURREL' *CHANNA STRIATA* (BLOCH, PISCES)

R. Devi,<sup>\*</sup> T. K. Banerjee

Department of Zoology, Centre of Advanced study, Banaras Hindu University, Varanasi- 221005, India

Received 21 June 2007; revised 18 August 2007; accepted 10 September 2007

### ABSTRACT

Sub-lethal toxicity of lead nitrate solution (46.25mg/L, 5% of 96h LC<sub>50</sub> value) on the air-breathing organ (suprabranchial chamber) of *Channa striata* was analysed for 60 days. Because air-breathing organs of *C. striata* remain in direct contact with waterborne xenobiotics, any change in the aquatic ecosystem was directly reflected in them. Concentration of lead accumulation in the air-breathing organ fluctuated at different stages of exposure. Due to extensive secretory activity, the mucous cells very often got exhausted and disappeared followed by their regeneration. This causes periodic fluctuations in the density of the mucous cells. A significant increase in the gross DNA contents in relation to the respective control is noticed at many stages of exposure. Increases in the RNA and protein contents with simultaneous increase in the mucogenic activity of the mucous cells were also observed. The total lipid contents also showed a periodic fluctuation in their concentration.

**Key words:** Air-breathing organ, Histopathology, Lead nitrate, *channa striata*

### INTRODUCTION

Main sources of lead pollution of aquatic ecosystems are the industrial discharge, atmospheric fall out and sewage effluents. Toxicity of lead in the lung-breathing animals is generally manifested through the contaminated air. In fish, the toxicity of lead is however induced via the gills, which are their main respiratory organs. Keeping this in mind, the gills have widely been used as bio-indicator not only to detect lead toxicity (Parashar and Banerjee, 2002) but also for analyses of several other pollutants (Nath *et al.*, 1989; Munshi and Singh, 1992; Chandra and Banerjee, 2004). Many of the fishes in the Indian subcontinent have developed a bimodal respiratory mechanism for exploitation of water (through their gills and highly vascularized skin) as well as air (through air-breathing organs, ABOs). These ABOs in fishes are analogous to the respiratory organs of the tetrapods. Although in many air-breathing species (for e.g. *H. fossilis* and *C. batrachus*), aerial respiratory organs are modified gill structures, the ABO in *Channa striata*, an

important edible fish, is made of a pair of suprabranchial chamber, which develops dorsal to the gill arches. The outer surface of the suprabranchial chamber in this fish gets highly vascularized for absorbing atmospheric oxygen. In this paper the attempts have been made to use the air-breathing organ (ABO) of *C. striata* as a potential bio-indicator of the contaminated waters. Several researchers have investigated the functional anatomy of the ABOs of different species of *Channa* with respect to their gross anatomy (Liem, 1984), ultrastructure (Hughes and Munshi, 1973) and surface architecture (Hughes and Munshi, 1986). According to Munshi, (1962), the suprabranchial chamber of *Channa* (= *Ophicephalus*) is not a waterproof compartment and remains in free communication with the pharynx. The ABO of *C. striata* therefore faces the contact stress of the environmental hazards, hence needs proper investigation.

### MATERIALS AND METHODS

#### *Exposure to lead nitrate*

Fish (12-16cm length and 50-55g weight) were

<sup>\*</sup>Corresponding author-Email: [tkbzool@yahoo.co.in](mailto:tkbzool@yahoo.co.in)

Tel: +98 542 3112150, Fax: +98 542 2368174

purchased from the local market, Chauka Ghat Varanasi, UP, India and acclimatized to laboratory conditions for three weeks. Fish were fed with minced goat liver and water was renewed every 24h. Twenty groups of ten acclimatized fish (20-22cm length and 40-45g body weight) each were exposed to 20L of 46.25mg/L lead nitrate (Glaxo India Ltd., Mumbai; 99% pure) {5% of 96h  $LC_{50}$  value, 925mg/L (Spearman-Karber method, Hamilton *et al.*, 1977)} solution prepared in tap water (having dissolved  $O_2$  6.3mg/L, pH=7.2, water hardness 23.0mg/L and room temperature  $28\pm 2^\circ C$ ) for 60days. Parallel control groups of fish were kept in 20L of plain tap water (without addition of lead nitrate). Feeding was allowed to both experimental and control fish throughout the tenure of experiments. Five fish, each from the experimental as well as control groups, were sacrificed after anaesthetization in ice at different periods of exposure. While the ABO of one side was used for histopathological analyses, other side was subjected to biochemical analyses. The entire experiment was repeated twice. Remaining fish were sacrificed to analyse the lead accumulation.

#### *Estimation of lead accumulation*

ABOs were dried in an oven at  $80^\circ C$  for 12h. Tissues were digested for overnight in concentrated nitric acid and perchloric acid (3:1) at  $100^\circ C$  for overnight. The digested samples were diluted in de-ionised water and lead concentrations were measured using "Perkin-Elmer (Model 2380) atomic absorption spectrophotometer.

#### *Histopathological analyses*

Six  $\mu m$  paraffin sections of ABOs fixed in Bouin's fluid and 10% neutral formalin were stained in Ehrlich's haematoxylin/eosin (H/E) (Pearse, 1985) for routine histopathological observations. Sections were also stained for certain carbohydrate, protein and nucleic acid moieties (Pearse, 1985). The density and area of MCs and the thickness of the epidermis were measured from the Alcian Blue pH=2.5/Periodic Acid Schiffs stained sections with the help of Camera lucida (Rajan and Banerjee, 1994; Paul and Banerjee, 1996) and were subsequently confirmed by an Image analyser.

*Biochemical analyses*-Nucleic acid estimation  
10% homogenate of 250mg ABO was prepared

in tris-HCl buffer on ice. Acid soluble free phosphates and lipid moieties were removed by 10% perchloric acid and ethanol-ether (3:1) respectively. The final precipitate was dissolved in 5% trichloroacetic acid (TCA), centrifuged at 5000 rpm for 20min and supernatant was used for nucleic acid estimation. The DNA content was estimated with freshly prepared diphenylamine reagent and the blue colour developed was measured at 600nm. Standard curves were drawn using different known concentrations of calf thymus DNA (Schneider, 1957). The RNA content was estimated with freshly prepared orcinol reagent and the greenish-blue colour developed was measured at 660nm. Standard curves were drawn with yeast RNA (Schneider, 1957).

#### *Protein estimation*

The proteins were precipitated in 5% TCA and the precipitates were dissolved in 1N KOH. Total protein contents of the respiratory organs were estimated with Folin's reagent following the method of Lowry *et al.*, (1951). The blue-coloured product was measured at 600nm. Standard curves were prepared with bovine serum albumin.

#### *Lipid estimation*

The total lipids were extracted in chloroform methanol (2:1) following the method of Folch and Stanely (1956).

For statistical analyses, each experiment was repeated twice with five fish and the values have been expressed as mean $\pm$ SE. Two tailed students' t-test and one-way analysis of variance (ANOVA) followed by Duncan's multiple range tests were performed by Microsoft excel software. Since there were no significant variations between the values obtained from different control groups, the average value of all the control groups was taken into account.

## RESULTS

#### *Lead accumulation*

No lead accumulation was recorded in the ABO of unexposed fish. Following exposure, mean accumulation values of lead in the ABO of exposed fish were significantly increased (Fig. 1). Maximum accumulation was noted after 40day.

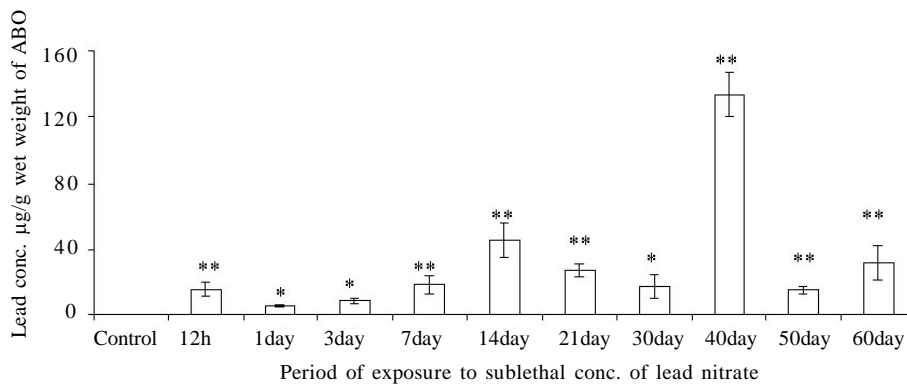


Fig 1: Lead accumulation in the ABO of *C. striata* after sublethal concentration of lead nitrate exposure. Values are expressed as mean±SE, No.=10, Values are significantly different from control (\* = P<0.05; \*\* = P<0.01)

*Histopathological alterations*

*Control:* A stratified epithelium containing islets of highly vascular components lines the ABO (suprabranchial chamber). Each of the islets is

composed of small groups of vascular papillae (VP) made up bunches of minute blood capillaries (BLCs) through which gaseous exchange takes place (Fig. 2a). These VP remain connected with

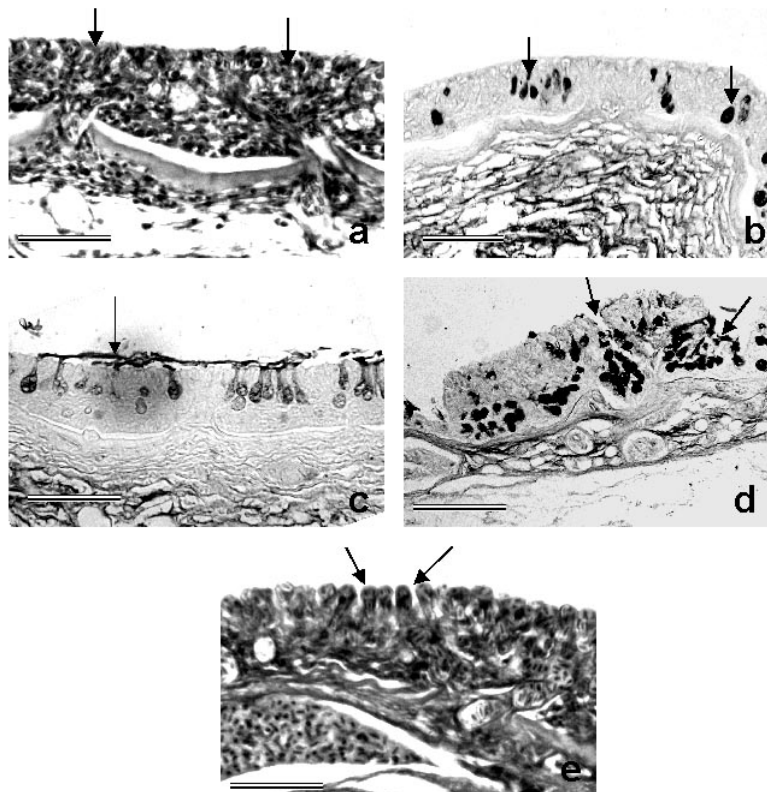


Fig 2: Histopathological alterations in the ABO of the *C. striata* under control condition (a,b) and after sublethal concentration of lead nitrate exposure (c-e)

(a) structural organization of the respiratory epithelium lining the floor of its lumen containing well formed vascular papillae at the surface of the epithelial lining. (Haematoxylin/Eosin), (b) distribution of MCs (!) in the epithelial lining (Alcian blue pH=2.5/Periodic Acid Schiff, AB 2.5/PAS), (c) a thick slimy layer (!) laid on the surface of the respiratory epithelium (AB 2.5/PAS), (d) enormous increase in the number of MCs opening in common pit like depressions (!) on the respiratory epithelium (AB 2.5/PAS), (e) bulging out of the blood channels (!) of vascular papillae from the surface of the respiratory epithelium giving them lamellar appearance (H/E). Scale bar 0.1 mm.

the underlying main blood supply via fine blood vessels. The mucous cells (MCs) present in the middle layers, open onto the surface of the epithelium via small pores (Figs. 2a, b.). A thin slimy layer often covers the surface of the epithelium lining the floor of lumen of the ABO.

*Exposed:* Following exposure, patches of thick slime covered the outer surface of the epithelium (Fig. 2c). Between 2-6h of exposure, the newly formed MCs engorged almost the entire inner layer of epithelial lining (Figs. 2c, d). Thus the blood channels (BLCs) got compressed. Often a prominent vacuole occupied the central core of MCs staining more intensely. Even though the staining intensities of these MCs increased with alcian blue pH=2.5 (AB 2.5), alcian blue pH=2.5/periodic acid Schiffs (PAS) and AB 2.5/Bismark brown (BB), they showed negative reaction with alcian blue pH=1.0 and aldehyde fuchsin techniques (Table 1). This staining property of the MCs almost remained unchanged up to 12h. Their number, however, decreased significantly ( $P<0.01$ ) (Table 2) after 12h.

After 3days, due to extensive hyperplasia of the MCs, the ECs and the BLCs got further compressed. Most of these MCs stained very strongly (greenish blue) with AB 2.5/PAS, moderately to strongly with AB 2.5, BB and AB 2.5/BB and moderately with PAS (Table 1). However, after 7day the density as well as intensities of some of the staining reactions of the MCs decreased markedly ( $P<0.01$ ) (Table 2). The membrane like barrier between the engorged RBCs of the BLCs and the air in the lumen became very thin due to extensive stretching. The density and staining intensity of the MCs increased once again after 15day. Also the entire epithelial lining showed great hyperplasia due to regeneration. A plexus of fine blood capillaries formed a network through out the thickness of the epithelium. The round globular projections of the BLCs at the epithelial surface gave false appearance of secondary lamellae of a gill (Fig. 2e). Increased density of chloride cells is also an important histopathological manifestation noticed due to lead exposure.

Table 1: Summary of the histochemical alterations in the carbohydrate contents of the MCs of the ABO *C. striata* exposed to different intervals of lead nitrate solution

Period of exposure	Intensity of reaction with different histochemical techniques						
	PAS	AB 2.5	AB2.5/AS*	AB 1.0	AF	BB	AB2.5/BB**
0 h	2-3	2-3	2-4	1	0	3	3
1 h	2-3	3-4	2-4	0	0	0-1	2-3
2 h	2-3	3-4	2-3	0	0	1	3
4 h	2-3	2-3	3-4	0	0	1-2	2-3
6 h	2-4	2-3	2-4	0	0	2-3	3-4
12 h	2-3	2-3	3-4	0	0	2	4
1 day	3-4	2-3	4	0	0	3	2-3
3 day	3-4	3-4	3-4	0	0	3	2-3
7 day	2-3	3-4	4	0	0	0-1	2-3
14 day	2-3	3-4	3-4	0	0	1-2	2-3
21 day	3-4	3-4	3-4	0	0	1-2	3-4
30 day	1-2	3-4	4	0	0	2-3	3-4
40 day	1-2	3-4	4	0	0	1-2	2-3
50 day	2-3	2-3	4	0	0	0-1	1-2
60 day	2-3	2-3	2-4	0	0	2-3	2-3

Symbols and abbreviations:

PAS = Periodic acid Schiff; AB 2.5=Alcian blue pH=2.5; AB 1.0=Alcian blue pH=1.0; AF=Aldehyde fuchsin; BB = Bismark brown; - = to; 0= negative reaction; 1=weak reaction; 2=moderate reaction; 3=strong reaction; 4=very strong reaction; \*=Variously stained reactions ranging from various shades of magenta, violet to greenish-blue in the same or different MCs; \*\*=variously stained reactions ranging from brown, brownish-green to greenish brown.

Table 2: Alterations in the density and percentage area occupancies of goblet MCs in the epithelial lining of ABO following exposure to sublethal concentration of lead nitrate solution

Period of exposure	Density of MCs (No. of MCs/mm <sup>2</sup> )	% Area occupied by MCs
0 h	0.68 ± 0.01	5.63 ± 0.05
1 h	0.33 ± 0.02**	4.66 ± 0.20
2 h	0.66 ± 0.06	5.63 ± 0.38
4 h	0.71 ± 0.05	7.79 ± 0.66**
6 h	0.99 ± 0.04*	9.87 ± 0.35**
12 h	0.75 ± 0.03	6.77 ± 0.41**
1 day	0.54 ± 0.02	5.46 ± 0.21**
3 day	0.62 ± 0.04	7.99 ± 0.36**
7 day	0.39 ± 0.04	4.98 ± 0.37**
14 day	0.33 ± 0.13**	3.08 ± 0.17**
21 day	0.68 ± 0.02	9.79 ± 0.43**
30 day	1.15 ± 0.05**	10.15 ± 0.35**
40 day	0.80 ± 0.04	8.46 ± 0.33**
50 day	0.87 ± 0.05*	10.10 ± 0.83**
60 day	0.88 ± 0.03	9.59 ± 0.49**
ANOVA	P<0.01	P<0.01

Values are expressed as mean ± SE, No.=10, Significantly different from control value (\* = P<0.05; \*\* =P<0.01); values without any \* =P>0.05

**Biochemical alterations**

The suprabranchial chamber (ABOs) of the control *C. striata* contained 0.69mg DNA, 7.95mg RNA, 79.23mg proteins and 185.71mg lipids per gram of wet weight of the tissue. ABO showed significant increase in the total DNA and RNA contents after exposure (Table 3). However, after 21day, there was a significant decrease in their contents. The amount of proteins also increased significantly (P<0.01) after several stages of exposure (Table 3). Initially, within 2h and 6h, the lipid contents decreased significantly (P<0.01) followed by fluctuations through out the remaining period of exposure (Table 3).

**DISCUSSION**

Deposition of lead took place in the ABO of *C. striata* throughout the period of exposure. Fantin *et al.*, (1992) noticed significant deposition of lead

Table 3: Variations in the total nucleic acids (DNA and RNA), proteins and lipid contents in the ABO of *C. striata* at various stages of sublethal concentration of lead nitrate exposure

Period of exposure	Amounts of the chemical constituents (mg/g wet weight of tissues)			
	Nucleic acids		Protein	Lipids
	DNA	RNA		
0 h	0.69 ± 0.01	7.95 ± 0.05	79.23 ± 1.04	185.71 ± 2.03
1 h	0.91 ± 0.03**	11.46 ± 0.45**	205.71 ± 6.96**	150.00 ± 4.05*
2 h	0.56 ± 0.03**	8.74 ± 0.50*	81.94 ± 6.16	140.16 ± 6.12**
4 h	0.85 ± 0.05*	11.95 ± 0.63**	105.37 ± 3.83**	106.45 ± 7.79**
6 h	0.83 ± 0.05*	8.38 ± 0.32	106.02 ± 2.91**	82.87 ± 4.31**
12 h	0.81 ± 0.05*	6.52 ± 0.64	91.99 ± 1.94	215.95 ± 3.15*
1 day	0.80 ± 0.03	8.57 ± 0.48	106.11 ± 2.16**	307.69 ± 1.94**
3 day	1.08 ± 0.14	14.37 ± 0.26**	109.97 ± 1.59**	151.29 ± 1.3*
7 day	1.06 ± 0.08	8.71 ± 0.49**	122.31 ± 1.42**	163.22 ± 1.85
14 day	1.41 ± 0.15	19.00 ± 0.87**	151.83 ± 2.38**	230.22 ± 2.79*
21 day	0.38 ± 0.03**	6.13 ± 0.5*	93.75 ± 1.39**	285.15 ± 1.91*
30 day	0.87 ± 0.04*	8.75 ± 0.71	104.77 ± 1.59**	168.47 ± 4.03
40 day	0.99 ± 0.09	10.31 ± 1.26	105.16 ± 1.50**	180.95 ± 2.39
50 day	1.80 ± 0.09**	10.65 ± 0.72	110.37 ± 1.29*	178.95 ± 3.80
60 day	1.10 ± 0.15	15.99 ± 0.28**	186.16 ± 0.91*	220.00 ± 1.91*
ANOVA	P<0.01	P<0.01	P<0.01	P<0.01

Values are expressed as mean ± SE, No.=10, Significantly different from control value (\* = P<0.05; \*\* =P<0.01); values without any \* =P>0.05

in the hepatocytes of *Carassius carassius* after 48h of exposure. Tao *et al.*, (1999) suggested the two-step process involved in the uptake of particulate lead by fish gills: (i) adherence of the particles on the gill surface where mucus was

attached and (ii) desorption of lead from the particles under conditions of the gill microenvironment. While studying the uptake of particulate lead via gills of gold fish, Lin *et al.*, (2001) noticed deposition of the particulate lead

on the gill surface temporarily that sloughed along with the slime into the water flow.

The slime secreted by the ABO of *C. striata* especially after lead nitrate exposure contains a mixture of neutral and acidic glycoproteins as evidenced by the variations in the staining properties shown by the same or different MCs at the same or different stages of exposure (Table 1). This is because ABO of *C. striata* always remains in direct contact with the dissolved toxicants. Thus, due to masking of the heavy metal salts with the mucus from the respiratory surfaces of *C. striata*, the toxicity of the irritant substantially reduces.

The density of the chloride cells in the ABO of lead nitrate exposed *C. striata* showed periodic increases followed by decreases especially in the initial stages of exposure. This may perhaps be due to their regeneration followed by degeneration. Sola *et al.*, (1994) also noticed cellular degeneration followed by renewal with modification in the number and morphology of chloride cells of lead exposed rainbow trout (*Oncorhynchus mykiss*). Rajbanshi and Gupta (1988), Kurant *et al.*, (1997), Mazon *et al.*, (1999, 2002), and Costa and Fernandez (2002) however reported increased density of chloride cells following exposure to ambient toxicants.

The irritant induced alterations in ABO histology represent damage as well as compensatory response of the fish. The illustrations of the first (representing damage) are necrosis of the epithelial cells and dilatation of the blood capillaries of respiratory lamellae. The compensatory responses include hypertrophy and hyperplasia of the respiratory epithelium, MCs and chloride cells.

The DNA contents of ABO increased significantly at certain stages of exposure. These stages were also marked by the extensive hyperplasia. It is important to note that the total protein contents of the ABO of *C. striata* increased due to lead salt treatment (Table 3). The protein contents increased with simultaneous increase in the mucogenic activity of the MCs. Increased quantity of RNA within the MCs confirms the active synthesis of slime that is mainly made up of glycoproteins. Secretion of slime provides very effective defence layer for negotiating the toxicity

of the lead salt for keeping the respiratory surface of ABO un-damaged.

Chandravathy *et al.*, (1987) also found an increase in the total protein concentration of muscle, liver, gills, kidney and brain of the climbing perch *A. scandens* following lead nitrate exposure. Elevation in the ratio of protein contents was also noticed after treatments with other heavy metals (e.g. mercury, Radi and Matkovics, 1988 and cadmium, Rajanna *et al.*, 1981 and Joshi and Bose, 2002). Increased protein synthesis against the toxicity of heavy metals leads to the adaptation of organisms to a toxic environment and also induces tolerant stress (Ferragut *et al.*, 1991). Continuous exposure of freshwater fish, *H. fossilis* to sub-lethal concentration of lead nitrate for 35 days however causes decreased soluble proteins and RNA contents of its liver (Jain *et al.*, 1996). While comparing the effects of lead chloride, lead acetate and aluminium compounds on the air-breathing catfish *Clarias lazera*, Abdelhamid and el-Ayouty (1991) noticed that lead chloride decreased protein contents of kidney. Xie *et al.*, (1986) reported a reduction in serum protein contents of bighead carp (*Aristichthys nobilis*) following exposure to lead. Following lead nitrate exposure, the total lipid contents of ABO of *C. striata* decrease in the early stages of exposure (Table 3). This may perhaps be due to their use in extensive slime secretion. Subsequently at various stages, the volume of the lipids fluctuated. The lipid content also becomes subnormal at several stages. Following cadmium exposure, Fantin *et al.*, (1992) however found increased lipid contents. Similarly the total lipid contents in the liver, muscle, kidney and ovary of *Clarias batrachus* increased following exposure to carbofuron toxicity (Begum and Vijayaraghavan, 2001).

Results of this study showed that toxicopathological manifestations of the sublethal concentration of lead nitrate in the ABO of *Channa striata* are manifested in the form of hyperplasia and hypertrophy of the (MCs) with increased mucogenic activity, increased synthesis of proteins and decreased amount of lipid contents. Extensive accumulation of lead and increased density of chloride cells are other important alterations. Analyses of these toxicopathological alterations

suggest that the ABO of *Channa striata* can very well be used as a potent potential bio-indicator for evaluation of polluted waters contaminated with heavy metals including the lead.

## ACKNOWLEDGMENTS

The authors are thankful to University Grant Commission, New Delhi for financial support. R. Devi is thankful to Council of Scientific and Industrial Research, New Delhi, INDIA for the award of a Junior Research Fellowship.

## REFERENCES

- Abdelhamid, A. M., el-Ayouty, S. A., (1991). Effect on catfish (*Clarias lazera*) composition of ingestion rearing water contaminated with lead or aluminium compounds. Arch. Tierernahr., **41**: 757-763.
- Begum, G., Vijayaraghavan, S., (2001). Carbofuran toxicity on total lipids and free fatty acids in air breathing fish during exposure and cessation of exposure *-in vivo*. Environ. Monit. Assess., **70**: 233-239.
- Chandra, S., Banerjee, T. K., (2004). Histopathological analysis of the respiratory organs of *Channa striata* subjected to air exposure. Veter Arhiv., **74**: 37-52.
- Chandravathy, V. M., Venugopal, N. B. R. K., Sultana, S., Reddy, S. L. N., (1987). Lead induced changes in the protein metabolism of a freshwater fish *Anabas scandens*. Trends in Life Sciences., **2**: 13-20.
- Costa, O. T. F., Fernandez, M. N., (2002). Chloride cell changes induced by nitrite exposure in an Amazonian fish species. Aquatic Toxicology: Mechanism and Consequences. Eds. Chris Kennedy, Alan Kolok and Don MacKinlay. Int. Congress of Fish Biology, Canada., 51-61.
- Fantin, A. M., Franchini, A., Trevisan, P., Pederzoli, A., (1992). Histomorphological and cytochemical changes induced in the liver of goldfish *Carassius carassius* var. *auratus* by short-term exposure to lead. Acta. Histochem., **92**: 228-235.
- Ferragut, C. O., Espigares, M., Dive, D., (1991). Stress protein synthesis, a potential toxicity maker in *Escherichia coli*. Ecotoxicol. Environ. Safety., **21**: 275-282.
- Folch, J. M., Stanelly, G. H. S., (1956). A simple method for the isolation and purification of total lipids from animal tissues. J. Biol. Chem., **226**: 497-509.
- Hamilton, M. A., Russo, R. C., Thurston, R.V., (1977). Trimmed Spearman-Kärber method for estimating median lethal concentrations in toxicity bioassays. Environ. Sci. Technol., **11**: 714-719.
- Hughes, G. M., Munshi, J. S. D., (1973). Nature of air-breathing organs of the Indian fishes *Channa*, *Amphipnous*, *Clarias* and *Saccobranchus* as shown by electron microscopy. J. Zool. Lond., **170**: 245-270.
- Hughes, G. M., Munshi, J. S. D., (1986). Scanning electron microscopy of the accessory respiratory organs of the snakehead fish, *Channa striata* (Bloch) (Channidae, Channiformes). J. Zool. Lond., **209**: 305-317.
- Jain, S. K., Raizada, A. K., Shrivastava, S., Jain, K., (1996). Protective effect of zeolite on the toxicity of lead to freshwater fish. Fresenius Environ. Bull., **5**: 466-468.
- Joshi, P. K., Bose, M., (2002). Toxicity of Cadmium: A comparative study in the air breathing fish, *Clarias batrachus* and in non-air breathing one, *Ctenopharyngodon idellus*. Aquatic Toxicology: Mechanism and Consequences. Eds. Chris Kennedy, Alan Kolok and Don MacKinlay. Int. Congress of Fish Biology, Canada., 109-118.
- Kurant, V. Z., Stolyar, O. B., Balaban, R. B., Homechivck, V. O., (1997). Effect of Copper and lead on the nucleoproteins and thiols in tissues of Carp (*Cyprinus carpio* L.). The society for experimental biology annual meeting, (7-11 April). Univ. of Kent at Canterbury, online.
- Liem, K. F., (1984). The Muscular basis of aquatic and aerial ventilation in the air breathing teleost *Channa*. J. Exp. Biol., **113**: 1-18.
- Lin, M. C., Liao, C. M., Liu, C.W., Singh, S., (2001). Bioaccumulation of arsenic in aquaculture large-scale mullet *Liza macrolepis* from blackfoot disease area in Taiwan. Bull. Environ. Contam. Toxicol., **67**: 91-97.
- Lowry, O. H., Rosebrough, N. J., Farr, A. L., Randell, R. J., (1951). Protein measurement with foline phenol reagent. J. Biol. Chem., **193**: 265-275.
- Mazon, A. F., Cerqueira, C. C. C., Monteiro, E. A. S., Fernandez, M. N., (1999). Acute copper in fresh-water fish: morphological and physiological effects. In 'Biology of Tropical Fishes'. Eds. Val, A L. and V. M. F. Almeida-Val.) INPA, Manaus, Brazil, 261-275.
- Mazon, A. F., Monteiro, E. A. S., Pinheiro, G. H. D., Fernandez, M. N., (2002). Hematological and physiological changes induced by short-term exposure to copper in the freshwater fish, *Prochilodus scrofa*. Braz. J. Biol., **62**: 621-631.
- Munshi, J. S. D., (1962). On the accessory respiratory organs of *Ophicephalus punctatus* and *Ophicephalus striatus*. J. Linn. Soc. London (Zool.), **44**: 616-626.
- Munshi, J. S. D., Singh, A., (1992). Scanning electron microscopic evaluation of effects of low pH on gills of *Channa punctatus* (Bloch). J. Fish Biol., **41**: 83-89.
- Nath, K., Kumar, N., Srivastav, A. K., (1989). Chromium induced histological alterations in the gills of a freshwater teleost, *Colisa fasciatus*. The Science of the Total Environment., **80**: 293-296.
- Parashar, R. S., Banerjee, T. K., (2002). Toxic impact of lethal concentration of lead nitrate on the gills of air-breathing catfish, *Heteropneustes fossilis* (Bloch). Vet Arhiv., **72**: 167-183.
- Paul, V. I., Banerjee, T. K., (1996). Analysis of ammonium sulphate toxicity in the catfish *Heteropneustes fossilis* using mucocyte indexing. Pol. Arch Hydrobiol., **43**: 111-125.
- Pearse, A.G.E., (1985). Histochemistry- Theoretical and Applied. Edinburgh/ London. Churchill Livingstone Inc., **2**: 441-1055.
- Radi, A. A., Matkovic, B., (1988). Effects of metal ions on the antioxidant enzyme activities, protein content and lipid peroxidation of carp tissues. Comp. Biochem. Physiol. (C), **90**: 69-72.

- Rajan, M. T., Banerjee, T. K., (1994). Toxicity of fish disinfectant, malachite green to *Heteropneustes fossilis* and induced changes in the mucocyte density of its skin. *J. Freshwater Biology*, **6**: 177-182.
- Rajanna, B. K., Chapatwala, K. D., Vaishnav, D. D., Desai, D., (1981). Changes in ATPase activity in tissues of rat fed on cadmium. *J. Envi. Biol.*, **2**: 1-9.
- Rajbanshi, V. K., Gupta, A. K., (1988). Alterations in the architecture of gill surface produced by water borne copper in *Heteropneustes fossilis* (Bloch). *Acta hydrochim et hydrobiol.*, **16**: 325-332.
- Schneider, W.C., (1957). Determination of nucleic acids in tissue by pentose analysis. In *Methods of Enzymology*. Ed. S. P. Calowick and N. O. Kaplan, Academic press, N. Y.. 680.
- Sola, F., Masoni, A., Isaia, J., (1994). Effects of lead loads on branchial osmoregulatory mechanisms in the rainbow trout (*Oncorhynchus mykiss*). *J. Appl. Toxicol.*, **14**: 343-349.
- Tao, S., Liu, C., Dawson, R., Cao, J., Li, B., (1999). Uptake of particulate lead via the gills of fish (*Carassius auratus*). *Arch. Environ. Contam. Toxicol.*, **37**: 352-357.
- Xie, J., Guo, Y., Zhou, Q., Ou, D., Yang, C., Lai, Q., Liu, Y., (1986). Relation between toxicity of heavy metals, cadmium, lead and copper in sediments and some biochemical alterations in fish. *Hunan Shifan Daxue Xuebao, Ziran Kxueban.*, **9**: 2-14.