

Focal Injection of Ethidium Bromide as a Simple Model to Study Cognitive Deficit and Its Improvement

Mahdi Goudarzvand ^{1*}, Samira Choopani ², Alireza Shams ³, Mohammad Javan ⁴, Zohreh Khodaii ⁵, Farhad Ghamsari ⁶, Naser Naghdi ², Abbas Piryaei ⁷, Abbas Haghparast ⁸

1. Department of Physiology and Pharmacology, School of Medicine, Alborz University of Medical Sciences, Karaj, Iran.

2. Department of Physiology and Pharmacology, Pasteur Institute, Tehran, Iran.

3. Department of Anatomy, School of Medicine, Alborz University of Medical Sciences, Karaj, Iran.

4. Department of Physiology, Faculty of Medicine, Tarbiat Modares University, Tehran, Iran.

5. Department of Nutrition, School of Medicine, Alborz University of Medical Sciences, Karaj, Iran.

6. Department of Internal Medicine, School of Medicine, Alborz University of Medical Sciences, Karaj, Iran.

7. Department of Anatomy, Faculty of Medicine, Shahid Beheshti University of Medical Sciences, Tehran, Iran.

8. Neuroscience Research Center, Faculty of Medicine, Shahid Beheshti University of Medical Sciences, Tehran, Iran.

Article info:

Received: 10 April 2015

First Revision: 20 July 2015

Accepted: 12 September 2015

ABSTRACT

Introduction: Memory and cognitive impairments are some of devastating outcomes of Multiple Sclerosis (MS) plaques in hippocampus, the gray matter part of the brain. The present study aimed to evaluate the intrahippocampal injection of Ethidium Bromide (EB) as a simple and focal model to assess cognition and gray matter demyelination.

Methods: Thirty Wistar rats were divided into three groups: control group, which received saline, as solvent of EB, into the hippocampus; and two experimental groups, which received 3 μ L of EB into the hippocampus, and then, were evaluated 7 and 28 days after EB injection (n=10 in each group), using a 5-day protocol of Morris Water Maze (MWM) task as well as Transmission Electron Microscopy (TEM) assay.

Results: Seven days after EB injection, the behavioral study revealed a significance increase in travelled distance for platform finding in the experimental group compared to the control group. In addition, the nucleus of oligodendrocyte showed the typical clumped chromatin, probably attributed to apoptosis, and the myelin sheaths of some axons were unwrapped and disintegrated. Twenty-eight days after EB injection, the traveled distance and the time spent in target quadrant significantly decreased and increased, respectively in experimental groups compared to the control group. Also, TEM micrographs revealed a thin layer of remyelination around the axons in 28 days lesion group.

Discussion: While intracerebral or intraventricular injection of EB is disseminated in different parts of the brain and can affect the other motor and sensory systems, this model is confined locally and facilitates behavioral study. Also, this project could show improvement of memory function subsequent to the physiological repair of the gray matter of the hippocampus.

Key Words:

Behavior, Remyelination,
Ethidium bromide,
Hippocampus, Rat

1. Introduction

Demyelination is the most common complication of Multiple Sclerosis (MS) in which the myelin sheath around the axons gets damaged. Most of the time, demyelination

is compensated by the spontaneous formation of a thin layer of remyelination (Smith, Blakemore, & McDonald, 1979; Woodruff & Franklin, 1999).

Direct injection of Ethidium Bromide (EB) is a simple tool for induction of neural cells degeneration and

* Corresponding Author:

Mahdi Goudarzvand, PhD

Address: Department of Physiology and Pharmacology, School of Medicine, Alborz University of Medical Sciences, Eshteraki Ave., Baghestan Blv., Karaj, Iran. P.O. Box: 3148/561

Tel: +98 (912) 5644620 Fax: +98 (26) 34302090

E-mail: m118medical@yahoo.com

helps researchers to study the demyelination and remyelination processes (Blakemore, 1982; Bondan, Lallo, Sinhorini, Pereira, & Graça, 2000; Bondan et al., 2006). While this model is limited to local area and facilitates behavioral or other studies, intracerebral or intraventricular injection of EB disseminates in different parts of the brain (Guazzo, 2005) and can affect the motor and sensory systems.

The hippocampus, a white and grey part of the CNS, is an active portion of the adult brain, where neural stem cells continue to proliferate and differentiate into other neural cells throughout the life (Becq, Jorquera, Ben-Ari, Weiss, & Represa, 2005; Nakatomi et al., 2002). This neurogenesis is associated with learning and memory formation (Gould, Beylin, Tanapat, Reeves, & Shors, 1999; Kempermann, Kuhn, & Gage, 1997). This part of the brain is especially involved in spatial memory i.e. memory of the objects around the visual field (Baulieu & Robel, 1990).

Several human studies, using MRI technique, have reported that hippocampal formation is affected in MS. In their findings, the demyelinated plaques were observed in different parts of the hippocampus. Such plaques in the hippocampus cause memory and cognitive deficits and neuropsychological abnormalities (Bagert, Camplair, & Bourdette, 2002; Geurts et al., 2007; Rao, Leo, Bernardin, & Unverzagt, 1991; Sailer et al., 2003; Nagaraj et al., 2013). Spontaneous remyelination which occurs after demyelination may improve memory. Therefore, the present study aimed to evaluate the intrahippocampal injection of ethidium bromide as a simple and focal model to assess cognition and gray matter demyelination.

2. Methods

2.1. Animals

All experiments were carried out on thirty adult male Wistar rats weighting 200–250 g (Pasteur Institute, Tehran, Iran). Five rats were located in each cage under a 12:12 h light/dark cycle in a room with controlled temperature ($23\pm 2^\circ\text{C}$). Food and water were provided ad libitum. All procedures were performed according to international guidelines on the use of laboratory animals according to the Helsinki Ethical Committee for animal research.

2.2. Microinjection of ethidium bromide

About 7 days prior to beginning of the behavioral experiments, the animals were anaesthetized with IP injection of a mixture of ketamine hydrochloride (100 mg/kg) and xylazine (5 mg/kg). Rats were randomly divided into

three groups ($n=10$ in each group); one control group and two EB groups. The two experimental groups were analyzed 7 and 28 days after EB (CinnaGen Co.) injection. In the control group, saline, as solvent of the EB, was injected into the right dentate gyrus of hippocampal formation, while in the lesioned groups demyelination was induced unilaterally by single direct injection of 3 μL of 0.01% EB in sterile 0.9% saline (Sim, Hinks, & Franklin, 2000), using appropriate stereotaxic coordinates; AP=-2.8; ML=1.8; DV=2.5 (Paxinos & Watson, 2006).

2.3. Behavioral evaluation

2.3.1. Morris Water Maze Procedure

The Morris Water Maze (MWM) has been described extensively by McNamara et al. (McNamara & Skelton, 1993). The tracking system was located directly above the maze to measure the traveled distance, escape latency (time spent to reach the platform), and the time spent in target zone to evaluate spatial learning and memory. Swimming speed was considered as an index of sensory motor system's functionality.

A 5-day protocol (the first 4 days invisible platform and day 5 visible one) was performed on 3 groups that has been described extensively by Soodi et al. (2010).

2.3.2. Animal training

In hidden platform experiments, each rat was given 4 daily trials for 4 days in which a random set of 4 different start locations (north, south, west, and east) was used. Each time rats were given 60 seconds to reach the platform. If rats could not reach the platform before 60 seconds, they would be gently guided to platform. Rats had 30 seconds time to stay on the platform and evaluate the surrounding. On the fifth day, platform was covered with aluminum foil and located 1 cm above water. Reaching the platform by rats was related to their motor and visionary health. After every day experiment, animals were dried and transferred to home cages.

2.4. Ultrastructural analysis of hippocampal formation

Two rats from each experimental group were anesthetized and submitted to intracardiac perfusion with Karnovsky solution (2.2% glutaraldehyde and 2.5% paraformaldehyde in 0.1 M phosphate buffer, pH 7.35) for electron microscopy. Subsequently, sliced blocked of the brain were dissected out and postfixed in the same fixative for 2 h and in OsO_4 for 30 min. After intense washing with 0.1 M phosphate buffer (pH 7.35), the tis-

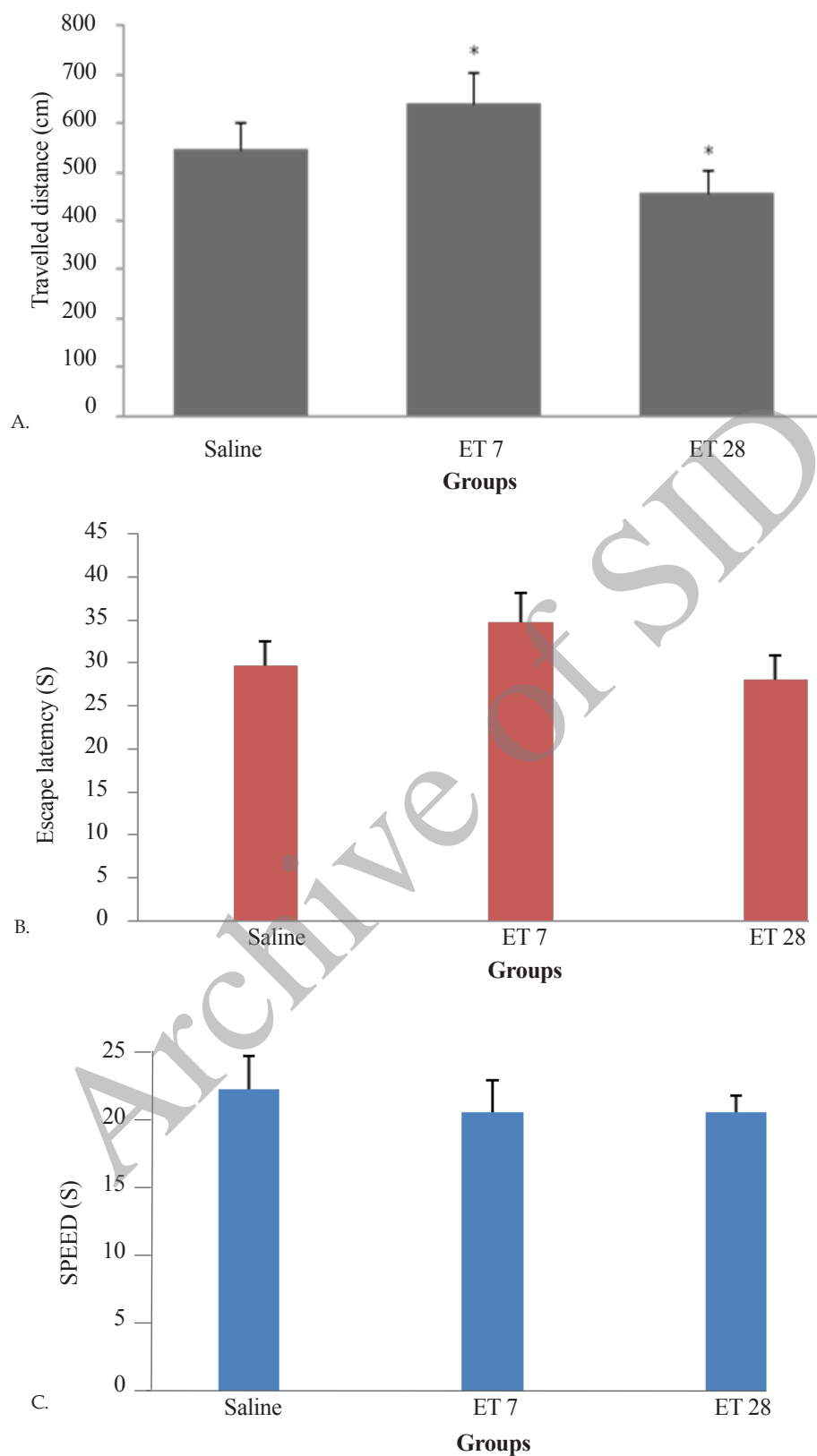


Figure 1. Effect of EB toxin on learning and spatial memory of Wistar rats 7 and 28 days after toxin injection. A: Effect of toxin on traveled distance by rats as an indicator of acquisition of spatial memory. B: Effect of toxin on escape latency for platform finding as an indicator of acquisition memory. C: Effect of toxin on swimming speed as an indicator of healthy locomotor behavior of rats. *: $P < 0.05$ is considered as significant difference between control and EB-induced lesioned groups.

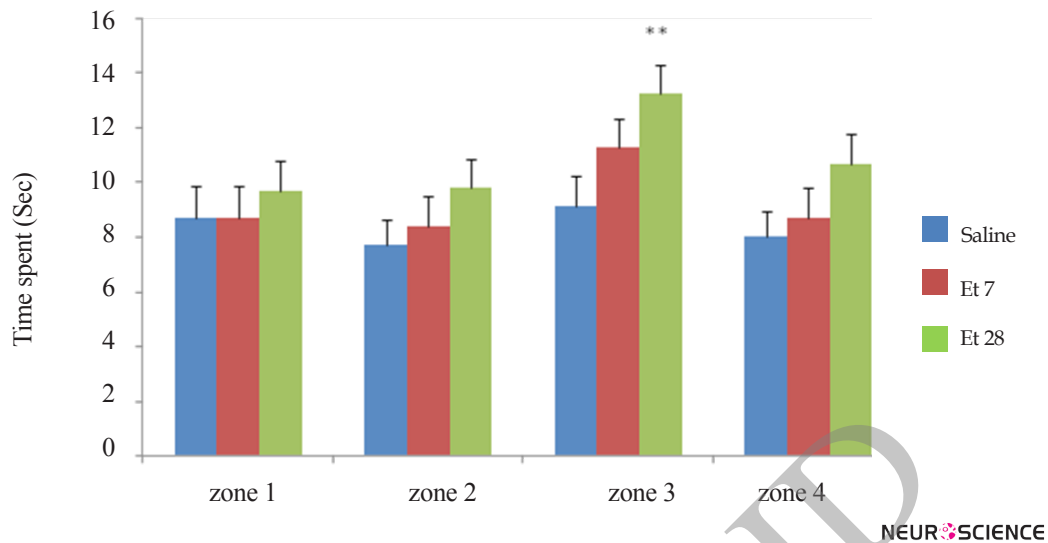


Figure 2. Time spent in 4 virtual quadrants during the 90 s training period. **: $P < 0.01$ is considered as significant difference between control and 28-day post EB-induced lesioned group in zone 3.

sue was dehydrated in ethanol and embedded in epon. Ultrathin sections were contrasted with uranyl acetate and lead citrate and viewed in transmission electron microscope. Thick sections were stained with 0.25% alkaline toluidine blue.

2.5. Statistical analysis

Data obtained over invisible platform tests were analyzed using 1-way analysis of variance (ANOVA) followed by the Tukey post hoc test. The results were expressed as mean \pm SEM, and $P < 0.05$ was considered as the minimum significant difference of means.

3. Results

3.1. Acquisition in the training period improved after EB injection over the time

Using the animal model of demyelination, the effect of EB injection on the total distance traveled to reach the platform, time taken for finding the platform (escape latency), time spent in target quadrant, and animal swimming speed were analyzed 7 and 28 days after induction of hippocampal injury.

Seven days after injury, the distance travelled increased significantly ($P < 0.05$) compared to the control group (Figure 1 A). There were no significant differences on escape latency, swimming speed (Figure 1 B, C) and time spent in target quadrant (Figure 2).

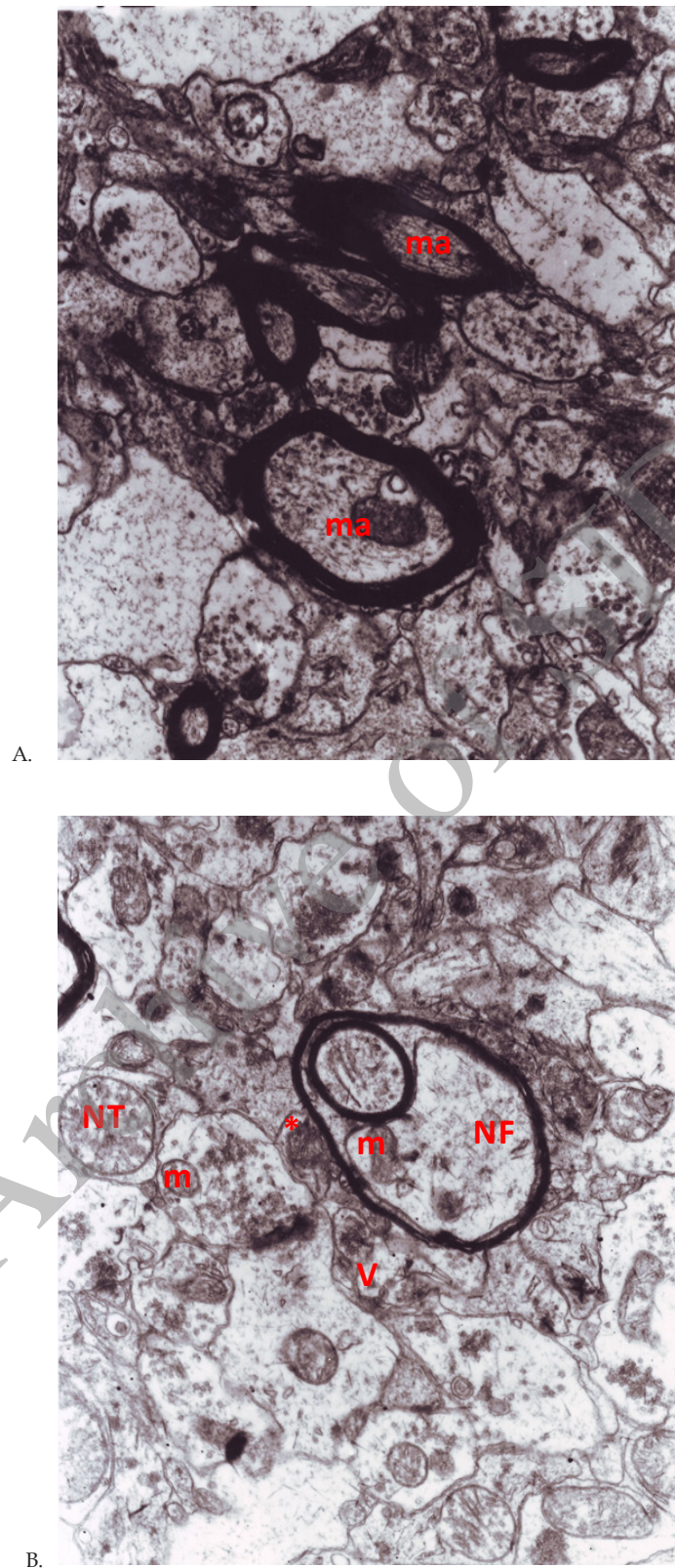
The effect of EB toxin-induced demyelination was also evaluated on traveled distance, escape latency for

platform finding, swimming speed, and time spent in target quadrant, 28 days after hippocampus damage. Toxin injection caused significant decrease in traveled distance for platform finding ($P < 0.05$) and also significant increase in time spent in target quadrant ($P < 0.01$) compared to the control group (Figure 1 A; Figure 2), but there were no significant differences in escape latency and swimming speed between the control group and experimental groups (Figure 1 B, C).

3.2. Transmission electron microscopic findings revealed substantial demyelination and oligodendrocyte remyelination over the time

Electron microscopic study of the control group demonstrated a spiral structure of myelin sheath of axons with major dense, interperiod lines, and internal mesaxon (Figure 3 A). Neurofilaments, microtubules, and mitochondria were observed in the cytoplasm of the axons. Also, tubulovesicular structures with branching, interconnected tubules and vesicles, which probably derived from endoplasmic reticulum, were seen. Distribution and presence of neurofilaments and neurotubules inside the myelinated axons were characteristics of normal axons (Figure 3 B).

In the experimental group which underwent analysis, 7 days after the injection, the myelin sheaths of some axons were unwrapped and disintegrated. Dense and interperiod lines were detached, however, a slightly thin layer of remyelination was observed. Hypertrophy of myelin forming cells with an increase in the interspace of oligodendrocyte nucleus and cytoplasm were observed (Figure 4 A).



NEURSCIENCE

Figure 3. Electron microscopy has been taken from dentate gyrus of hippocampus before ethidium bromide injection. A; Spiral structure of myelin sheath of axons (ma) have been surrounded by myelinated oligodendrocyte cell. B; Neurofilaments (NF), neurotubules (NT), tubulovesicle structure (asterisk), vesicle (V), and mitochondria (m) were observed in the cytoplasm of the axons. Magnification factor is x12000 in (A) and (B).

Oligodendrocyte cells were swollen, vacuolized with some dense bodies. Some abnormalities in certain elements were observed such as dramatic increase in the size and number of mitochondria in oligodendroglia and axons, as well as increase in neurofilaments with a defect in the orientation of bundles of filaments that produced a distorted configuration (Figure 4 B).

Oligodendrocytes also displayed some processes emanating from cell bodies. The compacted nucleus showed the typical clumped chromatin and heterochromatin nucleus that may be attributable to apoptosis (Figure 4 C).

In the other experimental group, which were analyzed 28 days after EB injection, thin layer of remyelination around the axons were observed (Figure 5 A, B). The cytoplasm of oligodendrocyte was composed of Golgi apparatus around the nucleus (Figure 5 B). The short cisternae of the granular endoplasmic reticulum, mitochondria and free ribosomes passed through and came out of the cell body (Figure 5 B). These findings might be due to glial reaction.

4. Discussion

Demyelination plaques within the hippocampus have been reported in clinical studies using MRI technique (Geurts et al., 2007; Rao et al., 1991; Sailer et al., 2003). The chemical toxin, EB, is commonly used to induce local demyelination (Guazzo, 2005). However, there are few animal studies analyzing the learning and memory deficits following EB-induced demyelination in the hippocampus. Instead, many basic and clinical studies were focused on the remyelination processes of the white matter of the CNS (Moon, Brecknell, Franklin, Dunnett, & Fawcett, 2000; Setzu, Ffrench-Constant, & Franklin, 2004; Woodruff & Franklin, 1999). In fact, the neuro-degeneration and -regeneration mechanisms following demyelination in the hippocampus, which contains both white and gray matters of CNS are not being well-understood yet. Therefore, the aim of present study was to evaluate intrahippocampal injection of ethidium bromide as a simple model to assess cognition and gray matter demyelination. In this regard, the micrographs of TEM study in the control group showed oligodendrocyte-myelinated axons with several mitochondria and neurofilaments.

In the experimental group, 7 days after EB injection, the MWM task was carried out. The EB treated rats performed significantly worse than the control group with respect to traveled distance (one of the acquisition memory parameters), but their escape latency, time spent

in target quadrant, and swimming speed did not change significantly. These findings indicated that the memory may be impaired by EB toxin injection, but the locomotor behavior remained healthy.

Ultrastructural study of the micrographs from the dentate gyrus of hippocampus showed prominent unwrapped and disintegrated myelin sheaths consisting of barely axons and compressed cytoplasm and nucleus. This evidence strongly pointed to the apoptosis-inducing effect of EB. These findings are in agreement with our study as well as others (Frohman, Racke, & Raine, 2006; Goudarzvand, 2010; Stangel & Hartung, 2002). Bondan et al. showed that EB-induced demyelinated axons of the brainstem after 7 days, accompanied with cellular changes of macrophages (Bondan et al., 2006). EB-induced demyelination of the Caudal Cerebellar Peduncle (CCP) has also been reported due to oligodendrocyte damage using toluidine staining and TEM assessment (Woodruff & Franklin, 1999). Our TEM findings, 7 days post lesion, showed swollen vacuoles with some dense bodies within the oligodendrocytes.

Some abnormalities, including the neurofilament orientation, dramatic increase in the size and number of the mitochondria in oligodendrocyte were also observed. The structural abnormalities after EB-induced lesion of the striatum were previously reported by Moon and his colleagues. They claimed decreased astrocyte and oligodendrocyte cells. Debris-filled macrophages and small processes of the reactive astrocyte containing intermediated filaments were also reported (Moon et al., 2000). In our study, the compacted nucleus showed the typical clumped chromatin that was probably due to apoptosis or glial reaction. Several studies have demonstrated the astrogliosis in Experimental Autoimmune Encephalomyelitis (EAE) model of MS (Di Bello, Dawson, Levine, & Reynolds, 1999), microgliosis, oligodendrocyte death, and extensive demyelinating effect of EB injection into the different regions of the CNS (Bondan et al., 2006; Levine & Reynolds, 1999; Woodruff & Franklin, 1999). Therefore, memory impairment may be associated with EB-induced cellular changes.

Interestingly, we found evidence of thin remyelination 7 days after EB injection. These findings may indicate the onset of the hippocampus repair process after injury, which is in consistent with the study of Franklin et al., reporting slight oligodendrocyte-remyelination in the CCP (Woodruff & Franklin, 1999).

Micrographs of 28-day post lesion revealed the substantial thinner remyelinated axons in the lesion site

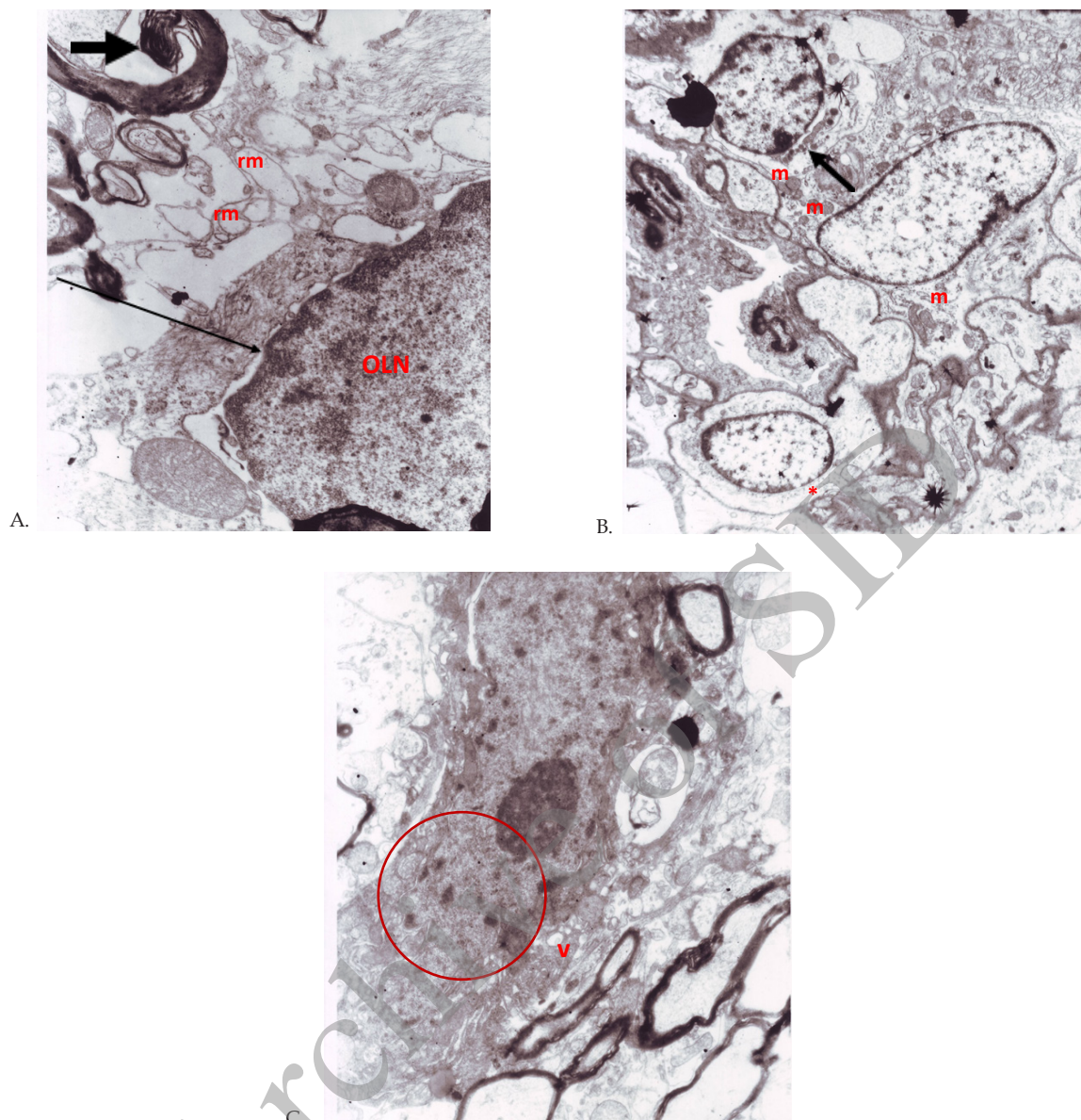
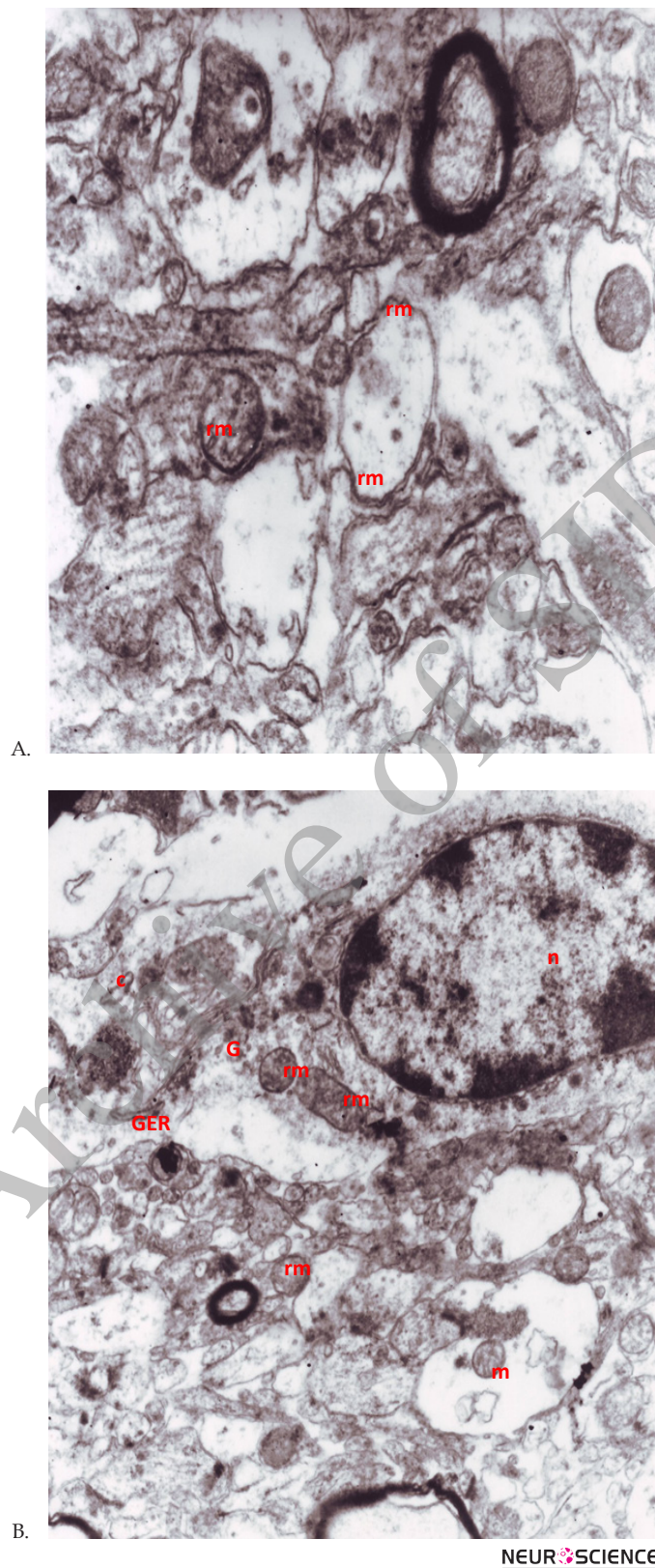


Figure 4. Micrographs of the dentate gyrus of hippocampus, 7 days after EB-induced lesions. A; The myelin sheaths of some axons were unwrapped and disintegrated (thick arrowhead), however, slightly thin remyelinated axons (rm) were observed. Hypertrophy of myelin forming cells with an increase in the inter space of oligodendrocyte nucleus (OLN) and cytoplasm is shown (thin arrowhead). B; Oligodendrocyte cells were swollen, and vacuolized with some dense bodies (arrowhead), a dramatic increase in the size and number of mitochondria (m) in oligodendroglia and axons, and also a defect in the orientation of neurofilaments (asterisk). C; The compacted nucleus of oligodendrocyte showed the typical clumped chromatin (red circle) and heterochromatin that was probably due to or glial reaction, and also oligodendrocyte cells were vacuolized (v). Magnification factors are $\times 12000$ in (A), $\times 3000$ in (B), and $\times 7000$ in (C).

compared to the myelinated ones located close to the lesion region. This chronological remyelination (Bondan et al., 2006; Di Bello et al., 1999; Woodruff & Franklin, 1999; Goudarzvand et al., 2010) has been previously reported by several studies in different animal models of multiple sclerosis at 2 to 6 weeks post lesion. In the experimental group of our study, the dark cytoplasm of oligodendrocyte composed of Golgi apparatus around

the nucleus, as well as the short cisternae of the granular endoplasmic reticulum, mitochondria, and free ribosomes were observed. These findings might be attributed to glial reaction.

In the behavioral study evaluated 28 days post lesion, the traveled distance to find the hidden platform by rats decreased compared to the control group to a significant



NEUR SCIENCE

Figure 5. Ultrastructural features of the dentate gyrus on EM examination 28 days after EB injection. A; The EB-induced lesion contained a thin layer of remyelination (rm) around the axons. B; The cytoplasm of oligodendrocyte with thin remyelination (rm) was composed of Golgi apparatus (G) around the nucleus (n; in upper right), the short cisternae (C) of the granular endoplasmic reticulum (GER), mitochondria and free ribosomes. These findings might be due to glial reaction. Magnification factors are $\times 20000$ (A) and $\times 7000$ in (B).

extent and also time spent in target quadrant (zone 3) increased in comparison to the control group, without any remarkable change in the escape latency and swimming speed. The decline of traveled distance and the increase of time spent in target zone, as indicators of the memory improvement, are probably due to the physiological repair capacity of CNS and thin and limited remyelination, even without any exogenous intervention. Our findings from TEM assay are in line with the behavioral analysis results.

Basically, EB-damage causes oligodendrocyte cell death nearly 72 hours after the lesion (Guazzo, 2005), and then the remyelination process starts by recruiting oligodendrocyte cells (Itoyama et al., 1983; Ogata & Feigin, 1975). In this study, we observed the remyelination of oligodendrocyte cells, and not Schwann cells, which was most probably because of the procedure limitations to take the micrographs. In addition, there were a few technical problems in washing process that led to the deposition of the lead citrate particles as artifacts in some slides.

In conclusion, this project represents the data supporting physiological repair capacity of the dentate gyrus of hippocampus, and improvement of memory function, subsequent to intracellular changes of the hippocampus following EB injection, in a chronological manner. Therefore, direct focal injection of EB into the hippocampus may be considered as a simple and suitable model to study cognition and also degeneration and regeneration processes of the grey matter.

Acknowledgments

We thank the Research Council of Alborz University of Medical Sciences for the funding of this project. We are also grateful to Physiology and Pharmacology Department of Pasteur Institute and Tarbiat Modares University, Iran for providing facilities of the current study.

Conflict of Interest

The authors declare that there are no conflicts of interest.

Abbreviations

MS: Multiple sclerosis; EB: Ethidium Bromide; CNS: Central Nervous System; MRI: Magnetic Resonance Imaging; IP: Intraperitoneal; MWM: Morris Water Maze; NW: Northwest; NE: Northeast; SW: Southwest; SE: Southeast; TEM: Transmission Electronic Microscopy; SER: Smooth Endoplasm Reticulum, CCP: Caudal Cerebellar Peduncle

References

- Bagert, B., Camplair, P., & Bourdette, D. (2002). Cognitive dysfunction in multiple sclerosis. *CNS Drugs*, 16(7), 445-455.
- Baulieu, E. E., & Robel, P. (1990). Neurosteroids: a new brain function? *The Journal of Steroid Biochemistry and Molecular Biology*, 37(3), 395-403.
- Becq, H., Jorquera, I., Ben-Ari, Y., Weiss, S., & Represa, A. (2005). Differential properties of dentate gyrus and CA1 neural precursors. *Journal of Neurobiology*, 62(2), 243-261.
- Blakemore, W. (1982). Ethidium bromide induced demyelination in the spinal cord of the cat. *Neuropathology and Applied Neurobiology*, 8(5), 365-375.
- Bondan, E., Lallo, M., Sinhorini, I., Pereira, L., & Graça, D. (2000). The effect of cyclophosphamide on brainstem remyelination following local ethidium bromide injection in Wistar rats. *Journal of Submicroscopic Cytology and Pathology*, 32(4), 603.
- Bondan, E., Lallo, M., Trigueiro, A., Ribeiro, C., Sinhorini, I., & Graça, D. (2006). Delayed Schwann cell and oligodendrocyte remyelination after ethidium bromide injection in the brainstem of Wistar rats submitted to streptozotocin diabetogenic treatment. *Brazilian Journal of Medical and Biological Research*, 39(5), 637-646.
- Di Bello, I. C., Dawson, M., Levine, J., & Reynolds, R. (1999). Generation of oligodendroglial progenitors in acute inflammatory demyelinating lesions of the rat brain stem is associated with demyelination rather than inflammation. *Journal of Neurocytology*, 28(4-5), 365-381.
- Frohman, E. M., Racke, M. K., & Raine, C. S. (2006). Multiple sclerosis—the plaque and its pathogenesis. *New England Journal of Medicine*, 354(9), 942-955.
- Geurts, J. J., Bö, L., Roosendaal, S. D., Hazes, T., Daniëls, R., Barkhof, F., et al. (2007). Extensive hippocampal demyelination in multiple sclerosis. *Journal of Neuropathology & Experimental Neurology*, 66(9), 819-827.
- Goudarzvand, M., Javan, M., Mirnajafi-Zadeh, J., Mozafari, S., & Tiraihi, T. (2010). Vitamins E and D3 attenuate demyelination and potentiate remyelination processes of hippocampal formation of rats following local injection of ethidium bromide. *Cellular and Molecular Neurobiology*, 30(2), 289-299.
- Gould, E., Beylin, A., Tanapat, P., Reeves, A., & Shors, T. J. (1999). Learning enhances adult neurogenesis in the hippocampal formation. *Nature Neuroscience*, 2(3), 260-265.
- Guazzo, E. P. (2005). A technique for producing demyelination of the rat optic nerves. *Journal of Clinical Neuroscience*, 12(1), 54-58.
- Itoyama, Y., Webster, H. D., Richardson, E. P., & Trapp, B. D. (1983). Schwann cell remyelination of demyelinated axons in spinal cord multiple sclerosis lesions. *Annals of Neurology*, 14(3), 339-346.
- Kempermann, G., Kuhn, H. G., & Gage, F. H. (1997). More hippocampal neurons in adult mice living in an enriched environment. *Nature*, 386(6624), 493-495.
- Levine, J. M., & Reynolds, R. (1999). Activation and proliferation of endogenous oligodendrocyte precursor cells during ethidium bromide-induced demyelination. *Experimental Neurology*, 160(2), 333-347.

- McNamara, R. K., & Skelton, R. W. (1993). The neuropharmacological and neurochemical basis of place learning in the Morris water maze. *Brain Research Reviews*, 18(1), 33-49.
- Moon, L. D., Brecknell, J. E., Franklin, R. J., Dunnett, S. B., & Fawcett, J. W. (2000). Robust regeneration of CNS axons through a track depleted of CNS glia. *Experimental Neurology*, 161(1), 49-66.
- Nagaraj, K., Taly, A. B., Gupta, A., Prasad, C., Christopher, R. (2013). Depression and sleep disturbances in patients with multiple sclerosis and correlation with associated fatigue. *Journal of Neurosciences in Rural Practice*, 4(4), 387-391.
- Nakatomi, H., Kuriu, T., Okabe, S., Yamamoto, S. I., Hatano, O., Kawahara, N., et al. (2002). Regeneration of hippocampal pyramidal neurons after ischemic brain injury by recruitment of endogenous neural progenitors. *Cell*, 110(4), 429-441.
- Ogata, J., & Feigin, I. (1975). Schwann cells and regenerated peripheral myelin in multiple sclerosis. An ultrastructural study. *Neurology*, 25(8), 713-713.
- Paxinos, G., & Watson, C. (2006). *The rat brain in stereotaxic coordinates: hard cover edition*: Academic press.
- Rao, S. M., Leo, G. J., Bernardin, L., & Unverzagt, F. (1991). Cognitive dysfunction in multiple sclerosis. I. Frequency, patterns, and prediction. *Neurology*, 41(5), 685-691.
- Sailer, M., Fischl, B., Salat, D., Tempelmann, C., Schönfeld, M. A., Busa, E., et al. (2003). Focal thinning of the cerebral cortex in multiple sclerosis. *Brain*, 126(8), 1734-1744.
- Setzu, A., Ffrench-Constant, C., & Franklin, R. J. (2004). CNS axons retain their competence for myelination throughout life. *Glia*, 45(3), 307-311.
- Sim, F., Hinks, G., & Franklin, R. (2000). The re-expression of the homeodomain transcription factor Gtx during remyelination of experimentally induced demyelinating lesions in young and old rat brain. *Neuroscience*, 100(1), 131-139.
- Smith, K., Blakemore, W., & McDonald, W. (1979). Central remyelination restores secure conduction. *Nature*, 280(5721), 395-396.
- Soodi, M., Naghdi, N., Sharifzadeh, M., Ostad, N., & Abdollahi, M. (2010). Effect of Lead (Pb²⁺) Exposure in Female Pregnant Rats and Their Offspring on Spatial Learning and Memory in Morris Water Maze. *Iranian Journal of Pharmaceutical Research*, 7(1), 43-51.
- Stangel, M., & Hartung, H.-P. (2002). Remyelinating strategies for the treatment of multiple sclerosis. *Progress in Neurobiology*, 68(5), 361.
- Woodruff, R. H., & Franklin, R. J. (1999). Demyelination and remyelination of the caudal cerebellar peduncle of adult rats following stereotaxic injections of lyssolecithin, ethidium bromide, and complement/anti-galactocerebroside: A comparative study. *Glia*, 25(3), 216-228.

Archive of SID