

Case Report: Iatrogenic Seeding of Tumor Cells in Thigh Soft Tissue Upon Surgical Removal of Intracranial Meningioma



Ghodratollah Maddah¹, Hossein Shabahang¹, Vahid Zehi^{1*}, Nouriyeh Sharifi Sistani², Hossein Mashhadi Nejad³

1. Endoscopic and Minimally Invasive Surgery Research Center, Mashhad University of Medical Sciences, Mashhad, Iran.

2. Department of Pathology, Ghaem Hospital, Faculty of Medicine, Mashhad University of Medical Sciences, Mashhad, Iran.

3. Department of Neurosurgery, Ghaem Hospital, Faculty of Medicine, Mashhad University of Medical Sciences, Mashhad, Iran.

Citation: Maddah, Gh., Shabahang, H., Zehi, V., Sharifi Sistani, N., & Mashhadi Nejad, H. (2016). Iatrogenic seeding of tumor cells in thigh soft tissue upon surgical removal of intracranial meningioma. *Basic and Clinical Neuroscience*, 7(2), 159-164. <http://dx.doi.org/10.15412/J.BCN.03070209>

doi <http://dx.doi.org/10.15412/J.BCN.03070209>

Article info:

Received: 23 March 2015

First Revision: 01 May 2015

Accepted: 30 July 2015

Key Words:

Meningioma, Seeding, Implantation

ABSTRACT

Introduction: Meningioma is a benign and slowly-growing tumor that is responsible for 20% of brain neoplasms. It can be accompanied by some genetic disorders such as neurofibromatosis type 2 and is more common among women. As a space occupying lesion, it produces a wide range of signs and symptoms by compressing the adjacent and underlying tissues in the brain. Trauma and viruses are possible etiologies for meningioma. The ideal treatment of benign meningioma is surgical resection.

Case Presentation: In this case report, we present a middle-aged man with a seeding metastasis of the cranial meningioma (after its removal) in the left thigh. During the removal operation, fascia lata had been used to repair the dura mater and the skin defect was repaired primarily.

Conclusion: We believe that the occurrence of meningioma at the site of incision in the thigh is related to using the same surgical instruments for the removal of the brain tumor.

1. Introduction

Meningioma is generally a benign localized and slowly-growing tumor that may occur intracranially or within the spinal cord. Meningioma accounts for approximately 20% of all primary intracranial neoplasms.

Meningioma is multiple in 5%-40% of cases, particularly when it is associated with neurofibromatosis type 2 (NF-2).

Some meningioma tumors are discovered fortuitously during CT or MRI tests to assess unrelated diseases or conditions. Meningioma afflicts women more often than men (1:1.4 to 1:2.8).

Meningioma produces its symptoms by several mechanisms, such as irritating the underlying cortex, compressing the brain or the cranial nerves, producing hyperostosis, invading the overlying tissue, or inducing vascular injuries to the brain. Signs and symptoms become exacerbated during pregnancy while improved in the postpartum period.

* Corresponding Author:

Vahid Zehi, MD

Address: Endoscopic and Minimally Invasive Surgery Research Center, Mashhad University of Medical Sciences, Mashhad, Iran.

Tel: +98 (51) 38012806

E-mail: emis@mums.ac.ir

Trauma and viruses have been investigated as the possible contributors to the development of meningioma. However, no definitive proof has been found yet. Genetic causes have been also implicated in the development of meningioma.

Medical care for meningioma has been disappointing. Meanwhile, the use of corticosteroids has significantly decreased the mortality and morbidity rates associated with surgical resection. Furthermore, the current experience with chemotherapy is disappointing.

Clinical benefit has been reported in many case series with either tumor regression or stasis after radiotherapy. Radiotherapy is mainly used as adjuvant therapy for incompletely resected, high grade, or recurrent tumors. In general, the ideal treatment of a benign meningioma is surgical resection if possible.

In our report, a 34-year-old man has been presented with an unusual seeding metastasis of the cranial meningioma in his left thigh, 6 years after the removal of the tumor. The patient underwent repeated operations with a wide skin resection, including the masses followed by reconstruction of the surgical site using split thickness graft.

No report of recurrence has been reported yet. We strongly believe that the main cause of tumor recurrence is the use of the same surgical instruments already used for the tumor site. This should have been prevented by substituting all surgical instruments with new ones.

2. Case Presentation

On July 13, 2007, a 34-year-old man was admitted to the Department of Surgery of Ghaem Hospital, Mashhad University of Medical Sciences, for recurrence of tumor in the lateral part of the left thigh over the previous incision of fascia lata graft to reconstruct the dura mater following removal of the brain tumor.

In April 2001, 6 years before the patient's current admission, brain CT scanning had been performed on the patient who complained from long-lasting headache during recent years. CT scan results revealed a space occupying lesion in the left parietal zone suggesting a brain tumor (Figure 1).

In the Neurosurgery Department, the patient underwent a craniotomy. To reconstruct the dura mater following tumor removal (by a longitudinal incision), a fascia lata graft from lateral side of the left thigh was performed. The pathological report of the brain tumor was compatible with meningioma. After the operation, the patient was treated with phenytoin, carbamazepine, and phenobarbital.

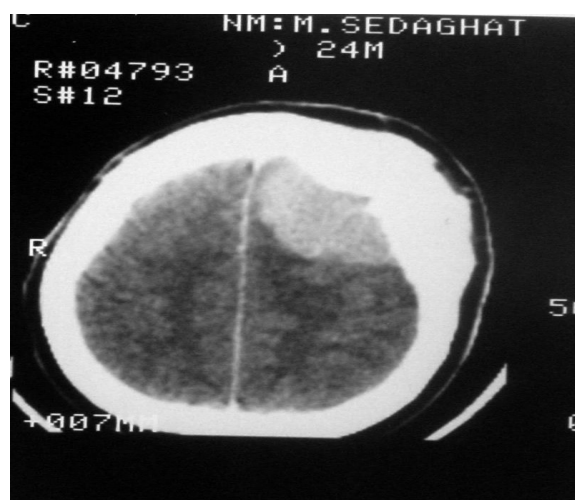
Over 4 years following craniotomy, the patient had no signs and symptoms. In April 2005, the patient referred to the hospital with two solid masses in the lateral part of the left thigh over the previous incision of fascia lata graft that gradually became bigger up to 2×2 cm.

An excisional biopsy from the solid masses was done and the pathological report indicated meningioma. Therefore, the patient underwent the resection of skin masses by an elliptical incision around the scar of the previous one. He was discharged 4 days later.

Two years later, in July 2007, three adjacent masses ranging 1-2 cm in diameter, reappeared over the previous incision with no signs of erythema or tenderness and the patient was referred to our surgery department.

At this time, a wide and elliptical skin resection, including the masses with 3 cm free margin and removal of left quadriceps muscle beneath the fascia was performed for the patient. All surgical instruments used in the operation were substituted with new ones before performing split grafting from the other thigh. No frozen section or 5-ALA test was done. Reconstruction was performed using a split thickness graft from the other thigh (Figures 2 and 3).

Based on histopathological evaluation and our pathologist report, the surgical specimen showed proliferation of round to oval meningothelial type cells with inconspicuous cytoplasmic borders and scanty chromatin consistent with intramuscular seeding of meningioma cells (Figures 4a and 4b). Since the last surgery (or 84 months), no sign of recurrence in thigh and cranial meningioma has been reported.



NEURSCIENCE

Figure 1. CT scanning image showing a space occupying lesion in the parietal zone of the left hemisphere (April 2001).

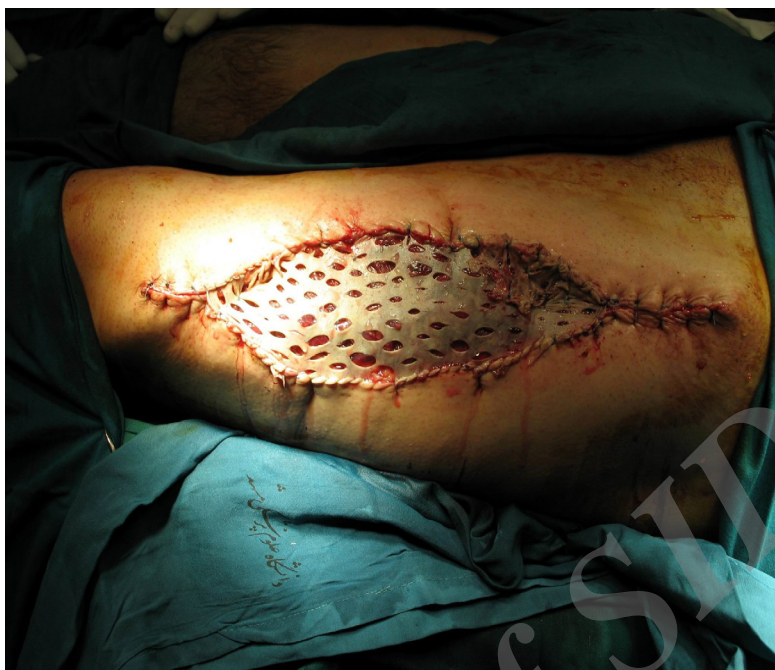

Figure 2. Reconstruction by performing a split thickness graft from the other thigh (July 2007).

NEURSCIENCE

3. Discussion

Meningioma is usually a benign and slowly-growing brain tumor, originating from dura mater and accounts for 14% to 19% of all primary intracranial neoplasms, and is considered as the second most common brain tumor (Akai et al., 2004; Ozer, Kalemci, Acar, & Canda, 2007).

In WHO classification, meningioma falls into 3 categories according to their estimated risk of recurrence or aggressive growth (Palmer, Cook, & Ellison, 1994). The incidence of metastasis occurrence among malignant meningioma is 0.1%.

The metastasis rate in papillary meningioma has been reported to be 20%. Different kinds of metastatic formation have been documented for malignant meningioma. Those

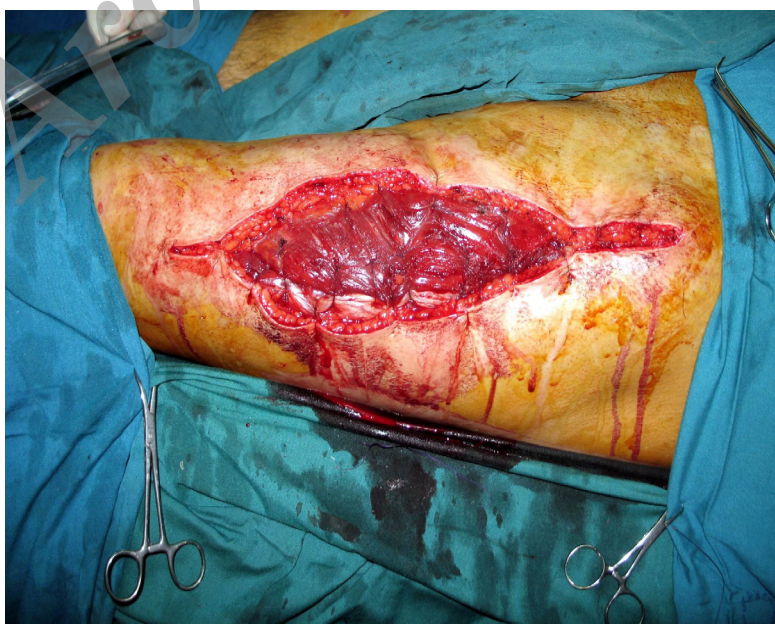
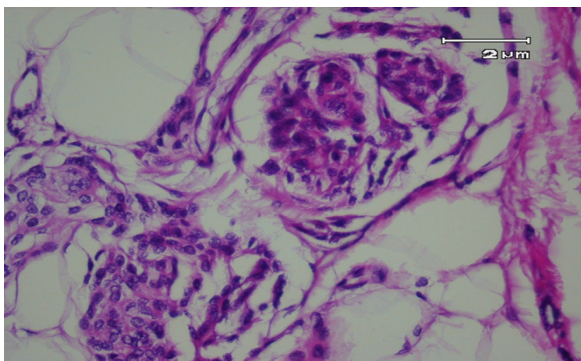


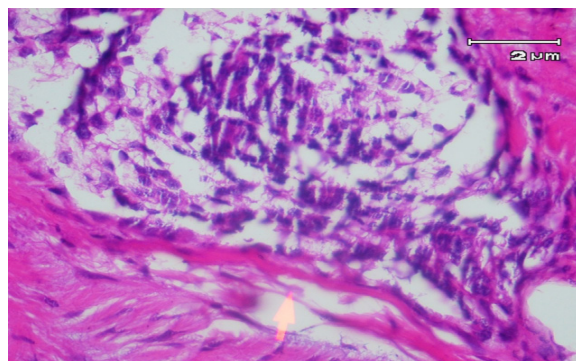
Figure 3. This figure shows post resection defect of the left thigh (July 2007).

NEURSCIENCE

4a



4b



NEURSCIENCE

Figure 4a _Figure 4b. Microscopic views show fibrofatty and muscle tissue with nests of meningioma by round to oval benign nuclei and syncytial acidophil cytoplasm with whorle pattern (H & E staining 400 #) (August 2007).

include spreading through blood, lymph, CSF, and surgical treatment (Lee & Landy, 1998; Mahore, Chagla, & Goel, 2010)

Iatrogenic seeding of neoplasms may occur during various types of surgical interventions. Surgical seeding of various types of CNS tumors has been reported.

Histologically-benign meningioma tumors are also reported to have metastasized extracranially through hematogenous route. Furthermore, local recurrences rates after complete resection vary from 10% to 30% (Ludemann, Obler, Tatagiba, & Samii, 2002). The histological grade of the tumor is the most important property to predict metastases and recurrences (Tahir, Shamim, & Chishti, 2009). Malignant meningioma tumors have the potential for spreading to distant locations.

Distant metastases from benign meningioma are extremely rare and almost all of the reported cases were associated with a large intracranial tumor (Akai et al., 2004; Lee & Landy, 1998).

As stated earlier, meningioma may disseminate through hematogenous, lymphatic, or cerebrospinal fluid routes. It has been reported that surgical resection carries a risk of metastasis formation through the mobilization of tumor cells from the primary lesion and their dissemination during the operation (Abboud, Haddad, Kattar, Aburiziq, & Geara, 2009; Akai et al., 2004; Lowden & Taylor, 1974; Tahir et al., 2009) however, as far as we know, seeding of the tumor in the area of fascia lata removal, has not been reported.

In our case, we believe that surgical instruments used for resection of the brain tumor were responsible for seeding of the tumor in left thigh. The diagnosis of meningioma is greatly facilitated by their ready visualization with contrast-

enhanced CT and MRI, which reveal their tendency to calcify and prominent vascularity. Electroencephalography may also serve as a helpful tool both in diagnosis of meningioma and postoperative follow-up period (Abboud et al., 2009; Erkutlu et al., 2009; Lowden & Taylor, 1974; Mahore et al., 2010). In our case, the tumor was first recognized by CT scan (Figure 1).

Surgical excision is the mainstay treatment and must be preceded by radiographic determination of the extent of the primary lesion and possible metastatic deposit (Erkutlu et al., 2009). Recurrence is likely if removal is incomplete (Ichikawa et al., 2010). Several reports of metastatic meningioma have indicated the recurrence of disease after surgical removal of the tumor (Mahore et al., 2010; Velnar & Bunc, 2008).

4. Conclusion

Based on the present case, we concluded that a key reason for implantation of the tumor on the other areas, is using the same surgical instruments which were already used in the tumor site. We believe this as a case of tumor metastasis since the site of involvement was precisely overlying the graft incision and other areas were intact.

We highly suggest that surgical instruments, surgical gowns, surgical gloves, and whatever used in the tumor site be substituted with the new ones when another operation is required. This strategy will reduce the probability of tumor implantation on the other sites.

It has been proved that in operation rooms where several operations are performed in one session, especially if changing gowns and surgical gloves are not taken into considerations; the tumor seeding is likely to happen.

Acknowledgement

His work was supported by the vice chancellery Of research of Mashhad University of Medical Sciences, Mashhad, Iran, and performed in the Endoscopic and Minimally Invasive Surgery Research Center of Mashhad University of Medical Sciences, Mashhad, Iran. We would like to thank Mrs Sima beigoli for her kind assistance in preparation of this manuscript.

Conflict of Interest

The authors declared no conflict of interest.

References

- Aboud, M., Haddad, G., Kattar, M., Aburiziq, I., & Geara, F. B. (2009). Extraneural metastases from cranial meningioma: A case report. *Radiation Oncology*, 4, 20.
- Akai, T., Shiraga, S., Iizuka, H., Kishibe, M., Kawakami, S., & Ueda, Y. (2004). Recurrent meningioma with metastasis to the skin incision-case report. *Neurologia Medico-chirurgica (Tokyo)*, 44(11), 600-602.
- Erkutlu, I., Buyukhatipoglu, H., Alptekin, M., Berkyurek, E., Tutar, E., & Gok, A. (2009). Spinal drop metastases from a papillary meningioma: A case report and review of the literature: Utility of CSF sampling. *Medical Oncology*, 26(2), 242-246.
- Ichikawa, M., Saito, K., Ito, E., Kawai, K., Fujimoto, Y., & Kamei, Y. (2010). Iatrogenic drop metastasis of recurrent meningioma in a vascularized free omental flap-case report. *Neurologia Medico-chirurgica (Tokyo)*, 50(1), 70-73.
- Lee, T. T., & Landy, H. J. (1998). Spinal metastases of malignant intracranial meningioma. *Surgical Neurology*, 50(5), 437-441.
- Lowden, R. G., & Taylor, H. B. (1974). Angioblastic meningioma with metastasis to the breast. *Archives of Pathology*, 98(6), 373-375.
- Ludemann, W. O., Obler, R., Tatagiba, M., & Samii, M. (2002). Seeding of malignant meningioma along a surgical trajectory on the scalp. Case report and review of the literature. *Journal of Neurosurgery*, 97(3), 683-686.
- Mahore, A., Chagla, A., & Goel, A. (2010). Seeding metastases of a benign intraventricular meningioma along the surgical track. *Journal of Clinical Neuroscience*, 17(2), 253-255.
- Ozer, E., Kalemci, O., Acar, U. D., & Canda, S. (2007). Pin site metastasis of meningioma. *British Journal of Neurosurgery*, 21(5), 524-527.
- Palmer, J. D., Cook, P. L., & Ellison, D. W. (1994). Extracranial osseous metastases from intracranial meningioma. *British Journal of Neurosurgery*, 8(2), 215-218.
- Tahir, M. Z., Shamim, M. S., & Chishti, K. N. (2009). Recurrent atypical meningioma seeding to surgical scar. *Neurology India*, 57(2), 222-224.
- Velnar, T., & Bunc, G. (2008). Iatrogenic metastasis of a benign meningioma to the periosteum at the site of previous craniotomy: a case report. *Wiener Klinische Wochenschrift*, 120(23-24), 766-769.