




International Journal of Molecular and Clinical Microbiology



Identification of cutaneous granuloma caused by *Mycobacterium marinum* using PCR method

Kasra Behrouznasab^{1*}(Ph.D), Mohammad Reza Razavi² (Ph.D), Fatollah Fathalian¹ (Ph.D), Hassan Seirafi³ (Ph.D), Taher Nejdassattari⁴ (Ph.D), Nima Mohammadi⁵(Ph.D)

1. Department of microbiology, Science and Research Branch, Islamic Azad University, Tehran, Iran.

2. Department of parasitology, Pasteur Institute, Tehran, Iran.

3. Department of Dermatology, Tehran Medical Sciences University, Tehran, Iran.

4. Department of Biology, Faculty of Basic Sciences, Science and Research Branch, Islamic Azad University, Tehran, Iran.

5. Young Researchers and Elites club, Science and Research Branch, Islamic Azad University, Tehran, Iran

ARTICLE INFO

Article history:

Received 21 February 2013

Accepted 7 April 2013

Available online 1 June 2013

Keywords:

Mycobacterium marinum,
Granuloma, PCR, HSP-65

ABSTRACT

Atypical *Mycobacterium* granulomatous skin infections are often caused by *Mycobacterium marinum*, *M. ulcerans*, *M. fortuitum*, and *M. avium* colonies. Skin infections probably originate from an environmental source such as contacting with aquatic animals, fish farming and swimming in the pools, and inoculate into skin through skin wounds, scratches, trauma, and surgery. The lesions appear as purple papules, nodules in hands and feet, plaque blisters wart ulcers and markers transmission (sporotrichosis) in the path of lymph nodes. They have granulomatous accumulation with giant cells, and abscess pus appears, and sometimes in the form of ulcerative. Infection is limited to the skin, while in immunosuppressed cases it would be able to infect the whole body. To determine if *Mycobacteria* were present in granulomatous skin lesion, a total of 58 paraffine embedded tissue blocks were obtained and their DNA was extracted. The polymerase chain reaction (PCR) was used to amplify the HSP-65 gene. PCR amplification demonstrated the presence of *Mycobacterium* spp. In 18 blocks (31%). Among these 18 blocks, 8 (44%) were positive for *M. marinum*, 3 (17%) for *M. ulcerans*, 5 (27%) for *M. fortuitum* and *M. chelonae*, and 2 (12%) for *M. avium*. We conclude that *Mycobacteria* ought to be considered in the treatment of skin granulomas in Iran.

1. Introduction

Atypical *Mycobacterium* infections typically include pulmonary infections, lymphadenitis, granulomatous skin and transmitted infections (in people with immune system defects) (Wagner and Young, 2004). Skin infections are often caused by *M. marinum*, *M. ulcerans*, *M. fortuitum*, *M. chelonae* are atypical in from of swimming pool granuloma (Palenque, 2000). Skin

infections are probably caused by a common environmental source such as being exposed to aquatic animals, fish farming ponds, and swimming pools, or through injections by causing surface wound, skin scratch, or trauma (Mahaisavariya et al., 2003). Granulomatous cutaneous lesions often appear on the elbows, fingers, and hands as papules, nodules, blisters, plaques, wart ulcers, sporotrichoid transmission lesions and sometimes ulcerative.

*Corresponding author. Kasra Behrouznasab
E-mail address: Kbehrouznasab@gmail.com

The infection is limited to the skin and in case of immunosuppression would change to lymphatic spread infection. Transmission from person to person is rare (Tan and Chan, 1999). PCR is a specific, sensitive and accurate method for diagnosis of bacterial infections. This method can recognize a few atypical *Mycobacterium* genomes in paraffin-embedded tissue samples and its differentiation from granulomatous cutaneous lesions similar to parasitic and fungal infection. (Cook *et al.*, 1994; Ghossein *et al.*, 1992). With this diagnostic method, cutaneous lesion caused by atypical *Mycobacterium* can be diagnosed from other granulomatous infections such as leishmaniasis and Sporotrichosis. The detection will help in choosing the appropriate treatment of such cutaneous disease by either antibiotics or, if necessary, using surgery. (Sanchez *et al.*, 2000; Wolinsky *et al.*, 1972; Frevel *et al.*, 1999).

2. Material and Methods

In this study atypical *Mycobacterium granulomatous* skin infections diagnosed by PCR, using specific primers designed for *Mycobacterium* genes (hsp65). Fifty eight (58) formalin-fixed, paraffin-embedded tissue samples of granulomatous lesion from the period of time effective from 2006 until 2010 were obtained from the Pathology archives of Razi Hospital, Iran, Tehran. All paraffine-embedded skin tissues had clinical signs of granuloma. *Mycobacterium smegmatis* (PTCC 1307) was used as a positive control. In Lewenstein-Jensen (LJ) agar medium. They were checked for *Mycobacterium* colony appearing on the agar media after 14 days. *M. smegmatis* is a positive control for diagnosis of *M. marinum* and *Mycobacterium* except Tuberculosis (NTM).

2.1. PCR method

DNA was extracted from paraffine-embedded tissue by the method explained by Goldmann *et al.*, (1998). In this study, a pair of primers (forward and reverse) were used to amplify a 292bp fragment of HSP-65 gene belonging to the *Mycobacterium* genus. Another pair of primers were also used to amplify a 154bp fragment of HSP-65 gene specific to

M. marinum. The primers used are given in table 1.

DNA amplifications were carried out in a total volume of 25 μ L containing 17.5 μ L DNA, 0.1 μ L of each primers, 0.5 μ L dNTP mix (10mM) (Cinnagen Inc., Tehran, Iran), 4 μ L MgCl₂ (25 mM), 2.5 μ L PCR buffer (10x) (Cinnagen Inc., Tehran, Iran), and 0.25 μ L Taq DNA polymerase (5 u/ μ L) (Cinnagen Inc., Tehran, Iran). Reaction mixture were thermocycled 30 times beginning with an initial denaturation step of 20 min at 94°C. The temperature and time profile of each cycle was as following: 60°C for 1 min (Annealing) and 72°C for 1 min (extension). Reactions were finished with a final extension step at 72°C for 5 min (Folgeira *et al.*, 1993). 1 μ L of PCR products were mixed with 2 μ L of loading buffer (6x) and were electrophoresed along with 100bp DNA ladder on 1% agarose gel (100 V for 1 hr). The bands were visualized by staining with 0.5 μ L/ml ethidium bromide.

3. Results

Of 58 paraffin-embedded tissues studied, 18 (31%) samples had granulomatous skin infections caused by atypical *Mycobacterium* and 40 (69%) samples of granulomatous skin infection had recourse of non-*Mycobacterium* (Parasitic and fungal).

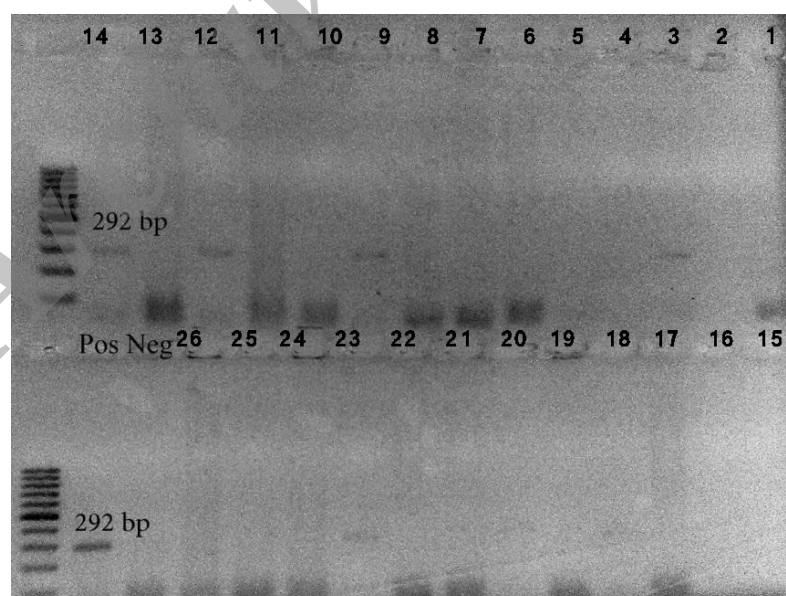
PCR identification of Atypical *Mycobacterium* species in samples was successful in 18 strains and showed specific amplicon at 292 bp (Figure 1). It proved that 31% of suspected granuloma tissues were infected with Atypical *Mycobacterium*. The results of PCR samples are present in Table 2 and 3. Based on the results obtained by PCR test, 8 (44%) isolates were positive for *M. marinum*, 3 (17%) isolates for *M. ulcerans*, 5 (27%) isolates for *M. fortuitum-chelonae* and 2 (12%) isolates for *M. avium*, as they showed specific amplicon at 154 bp (Figure 2). The method used in this study showed that 8 out of 58 granuloma tissues were infected with *M. marinum*. Of all samples studied, 40 (69%) were negative for PCR tests, which shows they have been infected with other parasitic and fungal microorganisms.

Table 1. Nucleotide sequences and primers used for identification of *Mycobacterium* spp. Design primers can detect all of *Mycobacterium* atypic species

Primer	Target genes	Sequence	Length(bp)
HSP-65		F:5'-GCCAAGAAGACCGACGACG-3'	292
		R:5'-GTGATGACGCCCTCGTTGC-3'	
HSP-65		F:5'-AAGCGCGGCATCGAGAAGG-3'	154
		R:5'-ACCTTGTCATGGCCTCGGC-3'	

Table 2: Identification of Atypical *Mycobacterium* species of samples, Atypic *Mycobacterium*-PCR and *M. marinum*-PCR results.

Percentage	Atypical <i>Mycobacterium</i> - PCR	
31%	18	+
	58	Total
<i>Mycobacterium</i> species- PCR		
17%	<i>Mycobacterium ulcerans</i> (3)	+
12%	<i>Mycobacterium avium</i> (2)	+
27%	<i>M. fortuitum chelonae</i> (5)	+
44%	<i>Mycobacterium marinum</i> (8)	+
	58	Total

**Figure 1.** Specificity of the PCR detection assay using the specific primers. M: Marker 100bp; PC: positive control [*M. smegmatis* (PTCC 1307)]; NC: Negative control, 1-9 suspected samples. The formation of 292bp bands in 9 Atypical *Mycobacterium* positive samples.

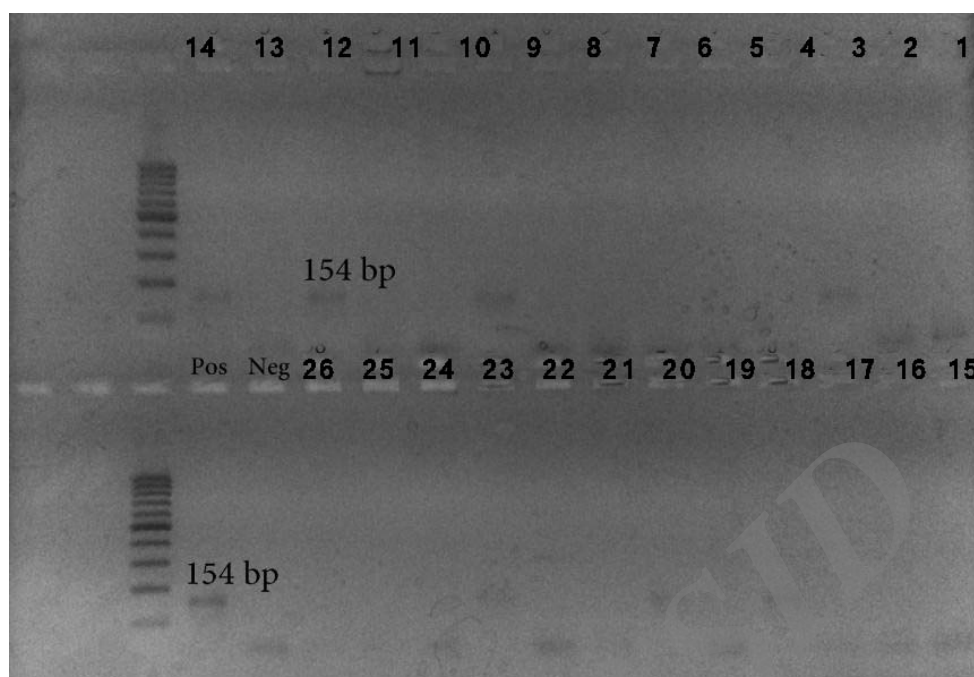


Figure2. Specificity of the PCR detection assay using the primers .M: Marker 100bp; PC: positive control [*M. smegmatis* (PTCC 1307)]; NC: Negative control. 1-8: positive *Mycobacterium* species. The formation of 154bp in 8 positive species.

4. Discussion

The results reported in this paper confirmed the detection of *M. marinum* as major agent of swimming pool granuloma for the first time in Iran.

These results reported occurrence of *M. marinum* in Iran as well as with intensive of granuloma tissues (Sciaccia, 2006). Microorganism with characteristics of Atypic *Mycobacterium* was isolated from granuloma skin tissues. The identification of the isolates was performed by PCR test. Routine identification of Atypic *Mycobacterium* species is usually based on Classic methods including acid-fast staining, culture, biochemical tests, BACTEC and immunofluorescence examination (Tsukamura, 1981). PCR is faster than the routine tests and it can be used as trusty and supersede test in the detection of *M. marinum* from skin tissues. In current syudy this technique showed a distinct advantage over the culture method of identification. In this study, examination of 58 granuloma skin tissue samples provided 18 Atypical *Mycobacterium* species. All *Mycobacterium* positive samples that were

analyzed for *M. marinum* infection by PCR method were positive (44%). On the other hand, of 58 skin tissue samples, 18 (31%) were infected with Atypical *Mycobacterium* species, while 40 (69%) samples were infected by non *Mycobacterium* organisms This study suggests that among different collecting sites, granuloma skin tissue samples are suitable for detection of *M. marinum* and the number of Atypic *Mycobacterium* in granuloma tissue may vary considerably. The results of this study confirmed that the main agent of fish tank granuloma was *M. marinum* and other strains may infect granuloma.

In other studies they used the PCR technique to amplify 16S rRNA and 23S rRNA genes to identify species of *Mycobacterium* (Abed et al., 1995). Reaserches provd that skin infection with *M. marinum* which in most cases it was associated and the majority of these skin lesions were on the hands with clinical sporotrichosis appearance (Sanchez et al., 2000). Based on the results obtained by an epidemiological study, cutaneous infection patients infected with *M. marinum* had been exposed to the fish due to their job as fishermen.

It can be concluded that the most dangerous places to get infected with this bacterium are swimming pools and fish farming ponds (Johnson and Tzumi., 1987). Granulomatous skin infections caused by atypical *Mycobacterium* generally occurs in soft tissues, skin and sometimes deep wounds, necrotic ulcers and subcutaneous on the skin and lesion has granulomatous transmission in the path of lymph glands similar cutaneous (Leishmaniasis & Sporotrichosis) (Sciacce-Kirby, 2006).

In conclusion, this report demonstrates that PCR can be considered as the method of choice for identification of Atypic *Mycobacterium*. The culture method not only can be costly and time consuming, but also may show some false negative results. The PCR method is rapid, reliable, and simple for detection of *Mycobacterium* contamination in granuloma tissues. This technique can successfully detect *M. marinum* and differentiate it from other similar parasitic and fungal microorganisms that cause granulomatous skin lesions.

References

- Abed, y., Bollet, C., Micco, H.S., 1995. Identification and strain differentiation of *Mycobacterium* species on the basis of DNA 16S-23S Spacer region polymorphism. *J Clin. Microbiol.* 146, 405-413.
- Bartralot, R., Garcia-Patos, V., Sitjas, D., Rodriguez-Cano, L., Mollet, J., Martin-Casabona, N., 2005. Clinical patterns of cutaneous non tuberculous *Mycobacterial* infection. *Br. J. Dermatol.*, 152 (4), 727-734.
- Boddinghaus, B., Rogall, T., Flohr, H., Blocker, and Bottger, E.C., 1990. Detection and identification of *Mycobacteria* by amplification of r RNA. *J. Clin. Microbiol.*, 28, 1751-1759.
- Cook, S., Bartos, R., Pierson, C., 1994. Detection and characterization of atypical *Mycobacteria* by the polymerase chain reaction. *Diagn MOL Pathol.*, 3, 53-58.
- Folgeira, L., Delgado, E., Palenque, 1993. Detection of *Mycobacterium tuberculosis* DNA in clinical samples by using a simple lysis method and polymerase chain reaction. *J. Clin. Microbiol.*, 31, 1019-1021.
- Frevel, T., Schafer, K., Totsch, M., 1999. PCR based detection of *Mycobacteria* in paraffin wax embedded material routinely processed for morphological examination. *MOL. pathol.*, 52, 283-288.
- Ghossein, R., Ross, R., Salomon, N., and Rabsonm, A., 1992. Rapid detection and species identification of *Mycobacteria* in paraffin-embedded tissues by polymerase chain reaction. *Diagn. MOL. Pathol.*, 1, 185-191.
- Goldmann, T., Richter, E., Galle, J., 1998. Molecular technologies in pathology detecting *Mycobacterial* DNA in paraffin-embedded tissue. *Pathol. Res. Pract.*, 194-261A.
- Johnson, J., Tzumi, A., 1987. Cutaneous *Mycobacterium marinum* infection (Swimming pool granuloma). *Clin. Dermatol.*, 5, 68-75.
- Mahaisavariya, P., Chaiprasert, A., Khemngern, S., Manonukul, J., 2003. Non tuberculous *Mycobacterial* skin infections. *Clinical & bacteriological studies J. Med. Assoc. Thai.*, 86, 52-60.
- Marie-claude, L., Haddad, N., Richard-Moreau, C., Marie-Francoise, T., 2000. Molecular characterization of environmental *Mycobacterium* strain by PCR-restriction fragment length polymorphism of hsp65 and by sequencing of hsp65, and of 16S and ITS r DNA. *Res. Microbiol.*, 151, 629-638.
- Palenque, E., 2000. Skin disease and Nontuberculous atical *Mycobacteria*. *Int. J. Dermatol.*, 39, 659.
- Sanchez, R., Ortiz, C., Munoz-Sanz, A., 2000. Cutaneous sporotrichoid infection by *M. marinum*. *Infect. Microbiol. clin.*, 18 (1), 50-51.
- Sciacce-Kirby, J., 2006. *Mycobacterium marinum* infection of the skin. Available from [http:// www.emdicine.com/derm/](http://www.emdicine.com/derm/)
- Tan, H., Chan, R., 1999. Atypical *Mycobacterium* infection with sporotrichoid spread in a patient with human immunodeficiency virus. *Ann. Acad. Med. Singapore.*, 28 (6), 846-848.
- Tsukamura, M., 1981. A review of the methods of identification and differentiation of *Mycobacteria*. *Rev. Infect.* 3, 841-861.
- Vaneechoutte, M., de Beenhouwer, H., Claeys, G., Verschraegen, A., de Rouck, N., Paepe, A., 1993. Identification of *Mycobacterium* species by using amplified ribosomal DNA restriction analysis. *J. Clin. Microbiol.* 31, 2061- 2065.
- Wagner, D., Young, L., 2004. Nontuberculous *Mycobacterial* infections. A clinical review infection. 32, 257- 270.
- Wolinsky, E., Gomez, S., and Zimpfer, S., 1972. Sporotrichoid *M. marinum* infection treated with rifampin- ethambutol. *Am. Rev. Respir.*, 105, 964-967.