

CASE REPORT

Received: October 2018

Accepted: November 2018

## Head & Neck Interdigitating Dendritic Cell Sarcoma: A Case Report & Literature Review

Abolfazl Salari<sup>1</sup>, Hana Saffar<sup>2</sup>, Mohammad Shirkhoda<sup>1,\*</sup>

### A B S T R A C T

40

1. Cancer Research Center, Cancer Institute, Imam Khomeini Hospital Complex, Tehran University of Medical Sciences.
2. Anatomical and Clinical Pathology, Department of Pathology, Cancer Institute, IKHC, TUMS.

**\*Corresponding Author:**

Mohammad Shirkhoda, MD  
Department of Oncosurgery, Cancer Institute, Tehran University of Medical Sciences.

Tel: (+98)913 352 9627

Email: mshirkhoda@sina.tums.ac.ir

Interdigitating dendritic cells (IDCs) act as antigen-presenting cells (APC) of the immune system and have the ability to stimulate T cells. These cells are mostly seen in the paracortex of the lymph node. The interdigitating dendritic cell sarcoma (IDCS) originating from the IDC is an extremely rare tumor. This tumor is observed in both lymph nodes and non-lymph nodes. This malignancy is difficult to diagnose due to its rarity, and thus far no guideline has been established for its treatment. However, it seems that the best treatment for this malignancy is radical resection of the tumor. Meanwhile, the role of chemotherapy and radiotherapy in the survival and recurrence of the tumor is not clear. In this study, we present a case of IDCS originating from a cervical lymph node, which was first exposed to mass resection, with IHC evaluation revealing negative CD1a, CD3, CD20, CD23, and CD21 factors and positive S100 and LCA factors. After confirming the diagnosis, modified radical neck dissection was performed. In the next stage, the patient underwent chemotherapy with an R-CHOP regimen (Rituximab, Cyclophosphamide, Doxorubicin Hydrochloride, Oncovin, Prednisone) and neck radiotherapy. 18 months after the formation of the tumor, no sign of recurrence or metastasis was observed in the patient.

**Keywords:** Dendritic cells, Interdigitating dendritic cell sarcoma, Lymph node, Neoplasm

**BCCR**

2018; 10(4): 40-46

www.bccrjournal.com

## INTRODUCTION:

**I**nterdigitating dendritic cells (IDCs) are a subtype of dendritic cells that act as antigen-presenting cells (APC) of the immune system and have the ability to stimulate T cells<sup>1</sup>. Interdigitating dendritic cell sarcoma (IDCS) is classified as a histiocytic & dendritic cell neoplasm by the World Health Organization (WHO)<sup>2</sup>. In 1981, Feltkamp et al. reported the first case of this disease<sup>3</sup>. To date, a limited number of patients with this malignancy have been reported<sup>4</sup>. The mean age of these patients was 56.5 years, however, the disease has also been observed in children. In general, nodal involvement is more common than extranodal involvement. In terms of nodal involvement, cervical and axillary lymph nodes are more frequently involved than other lymphatic regions. On the other hand, the liver is the most common site for extranodal involvement. In addition to the liver, this tumor has been detected in the gastrointestinal tract, bone marrow, skin, and spleen<sup>5</sup>.

In terms of the morphology of the tumor, there is a fascicled proliferation or expansion of oval-shaped cancerous cells in a focal storiform pattern, with separate nucleoli inside vesicular nuclei<sup>4</sup>. Observing this morphology, alongside positive S100 and negative CD1a factors in IHC (immunohistochemistry) bring us closer to a diagnosis of IDCS. The low incidence of this sarcoma complicates its detection, even by experienced hematopathologists. Furthermore, there are therapeutic challenges for the treatment of these patients; because, while surgery is used for this type of tumor (similar to other sarcomas), the role of adjuvant treatments (e.g., chemotherapy and radiotherapy or chemo-radiation) in these patients is not yet clear<sup>6</sup>.

In this study, we introduce a case of head & neck IDCS and evaluate the diagnostic and treatment methods of the disease.

## CLINICAL HISTORY

A 43-year-old male was referred to our center after ex-

cision of a neck mass with IDCS pathology. The patient claimed that a painless tumor had existed on the right side of his neck for the last two months, detected as a hypo-echoic mass lesion (size=13\*27mm) via ultrasound. He mentioned no other diseases in his past medical history. Following a diagnosis of pathologic lymphadenopathy in the primary center, the patient underwent an excisional biopsy. Pathology analysis led to a diagnosis of IDCS in the patient using morphology and IHC methods.

## Pathological Features:

Sections from the lymph node showed distorted architecture and partial effacement by neoplastic cells composed of oval to spindle cells with vesicular nuclei and eosinophilic cytoplasm arranged in focal storiform fascicles and vague nodules (**Figure 1**). The background was infiltrated by inflammatory cells rich in lymphocytes and plasma cells. On immunohistochemistry study, neoplastic cells were positive for LCA (**Figure 2**). S100 was positive in some elongated spindle cells (**Figure 3**). The expanded follicular dendritic cell meshwork was highlighted by CD21. CD23 was mainly positive in mantle zones. CD20 and CD3 decorated background B and T lymphocytes respectively. Other markers such as CD1a, CD15, CD30, keratin, EMA and melanoma markers including HMB45 and melan A were negative. Ki67 expression was about 40%. Overall histo-morphology and immunohistochemistry results were in favor of dendritic cell sarcoma. Due to negative staining for FDC markers and positive reaction of some elongated cells for S100, IDCS seemed like the more probable diagnosis.

## Treatment & Follow up:

After diagnosis of the disease, the patient underwent a neck and thorax CT scan, which was normal. One month after the initial surgery, the patient underwent modified radical cervical lymph node dissection, which led to the removal of 30 lymph nodes, all of which were

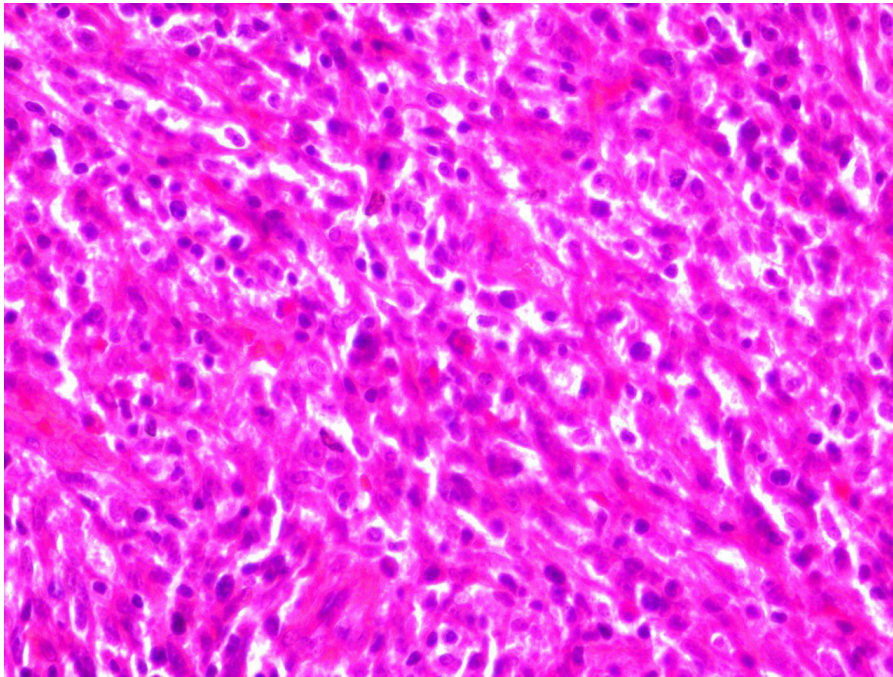


Figure 1. H&E, X400 - Partial effacement of lymph node by oval to spindle cells

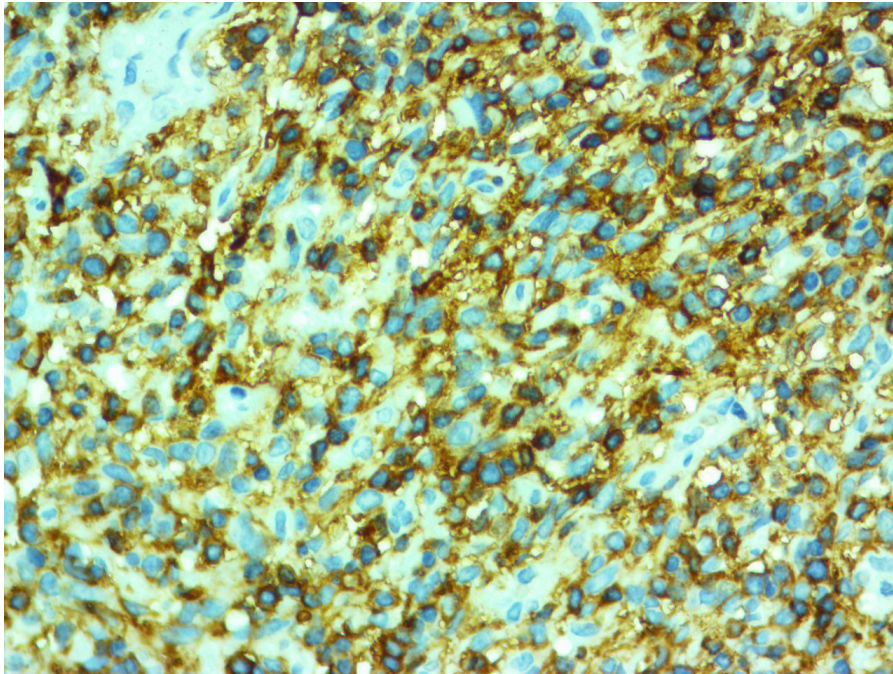


Figure 2. LCA is strongly positive in neoplastic cells.x400

free of tumor cells. Moreover, previous tumor margins were not tumoral.

Adjuvant treatment was initiated for the patient following surgical treatment. One month after the second surgery, chemotherapy with a regimen of 5 drugs known as R-CHOP (rituximab, cyclophosphamide, doxorubicin hydrochloride, Oncovin, and prednisone) was initiated for 6 sessions with 21 day intervals. One month after the chemotherapy sessions, radiation therapy was done in 2 fields (neck- supraclavicular & axillary). In each field 45 Gy radiation was used in 25 fractions.

Two months after treatment and one year after the start of the disease, the patient underwent thorax, neck, and brain CT scan as a follow-up, which showed no metastasis or recurrence. Today, 18 months from the start of the disease, the patient's general condition is good, and there has been no sign of recurrence or metastasis.

### LITERATURE REVIEW:

After conducting a search in electronic databases, information on patients diagnosed with IDCS and cervical lymph node involvement was gathered and summarized in **Table 1**. Different modalities have been used for the treatment of patients, most of which were successful in controlling the disease. In 4 cases, surgical treatment was the only applied therapeutic modality. Chemotherapy was used as the only therapeutic modality in 5 patients. However, one patient received no treatment except for radiation therapy. In this respect, the most common type of chemotherapy regimen used was CHOP (cyclophosphamide, doxorubicin, vincristine, and prednisone).

### DISCUSSION:

Dendritic cells are non-lymphoid non-phagocyte cells

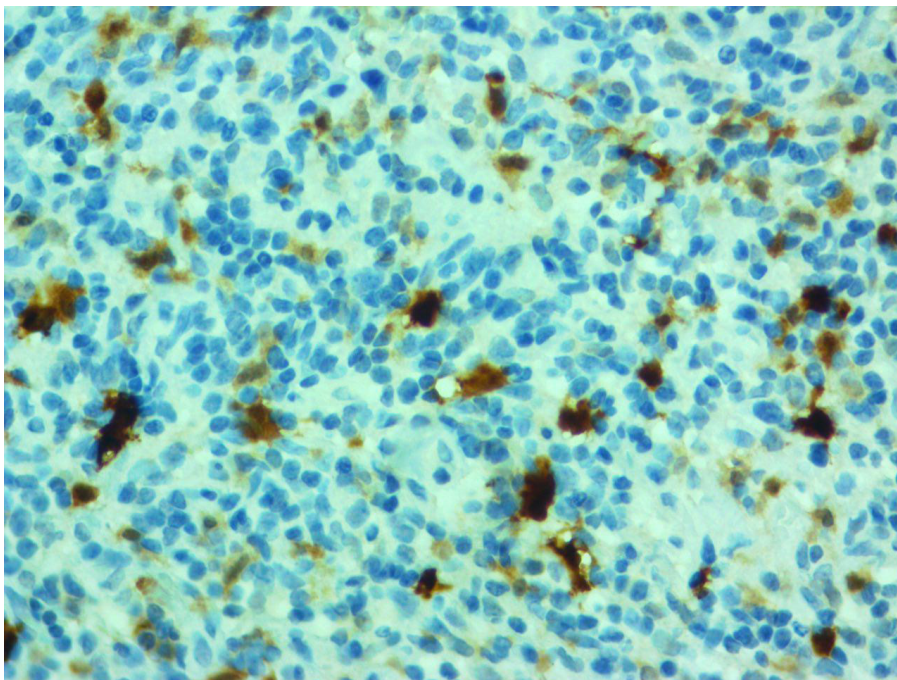


Figure 3. S100 positive nuclear immunoreaction in some elongated cells x400

and their role in shaping the immune response is recognizing antigens and presenting them to B and T cells<sup>7</sup>. There are four types of dendritic cells, including histiocytic, fibroblastic, follicular, and interdigitating, which exist in lymph nodes<sup>1</sup>. Interdigitating dendritic cells

present antigens to T cells and mostly exist in areas adjacent to these cells, such as paracortex lymph nodes<sup>8,9</sup>. According to previous studies, there is a higher prevalence rate of IDCS in men, compared to women. While most reported cases have been in lymph nodes, there

**Table 1. Literature review of cervical lymph node IDCS.**

Authors	Age/gender	Initial treatment	Recurrence (Months)	Salvage Treatment	Other site involvement	Life status (months)*
<u>Xue et al 2018</u> <sup>4</sup>	61/male	Complete excision	No	No	-	Alive (12)
	53/male	Complete excision	No	No	-	Alive (16)
	65/female	No	No	No	-	Dead (6)
	46/female	Complete excision + RT	No	No	-	Alive (17)
	44/female	CT	No	No	-	Alive (11)
<u>Madabhavi et al 2016</u> <sup>14</sup>	35/female	CT(CHOP)+ RT	No	No	-	Alive (10)
<u>Helbig 2015 et al</u> <sup>13</sup>	22/female	CT(ABVD)	No	No	-	Alive (24)
<u>Pokuri et al 2015</u> <sup>8</sup>	81 /male	M.R.N.D	No	No	-	Alive (18)
<u>Zhou et al 2011</u> <sup>15</sup>	41/female	Complete excision + CT(CHOP)	No	No	-	Alive (10)
<u>Jo et al 2006</u> <sup>16</sup>	51/male	Neck dissection	No	No	-	Alive (6)
<u>Sharma et al 2006</u> <sup>17</sup>	73/male	SND + P.P + RT	No	No	Parotid	Alive (15)
<u>Ylagan et al 2003</u> <sup>18</sup>	66/male	Parotidectomy+ RT	Yes (18)	No	-	Dead (19)
<u>Nakamura et al 1994</u> <sup>19</sup>	58/male	CT(CHOP)	Yes(48)	Excision	Jejunum, mesenteric L.Ns	Dead (101)
	54/male	CT(CHOP)	Yes (NR)	CT(CHOP)	Para-aortic and mesenteric L.Ns	Dead (12)
	55/female	RT	No	No	-	Alive (18)
<u>Yamakawa et al 1991</u> <sup>20</sup>	54/male	CT(CHOP)	No	No	-	Alive (12)

\*Time was measured from the date of diagnosis to the date of last follow-up or death  
 CT: chemotherapy RT: radiotherapy P.P: partial parotidectomy SND: selective neck dissection  
 L.N: lymph node NR: not reported  
 CHOP: cyclophosphamide, doxorubicin, vincristine, and prednisone  
 ABVD: Adriamycin, Bleomycin, vinblastine, Dacarbazine  
 MRND: modified radical neck dissection

have been some cases of independent extranodal involvement and simultaneous nodal and extranodal involvement. In this regard, the most common symptom reported by patients was the presence of painless tumors<sup>5</sup>.

Considering the difficult diagnosis process of this tumor, the use and evaluation of tissue samples and application of the IHC method greatly contribute to the diagnosis of this type of cancer. Spindle cells, with distinct nucleoli inside vesicular nuclei with an eosinophilic cytoplasm, located in a storiform or fascicled shape, are a sign of IDCS<sup>4,10</sup>. On the other hand, S100, CD21, CD23, CD35, and CD1a are IHC factors that help us in the differentiation of different DCS types. Positive CD1a is in favor of Langerhans cells sarcoma, and positive CD21, CD23, and CD35 are indicative of follicular dendritic cell sarcoma. On the other hand, positive S100 alongside a negative CD1a, CD21, CD23, and CD35 are in favor of an IDCS diagnosis<sup>7</sup>. In our case, the presence of pathological characteristics in favor of IDCS, as well as a positive S100 and negative CD21, CD23, and CD1a provided a definite IDCS diagnosis. The treatments of choice for this disease include surgery, chemotherapy, radiotherapy or a combination of these methods. In localized cases, surgery is the main treatment since it increases survival and is curative in more than half of cases<sup>6, 11, 12</sup>. While the role of surgery in the treatment of these patients is clear to some extent, the same is not true for chemotherapy and radiotherapy. It seems that while the use of radiotherapy as an adjuvant treatment had no impact on the overall survival of patients, it did increase disease-free survival<sup>1, 5</sup>. In metastatic cases, chemotherapy is recommended as an adjuvant treatment after surgery. Treatment regimens similar to those used in lymphoma cases include CHOP, ABVD (adriamycin, bleomycin, vinblastine, dacarbazine), and ICE (ifosfamide, carboplatin, etoposide)<sup>5</sup>. Treatment with chemotherapy via the ABVD regimen using no other modalities has also

been reported in curative patients<sup>13</sup>.

In conclusion, it is not possible to definitely specify the most efficient treatment for IDCS patients due to the low number of reported cases, lack of a specific treatment guideline, and lack of prospective studies in this regard. However, it seems that in operable cases, complete resection of the tumor is the main treatment of choice, yielding the best outcomes. We cannot give a definite opinion about the effect of post-operative chemotherapy or radiotherapy on recurrence or survival rates. Nonetheless, given the success of adjuvant treatment in some cases, it is better to use all therapeutic power to treat these tumors.

## REFERENCES:

1. Fonseca R, Yamakawa M, Nakamura S, van Heerde P, Miettinen M, Shek TW, et al. Follicular dendritic cell sarcoma and interdigitating reticulum cell sarcoma: a review. *American journal of hematology*. 1998;59(2):161-7.
2. Swerdlow SH, Campo E, Pileri SA, Harris NL, Stein H, Siebert R, et al. The 2016 revision of the World Health Organization classification of lymphoid neoplasms. 2016;127(20):2375-90.
3. Feltkamp CA, van Heerde P, Feltkamp-Vroom TM, Koudstaal J. A malignant tumor arising from interdigitating cells; light microscopical, ultrastructural, immuno- and enzyme-histochemical characteristics. *Virchows Archiv A, Pathological anatomy and histology*. 1981;393(2):183-92.
4. Xue T, Jiang XN, Wang WG, Zhou XY, Li XQ. Interdigitating dendritic cell sarcoma: Clinicopathologic study of 8 cases with review of the literature. *Annals of diagnostic pathology*. 2018;34:155-60.
5. Saygin C, Uzunaslana D, Ozguroglu M, Senocak M, Tuzuner N. Dendritic cell sarcoma: a pooled analysis including 462 cases with presentation of our case series. *Critical reviews in oncology/hematology*. 2013;88(2):253-71.
6. Perkins SM, Shinohara ET. Interdigitating and follicular dendritic cell sarcomas: a SEER analysis. *American journal of clinical oncology*. 2013;36(4):395-8.
7. Pizzi M, Ludwig K, Palazzolo G, Busatto G, Rettore C, Altavilla G. Cervical follicular dendritic cell sarcoma: a case report and review of the literature. *International journal of immunopathology and pharmacology*. 2011;24(2):539-44.
8. Pokuri VK, Merzianu M, Gandhi S, Baqai J, Loree TR, Bhat S. Interdigitating dendritic cell sarcoma. *Journal of the National Comprehensive Cancer Network : JNCCN*.

- 2015;13(2):128-32.
9. Steinman RM, Pack M, Inaba K. Dendritic cells in the T-cell areas of lymphoid organs. *Immunological reviews*. 1997;156:25-37.
  10. Ninkovic S, Cole-Sinclair MF. Interdigitating dendritic cell sarcoma: diagnostic pitfalls, treatment challenges and role of transdifferentiation in pathogenesis. *Pathology*. 2017;49(6):643-6.
  11. De Pas T, Spitaleri G, Pruneri G, Curigliano G, Noberasco C, Luini A, et al. Dendritic cell sarcoma: an analytic overview of the literature and presentation of original five cases. *Critical reviews in oncology/hematology*. 2008;65(1):1-7.
  12. Kairouz S, Hashash J, Kabbara W, McHayleh W, Tabbara IA. Dendritic cell neoplasms: an overview. *American journal of hematology*. 2007;82(10):924-8.
  13. Helbig G, Wichary R, Pajak J, Budny M, Makowska M, Machura K, et al. Sustained remission after ABVD treatment for interdigitating dendritic cell sarcoma. *Contemporary oncology (Poznan, Poland)*. 2015;19(1):83-5.
  14. Madabhavi I, Patel A, Modi G, Anand A, Panchal H, Parikh S. Interdigitating dendritic cell tumor: A rare case report with review of literature. *Journal of cancer research and therapeutics*. 2018;14(3):690-3.
  15. Zhou ZY, Sun RC, Yang SD, Liang JB, Rui J, Pan MH. Interdigitating dendritic cell tumor of the lymph node in the right submaxillary region: a case report and review of the literature. *International journal of surgical pathology*. 2011;19(1):88-92.
  16. Jo S, Babb MJ, Hilsinger RL, Jr. Interdigitating dendritic cell sarcoma of cervical lymph nodes. *Archives of otolaryngology--head & neck surgery*. 2006;132(11):1257-9.
  17. Sharma M, Ahsan F, Ah-See KW, McKean ME, Kain R, Chapman AD. Interdigitating dendritic cell sarcoma of the parotid gland. *The Journal of laryngology and otology*. 2006;120(3):244-6.
  18. Ylagan LR, Bartlett NL, Kraus M. Interdigitating dendritic reticulum cell tumor of lymph nodes: case report with differential diagnostic considerations. *Diagnostic cytopathology*. 2003;28(5):278-81.
  19. Nakamura S, Koshikawa T, Kitoh K, Nakayama A, Yamakawa M, Imai Y, et al. Interdigitating cell sarcoma: a morphologic and immunologic study of lymph node lesions in four cases. *Pathology international*. 1994;44(5):374-86.
  20. Yamakawa M, Matsuda M, Imai Y, Arai S, Harada K, Sato T. Lymph node interdigitating cell sarcoma. A case report. *American journal of clinical pathology*. 1992;97(1):139-46.