

Evaluation of Rotator Cuff Tendinopathies and Tears with High-resolution Ultrasonography and Magnetic Resonance Imaging Correlation

Zubair Ahmad, Mohd Ilyas, Gh. Mohammad Wani, Naseer A. Choh, Tariq A. Gojwari, Mir Junaid Ahmad Kazime

Department of Radiodiagnosis, Sher-I-Kashmir Institute of Medical Sciences, Srinagar, Jammu and Kashmir, India

Abstract

Background: The aim of this study was to assess the accuracy of high-resolution ultrasonography (USG) in the evaluation of rotator cuff tendinopathies and tears with magnetic resonance imaging (MRI) correlation to determine its sensitivity and specificity. **Materials and Methods:** The prospective study was conducted on 40 patients referred to the Department of Radiology for the evaluation of rotator cuff pathologies over a period of 18 months. All the patients underwent high-frequency USG followed by MRI. Variables such as sensitivity, specificity, negative predictive value (NPV), positive predictive value (PPV), and accuracy of high-frequency USG and MRI were evaluated. **Results:** The sensitivity, specificity, NPV, PPV, and accuracy of high-frequency USG in the evaluation of rotator cuff pathologies in comparison to MRI as standard were 90.6%, 87.5%, 96.6%, 70%, and 90%, respectively. **Conclusion:** High-frequency USG is almost equally sensitive and specific as MRI for the diagnosis of rotator cuff pathologies, and due to its cost-effectiveness, easy affordability, ease of evaluating contralateral shoulder, more patient compliance, noninvasiveness, and wider applications, we recommend it to be used as a primary modality for evaluating rotator cuff. MRI should be performed in case some extra information is required.

Keywords: High-frequency ultrasonography, magnetic resonance imaging, rotator cuff tears, rotator cuff tendinopathies

INTRODUCTION

The shoulder joint is an elegant anatomic structure held in place by a complex arrangement of muscles, tendons, and ligaments. Rotator cuff is a continuous structure around the shoulder comprised four tendons – subscapularis, supraspinatus, infraspinatus, and teres minor tendons; the long head of the biceps tendon also contributes to the cuff.^[1] The requisites for normal cuff functioning are strong, healthy, intact cuff muscles and tendons, normal capsular laxity, and smooth coracoacromial arch.

Rotator cuff tears are associated with heavy labor, bony subacromial impingement, tissue degeneration in the aging population, and repeated steroid injections.^[2-4]

Intrinsic causes lead to degenerative changes in the substance of the rotator cuff with increasing age. The degeneration may result from relative ischemia in the distal portion of the tendon near its insertion site on the humerus. Rotator cuff degeneration may incite secondary proliferative bony changes on the under surface of acromion.

Extrinsic cause of rotator cuff disease relates to the mechanical impingement by surrounding structures. The impingement can lead to inflammatory and degenerative changes in the underlying tendons.^[1] Rotator cuff tears can be full-thickness tear (FTT) or partial-thickness tear (PTT).

Full-thickness tear

A FTT is a defect that allows communication between the subacromial-subdeltoid (SASD) bursa and the glenohumeral joint.

Partial-thickness tear

PTTs are so called because they involve only either substance or surface of the tendon. Joint surface partial tears are more

Address for correspondence: Dr. Mohd Ilyas,
Department of Radiodiagnosis, Sher-I-Kashmir Institute of Medical
Sciences, Soura, Srinagar - 190 011, Jammu and Kashmir, India.
E-mail: ilyasmir40@gmail.com

This is an open access journal, and articles are distributed under the terms of the Creative Commons Attribution-NonCommercial-ShareAlike 4.0 License, which allows others to remix, tweak, and build upon the work non-commercially, as long as appropriate credit is given and the new creations are licensed under the identical terms.

For reprints contact: reprints@medknow.com

How to cite this article: Ahmad Z, Ilyas M, Wani GM, Choh NA, Gojwari TA, Ahmad Kazime MJ. Evaluation of rotator cuff tendinopathies and tears with high-resolution ultrasonography and magnetic resonance imaging correlation. Arch Trauma Res 2018;7:15-23.

Access this article online

Quick Response Code:



Website:
www.archtrauma.com

DOI:
10.4103/atr.atr_20_17

common than bursal surface partial tears.^[5] Shoulder pain is a significant cause of morbidity, the prevalence of self-reported pain is estimated to be between 16% and 26%, and it is the third most common cause of musculoskeletal consultation in primary care.^[6]

A thorough understanding of the anatomy and function of the rotator cuff and the consequences of rotator cuff disorders is essential for optimal treatment, planning, and prognostic accuracy. Identifying the disorder, understanding the potential clinical consequences, and reporting all relevant findings at rotator cuff imaging are also essential.

Both ultrasonography [USG] and magnetic resonance imaging (MRI), being two competing noninvasive techniques, are currently touted for evaluating rotator cuff pathologies and essentially obviating conventional arthrography. Technical improvements, coupled with advances in the understanding of anatomic and pathologic characteristic of the rotator cuff, have resulted in the maturation of these two modalities.^[7] Both techniques have their advantages and disadvantages and can be competitive and complementary at the same time.

At present, MRI is the preferred choice for the evaluation of rotator cuff fatty infiltration and muscle atrophy in clinical practice. However, it is expensive and time-consuming.^[8] The accuracy of these imaging tests is considered to have improved significantly over time, enabling useful assessment of the size and extent of the rotator cuff tear when planning surgery.

Various authors have suggested that US is as accurate as MRI for both FTTs and PTTs. These results, combined with the lower cost of US, suggest that US may be the most cost-effective imaging method for screening of rotator cuff tears provided that the examiner has been properly trained in this operator-dependent technique.^[9] Moreover, MRI should be used secondarily because it provides more information about extent of tendons and has lower risk of artifacts.

Aim and objectives

1. To assess the diagnostic accuracy of high-resolution USG for diagnosing rotator cuff tears and tendinopathies (one or more tendons) with MRI correlation
2. To determine the diagnostic accuracy of high-resolution USG for assessing the biceps tendon pathologies in people with rotator cuff tears and tendinopathy.

MATERIALS AND METHODS

The study was conducted over a period of 18 months in the Department of Radiology. The study was approved by the Institutional Ethical and Scientific Committee.

The prospective study was carried out on 40 patients with clinically suspected rotator cuff pathology referred from the departments of orthopedics and physical medicine and rehabilitation over a period of 18 months.

Inclusion criteria

Patients aged ≥ 20 years of either gender who presented with pain in shoulders and were clinically suspected to have rotator cuff pathology, both acute and chronic, were included in the study.

Exclusion criteria

- Patients with metallic implants, cardiac pacemakers, cochlear implants
- Patients who were claustrophobic
- Patients who refused to give consent
- Patient who were unwilling for imaging
- Patients who had undergone shoulder surgery
- Posttreatment patients.

Methods

The study was conducted in along the following lines:

- A high-resolution real-time US examination of shoulder was done
- US examination of the contralateral shoulder was done in each patient for comparison
- Dual-image technology and aligning the soft tissues on both the sides to mirror each other were used for precise comparison, often with bony landmarks and contours as guide
- MRI shoulder was done in all patients and the findings were recorded and correlated with the USG findings
- All the ancillary investigations such as shoulder X-ray (anteroposterior view) were done as and when required.

Sonographic technique and patient position

The sonography was performed with Siemens Aloka equipped with a phased array linear 7–11 MHz transducer. The US examination was done according to the American Institute of US in Medicine Practice Guidelines (2007) for the Performance of the Musculoskeletal US Examination.

Patients were examined in the sitting position, on a rotating seat. The biceps tendon was examined with the forearm in supination and resting on the thigh or with the arm in slight external rotation. The tendon was examined in a transverse plane (short axis), where it emerges from under the acromion to the musculotendinous junction distally. Longitudinal views (long axis) were also obtained. These views were used to determine if the tendon is properly positioned within the bicipital groove, subluxated, dislocated, or torn.

To examine the subscapularis tendon, the elbow remained at the side while the arm was placed in external rotation. Both transverse (long-axis) and sagittal (short-axis) views were obtained. Dynamic evaluation as the patient moved the arm from internal to external rotation was also done.

To examine the supraspinatus tendon, the arm was extended posteriorly, and the palmar aspect of the hand was placed against the superior aspect of the iliac wing with the elbow flexed and directed toward midline (patient was instructed to place the hand in the back pocket).

To scan the supraspinatus and infraspinatus tendons along their long axis, the transducer was oriented approximately 45° between the sagittal and coronal planes to obtain a longitudinal view. The transducer was then moved anteriorly and posteriorly to completely visualize the tendons.

Transverse views of the tendons were obtained by rotating the probe 90° to the long axis. The tendons were visualized by sweeping medially to the acromion and laterally to their insertions on the greater tuberosity. The more posterior aspect of the infraspinatus and teres minor tendons was examined by placing the transducer at the level of the glenohumeral joint below the scapular spine while the forearm rested on the thigh with the hand supinated. Internal and external rotation of the arm was helpful in identifying the infraspinatus muscle and its tendon and in detecting small joint effusions.

To visualize the teres minor tendon, the probe was angled slightly inferiorly. Throughout the examination of the rotator cuff, the cuff was compressed to detect nonretracted tears. In the evaluation of rotator cuff tears, comparison with the contralateral side was done.

While examining the rotator cuff, attention was also paid to evaluate for bursal thickening, effusion, loose bodies, tendon calcification, and muscle and bony abnormalities. If symptoms warranted, the acromioclavicular joint, the supraspinatus notch, and the spinoglenoid notch were also evaluated.

USG criteria for the diagnosis of rotator cuff tears include direct and indirect signs.

All MRI examinations were performed with a 1.5-T MR system (MAGNETOM Avanto, Siemens Healthcare, Germany). A flexible surface coil for shoulder was used. The patients were positioned in the magnet supine with the arms along the thorax and the affected arm externally rotated. The scanning protocol included oblique coronal (along the long axis of the tendon of the supraspinatus muscle), oblique sagittal (perpendicular to the course of supraspinatus muscle), and axial planes. The MRI shoulder protocol consisted of:

- Oblique sagittal T1-weighted fast-spin echo (FSE) images
- Oblique coronal T1-weighted FSE, T2-weighted FSE, proton-density images, and short tau inversion recovery images
- Axial gradient echo images.

A field of view of 16 cm and the slice thickness of 4 mm were used.

MRI findings were classified into intact cuff, partial-thickness and full-thickness rotator cuff tears, and tendinopathies. Established criteria were used for the diagnosis of a partial-thickness or full-thickness rotator cuff tears. Biceps tendon involvement and other associated abnormalities were noted.

Observations and Results

There were 22 males and 18 females, with a ratio of 1.2:1. Statistically, no difference was found in the prevalence of

shoulder pain in relation to gender. Distribution of patients with shoulder pain as per age group was 8 (20%) patients in 20–40 years of age group, 14 (35%) patients in 41–60 years of age group, and 18 (45%) patients in the age group of ≥61 years. The prevalence of shoulder pain increases with the increasing age.

The highest number of patients was in the age group of ≥61 years (45%). Eleven (27.5%) patients had a history of trauma. Two (5%) patients were in 20–40 years of age group, 4 (10%) patients were in 41–60 years of age group, and 5 (12.5%) patients were in the age group of ≥60 years. The number of patients with right shoulder pain was 32 (80%) and left shoulder pain was 8 (20%).

There was statistically significant difference between the prevalence of cuff tear in the dominant and nondominant arms. Out of 25 right-handed patients, 23 patients had rotator cuff pathology involving the right shoulder and two had pathology involving the left shoulder. Out of seven patients who were left handed, five patients had rotator cuff pathology of left shoulder while two patients had right shoulder cuff pathology. It suggests that the dominant arm is more prone to wearing effects and thus tear/tendinopathy.

Out of 40 patients, 14 patients showed FTTs, nine patients had PTTs, seven patients had tendinopathy, and 10 patients were normal.

Agreement between ultrasonography and magnetic resonance imaging

The agreement between the USG and MRI was done using kappa coefficient and the agreement was found to be good (kappa = 0.714).

The strength of agreement between USG and MRI for the diagnosis of rotator cuff tears and tendinopathy is considered to be “good.” Out of 30 patients with cuff lesions on USG, 14 patients showed FTTs and one patient with MRI-proven PTT was falsely diagnosed as having FTT. USG also showed nine PTTs, out of which one had FTT and one had tendinopathy on MRI.

Three patients with MRI-proven lesions were falsely diagnosed as normal. Out of seven patients with tendinopathy, one was normal, one had FTT, and two had PTT on MRI. USG detected 29 true-positive lesions, three false-negative lesions, and one false-positive lesion while seven patients were diagnosed as normal (true negatives). When MRI was conducted on these patients, 32 patients had rotator cuff lesions while eight patients were normal. Out of these 32 patients, 15 patients showed FTTs, 10 patients showed PTTs, and seven had tendinopathy.

Statistical evaluation of USG for the detection of rotator cuff tears and tendinopathy compared with MRI was done. Sensitivity, specificity, and positive and negative predictive values (PPV and NPV) were calculated according to accepted formulae. Tables 1-11 show the frequency of various abnormalities seen on USG and MRI with the correlation

Table 1: Direct ultrasound signs observed in patients with full- and partial-thickness rotator cuff tears and tendinopathy

Direct ultrasound signs	FTT (n=14), n (%)	PTT (n=9), n (%)	Tendinopathy (n=7), n (%)	Total (n=40), n (%)
1. Full-thickness discontinuity of the rotator cuff	8 (57.1)	0	0	8 (20)
2. Nonvisualization of the rotator cuff tendon	6 (42.8)	0	0	6 (15)
3. Focal thinning of the rotator cuff tendons	0	2 (22.2)	0	2 (5)
4. A hypoechoic defect involving surface (articular/bursal) or substance of the tendon	0	7 (77.7)	0	7 (17.5)
5. Bulky, heterogenous echogenicity of tendon	0	0	5 (71.4)	5 (12.5)
6. Diffuse thinning or calcifications in the tendon	0	0	2 (28.6)	2 (5)

FTT: Full-thickness tear, PTT: Partial-thickness tear

Table 2: Indirect ultrasound signs observed in patients with partial- or full-thickness rotator cuff tears and tendinopathy

Indirect USG signs	FTT (n=14), n (%)	PTT (n=9), n (%)	Tendinopathy (n=7), n (%)	Total (n=40), n (%)
1. The concavity of the subdeltoid bursal fat or loss of convexity of the outer border of the rotator cuff	3 (21.4)	0	1 (14.2)	4 (10)
2. Cortical irregularity at the insertion of rotator cuff tendon	10 (71.4)	6 (66.6)	2 (28.5)	18 (45)
3. Cartilage interface sign	3 (21.4)	1 (11.1)	0	4 (10)
4. SASD bursal effusion	8 (57.1)	3 (33.3)	2 (28.5)	13 (32.5)

USG: Ultrasonography, SASD: Subacromial subdeltoid, FTT: Full-thickness tear, PTT: Partial-thickness tear

Table 3: Results obtained on magnetic resonance imaging

Diagnosis	MRI	Percentage
FTT	15	37.5
PTT	10	25
Tendinopathy	7	17.5
No tear	8	20
Total	40	100

MRI: Magnetic resonance imaging, FTT: Full-thickness tear, PTT: Partial-thickness tear

between two including the statistical figures. Figures 1-7 show the comparative (USG and MRIs) of various rotator cuff tendinopathies seen in the present study.

DISCUSSION

One of the most common causes of shoulder pain is rotator cuff disease. It is the third most prevalent musculoskeletal disorder after low back and neck pain. Shoulder pain is usually due to one of several causes: subacromial impingement and bursopathy, tendinopathy, a tendon tear, a frozen shoulder, ligamentous instability, and osteoarthritis. This study was based on the evaluation of rotator cuff tendinopathies and tears with high-resolution USG and MRI correlation.

The present study found no statistical difference in the prevalence of rotator cuff tear or tendinopathy in each gender, which correlates to the study conducted by Milgrom *et al.*^[10]

The ages of all the cases ranged from 20 to 70 years (mean age 45 years).

History of trauma was more often seen in elderly patients. It was found that massive tears affect elderly population more frequently.

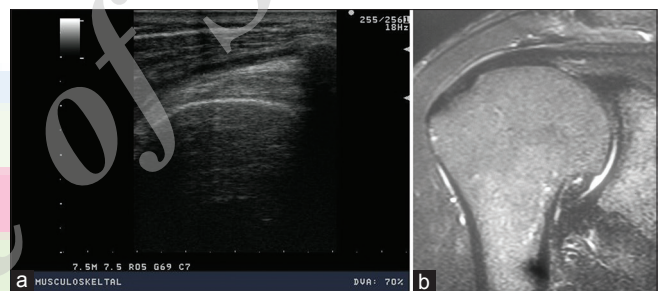


Figure 1: (a) Short-axis ultrasound image showing normal supraspinatus tendon. (b) Coronal T2-weighted image showing normal supraspinatus tendon

Out of 25 patients who were right handed, 23 patients had rotator cuff pathology involving the right shoulder and two had pathology involving the left shoulder. It suggests that dominant arm is more susceptible to wearing effects, leading to rotator cuff tears and tendinopathy.

Similar results were obtained by Moosmayer *et al.*, who studied 100 subjects with full-thickness rotator cuff tears and found that RCT was more common in the dominant arm.^[11]

US examination of the contralateral shoulder was done in each for comparison. Rutten *et al.* recommended comparison with the contralateral shoulder as additional support for avoiding misinterpretation of normal anatomic differences as tears.^[12]

Out of 40 patients, 14 patients showed FTTs, nine patients were diagnosed as having PTT, seven patients showed tendinopathy, and 10 patients were normal on USG. Thus, USG showed a total of 30 patients with rotator cuff pathologies.

Rotator cuff tears were diagnosed on US as per the direct and indirect signs. The direct signs were full-thickness discontinuity or nonvisualization of the tendon (FTT) and focal thinning or

Table 4: Magnetic resonance imaging signs observed in patients with full- and partial-thickness rotator cuff tears and tendinopathy

MRI signs	FTT (n=15), n (%)	PTT (n=10), n (%)	Tendinopathy (n=7), n (%)	Total (n=40), n (%)
1. Visualization of an altered signal intensity in the tendon, extending from articular surface to the bursal surface of the tendon	10 (66.6)	0	0	10 (25)
2. Nonvisualization of the rotator cuff tendon or retraction of the musculotendinous junction	5 (33.4)	0	0	5 (12.5)
3. Focal area of mildly increased signal on PD-weighted images, which increases in signal on T2-weighted images, and extends to one surface only (articular/bursal) or is seen within substance of the tendon	0	8 (80)	0	8 (20)
4. Contour irregularities (attenuated or thickened tendon)	0	2 (20)	2 (28.6)	4 (10)
5. Bulky hyperintense tendon on PD and T2-weighted sequences	0	0	5 (71.4)	5 (12.5)

MRI: Magnetic resonance imaging, FTT: Full-thickness tear, PTT: Partial-thickness tear, PD: Proton dense

Table 5: Other magnetic resonance imaging signs observed in patients with full- and partial-thickness rotator cuff tears and tendinopathy

MRI signs	FTT (n=15), n (%)	PTT (n=10), n (%)	Tendinopathy (n=7), n (%)	Total (n=40), n (%)
Presence of fluid in the subdeltoid bursa	9 (60)	2 (20)	2 (28.5)	13 (32.5)
Fluid in the glenohumeral joint	2 (13.3)	1 (10)	1 (14.2)	4 (10)
Loss of peribursal fat plane	6 (40)	2 (20)	2 (28.5)	10 (25)

MRI: Magnetic resonance imaging, FTT: Full-thickness tear, PTT: Partial-thickness tear

Table 6: Abnormalities of the ipsilateral biceps tendon observed on ultrasound and magnetic resonance imaging

Abnormalities of the ipsilateral biceps tendon	USG (%)	MRI (%)
Biceps tendon effusion	26 (65)	27 (67.5)
Rupture of the biceps tendon	1 (2.5)	1 (2.5)
Biceps tendon subluxation	2 (5)	2 (5)
Biceps tendinopathy	2 (5)	3 (7.5)

MRI: Magnetic resonance imaging, USG: Ultrasonography

focal hypoechoic defect involving surface or substance of the tendon (PTT). Tendinopathy was diagnosed as bulky heterogeneous tendon or diffuse thinning or calcifications of the tendon.

Out of 14 patients with FTTs, eight patients had full-thickness discontinuity and six patients showed nonvisualization of the tendon. Out of nine patients with partial tears, seven patients showed a hypoechoic defect involving substance or surface (articular or bursal) of the tendon and two patients demonstrated focal thinning of the tendon. The articular surface tears were the most common type of PTTs, seen in four patients. Similar results were reported by Rutten *et al.*, who found hypoechoic defect and focal thinning of the tendon as markers of PTT.^[13]

Because of the difficulty in diagnosing some rotator cuff tears with USG, certain indirect signs have been described. These indirect signs in our study were concavity of the subdeltoid bursal fat or loss of the convexity of the outer border of the rotator cuff, cortical irregularity, cartilage interface sign, fluid in the SASD bursa, and fluid in the long head of biceps tendon sheath. We found cortical irregularity as an important

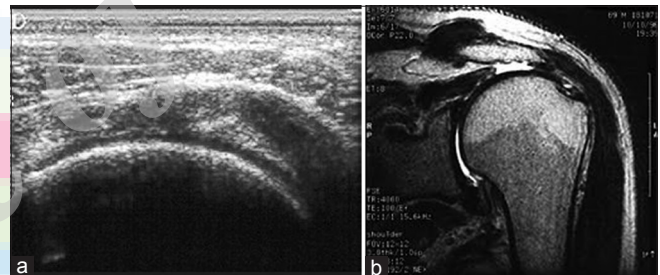


Figure 2: (a) Short-axis ultrasound image showing hypoechoic defect involving supraspinatus tendon extending from articular to bursal surface representing full-thickness tear. (b) Coronal T2-weighted image showing hyperintense signal involving supraspinatus tendon extending from articular to bursal surface representing full-thickness tear

secondary sign, seen in 10 out of 14 (71.4%) and 6 out of 9 (66.6%) patients with FTT and PTT, respectively. It is comparable to the study carried by Churchill *et al.*^[14]

Another important indirect sign was intrasynovial fluid which may be seen either in the SASD bursa or in biceps tendon sheath. This fluid is provoked by irritation and impingement of the entire rotator cuff.

On MRI, SASD bursal fluid was seen in a total of 13 (32.5%) patients, and all of them had either full- or partial-thickness rotator cuff tears or tendinopathies on USG. Out of these 13 patients, SASD bursal fluid was seen in eight out of 14 (57.1%) patients with FTTs, three out of 9 (33.3%) patients with PTTs, and two out of seven patients with tendinopathy. Similar results were reported by Beall *et al.*, who reported that the presence of intra-articular fluid in combination with SASD bursal fluid on US was highly specific and had a high PPV for rotator cuff tears.^[15]

Table 7: Prevalence of various findings on ultrasound and magnetic resonance imaging

Pathological findings in the rotator cuff	USG (n=30), n (%)	MRI (n=32), n (%)
Full-thickness discontinuity or hypoechoic defect on USG and altered signal intensity in the tendon on MRI	15 (50)	18 (56.2)
Tendon nonvisualization or complete or partial tendon retraction	6 (20)	5 (15.6)
Focal thinning of rotator cuff on USG or contour irregularities (attenuated or thickened) tendon on MRI	2 (6.6)	4 (12.5)
Biceps tendon effusion	21 (70)	25 (78.1)
Fluid in subdeltoid bursa	13 (43.3)	13 (40.6)
Bulky heterogenous echogenicity on USG and diffuse hyperintensity on MRI	5 (16.6)	5 (15.6)

MRI: Magnetic resonance imaging, USG: Ultrasonography

Table 8: Number of rotator cuff tears and tendinopathies diagnosed on ultrasound and magnetic resonance imaging

Result	Number of patients	
	USG (%)	MRI (%)
FTT	14 (35)	15 (37.5)
PTT	9 (22.5)	10 (25)
Tendinopathy	7 (17.5)	7 (17.5)
No tear	10 (25)	8 (20)
Total	40 (100)	40 (100)

MRI: Magnetic resonance imaging, USG: Ultrasonography, FTT: Full-thickness tear, PTT: Partial-thickness tear

Table 9: Agreement between ultrasound and magnetic resonance imaging for diagnosis of rotator tears and tendinopathies

USG	MRI				Total
	No tear	PTT	FTT	Tendinopathy	
No tear	7	0	0	3	10
PTT	0	7	1	1	9
FTT	0	1	13	0	14
Tendinopathy	1	2	1	3	7
Total	8	10	15	7	40

MRI: Magnetic resonance imaging, USG: Ultrasonography, FTT: Full-thickness tear, PTT: Partial-thickness tear

Table 10: Total number of rotator cuff lesions obtained on ultrasound and magnetic resonance imaging

USG	MRI		Total
	No tear	Tears/tendinopathy	
No tear	7 (TN)	3 (FN)	10
Tears/tendinopathy	1 (FP)	29 (TP)	30
Total	8	32	40

TP: True positive, TN: True negative, FP: False positive, FN: False negative, MRI: Magnetic resonance imaging, USG: Ultrasonography

When MRI examination was conducted in all these 40 patients, it showed a total of 32 rotator cuff lesions while eight patients were diagnosed as normal. Out of 32 patients diagnosed with rotator cuff pathologies on MRI, 15 showed FTTs while 10 showed PTTs and seven showed tendinopathy.

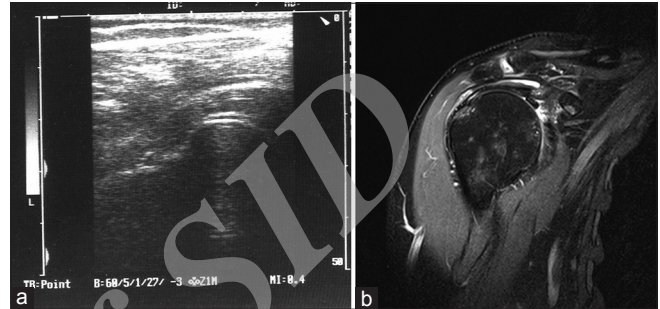


Figure 3: (a) Coronal ultrasound image showing hypoechoic defect of supraspinatus tendon and associated cartilage interface sign representing partial-thickness tear. (b) PD-weighted oblique coronal image showing hyperintense signal involving articular surface of supraspinatus tendon representing partial-thickness tear

On MRI, visualization of altered signal intensity in the tendon extending from the articular to the bursal surface of the tendon was seen in 10 (66.6%) patients and nonvisualization of the rotator cuff tendon was seen in 5 (33.4%) patients, respectively, out of 15 patients having FTTs of the rotator cuff.

Similar results were obtained by Teefey *et al.*, Yamakawa *et al.* (2001), and Farley *et al.* Teefey *et al.* reported that on MRI, signal changes of the rotator cuff tendon were the most reliable criteria in diagnosis of the tear.^[16-18]

Focal area of mildly increased signal intensity on Proton Dense (PD) images which increased in signal intensity on T2-weighted images and extended to one surface only or was seen within the tendon substance itself was seen in 8 out of 10 PTT (75%) patients. These patients were diagnosed as having partial thickness rotator cuff tears. Among these eight patients, four patients showed articular surface tears, three patients showed involvement of the bursal surface, and one patient showed intrasubstance tear. Similar results were found by McMonagle and Vinson, who reported that articular-sided tears are by far the most common, involving the tendon fibers adjacent to the humeral head.^[19] The most common finding of tendinopathy was bulky hyperintense tendon without retraction of fibers seen in five out of seven patients with tendinopathy.

Loss of the peribursal fat plane was seen in 10 patients, and all these patients had rotator cuff tears or tendinopathy. Concave subdeltoid fat contour was noted in 4 (10%) patients, which is

Table 11: Statistical evaluation for ultrasound diagnosis of rotator cuff pathologies

Parameter	Equation	Calculation	Result (%)
Sensitivity	$TP/TP + FN \times 100$	$29/29+3 \times 100$	90.6
Specificity	$TN/TN + FP \times 100$	$7/7+1 \times 100$	87.5
Positive predictive value	$TP/TP + FP \times 100$	$29/29+1 \times 100$	96.6
Negative predictive value	$TN/TN + FN \times 100$	$7/7+3 \times 100$	70
Accuracy	$TP + TN/TP + TN + FP + FN \times 100$	$29+7/40 \times 100$	90

TP: True positive, TN: True negative, FP: False positive, FN: False negative

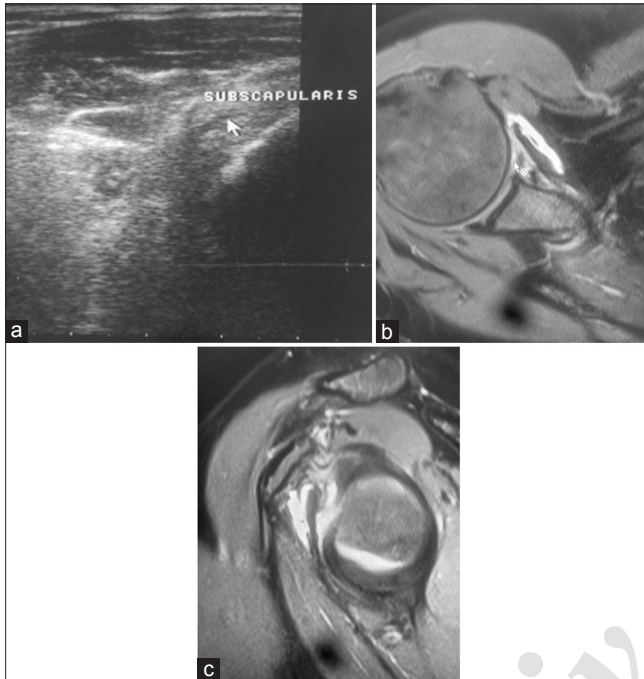

Figure 4: (a) Longitudinal ultrasound image showing hypoechoic defect in subscapularis tendon suggesting partial tear. (b and c) Axial and oblique sagittal PD-weighted images showing hyperintense signal involving subscapularis tendon representing partial tear

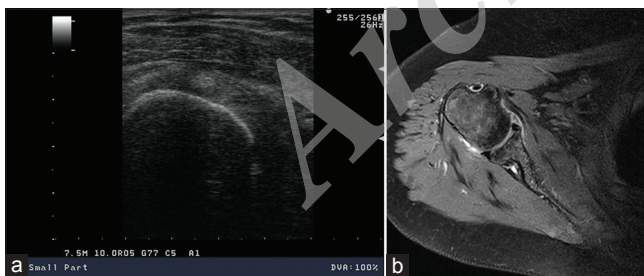


Figure 6: (a) Short-axis ultrasound image showing normal biceps tendon. (b) PD-weighted axial image showing normal biceps tendon

due to herniation of the overlying muscle through the medium and large tears.

In 26 (65%) cases, biceps tendon sheath effusion was seen on USG examination, while on MRI, 27 (67.5%) cases of biceps tendon sheath effusion were seen. Thus, USG and MRI showed a high agreement for the detection of tendon sheath effusion. Similar results were reported by Alasaarela *et al.*, who reported

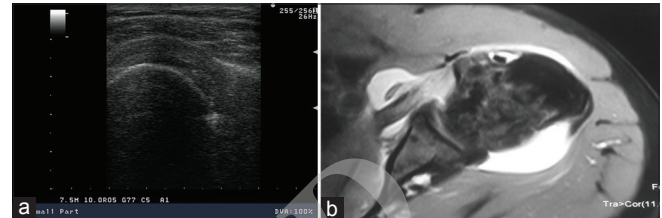


Figure 5: (a) Short-axis ultrasound image showing bulky heterogeneous subscapularis tendon suggestive of tendinitis. (b) Axial PD-weighted image showing hyperintense signal involving subscapularis tendon with associated distended subscapularis bursa representing tendinitis

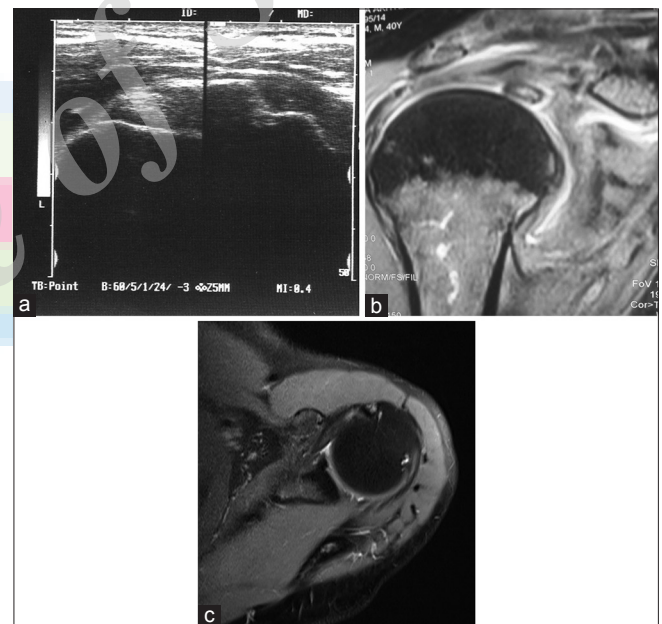


Figure 7: (a) Short-axis ultrasound image showing bulky hypoechoic biceps tendon suggesting tendinopathy. (b and c) Coronal T2-weighted and axial PD-weighted image showing hyperintense signal involving biceps tendon representing tendinopathy

effusion of the biceps tendon sheath in 24 shoulders by MRI and in 20 by US and concluded a good agreement between USG and MRI for the detection of effusion of the biceps tendon sheath.^[20]

Nonvisualization of the biceps tendon on the bicipital groove indicates either rupture or subluxation of the tendon. In our study of 40 patients, 2 (5%) patients demonstrated nonvisualized biceps tendon in the intertubercular sulcus. Out of these two patients, one patient demonstrated rupture of the

biceps tendon and one patient had biceps tendon dislocation both on USG and MRI.

Teefey *et al.* reported that biceps tendon abnormalities frequently are associated with rotator cuff tear.^[21] They reported a prevalence of dislocation of the biceps tendon was 6%, which correlates with the findings in our study

On USG, biceps tendinopathy was seen in two patients, whereas MRI showed three cases of biceps tendinopathy.

Out of 30 patients with rotator cuff lesions on USG, 14 patients showed FTTs and one patient with MRI-proven PTT was falsely diagnosed as having FTT. US also showed nine PTTs and one patient with MRI-proven FTT and tendinopathy each was falsely diagnosed as PTT. Out of seven patients with tendinopathy, one was normal and two had PTT on MRI. In total, US detected 29 true-positive rotator cuff lesions, three false negatives, and one false positive, while 7 patients were diagnosed as normal (true negative).

When MRI was conducted on these patients, 32 patients had rotator cuff lesions while eight patients showed no tears and were diagnosed as normal. Out of 32 patients with lesions, 15 patients showed FTTs, 10 had PTTs, and seven had tendinopathy.

The agreement between the two methods was assessed using kappa coefficient ($\kappa = 0.714$). The strength of agreement between USG and MRI for the diagnosis of rotator cuff pathologies is good as per the calculated kappa coefficient. Similar results were obtained by Rutten *et al.*^[12]

Statistical evaluation of USG for the detection of rotator cuff tears and tendinopathy compared with MRI was done. Sensitivity, specificity, and PPV and NPV were calculated according to formulae.

US had high sensitivity, specificity, PPV and NPV, and accuracy.

This study has revealed several important clinical implications. First, US is a cheap, easily available, and time-saving alternative to MRI for diagnosing suspected rotator cuff pathologies. Second, patients with prosthesis, implants, and claustrophobic patients which are the limitations of MRI can be benefited by US. The accuracy of US in experienced hands was found to be as good as that of MRI.^[22] The MRI has shorter learning curve; it should be used secondarily and in selective cases because it provides more information about extent of tendons and has lower risk of artifacts. Due to the cost difference between the two procedures, our study clearly shows that US is more cost-effective test to use for identification of rotator cuff tears and tendinopathy. Radiology department should have experienced musculoskeletal radiologists, high-frequency probes, and equipment so that accurate and cost-effective diagnosis can be made. Our study showed that US is accurate in diagnosing rotator cuff pathologies which is in favorable comparison with Kenn *et al.* and Łach *et al.*, who proved US to be accurate and reliable in diagnosing a wide range of shoulder disorders compared with MRI.^[23,24]

There are several advantages of USG over MRI. US is easily available, cheaper, and portable, has better patient compliance, and is less time-consuming. US is not subject to motion artifacts, it allows instant comparison with the contralateral side, and tendons and other structures can be evaluated dynamically. The real-time capacity of USG facilitates interventional procedures in or around the shoulder and allows better interaction with a patient who can point at the symptomatic area, which will optimize diagnostic yield. However, sonography of the shoulder joint is highly operator dependent. Small errors in transducer orientation and angulation may easily obscure small abnormalities within and around the cuff and give rise to false-positive and false-negative results.^[25] There is a steep learning curve for shoulder sonography. However, these potential pitfalls can be avoided by thoroughly understanding the normal anatomy, strictly insisting on proper transducer and patient position and using opposite shoulder for comparison. This can make sonography an effective, reliable, and noninvasive means of detecting rotator cuff tears and tendinopathies.

A number of international studies have compared USG with arthrography, MRI, and arthroscopic findings and have proved US to be an effective, comparable diagnostic tool.

CONCLUSION

High-resolution USG is an excellent modality for evaluation of rotator cuff pathologies owing to:

- Affordability
- Noninvasiveness
- Wide availability
- Excellent patient compliance
- Option of bedside evaluation
- Option to examine contralateral shoulder for comparison
- Rapidity of investigation.

The present study was based on high-resolution USG evaluation of rotator cuff pathologies and correlation of the findings with MRI was done in each case. USG and MRI are comparable modalities for the evaluation of rotator cuff pathologies. Evaluation of contralateral shoulder with USG should always be done for comparison.

Financial support and sponsorship

Nil.

Conflicts of interest

There are no conflicts of interest.

REFERENCES

1. Haaga JR, Dogra VS, Forsting M, Gilkeson RC, Kwon Ha H, Sundaram M. CT and MRI of Whole Body. 5th ed. St Louis: Mosby, Elsevier; 2009. p. 2159-60.
2. Yamamoto A, Takagishi K, Osawa T, Yanagawa T, Nakajima D, Shitara H, *et al.* Prevalence and risk factors of a rotator cuff tear in the general population. *J Shoulder Elbow Surg* 2010;19:116-20.
3. Oh JH, Kim JY, Lee HK, Choi JA. Classification and clinical significance of acromial spur in rotator cuff tear: Heel-type spur and rotator cuff tear. *Clin Orthop Relat Res* 2010;468:1542-50.

4. Mikolyzk DK, Wei AS, Tonino P, Marra G, Williams DA, Himes RD, *et al.* Effect of corticosteroids on the biomechanical strength of rat rotator cuff tendon. *J Bone Joint Surg Am* 2009;91:1172-80.
5. McNally GE. *Practical Musculoskeletal Ultrasound*. China: Elsevier Limited; 2005.
6. Dinnes J, Loveman E, McIntyre L, Waugh N. The effectiveness of diagnostic tests for the assessment of shoulder pain due to soft tissue disorders: A systematic review. *Health Technol Assess* 2003;7:iii, 1-166.
7. Seibold CJ, Mallisee TA, Erickson SJ, Boynton MD, Raasch WG, Timins ME, *et al.* Rotator cuff: Evaluation with US and MR imaging. *Radiographics* 1999;19:685-705.
8. Steinbach LS, Gunther SB. Magnetic resonance imaging of the rotator cuff. *Semin Roentgenol* 2000;35:200-16.
9. de Jesus JO, Parker L, Frangos AJ, Nazarian LN. Accuracy of MRI, MR arthrography, and ultrasound in the diagnosis of rotator cuff tears: A meta-analysis. *AJR Am J Roentgenol* 2009;192:1701-7.
10. Milgrom C, Schaffler M, Gilbert S, van Holsbeeck M. Rotator-cuff changes in asymptomatic adults. The effect of age, hand dominance and gender. *J Bone Joint Surg Br* 1995;77:296-8.
11. Moosmayer S, Tariq R, Stiris MG, Smith HJ. MRI of symptomatic and asymptomatic full-thickness rotator cuff tears. A comparison of findings in 100 subjects. *Acta Orthop* 2010;81:361-6.
12. Rutten MJ, Spaargaren GJ, van Loon T, de Waal Malefijt MC, Kiemeny LA, Jager GJ, *et al.* Detection of rotator cuff tears: The value of MRI following ultrasound. *Eur Radiol* 2010;20:450-7.
13. Rutten MJ, Jager GJ, Blickman JG. From the RSNA refresher courses: US of the rotator cuff: Pitfalls, limitations, and artifacts. *Radiographics* 2006;26:589-604.
14. Churchill RS, Fehringer EV, Dubinsky TJ, Matsen FA 3rd. Rotator cuff ultrasonography: Diagnostic capabilities. *J Am Acad Orthop Surg* 2004;12:6-11.
15. Beall DP, Williamson EE, Ly JQ, Adkins MC, Emery RL, Jones TP, *et al.* Association of biceps tendon tears with rotator cuff abnormalities: Degree of correlation with tears of the anterior and superior portions of the rotator cuff. *AJR Am J Roentgenol* 2003;180:633-9.
16. Teefey SA, Rubin DA, Middleton WD, Hildebolt CF, Leibold RA, Yamaguchi K, *et al.* Detection and quantification of rotator cuff tears. Comparison of ultrasonographic, magnetic resonance imaging, and arthroscopic findings in seventy-one consecutive cases. *J Bone Joint Surg Am* 2004;86-A:708-16.
17. Yamakawa S, Hashizume H, Ichikawa N, Itadera E, Inoue H. Comparative studies of MRI and operative findings in rotator cuff tear. *Acta Med Okayama* 2001;55:261-8.
18. Farley TE, Neumann CH, Steinbach LS, Jahnke AJ, Petersen SS. Full-thickness tears of the rotator cuff of the shoulder: Diagnosis with MR imaging. *AJR Am J Roentgenol* 1992;158:347-51.
19. McMonagle JS, Vinson EN. MRI of the shoulder: Rotator cuff. *Appl Radiol* 2012;41:20-7.
20. Alasaarela E, Takalo R, Tervonen O, Hakala M, Suramo I. Sonography and MRI in the evaluation of painful arthritic shoulder. *Br J Rheumatol* 1997;36:996-1000.
21. Teefey SA, Hasan SA, Middleton WD, Patel M, Wright RW, Yamaguchi K, *et al.* Ultrasonography of the rotator cuff. A comparison of ultrasonographic and arthroscopic findings in one hundred consecutive cases. *J Bone Joint Surg Am* 2000;82:498-504.
22. Zlatkin MB, Hoffman C, Shellock FG. Assessment of the rotator cuff and glenoid labrum using an extremity MR system: MR results compared to surgical findings from a multi-center study. *J Magn Reson Imaging* 2004;19:623-31.
23. Kenn W, Hufnagel P, Müller T, Gohlke F, Böhm D, Kellner M, *et al.* Arthrography, ultrasound and MRI in rotator cuff lesions: A comparison of methods in partial lesions and small complete ruptures. *Rofu* 2000;172:260-6.
24. Łach W, Dudarenko G, Brzosko M, Cyryłowski L, Fliciński J. Usefulness of ultrasonographic and MR imaging in diagnosis of shoulder impairment. *Chir Narzadow Ruchu Ortop Pol* 2003;68:307-11.
25. Middleton WD, Reinus WR, Totty WG, Melson CL, Murphy WA. Ultrasonographic evaluation of the rotator cuff and biceps tendon. *J Bone Joint Surg Am* 1986;68:440-50.