

A Comparative Analysis of the Findings of Postmortem Computed Tomography Scan and Traditional Autopsy in Traumatic Deaths: Is Technology Mutually Complementing or Exclusive?

Biplab Mishra, Mohit Kumar Joshi, Sanjeev Lalwani¹, Atin Kumar², Adarsh Kumar¹, Subodh Kumar, Amit Gupta, Sushma Sagar, Maneesh Singhal, Ananya Panda², Amulya Rattan

Departments of Surgical Disciplines and ¹Forensic Medicine and Toxicology, JPN Apex Trauma Center, ²Department of Radiodiagnosis, JPN Apex Trauma Center, All India Institute of Medical Sciences, New Delhi, India

Abstract

Background: Postmortem examination is indispensable to ascertain the cause of an unnatural death and as such is mandatory by the law. From ages, traditional autopsy (TA) has proved its worth in establishing the cause of death in the deceased despite some inherent difficulties and challenges and has enjoyed an insurmountable status. The increasing use of application of the modern-day radiology for postmortem examination has however opened a new arena overcoming some of the difficulties of the TA. There are conflicting reports in the published literature regarding superiority of one modality of the postmortem over the other. **Objective:** The objective of this study was to compare the findings of postmortem computed tomography (CT) scan and TA in the victims of traumatic deaths and to analyze whether postmortem CT can be used to replace TA. **Materials and Methods:** All patients with a history of trauma that were declared brought dead on arrival in the emergency department were subjected to full-body CT scan. An experienced radiologist reported the findings of CT scan. Subsequently, a forensic expert subjected the patients to TA. The physician who performed autopsy was blinded to the findings of CT scan and vice versa. An individual who was not part of the radiology or forensic team then entered the findings of CT scan and autopsy in a predesigned Pro forma. An unbiased assessor finally compared the findings of the two modalities and analyzed the results. McNemar's test was used to ascertain the level of significance between the findings reported by these two modalities considering $P = 0.05$ as statistically significant. The agreement or disagreement on cause of death reported by these two modalities was also assessed. **Results:** About 95% of the deceased were males. The mean age of the corpses was 35 years (range 16–67 years). CT was found superior in picking up most of the bony injuries, air-containing lesions, hemothorax, and hemoperitoneum. However, autopsy was found more sensitive for soft-tissue and solid visceral injuries. Both modalities were equally helpful in identifying extremity fractures. Statistically significant agreement (>95%) on cause of death by both modalities was not achieved in any patient of trauma. **Conclusion:** Postmortem CT scan is promising in reporting injuries in traumatic deaths and can significantly complement the conventional autopsy. However, at present, it cannot be considered as a replacement for TA.

Keywords: Autopsy, postmortem computerized tomographic, postmortem examination, postmortem computed tomography scan, virtual autopsy

INTRODUCTION

The value of traditional autopsy (TA) in the victims of unnatural deaths is paramount. Not only it sheds light on the possible cause and circumstances of death but it is also mandatory by the law. There are some intrinsic difficulties and challenges in conducting a conventional autopsy that has been observed and reported from time to time. The first and

Address for correspondence: Dr. Mohit Kumar Joshi, Room-5014 C, Fifth Floor, Teaching Block, All India Institute of Medical Sciences, New Delhi - 110 029, India.
E-mail: drmohitjoshi@gmail.com

This is an open access journal, and articles are distributed under the terms of the Creative Commons Attribution-NonCommercial-ShareAlike 4.0 License, which allows others to remix, tweak, and build upon the work non-commercially, as long as appropriate credit is given and the new creations are licensed under the identical terms.

For reprints contact: reprints@medknow.com

How to cite this article: Mishra B, Joshi MK, Lalwani S, Kumar A, Kumar A, Kumar S, *et al.* A comparative analysis of the findings of postmortem computed tomography scan and traditional autopsy in traumatic deaths: Is technology mutually complementing or exclusive?. Arch Trauma Res 2018;7:24-9.

Access this article online

Quick Response Code:



Website:
www.archtrauma.com

DOI:
10.4103/atr.atr_55_17

foremost is its extensive invasiveness leading to substantial disfigurement of the body.^[1] This is such a big concern that many family members request for waving off the postmortem examination of their deceased loved ones which at times is granted by the competent authorities respecting the emotions involved. However, there always remains a chance of misuse of this humanitarian act.

Other concerns include the exposure of bodily contaminants of the corpse and the risk of transmission of infection to the health-care workers. It also entails substantial time and workforce and can be conducted only in limited hours during the daytime as mandated by the law.^[2] There can be subjectivity in the assessment of the findings among different examiners. The procedure is not reproducible as once violated, the subsequent examination on the same body that may be required in disputed cases becomes difficult.^[1]

Some of these limitations can be offset by the use of postmortem computerized tomographic scan (PMCT) also known as virtual autopsy or virtopsy. Wüllenweber *et al.* first reported the use of computed tomography (CT) scan for forensic inquest in the year 1977 in patients with cranial gunshot wounds.^[3] Krantz pioneered the use of CT scan in the deceased in the year 1983 and since then with the ever-improving technology in diagnostic radiology, postmortem imaging has increasingly being used.^[4] The biggest attraction is its noninvasive nature. The examination can be conducted at any time with little workforce, and the images can be stored for subsequent examination and record purposes. In addition, the risk of transmission of infection is greatly minimized. Despite these advantages, the PMCT is still not considered the criterion standard for the postmortem examination.^[1,5]

We conducted this study to compare the findings of TA and PMCT to evaluate the advantages of one technique over the other and to ascertain whether PMCT can replace TA. While the use of postmortem imaging is not new to the Western world, this is the first study of its kind from the Indian subcontinent.

MATERIALS AND METHODS

This study was conducted at a Level-I trauma Center over a period of 5 years from 2010 to 2015 after obtaining clearance from the Institutional Ethics Committee. Seventy-seven patients of trauma that were declared brought dead at arrival to the emergency department (ED) were included in the study. After certification of death, the bodies were sealed in an impervious body bag and were subjected to CT scan.

An experienced radiologist performed CT scans. Multislice 40-detector scanner somatom (Siemens, Erlangen, Germany) was used. The bodies were kept in a supine position on CT gantry and scanned from vertex to mid-tibia level. Whole-body scans were performed with tube potential of 120 kVp, tube current time product of 100 mAs, collimation of 1.5×40 , and pitch of 1.2. With these parameters, 1.5-mm section thickness was obtained. Radiation dose was not an issue and these

parameters were maintained for all scans for uniformity and optimum image quality for interpretation. The images were viewed on the syngo. via (Siemens AG, Erlangen, Germany) workstation and were also reformatted in sagittal and coronal planes. An experienced radiologist interpreted the results of the CT scan and stated the findings for (1) head, neck, and cervical spine (2) thorax including thoracic spine (3) abdomen and pelvis including lumbar and sacral spine, and (4) extremities. Based on the findings, probable cause of death was also stated. An independent assessor recorded these findings in a predesigned Pro forma. Subsequently, an experienced forensic expert who was blinded to the findings of CT scan performed TA. The same independent assessor then recorded the findings of TA in the Pro forma.

The findings of PMCT and TA were then compared with respect to the various body regions and specific injuries in the area of the head and neck, chest, abdomen, pelvis, spine, and extremities. The evaluation included the analysis of soft tissues, bony structures, presence of fluid, and gases in the body cavities as well as pathological spaces. We compared the frequency of concurrence or conflict of injured structures reported by the two modalities. In addition, the findings reported by only one of the two modalities were also recorded. McNemar's test was used to test the level of significance. A value of $P = 0.05$ was considered statistically significant. Agreement or disagreement in the cause of death mentioned by TA and PMCT was calculated in percentage. An agreement of $>95\%$ in the cause of death mentioned by the two modalities was considered significant.

RESULTS

There were 73 males (94.8%). Road traffic injuries were the most common cause of death (85%). Other causes of death are presented in Figure 1. The mean age of the corpses was 35 years (range 16–67 years). The mean time of death to arrival in ED was approximately 3 h (30 min–5.5 h); however, in nine patients, the exact time of death was not available. The mean time from the declaration of death to PMCT and declaration of death to TA was 28 min (15 min–1.2 h) and 11.3 h (4 h–5 days), respectively.

Findings in head, neck and cervical spine

The findings are presented in Table 1. Of 41 fractures of skull and facial bones, PMCT detected injuries in all correctly, while TA failed to detect them in 18 victims. It was equally sensitive in detecting intracerebral bleed except for subarachnoid hemorrhage (SAH) that was picked up better by TA. TA was also found better in detecting the soft-tissue injuries in this region. Air-containing lesions such as pneumocephalus and vascular emboli were reported only by CT scan.

Thorax and thoracic spine

Although PMCT picked more rib fractures, the result did not achieve statistical significance. Scapular and thoracic spine fractures were detected only by PMCT. Similarly, air-containing lesions such as subcutaneous emphysema,

pneumothorax, and pneumomediastinum were picked up only on PMCT. PMCT was also found significantly better in picking up hemothorax, however, both modalities were found equally sensitive in detecting pulmonary contusions [Table 2].

Abdomen, pelvis, lumbar and sacral spine

PMCT fared poor in detecting solid visceral injuries. The result was marked for liver injury where PMCT could not pick even a single injury while, although TA was better in detecting splenic and renal injuries, the difference was not

statistically significant. Spinal injuries were reported only on PMCT. PMCT also identified significantly more number of hemoperitoneum, however, both modalities were found equally sensitive in detecting pelvic fractures [Table 3].

Extremities

PMCT was found equivalent to TA for detecting fractures in extremities; however, it could not pick soft-tissue injuries such as bruises, abrasions, lacerations, incised, stab, and gunshot wounds [Table 4].

Nontraumatic causes

In four patients, no traumatic cause of death could be identified.

DISCUSSION

The use of imaging in examination of trauma victims is not new. The use of X-rays in forensic pathology dates back more than a 100 years, and essentially, a year after their discovery.^[6] The use of cross-sectional imaging in examination of corpses have opened a new arena in the arsenal of medicolegal investigations. In the past decade, there has been a surge in the use of cross-sectional imaging (CT and magnetic resonance imaging [MRI]) as an adjunct to the conventional postmortem examination. This interest may primarily be due

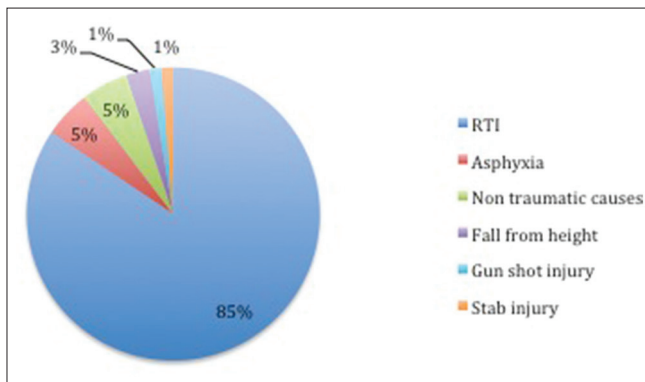


Figure 1: Injury mechanism

Table 1: Findings in head, neck, and cervical spine

Injuries (n)	Autopsy		PMCT		P	Corrected classification
	Picked	Missed	Picked	Missed		
Scalp hematoma (18)	17	1	2	16	0.002	5.56
Skull fracture (26)	20	6	26	0	0.040	76.9
Base of skull fracture (4)	1	3	4	0	0.240	25
Facial fracture (11)	2	9	11	0	0.007	18.18
EDH (1)	0	1	1	0	0.99	0
SDH (18)	12	6	10	8	0.288	22.22
SAH (13)	13	0	2	11	0.002	15.38
Contusion (3)	2	1	2	1	0.99	33.33
Brain edema (2)	2	0	2	0	0.99	100
Cervical spine fracture (3)	0	3	3	0	0.08	0

EDH: Epidural hemorrhage, SDH: Subdural hemorrhage, SAH: Subarachnoid hemorrhage, PMCT: Postmortem computerized tomographic

Table 2: Findings in thorax and thoracic spine

Injuries (n)	Autopsy		PMCT		P	Corrected classification
	Picked	Missed	Picked	Missed		
Rib fractures (24)	17	7	20	4	0.080	54.16
Scapular fracture (8)	0	8	8	0	0.004	0
Hemothorax (20)	13	7	18	2	0.025	61.11
Pulmonary contusion (6)	2	4	4	2	0.157	0
Pneumothorax (15)	0	15	15	0	0.001	0
Subcutaneous emphysema (11)	0	11	11	0	0.001	0
Pneumomediastinum (4)	0	4	4	0	0.001	0
Lung laceration (3)	1	2	2	1	0.310	0
Diaphragmatic injury (1)	0	1	1	0	0.310	0
Spinal fracture (6)	0	6	6	0	0.014	0

PMCT: Postmortem computerized tomographic

Table 3: Findings in abdomen

Injuries (n)	Autopsy		PMCT		P	Corrected classification
	Picked	Missed	Picked	Missed		
Hemoperitoneum (20)	15	5	11	9	0.040	30
Liver injury (10)	10	0	0	10	0.001	0
Splenic injury (5)	4	1	2	3	0.157	20
Renal injury (3)	3	0	1	2	0.150	33.34
Retroperitoneal hematoma (4)	3	1	1	3	0.150	0
Pelvic injury (8)	3	5	6	2	0.080	12.5
Pneumoperitoneum (3)	0	3	3	0	0.08	0
Stomach injury (2)	2	0	0	2	0.15	0

PMCT: Postmortem computerized tomographic

Table 4: Findings in soft tissues and extremities

Injuries (n)	Autopsy		PMCT		P	Corrected classification
	Picked	Missed	Picked	Missed		
Soft-tissue injuries (46)	46	0	0	46	0.001	0
Fracture of long bones (15)	12	3	12	3	0.68	60

PMCT: Postmortem computerized tomographic

Table 5: Agreement and disagreement on cause of death

Cause of death (n)	Agreement	Disagreement	Percentage agreement
Hemorrhagic shock (12)	4	8	33
Tension pneumothorax (2)	0	2	0
Head injury (21)	14	7	67
Cardiopulmonary injuries (8)	6	2	75
Polytrauma (3)	2	1	67
Asphyxia (4)	2	2	50
Nontraumatic cause (4)	4	0	100

to increased awareness and appreciation of usefulness of this tool for such examination. Technological improvement and wider availability of these modalities have also significantly contributed toward this rekindled interest. Most of the studies have used CT scan to compare their findings with the TA, however, the number of patients studied are less (ranging from 3 to 47) with only few series having >50 patients.^[1]

Majority of the patients in our study were males (95%), this is understandable as trauma is more common in them. In some of our patients, the time of death was not exactly known as they were found on roadside and were transported to our center by police; however, we included only those patients where the estimated time of death was <6 h. This is important as hypostatic and putrefactive changes starts as early as 4–6 h and increase with time that may significantly increase chances of artifacts and also hamper the interpretation of the CT images.^[7] Makhoulouf *et al.* in their study could perform PMCT in only 51 of 78 patients due primarily to putrefaction and organizational difficulty.^[8]

We found PMCT better in picking up air-containing lesions such as pneumocephalus, cerebral and venous gas embolism, subcutaneous emphysema, pneumothorax,

pneumomediastinum, and pneumoperitoneum. Other authors have also reported the same.^[8-10] TA misses these lesions unless special autopsy techniques such as opening the body under water or the use of a spirometers is employed that is cumbersome. With the use of PMCT, these special techniques of autopsy may not be required.

Intracranial injuries such as subdural hemorrhage, cerebral contusion, and brain edema were equally picked up well by both modalities in the present study. This has been the observation of other authors too.^[11,12] We found PMCT disappointing in detecting SAH, although other authors have reported both modalities to be equally sensitive in identifying SAH,^[8,11,12] the difference in our study was marked. The reason may be that in most of our patients the SAH was small. This thin rim of blood having the same appearance as that of the surrounding unenhanced brain parenchyma in the deceased may be missed on imaging. Hemorrhagic lesions in thorax such as hemothorax and pulmonary contusion were picked up better on PMCT, the difference however was not significant for pulmonary contusion. TA may miss small amount of hemothorax, which is well picked up on CT scan. This has been the observation of other authors too.^[8,9]

PMCT was found invaluable in detecting most osseous injuries, especially in the areas, where finding a fracture would require painful dissection such as craniofacial region, spine, scapula, and pelvis on autopsy. In the present study, PMCT detected craniofacial fractures in all 41 patients (100%) while TA identified them in only 56%. This was similar to the experience by Moskala *et al.*, Daly *et al.*, and Leth *et al.*^[10,11,13] The reason of increased identification of craniofacial fractures may be due to the fact that undisplaced fractures at these sites are unlikely to be explored during autopsy. PMCT detected more rib and pelvic fractures, however, the difference was not statistically significant.

In identifying extremity fractures, both modalities were found equally sensitive similar to the experience of others.^[11,13]

PMCT was found inferior in detecting the solid visceral injuries as compared to TA. Liver injuries were missed in all our patients by PMCT ($P = 0.001$). For splenic and renal injury, too PMCT fared poor than TA. Other authors also share similar findings in their study.^[5,8,9,11,14] In life, CT is considered much sensitive in detecting and characterizing even minor grades of solid abdominal viscera as the investigation is supplemented with intravenous contrast. This is not possible after death resulting in poor visualization of these injuries. To offset this inherent shortcoming of PMCT, many researchers are now finding ways to supplement intravenous contrast medium in corpses for improved visualization.^[15-17]

On reviewing the findings of autopsy, we found that in most of our patients the liver injury was minor in the form of hematoma and superficial lacerations. This may be the reason for poor identification of these injuries in the present study. Abu Bakar has reported the sensitivity of PMCT to be 71% for liver injuries, although they have not mentioned the severity or grade of these injuries on autopsy findings.^[5] We believe that the rate of identification of solid visceral injuries would improve with increased severity of injury. This has been reported by other authors too that the agreement between imaging and autopsy findings improve with increasing injury severity score.^[9,11,13]

TA far outweighed PMCT in detecting and characterizing soft-tissue injuries. This has been observed consistently by others.^[11,18] The injuries such as bruises, abrasions, sharp wounds, and superficial lacerations that are vital from medicolegal point of view can be entirely missed on CT scan. Although the shortcoming of PMCT in picking up intraabdominal solid visceral injuries can be offset to some extent by using angiography, the issue of picking these important superficial injuries by CT still remains at large. MRI has been reported to have a higher sensitivity in picking up soft-tissue injuries in deceased,^[19] but it needs to be pondered whether such specialized, costly, and relatively unavailable investigation is really needed for this purpose when the naked eye examination by a forensic expert can easily pick them up?

We observed some other inherent strength and weaknesses of these modalities. CT reported injuries such as hemoperitoneum and subcutaneous emphysema that could not be picked up on autopsy. Although these injuries are not significant to cause death by themselves, considering the mechanism and other corroborative findings on imaging, this may help in establishing the cause of death. On the other hand, an important medicolegal issue of 'time since death' that can be reasonably estimated on autopsy based on characterization of soft-tissue injuries and amount and status of food residue in stomach and intestine is difficult to evaluate on PMCT. Some of the incidental findings such as fatty liver, visceral granulomas, mediastinal lymphadenopathy, features suggestive of cystitis, renal stones, and insignificant vascular atherosclerosis were reported often on imaging distracted in analysis.

The agreement between the causes of death by two modalities could not achieve the level of statistical significance in any patient of trauma [Table 5]. In ten patients, either of the two modalities could not ascertain definitive cause of death. The difference in agreement was marked for intraabdominal hemorrhage (67%). This may be due to the poor sensitivity of PMCT in detecting solid visceral injury and hemoperitoneum. In three of our patients, moderate hemoperitoneum was missed on PMCT. In one patient with cardiogenic shock (stab injury to heart), although PMCT picked up moderate hemothorax, the cardiac injury was missed resulting in the difference of opinion. In another patient, the opinion on cause of the death was reserved on autopsy for chemical analysis as no convincing cause could be ascertained, however, the PMCT findings suggested a possibility of lung injury in this case. In a substantial majority of the patients, although the final cause of death was different on PMCT and TA, the combination of injuries mentioned by either modalities were sufficient enough to cause of death. Interestingly, the agreement was 100% for four patients with suspected nontraumatic death. In three of them, the cause of death was considered as myocardial infarction as both modalities could detect significant abnormality with the cardiac chambers and the coronary arteries. In one of these patients, no cause of death could be ascertained by either modality, there were no signs of trauma as well.

The strength of our study is its large sample size. This is one of the largest series reported till date and the first study of its kind from the Indian subcontinent. The other positive facet is its blinding. The radiologist, forensic pathologist, the person who recorded these findings in the Pro forma and the one who analyzed the results were all blinded to each other. This would certainly have eliminated the possibility of recording and observation bias.

We observed some limitations in the present study as well. At times, the injuries were not mentioned at all by one of the two modalities. This can be improved by having a standard recording sheet where all the injuries are mentioned region wise and the physician is expected to record them as either present or absent, further describing the injuries wherever they are present. Another shortcoming was a failure of PMCT to detect certain injuries that it is expected to pick. Filograna and Abu Bakar have also mentioned this as one of the limitation in their study.^[5,20] Although an experienced radiologist interpreted the images, the appearance of injuries after death is substantially different from that in life. At other times, some specialized signs are present in the corpses, the awareness of which may help the radiologist in identifying these injuries well.^[7] We hope that the radiological reporting may be improved and the incidence of missed injuries may significantly decrease as we gain experience with postmortem imaging.

CONCLUSION

PMCT scan is promising in reporting injuries in traumatic deaths and can significantly complement the findings of

conventional autopsy. However, at present, it cannot be considered as a replacement for TA.

Financial support and sponsorship

Nil.

Conflicts of interest

There are no conflicts of interest.

REFERENCES

1. Jalalzadeh H, Giannakopoulos GF, Berger FH, Fronczek J, van de Goot FR, Reijnders UJ, *et al.* Post-mortem imaging compared with autopsy in trauma victims – A systematic review. *Forensic Sci Int* 2015;257:29-48.
2. Bhullar DS, Gorea RK, Aggarwal AD. Medico-legal autopsy by panel of doctors present scenario. *JIAFM* 2004;26:114-8.
3. Wüllenweber R, Schneider V, Grumme T. A computer-tomographical examination of cranial bullet wounds (author's transl). *Z Rechtsmed* 1977;80:227-46.
4. Krantz P, Holtås S. Postmortem computed tomography in a diving fatality. *J Comput Assist Tomogr* 1983;7:132-4.
5. Norzailin AB, Noor Azman S, Mohd Helme MN, Khairul Anuar Z. The sensitivity, specificity and predictive values of post mortem computed tomography in detecting liver and splenic injury due to road traffic accident. *Med J Malaysia* 2016;71:1-7.
6. Kaplan DA. Imaging the Deceased: Post Mortem Radiology. Available from: <http://www.diagnosticimaging.com/ct/imaging-deceased-post-mortem-radiology>. [Last updated on 2016 Mar 03].
7. Panda A, Kumar A, Gamanagatti S, Mishra B. Virtopsy computed tomography in trauma: Normal postmortem changes and pathologic spectrum of findings. *Curr Probl Diagn Radiol* 2015;44:391-406.
8. Makhoulouf F, Scolan V, Ferretti G, Stahl C, Paysant F. Gunshot fatalities: Correlation between post-mortem multi-slice computed tomography and autopsy findings: A 30-months retrospective study. *Leg Med (Tokyo)* 2013;15:145-8.
9. Leth PM, Struckmann H, Lauritsen J. Interobserver agreement of the injury diagnoses obtained by postmortem computed tomography of traffic fatality victims and a comparison with autopsy results. *Forensic Sci Int* 2013;225:15-9.
10. Moskała A, Woźniak K, Kluza P, Romaszko K, Lopatin O. The importance of post-mortem computed tomography (PMCT) in confrontation with conventional forensic autopsy of victims of motorcycle accidents. *Leg Med (Tokyo)* 2016;18:25-30.
11. Daly B, Abboud S, Ali Z, Sliker C, Fowler D. Comparison of whole-body post mortem 3D CT and autopsy evaluation in accidental blunt force traumatic death using the abbreviated injury scale classification. *Forensic Sci Int* 2013;225:20-6.
12. Jacobsen C, Lynnerup N. Craniocerebral trauma – Congruence between post-mortem computed tomography diagnoses and autopsy results: A 2-year retrospective study. *Forensic Sci Int* 2010;194:9-14.
13. Leth PM, Ibsen M. Abbreviated injury scale scoring in traffic fatalities: Comparison of computerized tomography and autopsy. *J Trauma* 2010;68:1413-6.
14. Levy AD, Harcke HT, Getz JM, Mallak CT. Multidetector computed tomography findings in deaths with severe burns. *Am J Forensic Med Pathol* 2009;30:137-41.
15. Saunders SL, Morgan B, Raj V, Rutty GN. Post-mortem computed tomography angiography: Past, present and future. *Forensic Sci Med Pathol* 2011;7:271-7.
16. Palmiere C, Binaghi S, Doenz F, Bize P, Chevallier C, Mangin P, *et al.* Detection of hemorrhage source: The diagnostic value of post-mortem CT-angiography. *Forensic Sci Int* 2012;222:33-9.
17. Zerlauth JB, Doenz F, Dominguez A, Palmiere C, Uské A, Meuli R, *et al.* Surgical interventions with fatal outcome: Utility of multi-phase postmortem CT angiography. *Forensic Sci Int* 2013;225:32-41.
18. Malli N, Ehammer T, Yen K, Scheurer E. Detection and characterization of traumatic scalp injuries for forensic evaluation using computed tomography. *Int J Legal Med* 2013;127:195-200.
19. Ross S, Ebner L, Flach P, Brodhage R, Bolliger SA, Christe A, *et al.* Postmortem whole-body MRI in traumatic causes of death. *AJR Am J Roentgenol* 2012;199:1186-92.
20. Filograna L, Tartaglione T, Filograna E, Cittadini F, Oliva A, Pascali VL, *et al.* Computed tomography (CT) virtual autopsy and classical autopsy discrepancies: Radiologist's error or a demonstration of post-mortem multi-detector computed tomography (MDCT) limitation? *Forensic Sci Int* 2010;195:e13-7.