

# Humeral Shaft Fractures Treated by Closed Retrograde Intramedullary Kirschner Wire Fixation

H. Lalrinchhana, Chandrashekar Martand Badole, Girish Balasaheb Mote

Department of Orthopaedics, Mahatma Gandhi Institute of Medical Sciences, Wardha, Maharashtra, India

ORCID:

Chandrashekar Martand Badole: <http://orcid.org/0000-0002-4806-7920>

Girish Balasaheb Mote: <http://orcid.org/0000-0003-4375-9722>

## Abstract

**Context:** Flexible intramedullary nails have been reported to provide a stable humeral fixation with satisfactory results in terms of union and complications. In this study, Kirschner wire (K-wire) was used to achieve a closed intramedullary fixation of humeral shaft fractures. **Subjects and Methods:** This study included forty cases of the displaced diaphyseal fracture of the humerus based on inclusion and exclusion criteria. The study was done at Kasturba Hospital, Mahatma Gandhi Institute of Medical Sciences (MGIMS), Sevagram, between the periods January 2003 and November 2006. All the cases were operated after clinical evaluation. The final evaluation of the result was done by Qidwai's clinical and radiological criteria. **Results:** A total of forty cases were available for the study. K-wire of different sizes was used; the average duration of surgery was  $45.3 \pm 7.2$  min. The average time taken for radiological union was  $12.1 \pm 1.9$  weeks. The patients were analyzed by Qidwai's criteria and had excellent result in 30 (83.3%) cases, good in 4 (11.1%) cases, and poor in 2 (5.6%) cases. Three patients were lost to follow-up, and one patient was died due to medical illness. **Conclusion:** Intramedullary K-wire fixation is a satisfactory, safe, simple, minimally invasive technique and cost-effective treatment for humeral shaft fractures. It gives elastic mobility and stability.

**Keywords:** Biological, cost-effective, flexible, humeral shaft fractures, Kirschner wire

## INTRODUCTION

Fractures of the humeral shaft are relatively common injuries and account for approximately 3% of all fractures and represent an incidence of 19/100,000 person-years.<sup>[1]</sup> It has a bimodal age distribution. It is observed in the third decade and mainly in males as a result of high-velocity injuries and a larger case seen in the seventh decade mainly occurring in females, generally resulting from a fall and attributed to osteoporotic bone.<sup>[2]</sup>

Fractures of the humeral diaphysis respond well to nonoperative management. Rigid plate osteosynthesis, the most widely accepted operative method, carries documented disadvantages, including extensive soft-tissue injury, significant blood loss, increased operative time, and risk of intraoperative radial nerve injuries. Fracture location could play an important role in the usefulness of nails as these nails are more effective if their entry portal (antegrade or retrograde technique) is closer to the fracture site. Therefore, antegrade nailing should be

performed for fractures occurring in the proximal half of the humeral diaphysis, whereas retrograde nailing should be preserved for fractures located in the distal half of the humeral diaphysis.<sup>[3]</sup> Hence, the management remains controversial. Infection, neurovascular injury, joint problems, and nonunion are recognized complications of surgical treatment. These complications can be decreased by selecting a surgical treatment that is less invasive and safe. Intramedullary stabilization of humeral shaft fractures avoids these disadvantages, but the nails are not without complications. Compared to antegrade nails, retrograde intramedullary nailing

**Address for correspondence:** Dr. Chandrashekar Martand Badole,  
Department of Orthopaedics, Mahatma Gandhi Institute of Medical  
Sciences, Sevagram, Wardha, Maharashtra, India.  
E-mail: [cmbadole@mgims.ac.in](mailto:cmbadole@mgims.ac.in)

This is an open access journal, and articles are distributed under the terms of the Creative Commons Attribution-NonCommercial-ShareAlike 4.0 License, which allows others to remix, tweak, and build upon the work non-commercially, as long as appropriate credit is given and the new creations are licensed under the identical terms.

**For reprints contact:** [reprints@medknow.com](mailto:reprints@medknow.com)

**How to cite this article:** Lalrinchhana H, Badole CM, Mote GB. Humeral shaft fractures treated by closed retrograde intramedullary Kirschner wire fixation. Arch Trauma Res 2020;9:30-4.

**Received:** 15-11-2018, **Revised:** 01-10-2019,

**Accepted:** 28-01-2020, **Published:** 27-03-2020.

### Access this article online

#### Quick Response Code:



**Website:**  
[www.archtrauma.com](http://www.archtrauma.com)

**DOI:**  
[10.4103/atr.atr\\_83\\_18](https://doi.org/10.4103/atr.atr_83_18)

## Archive of SID

in humerus shaft fractures has the advantage of avoiding an iatrogenic rotator cuff tear. However, locked nails provide good rotational stability, but a potential risk of radial nerve injury remains because of the distal locking screws.<sup>[4]</sup> Hence, this study was planned to evaluate the results of closed reduction and retrograde intramedullary Kirschner wire (K-wire) fixation for displaced diaphyseal fractures of the humerus.

## SUBJECTS AND METHODS

This descriptive cross-sectional study includes forty cases of displaced diaphyseal fractures of the humerus. The age of cases ranging from 14 to 70 years presenting to the Orthopedics Emergency and Outpatient Department of Kasturba Hospital, MGIMS, Sevagram, between the periods January 2003 and November 2006. We included patients based on the following inclusion and exclusion criteria.

### Inclusion criteria

1. All patients with displaced diaphyseal fractures of the shaft of the humerus
2. Closed fractures or up to Gustilo and Anderson Grade II open fractures
3. Adequate neurovascular status of the involved limb
4. No active infection at the entry site of the K-wire
5. Stable hemodynamics and stable general condition.

Operative intervention with retrograde nailing in humerus shaft fractures has the advantage of avoiding an iatrogenic rotator cuff tear and is minimally invasive. The patients selected for K-wire fixation were with the fracture extending from the surgical neck to the distal third of the humerus 5 cm above the junction of the diaphysis and metaphysis on both anteroposterior and lateral radiographs.<sup>[5]</sup>

### Exclusion criteria

1. Active infection at entry site for K-wire
2. Gross comminution of the fracture
3. Open fracture with Grade III Gustilo and Anderson classification.

A detailed history regarding mode of trauma, duration, and nature of injury was taken. A thorough examination of the affected arm was done. Shoulder and elbow joints were assessed for any dislocation or instability. Radiographs of the shoulder with arm with elbow in anteroposterior and lateral views were obtained. The patients were given U-slab with collar and cuff sling. Fractures were classified using (AO) Arbeitsgemeinschaft für Osteosynthesefragen classification. Blood investigation was carried as per preoperative workup requirement. After preoperative evaluation, patients were considered for operative procedure.

### Surgical technique

Under suitable anesthesia, the patient was placed in supine or lateral on unaffected side. Cleaning and draping done with shoulder, arm, and elbow kept completely exposed to surgical field.

### Preparation of Kirschner wire

A standard K-wire of 2–3.5 mm × 30 cm length was bent at an angle of 30°–40° at a point approximately 2 cm from the proximal end. The wire was bent at 90° at the distal end in a direction opposite to the bent tip so that the tip could be rotated in the desired direction. Tips of the K-wire were made blunt to avoid perforation of the cortex.

### Operative technique

A vertical 2–3 cm long split incision in the triceps was used to expose the posterior aspect of the humerus just proximal to the olecranon fossa. A window of 1 cm × 0.5 cm diameter was made on the posterior cortex approximately 2 cm proximal to the olecranon fossa using drill bits. Holes were widened with the bone awl to facilitate oblique entry of the wire. K-wire was loaded on a T-handle chuck and inserted from the window into the medullary canal of the bone with the tip in line with the canal. K-wire was negotiated from distal fracture fragment to proximal fracture fragment under image intensifier. The tip of K-wire was engaged in the humeral head and impacted. The protruding distal end of the wires was cut at 1 cm away from the entry point and bent to avoid proximal migration of the K-wire. A total of 2–4 K-wires were inserted and stacked. The proximal tip of wires was kept divergent into the humeral head to achieve the rotational stability at the fracture site. Impaction of the fracture site was done to avoid distraction at fracture site. Wound was irrigated with saline and closed in layers. These are shown in Figure 1a and b shows a prepared K-wire for insertion.

### Postoperative management and follow-up

Postoperatively, U-slab is applied. Intravenous antibiotics were given. Wrist and finger mobilization exercises were

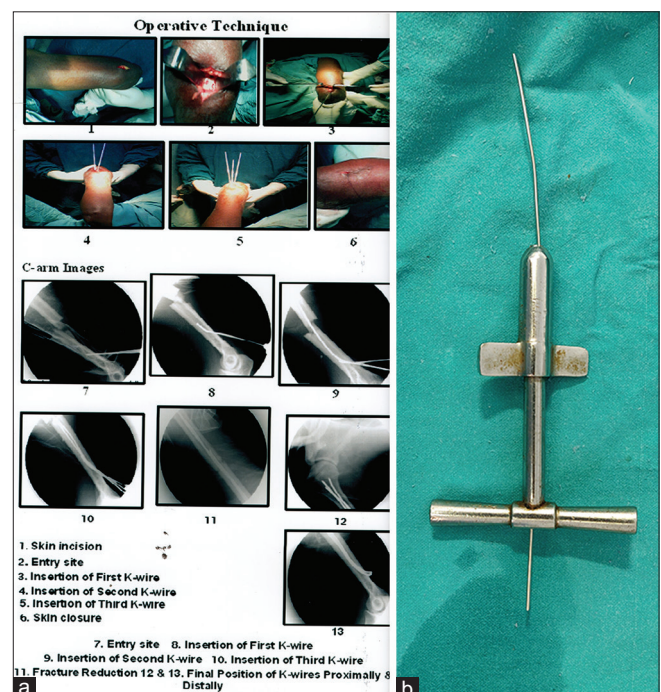


Figure 1: (a) Steps of surgical technique. (b) A prepared Kirschner wire

## Archive of SID

started on the same day of surgery. Patients were called for the first follow-up at the 12<sup>th</sup> day for suture removal. Suture removal was done and U-slab was reapplied. At the end of 2 months again, follow-up was done, the slab was removed, an arm brace was given, and shoulder and elbow mobilizations were started. The final evaluation of the results was done by Qidwai's clinical and radiological criteria<sup>[1]</sup> into excellent, good, and poor outcomes.

## RESULTS

In this study, a total of forty patients were studied, of which 14 patients were considered under the retrospective group and the remaining 26 were in the prospective group. There were 28 (70%) males and the rest were female. The mean age was  $42.1 \pm 11.6$  years, and the maximum number of patients belonged to the age group of 21–40 years. The most common mode of injury was fall in 22 (55%) patients, followed by road traffic accident in ten patients. The left-side humerus was involved in 25 (62.5%) cases and the rest in the right-side humerus.

Thirty-four (80.5%) cases were with closed and the rest were with open fractures. Middle one-third shaft fractures were common in 28 (70%) cases, followed by distal one-third shaft in 8 (20%) cases and then by proximal one-third shaft fractures in 4 (10%) cases. Considering fracture geometry, transverse fracture pattern was common (17, 42.5%). Fracture classified by AO classification and type A3 was a common fracture in 17 (42.5%) cases. Considering anesthesia, brachial block was used in 21 (52.5%) cases, general anesthesia was used in 18 (45%) cases, and axillary block was used in 1 (2.5%) cases. The average period of immobilization in the present study was 10 weeks. Table 1 shows that the number of K-wires was used for fixation of fractures. We mostly used two wires for fixation.

The average duration of hospital stay was  $7.2 \pm 3.4$  days. The average period of immobilization in the present study was 10 weeks. The maximum period of follow-up was 46 months and the minimum was 3 months. The average time for union was  $12.1 \pm 1.9$  weeks. The ranges of motion observed are shown in Table 2. It shows excellent shoulder abduction and elbow flexion range of motion in 32 and 30 cases, respectively.

Out of forty cases of diaphyseal fracture humerus fixed with K-wire, 36 patients were considered for evaluation of end result, three patients have not reported for follow-up, and one patient died 1 month after surgery due to medical illness. We analyzed results at the final follow-up using Qidwai's criteria, as discussed in Table 3 which shows excellent results in thirty cases.

We observed some complications which are mentioned in Table 4. We found that most of the cases had developed skin irritation because of protruded K-wires.

## DISCUSSION

Most of the surgeons believe that intramedullary nailing is the best fixation for femoral and tibial shaft fractures, but there

**Table 1: Number of used Kirschner wires**

Number	Number of cases (%)
Two	29 (72.5)
Three	8 (20)
Four	3 (7.5)
Total	40 (100)

**Table 2: Range of motion**

Grading	Shoulder abduction		Elbow flexion	
	Range of movement	Number of patients	Range of movement	Number of patients
Excellent	>160°	32	>130°	30
Good	150°-160°	2	120°-130°	4
Poor	<150°	2	<120°	2

**Table 3: Functional outcome by Qidwai's score**

Result	Number of cases (%)
Excellent	30 (83.3)
Good	4 (11.1)
Poor	2 (5.6)

**Table 4: Complications observed**

List of complications	Number of cases (%)
Skin irritation by the protruded K-wires and bursa formation	4 (11.1)
Superficial infection	2 (5.6)
Breakage of K-wires	1 (2.8)
Proximal migration of K-wires	1 (2.8)
Distal migration of K-wires	2 (5.6)
Shoulder stiffness	2 (5.6)
Elbow stiffness	2 (5.6)
Nonunion	2 (5.6)

K-wire: Kirschner wire

is no consensus about the ideal procedure for the fracture of humeral shaft in literature. Several series of patients with humeral fractures that were stabilized by various techniques have been reported.<sup>[5-7]</sup> Studies of the intramedullary stabilization of the humeral shaft fracture by Rush rods, Ender nail, and Hackethal nail have also been reported in the literature. Flexible intramedullary nails (Ender nail or Hackethal nail) are reported to provide stable humeral fixation with satisfactory results in terms of union and complications. A diaphyseal displaced fracture is an ideal fracture for closed intramedullary K-wire fixation however, it is possible to fix the fractures of proximal and distal thirds also by this technique. The advantages of this technique are safe, simple, minimally invasive technique, minimal blood loss during surgery, satisfactory axial and rotational stability, low cost and universal availability of the implant, minimal complications, and easy removal of implant.<sup>[4]</sup>



## Archive of SID

The present study comprised forty patients with males being more, i.e., 28 in number. This finding of male predominance correlates with studies of Qidwai<sup>[4]</sup> and Hall and Pankovich.<sup>[8]</sup> The average age in our study is  $42.1 \pm 11.6$  years. Middle thirds of the diaphysis is the most common site of injury, followed by distal third shaft of the humerus. The author is of the opinion that retrograde nailing does not provide mechanically stable fixation in distal third fractures because of the flattening of the distal third medullary canal, and as the portal of entry is close to fracture site, negotiating the K-wire through the medullary cavity becomes difficult. Here, we can use antegrade approach for distal third fractures with entry point outside the rotator cuff, as the same has been suggested in other series as well.<sup>[8,9]</sup> However, in the present study, we have considered distal third fracture of the humerus, extending from the junction of the middle and distal third to 5 cm above distal diaphysis and metaphysis junction on both anteroposterior and lateral radiographs. Out of eight cases of distal third fracture of the humerus, seven had excellent outcome and one case had poor outcome. The poor outcome is because of nonunion due to old age, osteoporotic bone, and noncompliance of the patient for follow-up.

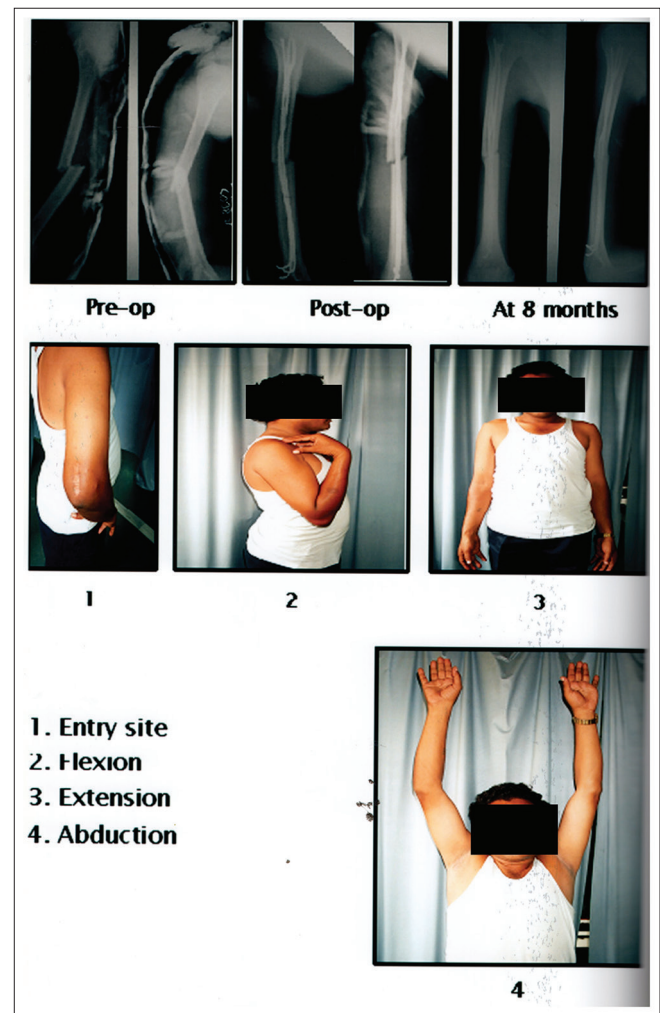
In the present study, entry portal is made through a small incision around 2 cm above olecranon fossa, as followed by other studies.<sup>[4-6,9]</sup> The retrograde approach has advantage that the entry portal does not disturb the olecranon fossa and also does not violate the rotator cuff which is seen with antegrade approach. Problems of shoulder impingement were encountered in a series of 16 patients that were treated by Rush rods.<sup>[10]</sup> In a series of Qidwai, none had a restriction of shoulder movements, whereas four had a restriction of elbow extension less than  $10^\circ$ . In the present study, two had a restriction of shoulder movements and four had a restriction of elbow movements less than  $20^\circ$  due to protruded K-wires with bursa formation.

The average period of immobilization in the present study was 10 weeks. We preferred immobilization for longer period as most of the patients were from low socioeconomic strata, from far-fetched villages, and engaged themselves in heavy labor as soon as the slab was removed. The average radiological union time was  $12.1 \pm 1.9$  weeks, similar to other studies: 11 weeks in Qidwai<sup>[4]</sup> and 13.2 weeks in Stern *et al.*<sup>[6]</sup> The union rate achieved in the present study is 94.4%. This may be attributed to the preservation of tissue and periosteum around the fracture. A similar union rate was also observed in other studies, as given in Table 5.

In our analysis, out of 36 patients who underwent closed intramedullary K-wiring, 30 (83.3%) had excellent results, 4 (11.1%) had good results, and 2 (5.6%) had poor results. The comparison of this study to other studies is shown in Table 6.

Figures 2 and 3 show clinical cases and their follow-up pictures.

The complications observed in this study are very less. Superficial infection was seen in two patients who had Grade II open fracture and were controlled well on oral antibiotics without any need for hospitalization. No patient had radial nerve palsy. In the present study, two patients had developed nonunion, one of which was geriatric, noncompliant female with wide intramedullary cavity and osteoporosis fixed with 4 K-wires and the other was elderly patient having middle third fracture in osteoporotic bone who presented to hospital as late as 21 days following a fracture, who also sustained trauma to operated arm 1 month postoperatively. Both the patients of nonunion were not willing for further management.



**Figure 2:** A clinical case-1 and its follow-up pictures

**Table 5: Comparison of rate of union**

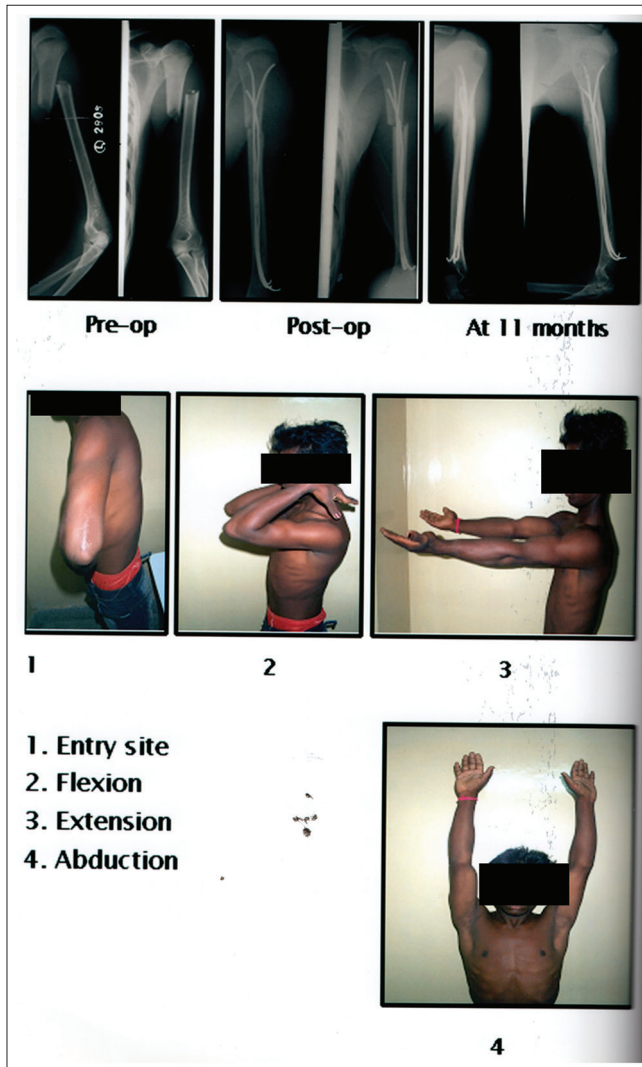
Series	Implant used	Number of cases	Union rate (%)
Present study	K-wire	36	94.4
Qidwai <sup>[4]</sup>	K-wire	29	93
Hall and Pankovich <sup>[8]</sup>	Ender nail	86	98.8
Brumback <i>et al.</i> <sup>[9]</sup>	Rush nail and Ender nail	58	94.8

K-wire: Kirschner wire

**Table 6: Comparison of results**

Series	Type of implant used	Results		
		Excellent (%)	Good (%)	Poor (%)
Present study	K-wire	83.3	11.1	5.6
Qidwai <sup>[4]</sup>	K-wire	86.4	6.8	6.8
Brumback <i>et al.</i> <sup>[9]</sup>	Ender nail and Rush nail	78.3	8.7	13.0

K-wire: Kirschner wire

**Figure 3: Another clinical case-2 and its follow-up pictures**

## Conclusion

Hence, K-wire fixation appears to be a satisfactory method for the treatment of displaced humeral diaphyseal fracture in adults. Furthermore, it is a safe, biological, simple, and minimally invasive technique with a cost-effective, universally available implant.

## Financial support and sponsorship

Nil.

## Conflicts of interest

There are no conflicts of interest.

## REFERENCES

- Huttunen TT, Kannus P, Lepola V, Pihlajamäki H, Mattila VM. Surgical treatment of humeral-shaft fractures: A register-based study in Finland between 1987 and 2009. *Injury* 2012;43:1704-8.
- Tytherleigh-Strong G, Walls N, McQueen MM. The epidemiology of humeral shaft fractures. *J Bone Joint Surg Br* 1998;80:249-53.
- Garnavos C. Diaphyseal humeral fractures and intramedullary nailing: Can we improve outcomes? *Indian J Orthop* 2011;45:208-15.
- Qidwai SA. Treatment of humeral shaft fractures by closed fixation using multiple intramedullary Kirschner wires. *J Trauma* 2000;49:81-5.
- Rommens PM, Verbruggen J, Broos PL. Retrograde locked nailing of humeral shaft fractures. A review of 39 patients. *J Bone Joint Surg Br* 1995;77:84-9.
- Stern PJ, Mattingly DA, Pomeroy DL, Zenni EJ Jr, Kreig JK. Intramedullary fixation of humeral shaft fractures. *J Bone Joint Surg Am* 1984;66:639-46.
- Bell MJ, Beauchamp CG, Kellam JK, McMurtry RY. The results of plating humeral shaft fractures in patients with multiple injuries. The Sunnybrook experience. *J Bone Joint Surg Br* 1985;67:293-6.
- Hall RF Jr, Pankovich AM. Ender nailing of acute fractures of the humerus. A study of closed fixation by intramedullary nails without reaming. *J Bone Joint Surg Am* 1987;69:558-67.
- Brumback RJ, Bosse MJ, Poka A, Burgess AR. Intramedullary stabilization of humeral shaft fractures in patients with multiple trauma. *J Bone Joint Surg Am* 1986;68:960-70.
- Weseley MS, Barenfeld PA, Eisenstein AL. Rush pin intramedullary fixation for fractures of the proximal humerus. *J Trauma* 1977;17:29-37.