

Ultrasonographic Triangular Cord Sign and Gallbladder Abnormality in Diagnosis of Biliary Atresia

Seyed Ali Jafari*¹, Mehrzad Mehdizadeh², Fatemeh Farahmand³,
Gholam Hossein Fallahi⁴, Hamid Reza Kianifar⁵

*1,5-Departments of pediatric, Divisin of gastroenterology, Ghaem Hospital,
Mashhad University of Medical Sciences, Mashhad, Iran*

*2-Departments of radiology, Children's Hospital Medical Center,
Tehran University Of Medical Sciences, tehran, Iran*

*3,4-Departments of pediatric, Divisin of gastroenterology, Children's Hospital Medical Center,
Tehran University of Medical Sciences Tehran, Iran.*

Abstract

Introduction

Early diagnosis of biliary atresia is very important for better outcome of treatment. Ultrasonography is one of the diagnostic tools for early differentiation of biliary atresia from other causes of neonatal cholestasis. It has been reported that triangular cord sign (TACS) in sonography is a reliable sign for diagnosis of biliary atresia. The aim of this study was to re-assess the accuracy of TACS alone and coupled with an abnormal gallbladder in the diagnosis of biliary atresia.

Materials and Methods

Infants with prolonged cholestatic jaundice underwent ultrasonography and liver biopsy. Results of ultrasound scans (TASC and gallbladder abnormality) were compared with histopathological findings. Sensitivity, specificity, positive predictive value, negative predictive value and accuracy of Ultrasonographic findings for diagnosis of biliary atresia based on liver histopathology were studied.

Results

The sensitivity, specificity and accuracy of TACS for diagnosis of biliary atresia were 36%, 95% and 77% respectively. Positive predictive value and negative predictive value was 77%. The sensitivity and specificity of gallbladder abnormality for diagnosis of biliary atresia were 36% and 88% respectively. Positive predictive value of TACS coupled with gallbladder abnormality for diagnosis of biliary atresia was 100%.

Conclusion

The Ultrasonographic TACS is very specific for diagnosis of biliary atresia. Positive predictive value and accuracy of this sign is much higher than of gallbladder abnormality. The sensitivity of TACS for diagnosis of biliary atresia is very low.

Key words

Cholestasis, TASC, Biliary atresia

Introduction

Biliary atresia is the end result of a destructive, idiopathic and inflammatory process that affects intra and extrahepatic bile ducts, leading to fibrosis and obliteration of the biliary tract and eventual

development of biliary cirrhosis. At present, there is no specific therapy that effectively halts or reverses cholestasis and hepatic injury in children with biliary atresia. The only therapeutic choice to increase biliary flow and improve jaundice is the

hepatopertoenterostomy. Prior to the development of this surgical procedure, the mortality from biliary atresia was virtually 100%. The success of this surgical procedure is much higher if it is performed before 2 months of age, therefore early diagnosis of biliary atresia is very important for successful surgery and better outcome.^{1,2} Ultrasonography is one of the methods for diagnosis of biliary atresia and approach to any infant with cholestasis. Ultrasonographic triangular cord sign (TACS) is an echogenic tubular or triangular density, seen immediately cranial to the portal vein bifurcation in patients with biliary atresia. It has been reported that this sign is very useful in the diagnosis of biliary atresia.^{3,4} The aim of our study was to re-assess the accuracy of the triangular cord sign, alone and when coupled with abnormal gallbladder in the diagnosis of biliary atresia.

Methods

All infants (age \leq 3mo) with prolonged cholestatic jaundice (direct bilirubin greater than 20% of total bilirubin for more than two weeks) that referred to the Children's Hospital Medical Center in Tehran from January 2007 to February 2008 were included in this study. Each infant underwent ultrasound scan, done by one of the authors; focus was on the triangular cord sign and gallbladder length. The gallbladder was considered abnormal if its length was less than 15 mm or if it could not be identified. Infants had ultrasound scans after 4 hours of fasting. Infants with choledocal cysts were excluded from the study. Percutaneous liver biopsy was done in all of patients with local anesthesia except in patients that we could not perform this procedure for them because of clinical instability or uncorrectable coagulopathy and in infants in whom liver biopsy was not necessary because the main cause of cholestasis was identified by methods other than liver biopsy, (For example patients with cystic fibrosis, galactosemia or tyrosinemia). Infants in whom liver biopsy was not performed were excluded from the study. The diagnosis of biliary atresia was suggested by the presence of bile duct proliferation, portal fibrosis and canalicular bile stasis on histopathological evaluation of biopsy specimens.

We compared the results of ultrasound scans (presence of TACS or gallbladder abnormality) with histopathological findings (presence or absence of findings compatible with biliary atresia) as the gold standard. Sensitivity, specificity, positive predictive value, negative predictive value and accuracy of ultrasonographic results compared with the gold standard were calculated.

Results

We included 63 infants in our study and they underwent ultrasonography and liver biopsy. The ages of the infants ranged from 27 to 90 days (mean = 67.1, SD= 18.8).

Ultrasonographic TACS was identified in 9 patients and diagnosis of biliary atresia was made based on histopathological findings in 7 of them. False positives were seen in two infants. (Table -1). The sensitivity, specificity and accuracy of TACS for diagnosis of biliary atresia were 36% (95% CI: 16%- 61%), 95% (95% CI: 84% -99%) and 77% respectively. Positive predictive value and negative predictive value were 77% (95% CI: 39% -97%) and 77% (95% CI: 64% - 87%) respectively. Likelihood ratio of positive test was 8.1 (95% CI: 1. 85-35.48).

Twelve patients had gallbladder abnormality on ultrasound scans in which 7 infants had evidences of biliary atresia histopathologically (Table 2). The sensitivity, specificity, positive predictive value, negative predictive value and accuracy of gallbladder abnormality for diagnosis of biliary atresia based on liver biopsy were 36% (95% CI: 16%-61%), 88% (95% CI: 75%-96%), 58% (95% CI: 27% - 84%), 76% (95% CI: 62% -87%) and 73% respectively. Likelihood ratio of positive test was 3.2 (95% CI: 1.17 – 8.93).

We also compared ultrasonographic TACS together with gallbladder abnormality in ultrasound scans with evidence of biliary atresia histopathologically. Three patients showed TACS coupled with gallbladder abnormality on ultrasonography and in all of them the diagnosis of biliary atresia was made based on liver histopathology. (Table-3). The sensitivity, specificity and accuracy of this parameter (TACS + gallbladder abnormality) for diagnosis of biliary atresia were 15% (95% CI: 3% -39%), 100% and 74% respectively. Positive predictive and negative predictive values were 100% and 73% (95% CI: 60% -83%) respectively.

Discussion

Early diagnosis of biliary atresia is very important for successful surgical treatment of patients. The success rate for establishing bile flow after surgery is much higher (90%) if this procedure is done before 2 months of age.^{1,2,5} The advent of ultrasonography has revolutionized the approach to infants with cholestasis. This non- invasive, non- ionizing imaging modality serves as an important tool for early differentiation of biliary atresia from other causes of neonatal cholestasis. In infants with biliary atresia the gallbladder is usually small or absent on ultrasound

scans. Choi et al were the first to report a triangular or tubular echogenic density seen immediately cranial to the portal vein bifurcation (triangular cord sign, TACS) as a reliable sign for diagnosis of biliary atresia.³ Park et al showed that sensitivity, specificity and accuracy of TACS for diagnosis of biliary atresia were 98%, 83% and 93% respectively.⁶ In another study performed by Kotb et al. sensitivity and specificity of this sign for diagnosis of biliary atresia was 100%.⁵ The sensitivity, specificity and accuracy of TACS for diagnosis of biliary atresia reported by others have varied from 80% -95.7%, 73.9%-98% and 84.8% -95% respectively.^{4,7,8} In one study, Kanegawa et al. showed sensitivity, specificity, accuracy and positive predictive value of gallbladder abnormality for diagnosis of biliary atresia were 95.7%, 73.9%, 84.8% and 78.6% respectively.⁹ One study showed that positive predictive value of TACS coupled with gallbladder abnormality for diagnosis of biliary atresia was 100%.⁶

Comparison of our results with previous studies showed that specificity and positive predictive value of TACS and gallbladder abnormality for diagnosis of biliary atresia in this study were comparable with others but the sensitivity of above findings was much lower in our study.

Low sensitivity of TACS in our study can be related to early stages of disease, because formation of fibrous tissue in hepatic portal, thereby detection of TACS partly depends on duration of disease. Other factors that influence the sensitivity of an ultrasound scan consist of cooperation of patient, experience of physician and resolution of the equipment, therefore sensitivity of an ultrasonographic finding can be very variable depending on above condition.

This study similar to others showed that the accuracy of TACS coupled with gallbladder abnormality was greater than that of TACS alone and that of gallbladder abnormality alone. Positive predictive value of TACS together with gallbladder abnormality was 100% similar to the study performed by Park et al.

Conclusion:

The ultrasonographic TACS for diagnosis of biliary atresia is very specific. Specificity, positive predictive value and accuracy of this sign are much higher than those of gallbladder abnormality. In a patient with clinical and paraclinical findings compatible with biliary atresia detection of TACS especially if coupled with gallbladder abnormality can eliminate need for invasive liver biopsy and this patient can be directly referred for surgical intervention. Absence of TACS

in ultrasound scan cannot rule out the diagnosis of biliary atresia because false negative results are relatively high, thereby sensitivity is very low

References:

- 1- Campbell KM, Bezerra JA. Biliary Atresia. In: walker WA, Goulet D, Kleinman RE, Sherman PM, Schneider BL, sanderson IR. Pediatric gastrointestinal disease. BC Decker Inc: Hamilton. 2004; P. 1122-1138.
- 2- Balistreri WF, Bezerra JA, Ryckman FC. Biliary Atresia and other disorders of the extrahepatic bile ducts. In: Suchy FJ, Sokol RJ, Balistreri WF. Liver disease in children. Cambridge university press: New York. 2007; P. 247-269.
- 3- Choi SO, Park WH, Lee HJ, Woo SK. Triangular cord: A sonographic finding applicable in the diagnosis of biliary atresia. Journal of pediatric Surgery. 1996; 31: 363-366.
- 4- Lee HJ, Lee SM, Park WH, Choi So. Objective criteria of triangular cord sign in biliary atresia on US sans. Radiology. 2003; 229: 395-400.
- 5- Kotb MA, Kotb A, Sheha MF, et al. Evaluation of the triangular cord sign in the diagnosis of biliary atresia. Pediatrics. 2001; 108: 416-420.
- 6- Park WH, Choi SO, Lee HJ. The ultrasonographic triangular cord coupled with gallbladder images in the diagnostic prediction of biliary atresia from infantile intrahepatic cholestasis. j pediatric surgery. 1999; 34: 1706-10.
- 7- Tan Kendrick AP, phua KB, Ooi BC, et al. Making the diagnosis of biliary atresia using the triangular cord sign and gallbladder length. Pediatric radiology. 2000; 30: 69-73.
- 8- Visrutaratna P, Wongsawasdi L, Lerttumnongtum P, et al. Triangular cord sign and ultrasound features of the gallbladder in infants with biliary atresia. Australasian Radiology. 2003; 47: 252-6.
- 9- Kanegawa K, Akasaka Y, Kitamura E, et al. sonographic diagnosis of biliary atresia in pediatric patients using the triangular cord sign versus gallbladder length and contraction. American Journal of Roentgenology. 2003; 181: 1387-1390.

Table – 1: Comparison of ultrasonographic TACS with biliary atresia based on liver histopathology

Yes		TACS		
		No		
Biliary atresia in liver histopathology	Yes	7	12	19
	No	2	42	44
		9	54	63
Sensitivity =36% Specificity = 25% PPV* = 77% NPV** = 77% Accuracy = 77%				

* Positive predictive value
** Negative predictive value

Table – 2: Comparison of ultrasonographic gallbladder abnormality with biliary atresia based on liver histopathology

Yes		Gallbladder abnormality		
		No		
Biliary atresia in liver histopathology	Yes	7	12	19
	No	5	39	44
		12	51	63
Sensitivity =36% Specificity = 88% PPV* = 58% NPV** = 76% Accuracy = 73%				

* Positive predictive value
** Negative predictive value

Table –3: Comparison of ultrasonographic TACS + gallbladder abnormality with biliary atresia based on liver histopathology

Yes		TACS + Gallbladder abnormality		
		No		
Biliary atresia in liver histopathology	Yes	3	16	19
	No	0	44	44
		3	60	63
Sensitivity =15% Specificity = 100% PPV* = 100% NPV** = 73% Accuracy = 74%				

* Positive predictive value
** Negative predictive value

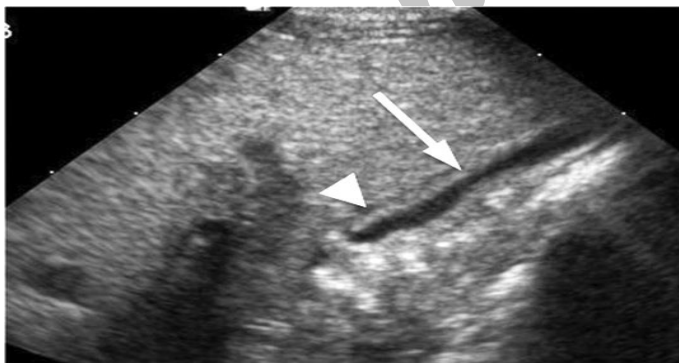

Fig 2. Normal gallbladder wall

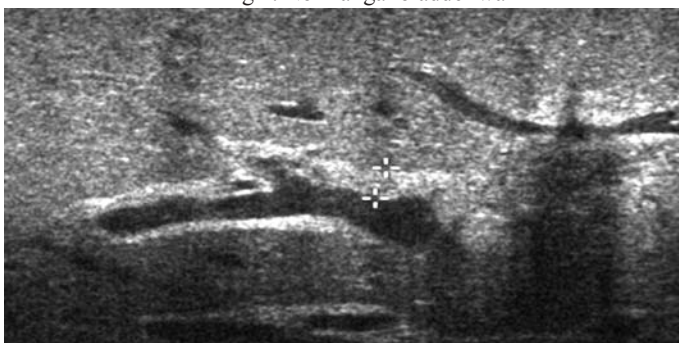

Fig 3. Objective criteria of triangular cord sign in biliary atresia seen on scan

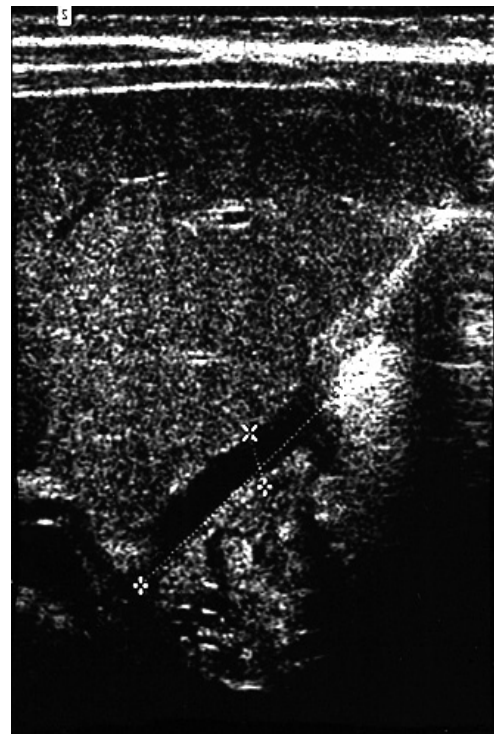


Fig 1. Gall bladder of an infant with biliary atresia