

Neonatal Outcomes of Fetuses with Isolated or Multiple Soft Markers in Ultrasound Screening

Mahboobeh Shirazi¹, Mona Taghavipour^{1*}, Behnaz Moradi^{2,3}, Fatemeh Rahimi Sharbaf¹, Fatemeh Golshahi¹, Behrokh Sahebdel¹, Elham Feizabad¹, Maria Nezamnia⁴, Zahra Khazaeipour⁵, Maryam Moshfeghi⁶, Fatemeh Sharafi⁷

1. Maternal, Fetal, and Neonatal Research Center, Yas Complex Hospital, Tehran University of Medical Sciences, Tehran, Iran

2. Department of Radiology, Yas complex Hospital, Tehran University of Medical Sciences, Tehran, Iran

3. Department of Radiology, Advanced Diagnostic and Interventional Radiology Research Center (ADIR), Imam Khomeini Hospital, Tehran University of Medical Sciences, Tehran, Iran

4. Department of Obstetrics and Gynecology, School of Medicine, Bam University of Medical Sciences, Kerman, Iran

5. Brain and Spinal Cord Injury Research Center, Neuroscience Institute, Tehran University of Medical Sciences, Tehran, Iran

6. Department of Endocrinology and Female Infertility, Reproductive Biomedicine Research Center, ACECR, Tehran, Iran

7. Cellular and Molecular Biology Department, Tehran Azad University of Medical Sciences, Tehran, Iran

ABSTRACT

Background: There is still controversy on the importance of soft markers on the fetus and neonatal outcomes. This study aimed to determine the mentioned outcomes in the fetuses with soft markers detected by ultrasound screening.

Methods: This prospective study was conducted on 461 pregnant women who were referred to the prenatal clinics of hospitals affiliated with the Tehran University of Medical Sciences, Tehran, Iran, in 2021. The study outcomes included incidence of abortion, preterm birth (PTB), cesarean section (CS), low birth weight (LBW), neonatal admission rates, and neonatal mortality.

Results: The most frequent soft marker in the present study was echogenic intra-cardiac foci (EIF) (32.5%), followed by choroid plexus cyst (CPC) (30.6%), pyelectasis (25.2%), and echogenic bowel (EB) (15.8%), respectively. Spontaneous abortion, PTB, CS, LBW, neonatal department admission, neonatal intensive care unit (NICU) admission, stillbirth, and fetal distress, and death occurred in 10 (2.1%), 52 (12.5%), 316 (76%), 35 (7.6%), 28 (6.7%), 42 (10.1%), 13 (3.1%), 26 (5.6%), and one (0.24%) cases, respectively.

Poor neonatal outcomes were significantly associated with EIF ($P=0.007$), CPC ($P=0.045$), echogenic bowel ($P=0.031$), pyelectasis ($P=0.026$), and single umbilical artery ($P=0.010$). In addition, the fetuses with synchronous CPC and IEF and also synchronous pyelectasis and IEF were at significantly higher risk of poor neonatal outcomes ($P=0.037$).

Conclusion: The study results showed that although poor neonatal outcomes were associated with some soft markers, most fetuses with soft markers had desired outcomes in the absence of structural or chromosomal abnormality.

Keywords: Fetus, Follow-up, Isolated soft marker, Neonatal, Outcome, Ultrasonography

Introduction

Ultrasound screening at 16 to 20 weeks of gestational age is commonly used (1). However, applying high-resolution ultrasound in prenatal assessment results in detecting some little non-pathological findings in the fetus called "soft markers" (2).

The most common detectable soft markers

include thickened nuchal fold, absent or short nasal bone, echogenic bowel, renal pyelectasis, short femur, and mild or severe cerebral ventriculomegaly (3-6).

Overall, the soft markers are reported to be 5%-17% of all pregnancies and although they might be considered normal variants, their incidence is

* Corresponding author: Mona Taghavipour, Maternal, Fetal, and Neonatal Research Center, Yas Complex Hospital, Tehran University of Medical Sciences, Tehran, Iran. Tel: 09111520242; Email: monataghavipour1982@yahoo.com

Please cite this paper as:

Shirazi M, Taghavipour M, Moradi B, Rahimi Sharbaf F, Golshahi F, Sahebdel B, Feizabad E, Nezamnia M, Khazaeipour Z, Moshfeghi M, Sharafi F. Neonatal Outcomes of Fetuses with Isolated or Multiple Soft Markers in Ultrasound Screening. Iranian Journal of Neonatology. 2022 Apr; 13(2). DOI: [10.22038/IJN.2022.62724.2197](https://doi.org/10.22038/IJN.2022.62724.2197)

remarkably higher in infants with genetic abnormalities and congenital anomalies (7-9).

Some studies (10, 11) reported that the echogenic intra-cardiac foci (EIF) could be considered a normal variant in the development of papillary muscles without any correlation with chromosomal abnormalities, while the other studies (12, 13) showed a correlation between EIF and chromosomal abnormalities, particularly in cases of trisomy 21.

There is still controversy over the importance of soft markers, and the specific etiology of soft markers has not been well understood (14). Therefore, this study aimed to determine the neonatal outcomes of fetuses with isolated or multiple soft markers detected by ultrasound screening.

Methods

This prospective study was conducted on pregnant women with isolated or multiple soft markers who were referred to the prenatal clinics of Yas, Imam Khomeini, and Shariati Hospital (affiliated with Tehran University of Medical Sciences), Tehran, Iran, from January to November 2021.

Inclusion criteria included singleton pregnant women with gestation ages of 15 to 22 weeks, whose fetuses had isolated or multiple soft markers (based on the results of the ultrasound screening) and no chromosomal abnormalities.

Women with underlying diseases, such as hypertension, diabetes, cardiac disease, genetic disorder, history of chromosomal abnormalities in their previous pregnancies, and those whose fetuses had the structural anomaly (detected by ultrasound screening), increased (≥ 95 percentile) nuchal translucence, high risk first- or second-trimester screening tests, a chromosomal abnormality in amniocentesis or noninvasive prenatal testing (NIPT), as well as withdrawal to participate, were excluded from the study.

The sampling was performed using the census method and all the pregnant women who met the inclusion criteria were enrolled in the study. All ultrasound screening tests were performed by expert perinatologists using a PHILIPS Infiniti 70 ultrasound machine equipped with a convex trans-abdominal 6-9 MHz probe.

Ultrasonographic soft markers that were assessed in this study included EIF, choroid plexus cyst (CPC), pyelectasis, echogenic bowel (EB), absent or hypoplastic nasal bone (NB), shortened femur, single umbilical artery (SUA), mild ventriculomegaly, enlarged cisterna magna (CM),

thickened nuchal fold (TNF), and aberrant right subclavian artery (ARSA).

An EIF is an echogenic (as bright as the surrounding bones) small area that appears in cardiac ventricles at least in two separate ultrasound planes. A CPC is defined as a fluid-filled structure that is visualized as an echolucent cyst in the lateral ventricles of the fetal brain. Pyelectasis is considered to be a dilation of the fetal urinary tract (15).

EB is diagnosed when the fetal bowel is visualized with echogenicity equal/higher than that of the surrounding fetal bone in ultrasound images. The absent or hypoplastic NB is diagnosed when the fetal NB is absent or is less than 2.5mm. In the fetus with SUA, one artery is detected (instead of two arteries) on a cross-section of the umbilical cord ultrasound screening (15).

The shortened femur is considered when the ratio of the measured femoral length to an expected femoral length (according to biparietal diameter) is less than 0.92. Mild ventriculomegaly is defined as the fetus's brain ventricle volume between 10 and 15 mm, and CM is diagnosed when its volume is more than 10 mm in an anteroposterior dimension on ultrasound examination (15).

TNF is diagnosed when the NF, which is illustrated as an angled caudally to capture the cerebellum and occipital bone is equal to/higher than 6 mm at 18 to 24 weeks of gestation. ARSA is followed by a left subclavian artery with an aberrant right subclavian artery and its aberrant can happen about the left subclavian artery (15).

According to Society for Maternal-Fetal Medicine, amniocentesis or NIPT was requested for the pregnant women, after soft marker detection in screening ultrasound (15). If any chromosomal abnormality was reported in amniocentesis or NIPT, the pregnant women were excluded from the study.

The data that were recorded for the study patients included age, body mass index (BMI), obstetrics history, and any relationship between the couples. The study outcomes were incidence of abortion, emergent cesarean section (CS), preterm birth (PTB), abnormal birth weight, neonatal mortality, and neonatal admission rate and the causes.

Ethical considerations

This study was conducted in compliance with the Helsinki Declaration and approved by the Ethics Committee of Tehran University of Medical Sciences, Tehran, Iran (IR.TUMS.IKHC.REC.1400.042).

The informed written consent was obtained from the participant prior to the commencement of the study.

Statistical analysis

All the statistical analyses were conducted using SPSS software (version 24.0). A p-value less than 0.05 was considered statistically significant. The Chi-square and Fisher's exact tests were used to evaluate the differences in proportion.

Results

In this study, a total of 7,450 pregnant women were assessed for eligibility, of whom 531 had isolated or multiple soft markers. In cases with positive soft markers, 48, 7, 5, and 10 women were excluded due to having underlying diseases, positive history of chromosomal abnormalities in

their previous pregnancies, having abnormal second-trimester screening tests, and chromosomal abnormality in amniocentesis or NIPT test, respectively. Eventually, 461 women were analyzed (Figure 1).

The mean±SD age of pregnant women was 30.37±5.40 (age range: 18-50 years) and their mean±SD of BMI was 26.41±4.25 kg/m². Moreover, 42.2% and 25% of women experienced their first gravidity and had at least one abortion history, respectively. In addition, 30 (6.5%) and 15 (3.3%) of the couples had first-degree and second-degree relationships, respectively.

The frequency of different soft markers in the study participants was evaluated. The most frequent soft marker was EIF (32.5%), followed by CPC (30.6%), pyelectasis (25.2%), and EB (15.8%),

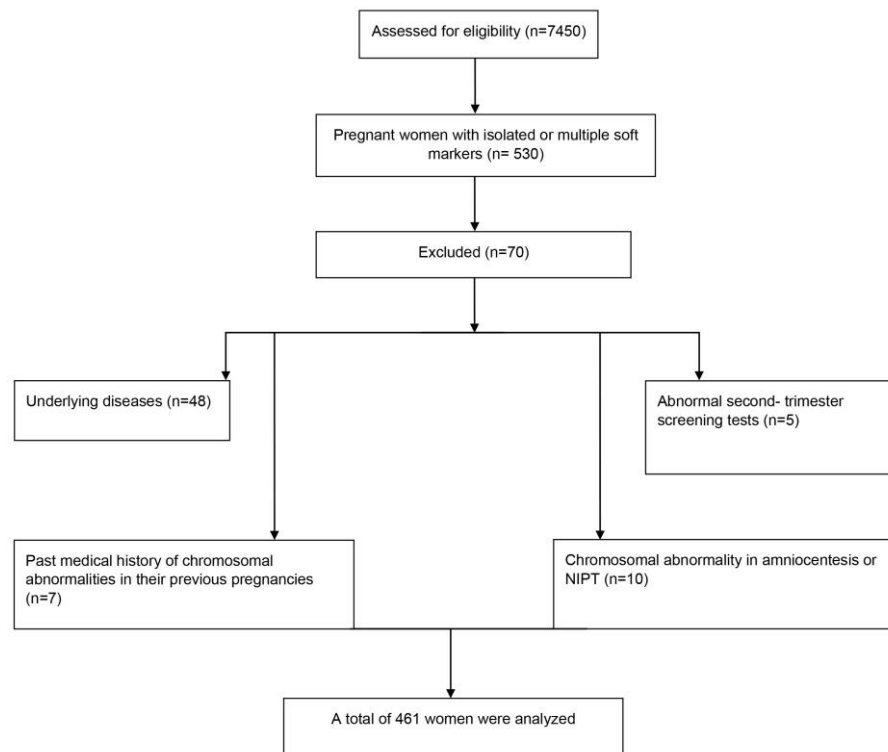


Figure 1. Flow diagram of the study

Table 1. frequency of soft markers in the participants

Soft Markers	Number	Frequency
Echogenic intra-cardiac foci	150	32.5
Choroid plexus cyst	141	30.6
Pyelectasis	116	25.2
Echogenic bowel	73	15.8
Absent or hypoplastic nasal bone	30	6.5
Shortened femur	15	3.3
Single umbilical artery	15	3.3
Mild ventriculomegaly	12	2.6
Enlarged cisterna magna	3	0.7
Thickened nuchal fold	2	0.4
Aberrant right subclavian artery	1	0.2

Table 2. Study outcomes according to different soft markers

Variables	Ventricomegaly	CPC	NB	TNF	EIF	EB	shortened femur	Pyelectasis	SUA	Cisterna
Abortion	0	2	2	0	2	4	0	2	0	0
GA at delivery										
Early pre-term	0	4	0	0	4	6	1	4	0	0
Late pre-term	1	8	1	0	15	4	1	7	5	0
Term	7	120	22	1	124	52	12	92	8	3
Post-term	0	0	1	0	1	0	0	2	0	0
Weight at delivery										
<2500gr	0	6	2	0	13	10	3	7	2	0
2500-4000gr	7	124	22	1	126	49	11	93	11	3
>4000gr	1	2	1	0	4	3	0	5	0	0
Neonate status										
Normal	7	108	21	1	108	45	12	88	7	3
Neo-department	0	9	1	0	18	0	0	4	1	0
NICU	1	11	2	0	14	7	2	9	4	0
Stillbirth	0	4	1	0	4	3	0	4	1	0
Dead	0	0	0	0	0	1	0	0	0	0
Total	4	132	25	1	144	62	14	105	13	3

CPC: choroid plexus cyst, NB: absent or hypoplastic nasal bone, TNF: thickened nuchal fold, EIF: echogenic intracardiac foci, EB: echogenic bowel, SUA: single umbilical artery.

respectively. The frequency of the other soft markers was less than 10% (Table 1).

An isolated soft marker was found in 80.7% of the fetuses, while multiple synchronous soft markers (with a range of two to three) were detected in 19.3% of them. As the most frequent soft marker, IEF was detected in 104 (69%) fetuses isolated, and other soft markers were reported in 46 (31%) fetuses, mostly accompanied by CPC and pyelectasis.

A total of 35 (7.5%) participants were lost to follow-up due to lack of response. In the other one, spontaneous abortion and PTB occurred in 10 (2.1%) in 52 (12.5%) pregnant women, respectively.

The route of delivery in 100 (24%) and 316 (76%) pregnant women was NVD and CS,

respectively. The frequency of different GA at delivery and other study outcomes, according to different soft markers, are presented in Table 2.

The neonate adverse outcomes included low birth weight, high birth weight, neonate department admission, NICU admission, stillbirth, fetal distress, and dead fetus in 35 (8.4%), 12 (2.8%), 28 (6.7%), 42 (10.1%), 13 (3.1%), 26 (5.6%) and one (0.24%) cases, with no case of asphyxia.

Poor neonatal outcomes including neonate department admission, NICU admission, and mortality were significantly associated with some soft markers, such as IEF (P=0.007), CPC (P=0.045), and EB (P=0.031), pyelectasis (P=0.026), and SUA (P=0.010) (Figure 2). In addition, the admission,

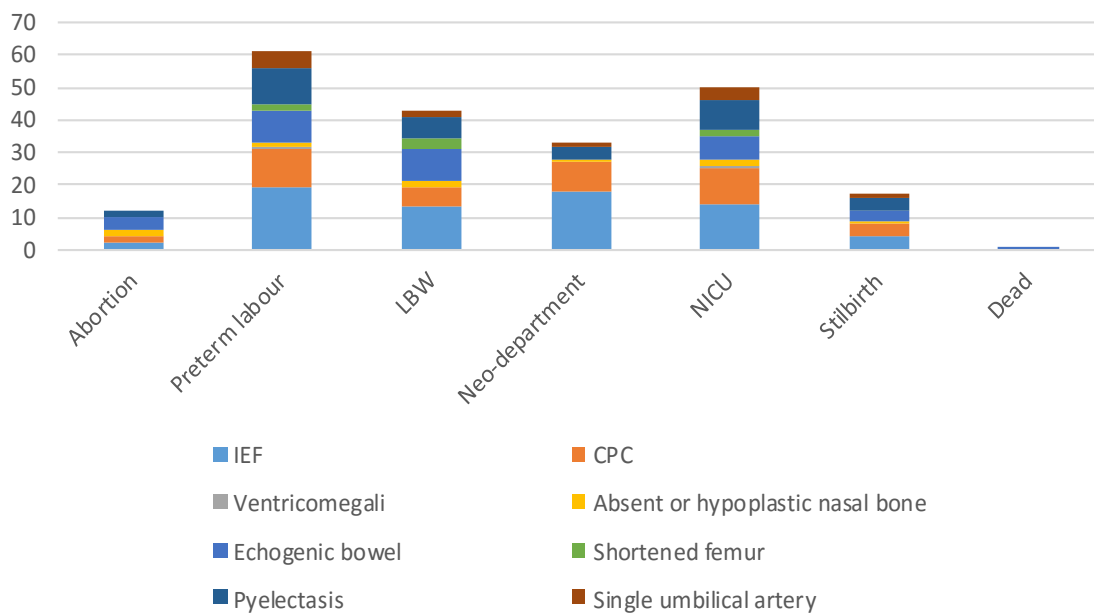


Figure 2. Poor pregnancy outcomes in different soft markers

Table 3. Admission and mortality causes

Admission cause	EIF* (N=36)	CPC (N=24)	EB (N=17)	Pyelectasis (N=17)	SUA (N=6)
Prematurity	11 (30.5)	8 (32)	10 (58.8)	7 (41.2)	3 (50)
Icterus	18 (50)	14 (56)	2 (11.8)	6 (35.3)	1 (16.7)
Infection disease	2 (5.5)	0	1 (5.9)	1 (5.9)	0
Others	4 (11.1)	3 (12)	4 (23.5)	3 (17.6)	2 (33.3)

*One missing data, EIF: echogenic intracardiac foci, CPC: choroid plexus cyst, EB: echogenic bowel, SUA: single umbilical artery.

Table 4. Study outcomes according to the number of soft markers

Variables	All	Number of soft markers			P-value
		One	Two	Three	
Abortion	10	7	2	1	0.180
GA at delivery					
Early pre-term	16	13	3	0	0.460
Late pre-term	36	31	4	1	
Term	360	285	69	6	
Post-term	3	2	1	0	
Weight at delivery					0.730
<2500gr	35	28	6	1	
2500-4000gr	368	294	69	5	
>4000gr	12	9	2	1	
Neonate status					0.140
Normal	332	268	60	4	
Neonate department	28	19	7	2	
NICU	42	34	8	0	
Stillbirth	13	10	2	1	
Dead	1	1	0	0	
Total	416	332	77	7	

and mortality causes are summarized in Table 3.

The fetuses with synchronous CPC and IEF and also synchronous pyelectasis and IEF were at significantly higher risk of poor neonatal outcomes ($P=0.037$), while the study outcomes were not significantly different in terms of the number of soft markers (Table 4).

Discussion

In this study, the most frequent soft marker was EIF, followed by CPC, pyelectasis (25.2%), and EB, respectively. Overall, spontaneous abortion, PTB, CS, LBW, neonatal department admission, NICU admission, stillbirth, fetal distress, and death occurred in 2.1%, 12.5%, 76%, 7.6%, 6.7%, 10.1%, 3.1%, 5.6%, and 0.24% of the cases, respectively.

Nowadays, the association between soft markers and aneuploidy, as well as soft markers and neonatal outcomes are one of the most noticeable and controversial issues in prenatal screening. In addition, long-term adverse outcomes are the other concern with soft markers. In this regard, ventricular septal defect (VSD), tetralogy of Fallot (TOF), and pulmonary hypertension were reported in some fetuses with EIF (16-19).

Evidence showed that the rates of chromosomal abnormalities in some soft markers, such as the short femur, TNF, CPC, absent NB, and ventriculomegaly, are higher than the others, with

no significant difference in the rate of chromosomal abnormalities according to numbers of soft markers (20). However, in this study, we could not assess this rate due to including fetuses without chromosomal abnormalities.

Although some former studies (18, 19) showed no complication except for epilepsy and attention-deficit/hyperactivity diseases in two live-born babies with CPCs, in this study poor pregnancy outcomes, including abortion, PTB, LBW, neonatal-department admission, NICU admission, and stillbirth were detected in 44 fetuses with CPC.

In our study, one neonatal death was reported in fetuses with EB with unknown causes. While in previous studies (21-25), EB has been associated with some abnormalities, including intrauterine bleeding, congenital infection, cystic fibrosis, fetal growth restriction, and primary fetal bowel abnormality.

In line with our findings, former studies showed that fetuses with SUA are at greater risk for some adverse outcomes, such as small for gestational age, PTB, admission to the NICU, and perinatal mortality (26).

Based on the study results, most fetuses with soft markers, detected by ultrasound, without structural or chromosomal abnormality have desired outcomes during and after pregnancy and the incidence of spontaneous abortion ($P=0.120$),

PTB ($P=0.086$), and neonatal admission ($P=0.160$) were not significantly different from the normal population (27).

In this study, long-lasting outcomes of soft markers were not assessed, while some studies evaluated the permanent effects of these markers. Based on the evidence, pyelectasis may be persistent or progressive in the future life; therefore, urinary tract assessment must be done after birth (18, 19).

Regarding the limitation of this study, one can refer to the small follow-up period. The prospective nature of this study and assessment of multiple synchronous soft markers are among the strengths of the current study.

Conclusion

Our study showed that although poor neonatal outcomes were associated with some ultrasound soft markers, especially in the case of having synchronous CPC and IEF or synchronous pyelectasis and IEF, most fetuses with soft markers, in the absence of structural or chromosomal abnormality, had desired outcomes during and after pregnancy. However, further studies are required to determine the importance of soft marker findings in prenatal screening.

Acknowledgments

This study was funded and supported by the Tehran University of Medical Sciences, Tehran, Iran (TUMS, Grant no. 52280).

Conflicts of interest

None.

References

1. Van den Hof MC, Wilson RD. Fetal soft markers in obstetric ultrasound. *J Obstet Gynaecol Can.* 2005;27(6):592-636.
2. Bethune M. Literature review and suggested protocol for managing ultrasound soft markers for Down syndrome: thickened nuchal fold, echogenic bowel, shortened femur, shortened humerus, pyelectasis and absent or hypoplastic nasal bone. *Australas Radiol.* 2007 ;51(3):218-25.
3. Smith-Bindman R, Chu P, Goldberg JD. Second trimester prenatal ultrasound for the detection of pregnancies at increased risk of Down syndrome. *Prenat Diagn.* 2007;27:535-544.
4. Nicolaides KH. Nuchal translucency and other first-trimester sonographic markers of chromosomal abnormalities. *Am J Obstet Gynecol.* 2004;191:45-67.
5. Sethna F, Tennant PW, Rankin J, Robson S. Prevalence, natural history, and clinical outcome of mild to moderate ventriculomegaly. *Obstet Gynecol.* 2011;117:867-876.
6. Salomon LJ, Bernard JP, Ville Y. Reference ranges for fetal ventricular width: a non-normal approach. *Ultrasound Obstet Gynecol.* 2007;30(1):61-6.
7. Viaux-Savelon S, Dommergues M, Rosenblum O, Bodeau N, Aidane E, Philippon O, Mazet P, Vibert-Guigues C, Vauthier-Brouzes D, Feldman R, Cohen D. Prenatal ultrasound screening: false positive soft markers may alter maternal representations and mother-infant interaction. *PLoS One.* 2012; 7(1):e30935.
8. Kaplan R, Adams S. Incidental Fetal Ultrasound Findings: Interpretation and Management. *J Midwif Womens Health.* 2018;63(3):323-9.
9. Tosun M, Kurtoglu Ozdes E, Malatyalioglu E, et al. Long-Term Outcome of Fetuses with Soft Marker and Without Genetic or Structural Abnormality. *J Obstet Gynaecol India.* 2019;69(1):56-61.
10. Levy DW, Mintz MC. The left ventricular echogenic focus: anormal finding. *Am J Radiol.* 1988;150:85-6.
11. Achiron R, Lipitz S, Gabbay U, Yagel S. Prenatal ultrasono-graphic diagnosis of fetal heart echogenic foci: no correlation with Down syndrome. *Obstet Gynecol.* 1997;89:945-8.
12. Simpson JM, Rowlands ML, Sharland GK. The significance of echogenic foci ('golfballs') in the fetal heart: a prospective study of 147 cases. *Ultrasound Obstet Gynecol.* 1996;(Suppl 3):225-8.
13. Lehman CD, Nyberg DA, Winter TC III, Kapur RP, Resta RG, Luthy DA. Trisomy 13 syndrome: prenatal US findings in a review of 33 cases. *Radiology.* 1995;194:217-2.
14. Cai M, Huang H, Xu L, Lin N. Classifying and Evaluating Fetuses With Ventriculomegaly in Genetic Etiologic Studies. *Front Genet.* 2021;12:682707.
15. Prabhu M, Kuller JA, Biggio JR. Society for Maternal-Fetal Medicine (SMFM). Society for Maternal-Fetal Medicine (SMFM) Consult Series# 57: Evaluation and Management of Isolated Soft Ultrasound Markers for Aneuploidy in the Second Trimester. *Am J Obstet Gynecol.* 2021; 225(4):B2-B15.
16. Gupta G, Aggarwal S, Phadke SR. Intracardiac echogenic focus and fetal outcome. *J Clin Ultrasound.* 2010;38(9):466-9.
17. Shakoor Shafia, Ismail Humera, Munim Shama. Intracardiac echogenic focus and fetal outcome—review of cases from a tertiary care centre in Karachi, Pakistan. *J Matern Fetal Neonatal Med.* 2013;26(1):2-4.
18. Tosun M, Kurtoglu Ozdes E, Malatyalioglu E, Yavuz E, Celik H, Bildircin FD, Canga K, Kokcu A, Ogur G. Long-Term Outcome of Fetuses with Soft Marker and Without Genetic or Structural Abnormality. *J Obstet Gynaecol India.* 2019;69(1):56-61.
19. Masihi S, Barati M, Karimi Moghaddam E, Rezazadeh A, Ronaghi F. Outcome of fetuses with soft markers: results of 3016 cases in Ahvaz city. *Med J Islam Repub Iran.* 2021;35:4.
20. Cai M, Lin N, Chen X, Fu M, Guo N, Xu L, Huang H. Evaluation of chromosomal abnormalities and copy number variations in fetuses with ultrasonic soft

- markers. *BMC Med Genet.* 2021;14(1):19.
21. Buitter HD, Holswilder-Older Scholtenhuis MA, Bouman K, et al. Outcome of infants presenting with echogenic bowel in the second trimester of pregnancy. *Arch Dis Child Fetal Neonatal Ed.* 2013;98(3):F256-9.
 22. De Oronzo MA. Hyperechogenic fetal bowel: an ultrasonographic marker for adverse fetal and neonatal outcome? *J Prenat Med.* 2011;5(1):9-13.
 23. Gupta G, Aggarwal S, Phadke SR. Intracardiac echogenic focus and fetal outcome. *J Clin Ultrasound.* 2010;38(9):466-9.
 24. Ekin A, Gezer C, Taner CE, et al. The effect of associated structural malformations in the prediction of chromosomal abnormality risk of fetuses with echogenic bowel. *J Matern Fetal Neonatal Med.* 2016;29(1):41-5.
 25. Dagklis T, Plasencia W, Maiz N, Duarte L, Nicolaides KH. Choroid plexus cyst, intracardiac echogenic focus, hyperechogenic bowel and hydronephrosis in screening for trisomy 21 at 11 to 13 weeks. *Ultrasound Obstet Gynecol.* 2008;31(2):132-5.
 26. Kim MS, Kang S, Cho HY. Clinical significance of sonographic soft markers: A review. *J Gene Med.* 2018;15(1):1-7.
 27. Abbott MB, Vlasses CH. *Nelson textbook of pediatrics.* *Jama.* 2011;306(21):2387-8.