

# Aplasia Cutis Congenita Associated with the Use of Antithyroid Medications during Pregnancy: A Case Report

Pham Chi Kong<sup>1\*</sup>, Huynh Minh Nhat<sup>2</sup>, Le Ha Yen Chi<sup>3</sup>

1. Department of Delivery, Vice-Director of Da Nang Hospital for Women and Children, 402 Lê Văn Hiến, Khuê Mỹ, Ngũ Hành Sơn, Đà Nẵng, Vietnam

2. Department of Gynecology, Da Nang Hospital for Women and Children, 402 Lê Văn Hiến, Khuê Mỹ, Ngũ Hành Sơn, Đà Nẵng, Vietnam

3. Department of Dermatology, Đà Nẵng C Hospital, 122 Hải Phòng, Thạch Thang, Hải Châu, Đà Nẵng, Vietnam

## ABSTRACT

**Background:** Aplasia Cutis Congenita (ACC) is a rare malformation characterized by localized congenital absence of the skin which was first described by Cordon in 1767. ACC is estimated to occur in approximately 1 to 3 cases in 10000 live births. Many factors can contribute to developing ACC among which antithyroid medications were the strongest risk factor. A total of 61 cases of ACC were reported due to Methimazole/Carbimazole.

**Case report:** We report a female infant with ACC whose mother received Methimazole during pregnancy. Two small, punch-out lesions of the scalp were observed in diameters from 1.5 cm to 2 cm. The patient was treated with conservative care. Crusting and scab formation began on the fifth day. Minor, atrophied and hairless scars were found at the previous location of lesions by reexamining after 12 months.

**Conclusion:** The etiology of ACC has not yet been clearly defined. Methimazole may be a factor associated with this disorder. Management of ACC includes conservative care and surgery depending on the location and size of lesions, associated anomalies, and health of the infant.

**Keywords:** Antithyroid medications, Aplasia cutis congenita, Carbimazole, Methimazole, Pregnancy

## Introduction

Many congenital anomalies occur during intrauterine life. Aplasia Cutis Congenita (ACC) is a rare malformation characterized by the congenital absence of epidermis, dermis, subcutaneous tissues, and rarely bone or dura which was first reported by Cordon in 1767. Campbell noted the first case of ACC 60 years later. ACC is estimated to occur in approximately 1 to 3 cases in 10000 live births (1, 2).

Many factors can contribute to the development of ACC such as genetic factors, vascular lesions, trauma, neural tube defects, and teratogens (3, 4).

Milham and Elledge were the first authors to report ACC after exposure to Methimazole in 1972 (5). The first cases of ACC following exposure to Carbimazole were described later by Milham in 1985 (6). According to the case series and literature review of Sachs C et al. (2016), 61 cases

of ACC were reported under Methimazole/ Carbimazole (including 2 cases reported by these authors and 59 cases existed in the literature), however, the causal relationship between the antithyroid medications and ACC is still controversial (7). According to the literature, Methimazole, the antithyroid medication, is the strongest risk factor (1, 4).

No consensus exists on the optimal threshold and specific treatment algorithm for ACC. Management strategies include conservative care or surgery depending on several factors such as location and size of lesions, underlying causes, and associated anomalies (1, 8, 9).

We report an infant with ACC whose mother received Methimazole during pregnancy. To the best of our knowledge, this is the first case of ACC associated with intaking Methimazole during pregnancy in Vietnam. Since no history of similar

\* Corresponding author: Pham Chi Kong, Da Nang Hospital, 402 Lê Văn Hiến, Khuê Mỹ, Ngũ Hành Sơn, Đà Nẵng, Vietnam. Tel: +8402363957777; Email: kongpc@danang.gov.vn

Please cite this paper as:

Chi Kong P, Minh Nhat H, Ha Yen Chi L. Aplasia Cutis Congenita associated with the Use of Antithyroid Medications during Pregnancy: A Case Report. Iranian Journal of Neonatology. 2022 Apr; 13(2). DOI: [10.22038/IJN.2022.58139.2099](https://doi.org/10.22038/IJN.2022.58139.2099)

defects was observed in other siblings, a causal role was suspected for Methimazole.

### Case report

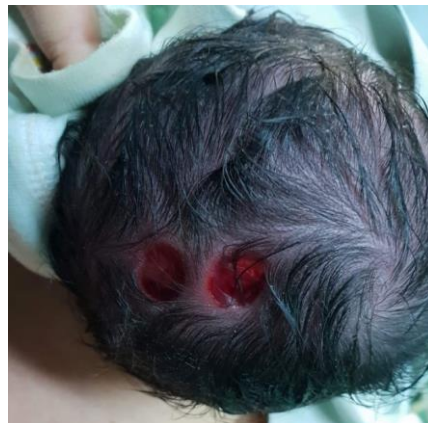We report a one-day-old female infant with ACC whose mother received Methimazole during pregnancy. The mother was a 25-year-old woman, gravida 2, para 1(C-section). In 2017, she received 20 mg of Methimazole daily to normalize hyperthyroidism. In 2018, an unintended pregnancy occurred for this woman, yet she continued to use Methimazole during all three trimesters of her pregnancy, and the ultrasound result indicated a 12-week intrauterine pregnancy. Her pregnancy was not eventful. Ultrasound scans performed at 22 and 34 weeks of gestation indicated satisfactory fetal growth and no congenital anomaly was detected. At 40 weeks of gestation, it was decided to perform C-section as the old scar was under 2 years. A live female infant was delivered (with an Apgar score of 9) whose parents presented no consanguinity or known medical problems.

Two small, punch-out lesions of the scalp were observed on the baby's head. The defects were observed at the vertex arranged in the form of two lesions, located on 1.5 cm right of the midline, varying in diameter: 1.5 to 2 cm and round to oval in

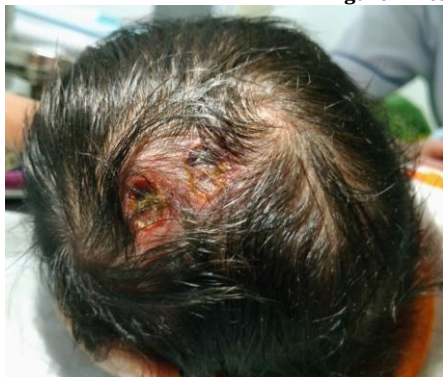shape. The margins were well demarcated and the surrounding skin was normally covered with hair. No gap in the underlying bone and bleeding was noted, and the bottom of the lesions was wet (Figure 1).

Following the clinical diagnosis of ACC, the neonatology department staff only instructed the infant's parents to examine the progress of the skin lesions. Skin biopsy was denied by the parents. No signs of infections and/or hemorrhages, skull defects, or other abnormalities (which could be detected using ultrasound) were not found in the following days. Povidone-iodine and normal saline were used in the local wound care treatment. On the first day, we diluted povidone-iodine and normal saline in a ratio of 1:10, respectively. Then we used this solution to clean the lesion and applied a thin layer of topical antibiotic cream (Fusidic acid) to them. Four days later, we only used normal saline to clean and continue applying topical antibiotic cream. Crusting and scab formation began on the fifth day (Figure 2).

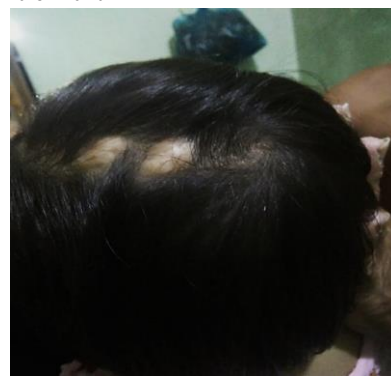
A follow-up examination was performed after 12 months and two small round, white, well-demarcated, atrophic, hairless lesions, 1-1.5 cm in diameter were detected on the vertex at the location of the former defect (Figure 3).



**Figure 1.** Lesions in a one-day-old female infant



**Figure 2.** Crusting and scab formation on the lesions (the 5th day)



**Figure 3.** 12 months later

## Discussion

Approximately 500 cases of ACC have been reported worldwide as of 2013 (2). Most cases of ACC (84%) locate in the scalp, of which 75% are single and most are located in the midline (10). In 1986, Frieden classified ACC according to the location of the lesion and the related anomalies which is still valid for reference. Nine groups of ACC exist in Frieden's classification: Groups 1-3 indicate Scalp ACC without multiple anomalies, with limb abnormalities, and with epidermal and organoid nevi; groups 4-6 list ACC associated with congenital malformations, fetus papyraceus of placental infarcts, and epidermolysis bullosa; Three last groups classify ACC localized to extremities without blistering; resulted from specific teratogens and malformation syndromes (11).

Various mechanisms, including intrauterine trauma, vascular compromise, infection, and medications (e.g. in utero exposure to valproic acid and antithyroid medications) are associated with the pathophysiology of ACC. Star-shaped or angled sides lesions are argued to occur with vascular abnormalities or intrauterine ischemia. Additionally, reported cases associated with autosomal dominant and less commonly autosomal recessive might prove that mutations in the ribosomal GTPase BMS1 could result in autosomal dominant ACC. In general, familial scalp ACC is nonmembranous while scalp ACC with a membrane is often irregular (1, 4, 10, 12).

Our case is classified in group 8 of Frieden's classification, which is caused by specific teratogens (Methimazole). Since no history of similar defects was observed in other siblings, a causal role was suspected for Methimazole. Synthetic antithyroid medications were the strongest risk factor associated with ACC (1, 4, 13). The most commonly used synthetic antithyroid medications are Propylthiouracil (PTU), Carbimazole, and Methimazole. Treatment of hyperthyroidism is essential as it can cause pregnancy complications (spontaneous miscarriage, premature birth, preeclampsia, heart failure, acute thyrotoxicosis) and fetal complications (birth defects, premature birth, intrauterine growth restriction, low birth weight, neonatal hyperthyroidism) (13). The potential cause of treatment with antithyroid medications that resulted in congenital anomalies was first described 50 years ago. Current evidence confirms that the risk of congenital malformations may be associated with exposure to Methimazole which may be severe. Concerning Propylthiouracil,

further studies are required to determine its teratogenic role (14). A meta-analysis by Song R et al. (2017) revealed that the use of Methimazole (MMI)/ Carbimazole (CMZ) is only associated with an increased risk of congenital malformations in prenatal development, as opposed to the absence of antithyroid medication treatment (OR 1.88; 95%CI 1.33 to 2.65;  $P = 0.0004$ ). No difference was observed between exposure to Propylthiouracil (PTU) and non-exposure to antithyroid medications during pregnancy (OR 0.81; 95%CI 0.58 to 1.15;  $P = 0.24$ ). Exposure to MMI/CMZ only during pregnancy significantly increases the risk of congenital malformations compared to that associated with exposure to PTU (OR 1.90; 95%CI 1.30 to 2.78;  $P = 0.001$ ) (15). Another systematic review and meta-analysis by Morales D et al. published in March 2021, indicated that previous meta-analyses overestimated the risk of congenital anomalies associated with the use of antithyroid medications during pregnancy due to bias. The risk of congenital anomalies in the group exposed to Propylthiouracil (adjusted risk ratio 1.16; 95% confidence interval 1.08–1.25) may be comparable to that in the untreated hyperthyroid group (adjusted risk ratio 1.15; 95%CI 1.02–1.29) which is lower than that in the group exposed to Methimazole/Carbimazole (adjusted risk ratio 1.28; 95%CI 1.06–1.54) (16). These meta-analyses indicated no specific risk of birth defects associated with antithyroid medications used during pregnancy.

In 2016, Sachs C et al. reported case series and a literature review. Results indicated 61 cases of ACC related to Methimazole/Carbimazole (2 cases reported by these authors and 59 cases existed in the literature). The noted lesions were characterized by isolation, minor in size, and located on the median scalp area. Exposure to the medications occurred during the early weeks of pregnancy (7).

The diagnosis of ACC is primarily based on clinical findings and examination. The biopsy usually fails to indicate the abnormality (17). In our case, the diagnosis was based on clinical findings and no biopsy was performed due to the opposition of the parents. The lesion in our patient is located on the scalp which is the most common site of ACC (84%) (18). Histological findings were described in very few reports as the diagnosis was based on clinical manifestations and examination. Histological findings of ACC are characterized by an absence of epidermis and dermis and the reduction of

subcutaneous tissue to the depth of muscle and fascia (19).

A consensus or algorithm for treating ACC has not yet been obtained due to the rarity of this malformation. Methods of treating ACC include conservative care and surgery. Choosing the method of treatment should be individualized based on the location and size of the lesion, associated abnormalities, risk of complications, and medical status of the infant. Conservative management includes daily wound cleansing and dressings change as well as the use of systemic antibiotics. The mean time to recovery in conservative management is 27.9 days. Surgical management consists of excision and closure, skin grafting, local flaps, and tissue expansion (1, 12). A conservative approach has been usually indicated for small scalp defects ( $\leq 1$  cm in diameter with intact dura, no sagittal sinus involvement, and no large vascular malformation). However, this approach is now also indicated for larger lesions with or without bone involvement and many cases of successful conservative management of large scalp defects with or without bone involvement were reported (20). Li et al. proposed the following treatment algorithm for ACC: urgent surgery is performed if the lesion is accompanied by a dural defect or a large vein is exposed. Conservative treatment should be first used even for larger lesions if the dura is intact. A skin allograft may be prescribed if the lesion size does not decrease after 3-5 days or the wound healing rate is slow (21). A conservative approach was performed on our patient as the size of lesions was relatively small (1.5-2.0 cm in diameter) and without bone involvement. Re-examination after 12 months indicated only a small, median scalp area, hairless scar of 1.5 cm in diameter, at the location of the former defects. The atrophic hairless scar can lead to cosmetic problems for the patient. Some researchers have used topical minoxidil to stimulate hair growth, however, the outcomes have not been promising (8). Further studies are required to solve this cosmetic problem.

## Conclusion

ACC is rare and its etiology has not yet been clearly defined. Methimazole may be a factor related to this disorder. Management of ACC includes conservative care and surgery depending on the location and size of lesions, associated anomalies, and health of the infant. In our case, conservative management is preferred to other treatments.

## Acknowledgments

The authors affirm that the patient's family provided informed consent for the publication of the present study.

## Conflicts of interest

The authors declare that there is no conflict of interest regarding the publication of the present study.

## Authors' contributions

PC Kong wrote the first draft of the paper. HM Nhat and LHY Chi collected the patient's information. PC Kong reviewed the literature. All authors contributed to revising the manuscript and approving the final submission.

## Funding

The authors received no financial support for the research, authorship, and publication of this article.

## References

1. Blionas A, Giakoumettis D, Antoniadis E, Drosos E, Mitsios A, Plakas S, Sfakianos G, Themistocleous MS. Aplasia cutis congenita: Two case reports and discussion of the literature. *Surg Neurol Int.* 2017;8:273.
2. Mukhtar-Yola M, Mshelia L, Mairami AB, et al. Aplasia cutis congenita: a report of two cases from National Hospital Abuja, Nigeria and review of the literature. *Pan Afr Med J.* 2020;36:291.
3. Dahmardehei M. A rare case of aplasia cutis congenita. *Acta Med Iran.* 2013;51(5):341-4
4. Cohen MI, Ribeiro JT, Costa CA, Westphal FL. Aplasia Cutis Congenita. Case report and literature review. *J Bras Neurocir.* 2019;30(3):105-111.
5. Milham Jr S, Elledge W. Maternal methimazole and congenital defects in children. *Teratology.* 1972;5: 125-126.
6. Milham Jr S. Scalp defects in infants of mothers treated for hyperthyroidism with methimazole or carbimazole during pregnancy. *Teratology.* 1985;32:321.
7. Sachs C, Tebacher-Alt M, Mark M, Cribier B, Lipsker D. Aplasia cutanée congénitale et antithyroïdiens de synthèse au cours de la grossesse : série de cas et revue de la littérature [Aplasia cutis congenita and antithyroid medications during pregnancy: Case series and literature review]. *Ann Dermatol Venereol.* 2016;143(6-7):423-35.
8. Yang MY, Ha DL, Kim HS, Ko HC, Kim BS, Kim MB. Aplasia cutis congenita in Korea: Single center experience and literature review. *Pediatr Int.* 2020;62(7):804-809.
9. Lei GF, Zhang JP, Wang XB, et al. Treating aplasia cutis congenita in a newborn with the combination of ionic silver dressing and moist exposed burn

- ointment: A case report. *World J Clin Cases*. 2019;7(17):2611-2616.
10. Eghbalian F. Aplasia Cutis Congenita after Methimazole Exposure in Utero; A case Report and Literature Review. *Iran J Pediatr*. 2007;17(3): 293-296.
  11. Frieden IJ. Aplasia cutis congenita: A clinical review and proposal for classification. *J Am Acad Dermatol*. 1986;14(4):646-60.
  12. Humphrey SR, Hu X, Adamson K, Schaus A, Jensen JN, Drolet B. A practical approach to the evaluation and treatment of an infant with aplasia cutis congenita. *J Perinatol*. 2018;38(2):110-117.
  13. Kojmane W, Atmani S. Aplasia cutis congenita suite à une exposition in utero au carbimazole [A case of aplasia cutis congenita following in utero exposure to carbimazole]. *Ann Dermatol Venereol*. 2020; 147(1):76-77.
  14. Andersen SL, Andersen S. Antithyroid drugs and birth defects. *Thyroid Res*. 2020; 13:11.
  15. Song R, Lin H, Chen Y, Zhang X, Feng W. Effects of methimazole and propylthiouracil exposure during pregnancy on the risk of neonatal congenital malformations: A meta-analysis. *PLoS One*. 2017;12(7):e0180108.
  16. Morales DR, Fonkwen L, Nordeng HME. Antithyroid drug use during pregnancy and the risk of birth defects in offspring: systematic review and meta-analysis of observational studies with methodological considerations. *Br J Clin Pharmacol*. 2021;87(10):3890-3900
  17. Arslanca SB, Arslanca T, Koç A. Aplasia cutis congenita: a case report. *J Obstet Gynaecol*. 2019;39(6):860-861.
  18. Perry BM, Maughan CB, Crosby MS, Hadenfeld SD. Aplasia cutis congenita type V: a case report and review of the literature. *Int J Dermatol*. 2017;56(6):e118-e121.
  19. Gassenmaier M, Bösmüller H, Metzler G. Aplasia cutis congenita of the scalp: Histopathologic features and clinicopathologic correlation in a case series. *J Cutan Pathol*. 2020;47:439-445.
  20. Barcot Z, Baskovic M, Car A, Juric M. Aplasia cutis congenita of the scalp: The success of conservative approach in treatment of a large defect. *Indian J Paediatr Dermatol*. 2019;20:166-8.
  21. Lee YJ, Kim SA, Moon SH. An Aplasia Cutis Congenita: Suggestion of Management Algorithm. *J Craniofac Surg*. 2019;30(8):2493-2496.