

Versatility of V-Y Flap in Gluteal Area

Ahmed El-Sabbagh*

Department of Plastic Surgery, Faculty of Medicine, Mansoura University, Mansoura City, Egypt

ABSTRACT

BACKGROUND

Lesions in perineal area are common. The usual treatment is coverage by skin graft and flaps which may be local, pedicled or free types. In this paper V-Y flaps were used to cover the defects.

METHODS

V-Y flaps were used in the gluteal area in 15 patients. Lesions were due to different causes.

RESULTS

Of 15 patients, 11 were males and 4 were females. Their ages ranged from 3 weeks to 52 years old. Two cases were due to myelomeningocele, necrotizing fasciitis (2 cases) and the rest were due to bed sores (11 cases). The flaps were located over the trochanter (3 cases), ischial (6 cases) and sacral (6 cases). Good healing and durable coverage were obtained in all cases except one case.

CONCLUSION

V-Y flap as a working horse flap is recommended in the gluteal area.

KEYWORDS

Gluteal area; Lesions; V-Y design

Please cite this paper as:

El-Sabbagh A. Versatility of V-Y Flap in Gluteal Area. World J Plast Surg 2016;5(2):154-159.

INTRODUCTION

Lesions in gluteal area secondary to congenital, traumatic, infectious, neurologic or ablative surgeries require reconstructive procedures. Different techniques have been described utilizing all the reconstructive ladder.¹⁻³ The use of local flaps is not a simple procedure. Availability of a pedicle near by the defect with an adequate territory to cover and fill the defect without donor defect is not the common scenario.

The V-Y advancement flap was credited by Dieffenbach in 1845. Later, changes made to the design including the triangular form, opposed shape, multiple flaps, and a Pacman flap design.⁴⁻⁶ Also, V-Y flap may be part of other flaps like the Manta Ray flap, five flap or cone flap.⁷⁻⁹ The V-Y advancement flap has been used extensively in face, trunk, and limb reconstruction.¹⁰⁻¹² The aim of this study was to optimize the use of V-Y flaps for reconstruction of the gluteal area with closure of donor site primarily in one stage procedure.

*Corresponding Author:

Ahmed El-Sabbagh, MD;
Assistant Professor of Department of Plastic Surgery,
Faculty of Medicine, Mansoura University,
Mansoura City, Egypt
E-mail: elsabbagh17@hotmail.com
Received: August 22, 2015
Revised: November 11, 2015
Accepted: December 12, 2015

MATERIALS AND METHODS

Between October 2012 and August 2015, fifteen patients were operated with V-Y flap for lesions in perineal areas. Each patient received a full surgical explanation and a written consent was obtained. A separate informed consent for photography was obtained from all patients. The lesion was carefully cleaned and all diseased tissues and bursa were excised. Any bony prominence was carefully removed. V-Y flap was used unilaterally or bilaterally according to the size of the defect.

The perforator was identified by the help of Doppler probe and the fascia was incised to the underlying muscle. The distal edge of the rotation flap was de-epithelialized and buried under the distal edge of the defect to ensure complete filling and obliteration of the defect. Cone flaps were used for trochanteric defects. Starting with the first component of the cone flap, as a rotation flap to cover the primary defect. The second component was a V-Y flap to close the donor site (Figure 1).

For ambulatory patients, full mobilization were allowed after the 10th postoperative operative day. Suction drains were removed when the drainage amount decreased below 25 ml per day. The cases were followed up

twice during the first 2 weeks. After the 1st month, patients were followed every month for 6 months. This study has been performed in accordance with the ethical standards set forth in the 1964 Declaration of Helsinki and its later amendments. Informed consent was obtained from all parents responsible for participants included in the study.

RESULTS

Of 15 patients, 11 were males and 4 were females. Their ages ranged from 3 weeks to 52 years old. Two cases were due to myelomeningocele, necrotizing fasciitis (2 cases) and the rest were due to bed sores (11 cases). The flaps were located over the trochanter (3 cases), ischial (6 cases) and sacral (6 cases). V-Y (Unilateral or bilateral) or cone flap was used sufficiently for closure of the defect in every patient. Median operative time was 60 min (45–90 min) for the unilateral V-Y or cone flap and 90 min (60–120 min) for the bilateral V-Y flap group. None of the patients developed flap necrosis, local hematomas or seromas except one case (Figures 1-4).

A 42 year-old overweight woman presented with big sacral bed sore occupying the entire buttock associated with bilateral trochanteric

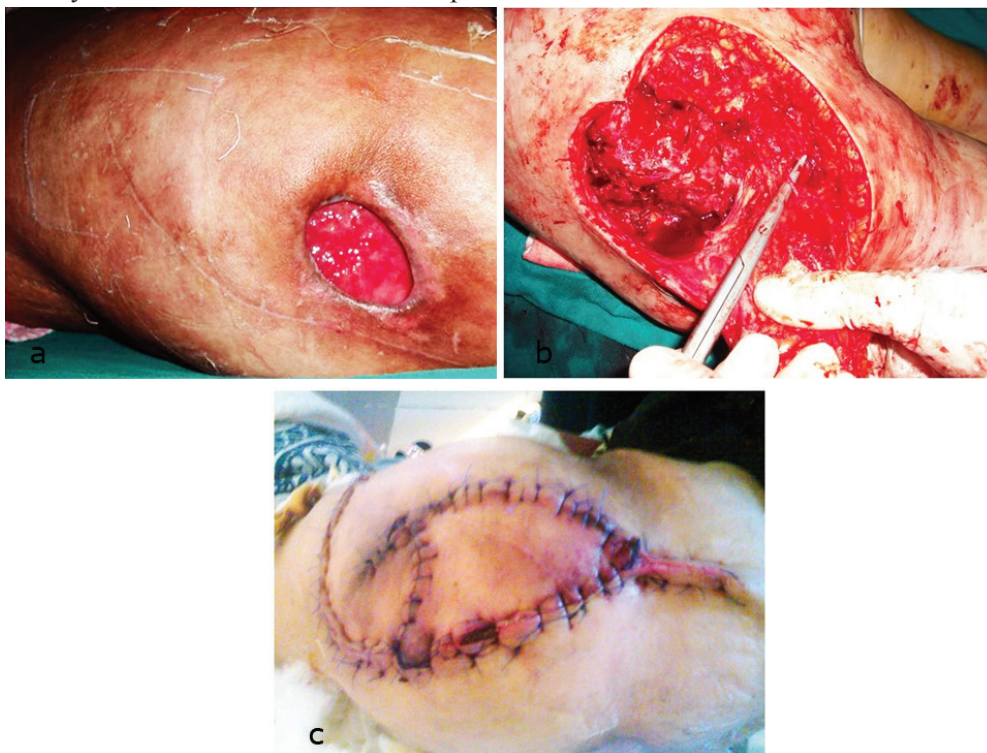

Fig. 1: a. Patient with trochanteric pressure sore, b. Elevation of the rotation flap on its pedicle, c. Postoperative with complete healing of the flap

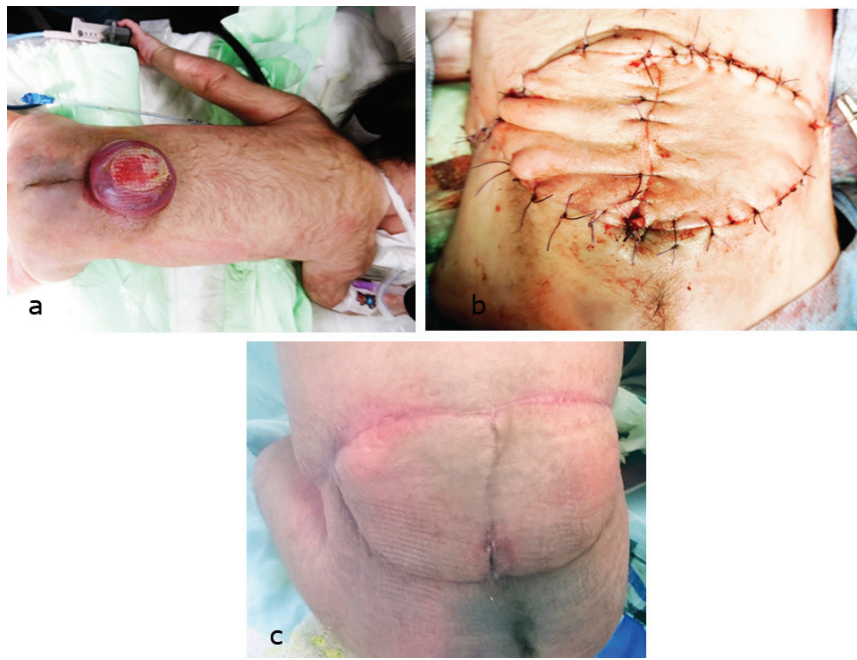

Fig. 2: a. 3 weeks old boy with myelomeningocele, b. Early postoperative, c. 6 months postoperative.

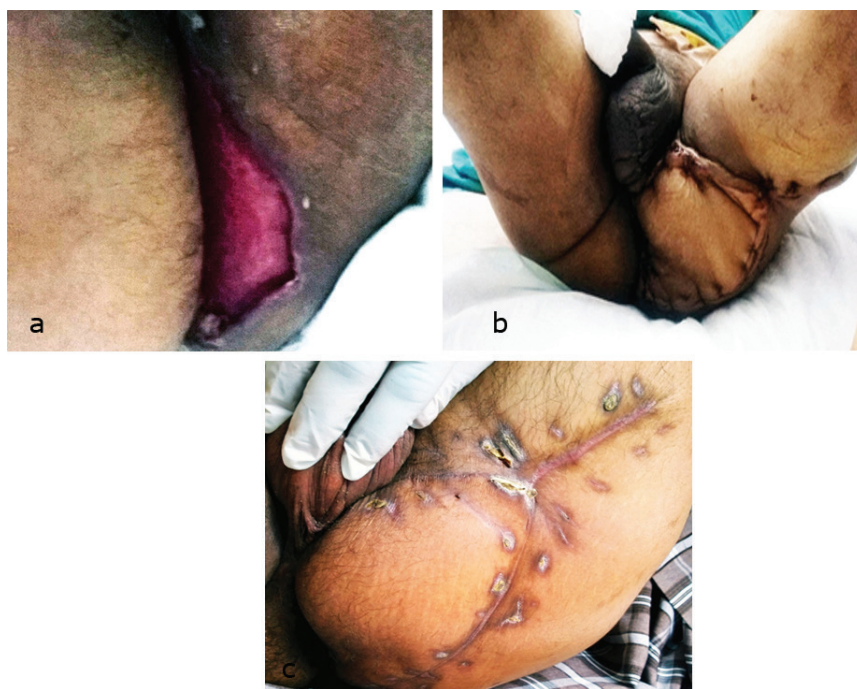

Fig. 3: a. Patient with wound in ischial area after necrotizing fasciitis, b. Early postoperative, c. 6 months postoperative

pressure sore. The patient was diabetic (on oral hypoglycemic) and paraplegic (history of stroke with previous deep venous thrombosis). The patient underwent bilateral V-Y flaps to cover the sacral pressure sore. After one week, the patient started to develop disruption in the center of the wound. Then, for successive 3 weeks, flap necrosis, seromas and hematomas developed in the wound. The wound was managed conservatively

till infection subsided with complete disruption of the wound (Figure 5).

DISCUSSION

One of the distinct differences in gluteal reconstruction compared with lower extremity reconstruction is the effectiveness of local pedicled flaps in this region.¹³ The gluteal area

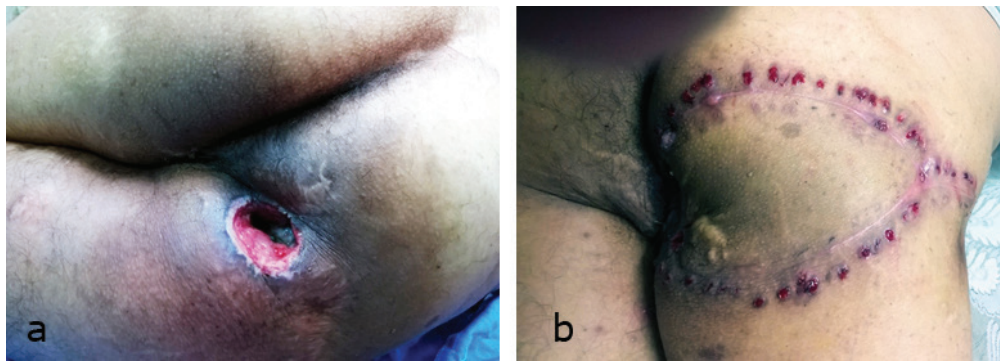


Fig. 4: a. Patient with ischial pressure sore, b. Postoperative with complete healing of the flap

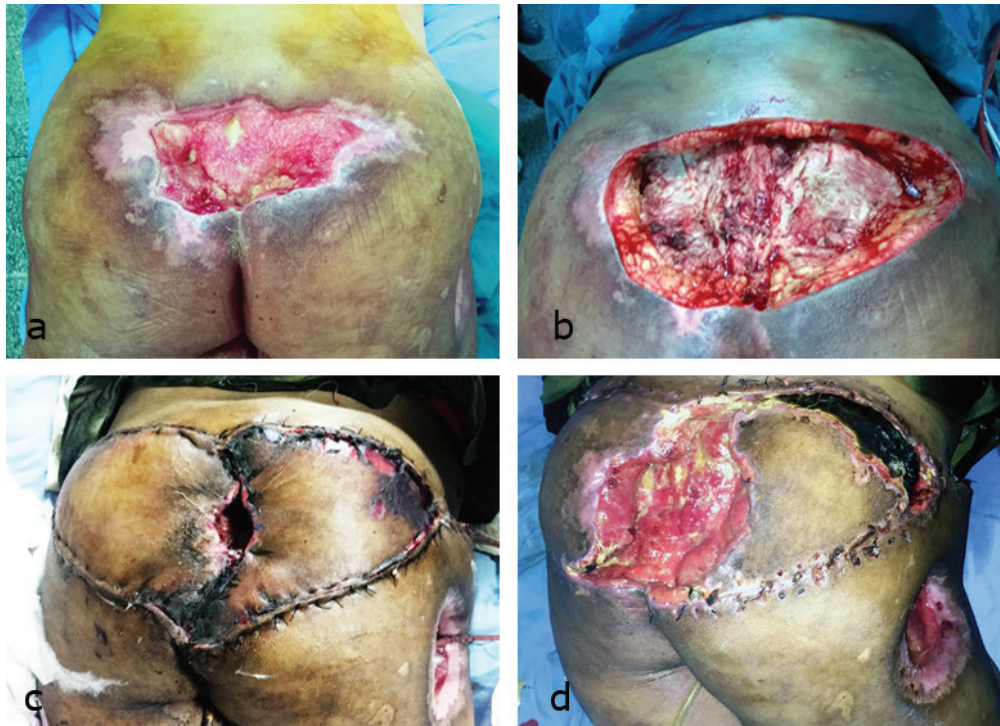


Fig. 5: a. Patient with extensive sacral pressure sore, b. Sore after debridement, c. Disruption in the center of the wound (1 week postoperative), d. Complete disruption of the flap with partial flap necrosis (2 weeks postoperative).

is liable to considerable pressure in all positions (sitting and recumbent). Even during walking, motions can make tension across the incision lines. Urinary and fecal contamination add additional risk factor for wound healing.¹⁴

The gluteus maximus muscle is the commonest flap. It can be designed as an advancement, rotation flap, island flap, or split flap. The decision depends on the size of the defect. Also, the superior gluteal artery flap had been used. However, this flaps needs learning curve and cannot be used again in recurrent cases.¹⁵⁻¹⁷ The gracilis muscle flap has its place for reconstruction of ischial area. It can be used as a vascular conduit for the skin island or the muscle itself can be used with some modification.^{18,19}

Like other flaps, it cannot be used again and confined to the ischial area.

As regard the tensor fascia latae flap, it was used extensively for the trochanteric area.²⁰ Possibility of skin graft to the donor site, limited arc of rotation and cannot be used again are limitations for its use. In this work, Cone flap was ideal for the trochanteric area, where the donor site is a problem due to presence of septa. Closure of the defect with a rotational flap based on an audible perforator without any tension is mandatory for successful reconstruction. Then the V-Y flap was harvested secondarily for closure of the donor site. by adapting this policy, possibility of disruption due to tension became minimal.

Actually, fasciocutaneous flaps better used in

males. The abundant fat in females may impair blood supply and delay healing. Moreover, co morbid conditions which are the primary causes for most of the lesions in the perineal area, add more difficulty to the wound healing process (Figure 5).

Repair strength varies considerably with the repair method, including blood supply, size and design of the flap. V-Y advancement flap is easier to execute. The flap has an excellent blood supply (based on a perforator with no tension in closure), filling and obliteration of the defect and can be raised safely without dissecting of the pedicle and filling and obliteration of the defect. It is a robust flap, which can be quickly harvested, and has got a lesser learning curve.

Despite the limited number of patients, this technique is simple and reliable and offers an effective and elegant alternative to the more classic operations for problematic wounds in lower limb as it has the advantage of being tension-free closure without leaving dead space and no need for drains, thus increasing patient comfort and wound healing, and decreases the length of hospital stay with early return to work.

Careful planning of the flap and hearing of perforators by Doppler probe is mandatory. The night before operation, three successive rectal enema after light super are needed. Purse string suture around the anal verge with 1 silk suture is the first step to prevent fecal contamination of field. After elevation of the flap, intraoperative Doppler is used for confirmation of blood supply to the flap. No undermining is made to close the vertical limb of the V-Y flap. Creation of potential spaces may lead to collection and wound disruption. Save the time and improve healing by suturing the flap in one layer. Any sutures included the fatty layer or fascia may impair vascularity and produce fat necrosis and wound infection in consequence.

Constipating measures and avoidance of pressure on the flap for the first 10 days are very important for successful outcome. Drains removed when the amount is less than 25 ml and clear yellow in color. Treatment of the wound like an abscess rather than a surgical wound is a unique character of this area. In summary, Time-honored principles of replacing like with like and delivering well-vascularized tissue remain for defects in the perineal area. Filling and obliteration of the cavity is the cornerstone for good healing and minimizing recurrence of

the lesion.

The ideal reconstruction is not by doing free flaps or by using advanced expensive tools but by providing simple, durable coverage with less morbidity to donor and recipient sites. Pedicled flaps has the upper hand for reconstruction in the gluteal area. Design of the flap as a V-Y ensures safe coverage with closure of donor site primarily.

CONFLICT OF INTEREST

The authors declare no conflict of interest.

REFERENCES

- 1 Chen TH. Bilateral gluteus maximus V-Y advancement musculocutaneous flaps for the coverage of large sacral pressure sores: revisit and refinement. *Ann Plast Surg* 1995;**35**:492-7.
- 2 Siclovan HR, Azar S. Use of bilaterally pedicled V-Y advancement flap for reconstruction of the nose. *Aesthetic Plast Surg* 2008;**32**:576-8.
- 3 Hayashi A, Maruyama Y. Bilateral latissimus dorsi V-Y musculocutaneous flap for closure of a large meningocele. *Plast Reconstr Surg* 1991;**88**:520-3.
- 4 Akan IM, Ulusoy, MG, Bilen BT, Kapucu MR. Modified bilateral advancement flap: The slide-in flap. *Ann Plast Surg* 1999;**42**:545.
- 5 Aoki R, Pennington DG, Hyakusoku H. Flap-in-flap method for enhancing the advancement of a V-Y flap. *Plast Reconstr Aesthetic Surg* 2006;**59**:653-7.
- 6 Aoki R, Hyakusoku H. Pacman flap method. *Plast Reconstr Surg* 2007;**119**:1799-802.
- 7 Coombs CJ, Thomas DJ. The Manta Ray flap: a technique for first web space release. *Tech Hand Up Extremity Surg* 2010;**14**:41-5.
- 8 Ersoy B. A new flap design for release of parallel contracture bands: dual opposing five-flap z-plasty. *Burns* 2014;**40**:69-70.
- 9 El-Sabbagh AH. How to do coverage of pre patellar lesions by cone flaps. *Update Plast Surg* 2011;**4**:61-4.
- 10 Pontes L, Ribeiro M, Vrancks JJ, Guimaraes J. The new bilaterally pedicled V-Y advancement flap for face reconstruction. *Plast Reconstr Surg* 2002;**109**:1870-4.
- 11 Micali E, Carramaschi FR. Extended V-Y latissimus dorsi musculocutaneous flap for anterior chest wall reconstruction. *Plast Reconstr Surg* 2001;**107**:1382-90.

- 12 Niranjan NS, Price RD, Govilkar P. Fascial feeder and perforator-based V-Y advancement flaps in the reconstruction of lower limb defects. *Br J Plast Surg* 2000;**53**:679-89.
- 13 Hollenbeck ST, Toranto JD, Taylor BJ, Ho TQ, Zenn MR, Erdmann D, Levin LS. Perineal and lower extremity reconstruction. *Plast Reconstr Surg* 2011;**128**:551-63.
- 14 Rubayi S, Chandrasekhar BS. Trunk, abdomen, and pressure sore reconstruction. *Plast Reconstr Surg* 2011;**128**:201-5.
- 15 Chen TH. Bilateral gluteus maximus V-Y advancement musculocutaneous flaps for the coverage of large sacral pressure sores: Revisit and refinement. *Ann Plast. Surg*, 1995;**35**:492.
- 16 Ulusoy MG, Koc, Er U, Sungur N, Karaaslan O, Kankaya Y, Ozdemir R, Gümüş M. Closure of meningocele defects with bilateral modified V-Y advancement flaps. *Ann Plast Surg* 2005;**54**:640-4.
- 17 Verpaele AM, Blondeel PN, Van Landuyt K, Tonnard PL, Decordier B, Monstrey SJ, Matton G. The superior gluteal artery perforator flap: An additional tool in the treatment of sacral pressure sores. *Br J Plast Surg* 1999;**52**:385-91.
- 18 Labandter HP. The gracilis muscle flap and musculocutaneous flap in the repair of perineal and ischial defects. *Br J Plast Surg* 1980;**33**:95-8.
- 19 El-Sabbagh AH. The accordion gracilis muscle flap: a new design for coverage of recurrent and complicated ischial pressure sores. *Int Wound J* 2011;**8**:447-53.
- 20 Siddiqui A, Wiedrich T, Lewis VL Jr. Tensor fasciae latae V-Y retroposition myocutaneous flap: Clinical experience. *Ann Plast Surg* 1993;**31**:313-317.