

# Saphenous Vein Graft for Treatment of Peyronie's Disease, a Comparison between Single and Multiple Graft Reconstruction

Kamyar Tavakoli Tabassi<sup>1</sup>, Mahdi Mottaghi<sup>2</sup>, Negar Nekooei<sup>3</sup>, Sanaz Salehi<sup>2</sup>,  
Atena Aghae<sup>4</sup>, Salman Soltani<sup>2\*</sup>

1. Department of Urology and Renal Transplantation, Imam Reza Hospital, Mashhad University of Medical Sciences, Mashhad, Iran
2. Kidney Transplantation Complications Research Center, Mashhad University of Medical Sciences, Mashhad, Iran
3. Student Research Committee, Faculty of Medicine, Mashhad University of Medical Sciences, Mashhad, Iran
4. Nuclear Medicine Research Center, Mashhad University of Medical Sciences, Mashhad, Iran

## ABSTRACT

**Background:** Surgical reconstruction is the gold standard of treatment for Peyronie's disease (PD). Grafting procedures provide satisfactory outcomes in patients with complex curvature, short penile length, and without previous erectile dysfunction (ED). We aimed to compare two different grafting methods of reconstruction in patients with PD.

**Method:** Fifty-two PD patients at Imam-Reza hospital of Mashhad from October 2011 to January 2019 with stable plaque, penile angulation of  $>60^\circ$ , complex curvature, and without ED who consented to cooperate, included in our study and divided into two groups. The first group consists of 26 patients, undergone grafting through a double-Y incision and a single saphenous graft placed within the incision. For the second group, two smaller saphenous vein grafts were placed in the two parallel incisions. ED assessed pre- and post-operational via the International index of erectile function. Penile angulation less than 20 degrees was considered a favorable outcome. Patients followed for 18 months, and sacculation, penile shortening, post-operation infection, and penile hypoesthesia were assessed as complications. We used a paired t-test to compare these two groups.

**Results:** ED was 25% and 12% in the first and the second group, respectively. Statistics showed no difference between the two groups regarding pre and post-operational ED ( $P=0.1$ ). Regarding complications during follow-up, sacculation occurred in four patients of the first group and none of the second group patients but no significant difference ( $P=0.23$ ).

**Conclusion:** We found no superiority to declare between these two procedures, although regarding the small sample size of our study, further evaluations are needed to establish more reliable results.

**Keywords:** Peyronie's disease; Grafting; Erectile dysfunction; Penile curvature; Surgical Procedure

### Please cite this paper as:

Tavakoli Tabassi T., Mottaghi M., Nekooei N., Salehi S., Aghae A., Soltani S. Saphenous Vein Graft for Treatment of Peyronie's Disease, a Comparison between Single and Multiple Graft Reconstruction. *World J Plast Surg.* 2022;11(2):62-67.

doi: 10.52547/wjps.11.2.62

### \*Corresponding Author:

Salman Soltani

Kidney Transplantation Complications Research Center, Mashhad University of Medical Sciences, Mashhad, Iran

Email: [soltanis@mums.ac.ir](mailto:soltanis@mums.ac.ir)

Received: 21 Oct 2021

Accepted: 15 Feb 2022

## INTRODUCTION

Peyronie's disease (PD) is a fairly common condition with a 2-8.9% prevalence, which is likely underestimated due to the shame of declaring it<sup>1</sup>. PD is an acquired condition in which a fibrous plaque is formed by



This work is licensed under a Creative Commons Attribution-NonCommercial 4.0 International license (<https://creativecommons.org/licenses/by-nc/4.0/>). Non-commercial uses of the work are permitted, provided the original work is properly cited.

an unknown etiology and causes the penile shaft to deviate from its normal axis<sup>2</sup>. Risk factors include trauma, hypertension, diabetes, dyslipidemia, coronary arterial disease, psychological disorders, smoking, and previous urologic surgeries<sup>2</sup>.

Patients complain of discomfort during intercourse, pain (especially during erection), palpable plaques, and erectile dysfunction (ED)<sup>1</sup>. The disease has two phases; acute and chronic. The acute phase is characterized by penile pain and inflammation, which lasts up to 18 months<sup>3</sup>. The eventual result of this inflammation is a penile deformity, and surgical interventions are prohibited during this period. When the fibrous plaque stabilizes, the disease enters its chronic phase<sup>4</sup>. In 13% of cases, resolution occurs spontaneously, but 30-50% of patients experience aggravation<sup>1</sup>. Surgery is the gold standard of treatment.

We aimed to compare two grafting techniques regarding their success rate and complications.

## MATERIALS AND METHODS

### Study design

This cohort study started at Imam-Reza Hospital of Mashhad University of Medical Sciences from October 2011 to January 2019. During this period, 125 patients with PD were referred to our tertiary hospital. The main complaint was penile deformity.

### Patient enrollment

Fifty-two patients were included for grafting surgery based on the penis size, degree of penile angulation, and patient's demand for fast, definite treatment. Inclusion criteria were considered as one of the following: severe penile angulation ( $>60^\circ$ ), penile length less than 13 centimeters, complex curvature (hinge- or hourglass-deformity). The presence of ED and pain (suggesting active phase of PD) is considered as exclusion criteria.

Written informed consent was taken from eligible participants. Mashhad University of Medical Sciences Ethics Committee approved this study under the ethical approval code: IR.MUMS.REC.fm.1395.589.

We randomly divided 48 patients into two groups, except four with hinge-deformity divided equally between two groups. Two sealed envelopes were prepared for randomization in the hospital examination room, either containing group-1 label

or group-2 label. During the last pre-operational visit, the patient was asked to choose one envelope; then, the surgical procedure was explained to him to give the patient data he needed for signing the informed consent. Then, automatically, the next patient was assigned to the other group. Blinding of the surgeon was not possible in our study. The first author performed all the surgeries. Blinding was also impossible in follow-up visits conducted by the corresponding author because the surgical scars were evident. However, we blinded the statistician by changing the group names before statistical analysis.

### Surgical technique

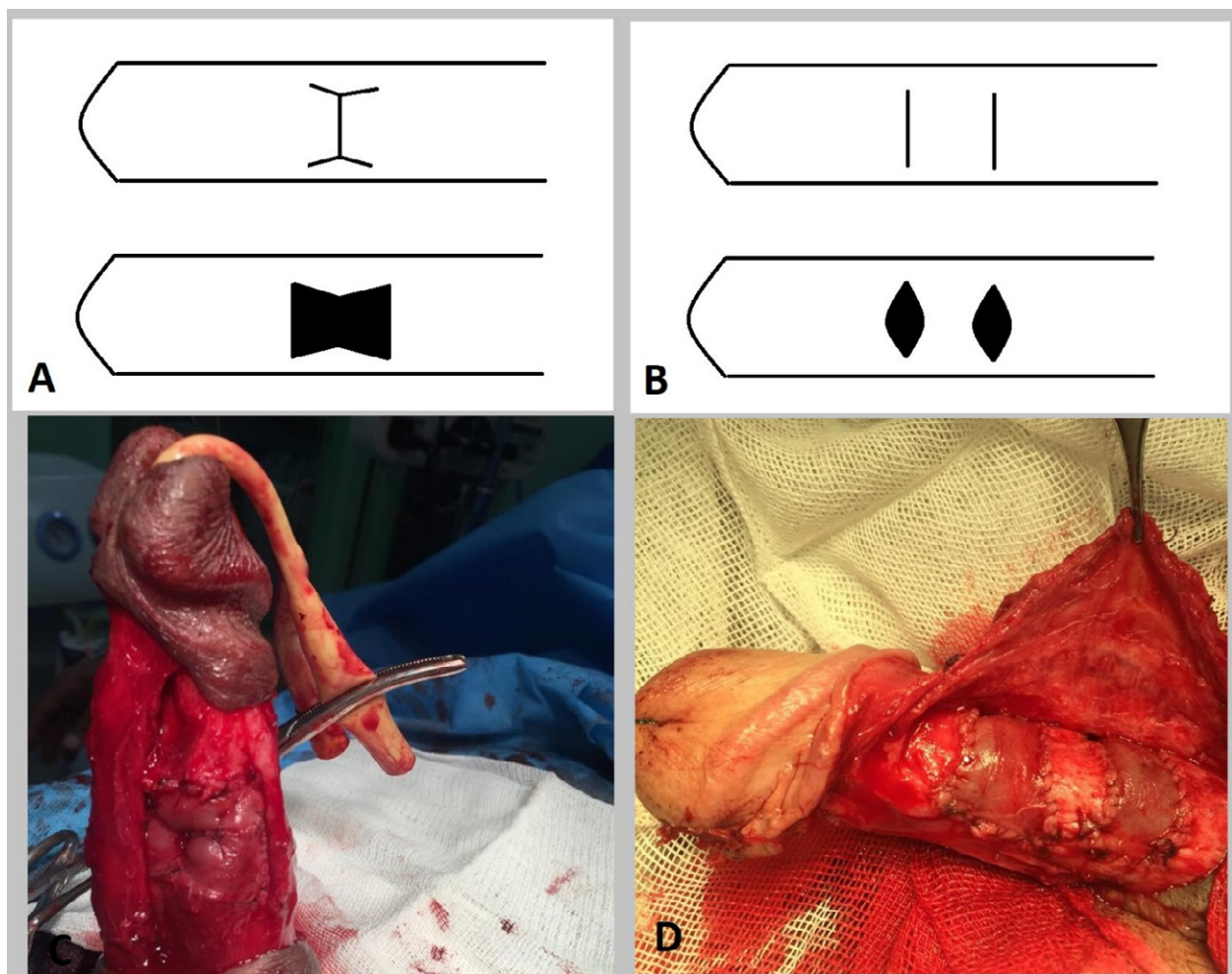
For both groups, a saphenous graft was harvested from the thigh's anterior surface. The width of the grafts was equal to the width of the harvested saphenous vein (usually less than 10 millimeters). A circumcision incision was performed, and penile skin was degloved followed by a complete or near-complete penile disassembly from the tip to the base of the penis (neurovascular bundle and corpus spongiosum). For group 1, one double-Y incision was made on tunica albuginea (TA). Then, two equal-length saphenous grafts were placed within the incision with its endothelial part facing the corpus cavernosum (Figure 1). For group 2, two transverse incisions were made. Then two pieces of one-layer saphenous grafts were placed (the total length of the used grafts were equal among the two groups, the difference between groups was that the grafts were placed together or separated). Then the TA sutured via a 4/0 polydioxanone suture. Penile curvature less than  $20^\circ$  was considered a successful outcome.

### Patient evaluation and Outcomes

We scheduled follow-up visits three and six months after the surgery and every six-month after that. In each follow-up visit, we assessed complications through physical examination and a 5-question International index of erectile function (IIEF-5) scale. Post-operation penile angulation less than 20 degrees considered as a favorable outcome

### Statistics

A paired *t*-test was used to compare each group's mean differences before and after the treatment. All values are presented as mean  $\pm$  standard deviation. We used SPSS software (Chicago, IL, USA). *P*-values less than 0.05 are considered significant.



**Figure 1:** A & C) Double-Y incision. B & D) two parallel incisions.

**Table 1:** Degree of angulation, mean follow-up duration, pre-, and post-IIEF scale

	Mean $\pm$ SD		P-value
	Group 1	Group 2	
Age (yr)	55.85 $\pm$ 8.0	53.81 $\pm$ 10.09	0.54
Degree of curvature	59.81 $\pm$ 15.32	60.58 $\pm$ 14.02	0.78
Pre-operation IIEF scale	20.27 $\pm$ 2.80	20.35 $\pm$ 2.68	0.92
Follow-up duration	18.5 $\pm$ 5.0	19.15 $\pm$ 4.8	0.56
Post-operation IIEF scale	17.92 $\pm$ 6.56	19.65 $\pm$ 4.39	0.91

## RESULTS

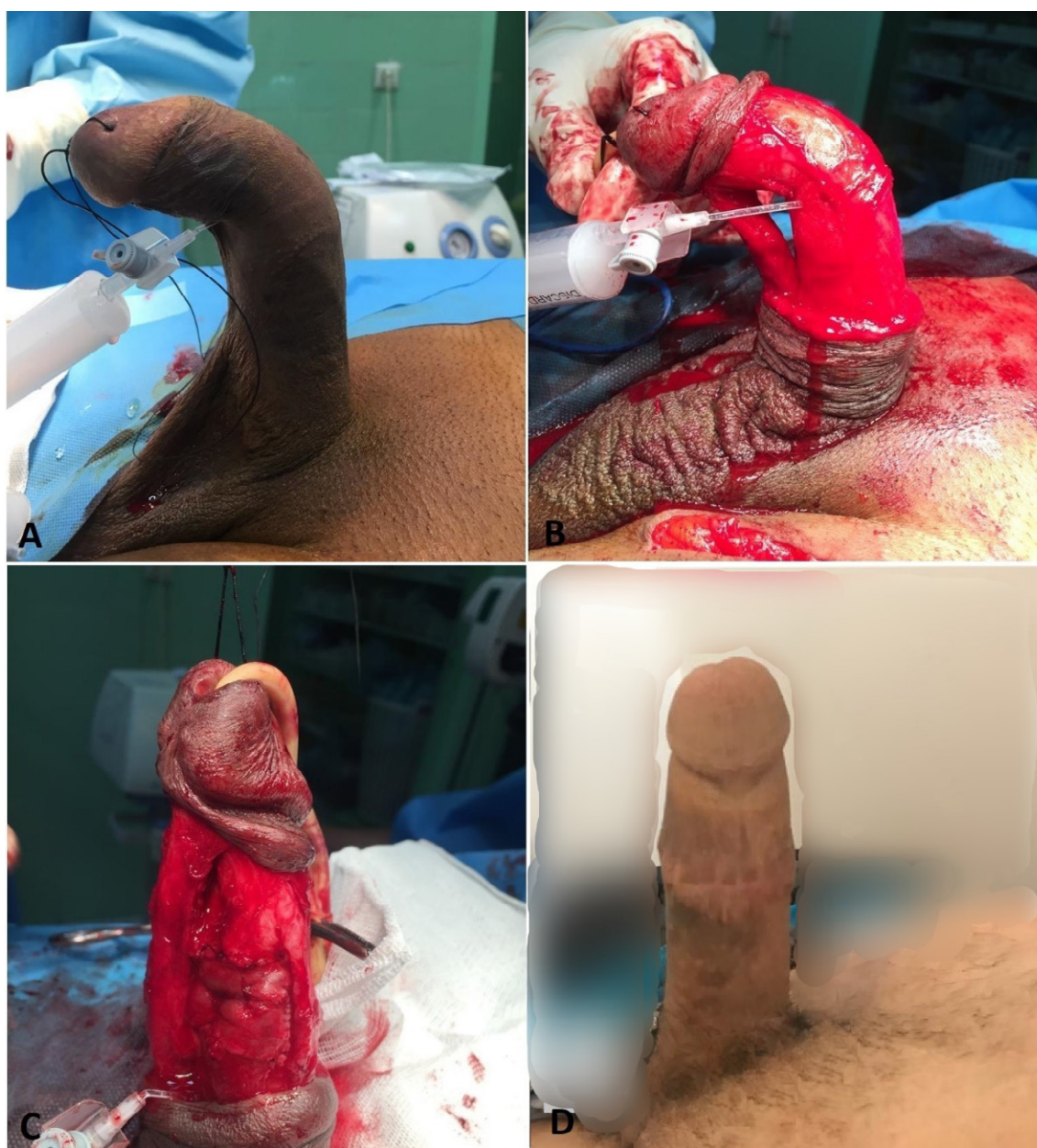In eight years, 52 patients with Peyronie's disease were included. Mean  $\pm$  SD age for groups 1 and 2 were 55.85  $\pm$  8 and 53.81  $\pm$  10.09, respectively. The dorsal deviation was detected in 50% of cases among both groups, followed by ventral and dorsal angulations. The degree of angulation, mean follow-up duration, pre-, and post-IIEF scale (after six

months of follow-up) are presented in Table 1. Mean  $\pm$  SD follow-up duration was 18.5  $\pm$  5 and 19.15  $\pm$  4.8 months for groups 1 and 2, respectively. The degree of deviation before the surgery was not statistically significant between the two groups. No operation-related complications, including bleeding, hematoma, and edema, were observed. ED after the surgery was 25% in group 1 and 12% in group 2; however, it was not statistically significant.



**Table 2:** Frequency of Complications, Erectile dysfunction (post-operational), and direction of curvature

		Number (%)		P-value
		Group 1	Group 2	
<b>Direction of curvature</b>	Dorsal	13(50.0)	13(50.0)	0.92
	Ventral	8(30.8)	7(26.9)	
	Lateral	5(19.2)	6(23.1)	
<b>Erectile dysfunction (post-operational)</b>	Absent	18(75.0)	22(88.0)	0.28
	Present	6(25.0)	3(12.0)	
	Sensation Loss	2(16.7)	2(18.2)	
<b>Complications</b>	Sacculation	4(33.3)	0(0.0)	0.73
	Shortening	5(41.7)	6(54.5)	0.11
	infection	1(8.3)	3(27.3)	0.61
	Overall	12	11	0.23



**Figure 2:** Pre-operational deviation. B) Artificial erection. C) The initial reduction of angle. D) After six months.

ED prevalence was about 2-times higher in the double-Y incision group. All of them underwent Doppler ultrasound assessment. Venous-occlusive dysfunction was reported for all of these patients. Owing to the vasculogenic nature of ED, all patients with this complication were considered for prosthesis device placement. Long-term follow-up for detecting complications like penile shortening, sacculation, post-operation infection, and decreased glans sensation are proposed in table 2 (A successful outcome was considered as penile curvature less than 20° (Figure 2)).

## DISCUSSION

Several non-surgical treatment options are proposed for Peyronie's disease (PD). Reassurance plus routine observations are the best options for patients with mild symptoms and satisfactory sexual life<sup>1</sup>. American Urology Association (AUA) strongly discourages the prescription of supplements for patients complaining of PD. The only indication for oral treatment is pain management, where NSAIDs are allowed<sup>5</sup>. Extracorporeal shock wave therapy (ESWT) is another dissuaded treatment based on a systematic review<sup>6</sup>. Intralesional injection of collagenase, clostridium histolyticum, and interferon-alpha help reduce the penile curvature; however, hyaluronic acid, verapamil, and corticosteroids failed to show efficacy<sup>7</sup>. Radiation therapy has been claimed to be useful for pain management and fibrous-plaque resolution<sup>8</sup>. Penile traction therapy (PTT) is not recommended alone, but it can be used as adjuvant therapy after surgical interventions<sup>9</sup>.

Surgery is indicated when the disease has passed the acute phase, the patient's sexual life is compromised, or the patient's demand for definite treatment. Plaque calcification is also another indication for surgery<sup>4,10</sup>.

Two surgical approaches are proposed to correct the penile anatomy based on the presence of erectile function. When erectile dysfunction exists, penile prosthesis implantation is required, which is out of the scope of this article<sup>2</sup>. Reconstruction techniques are advised when the erectile function is satisfactory (with or without medication)<sup>11</sup>. These techniques include plication and grafting methods (first shortens the convex aspect, latter elongates the concave side). The most popular plication

surgeries are Essed-Schroeder (most common and least invasive technique, far and near suturing of the convex aspect of TA), Nesbit procedure (ellipsoid excision of TA on the convex part), and Yachia/Modified Nesbit procedure (longitudinal incision followed by horizontal suturing)<sup>11</sup>. These methods are easy to perform with a high success rate. Still, they are not recommended in the presence of penile complex curvature, severe angulation (more than 60 degrees), hourglass-deformity, hinge-deformity, and penile length shorter than 13 centimeters<sup>11</sup>. In these situations, grafting is the gold standard of treatment. Various types of grafts are chosen based on surgeon experience and graft availability. The saphenous vein is the most common autologous graft used for grafting in PD<sup>10</sup>. It is generally preferred over buccal mucosa and dermal grafts. Allografts and xenografts also have shown favorable results but are unavailable in our country<sup>10,11</sup>. The discussion about which graft type is preferred is beyond the scope of this article. Several studies compared different graft materials, but we found only a few studies addressing different grafting techniques.

Grafting procedures usually are performed in a similar sequence, but the type of incision differs. Four types of TA incisions are proposed. Multiple transverse incisions, double Y-incision, H-incision, and Egidio<sup>12</sup>. With each incision, a unique defect on TA is made for being filled via a graft. None of these incisions is proven to be superior to the other<sup>11</sup>. We did not find any clinical comparisons between these types of this incision. We aimed to compare the first two types of straightening of the penis, erectile function, and post-operation complications. No difference was observed between the two techniques regarding the straightening of the curvature. Mean pre-operative curvature was about 60 degrees in both groups, corrected to less than 20 degrees. Choosing suitable suture material is crucial for penile straightening and obtaining the best cosmetic results. Most similar studies used polydioxanone sutures, which are absorbable to prevent palpable knots after surgery<sup>11</sup>.

Erectile dysfunction was 2-times more frequent in the double-Y incision group, but statistical meaningfulness was not achieved. Sacculation was not seen among the patients of the second group. Although the statistics showed no difference, we believe that increasing the sample size will produce more reliable results. A

comparison of the IIEF scale before and after surgery showed no statistical relationships between the two groups. We suggest performing a pre-operative doppler ultrasound which yields in better assessment of patients with post-operational ED.

Usual complications of grafting are sacculation, decreased penile sensation, penile shortening, and infection. All of these complications occurred similarly among these groups, and no statistical relationships were found.

To the best of our knowledge, this is the first study that compared mainly single versus multiple grafting techniques with different incisions. This study's limitations are its small sample size and not including other graft materials used in the surgical management of PD.

## CONCLUSION

The use of multiple transverse incisions has outcomes similar to the double-Y incisions. To achieve more reliable results, we suggest performing studies with more sample sizes.

## ACKNOWLEDGMENTS

We appreciate the supports of the Clinical Research Development Unit of Imam-Reza Hospitals.

## FUNDING

Self-funded.

## CONFLICT OF INTEREST

The authors declare that there is no conflict of interests.

## REFERENCES

- Cohen SD, Riu. Diagnosis and Treatment of Peyronie Disease With Both Dorsal and Ventral Plaques Using Doppler Ultrasound: NYU Case of the Month, July 2019. *Rev Urol* 2019;21(2-3):127.
- Kayigil O, Ozcan MF, Cakici O, UJA. The comparison of an acellular matrix graft with an autologous venous graft in the surgical treatment of Peyronie's disease. *Andrologia* 2019;51(1):e13168.
- Almeida JL, Felício J, Martins FE, JSMR. Surgical Planning and Strategies for Peyronie's Disease. *Sex Med Rev* 2020;9(3):478-487.
- García-Gómez B, González-Padilla DA, Alonso-Isa M, Medina-Polo J, Romero-Otero JJ, Joir. Plication techniques in Peyronie's disease: new developments. *Int J Impot Res* 2019:1-7.
- Nehra A, Alterowitz R, Culkin DJ, et al. Peyronie's disease: AUA guideline. *J Urol* 2015;194(3):745-53.
- Fojecki GL, Tiessen S, Osther P, JSJWJou. Extracorporeal shock wave therapy (ESWT) in urology: a systematic review of outcome in Peyronie's disease, erectile dysfunction and chronic pelvic pain. *World J Urol* 2017;35(1):1-9.
- Russo GI, Cacciamani G, Cocci A, et al. Comparative effectiveness of intralesional therapy for Peyronie's disease in controlled clinical studies: A systematic review and network meta-analysis. *J Sex Med* 2019;16(2):289-299.
- Eng TY, Abugideiri M, Chen TW, et al. Radiation Therapy for Benign Disease: Keloids, Macular Degeneration, Orbital Pseudotumor, Pterygium, Peyronie Disease, Trigeminal Neuralgia. *Hematology/Oncology Clinics* 2020;34(1):229-51.
- Haney NM, Kohn TP, Nichols PE, Hellstrom W, JJU. The effect of adjunct mechanical traction on penile length in men undergoing primary treatment for Peyronie's disease: A systematic review and meta-analysis. *Urology* 2018;122:110-5.
- Chung E, Ralph D, Kagioglu A, et al. Evidence-based management guidelines on Peyronie's disease. *J Sex Med* 2016;13(6):905-23.
- Rice PG, Somani BK, Rees RW, JSm. Twenty years of plaque incision and grafting for Peyronie's disease: a review of literature. *Sex Med* 2019;7(2):115-128.
- Miranda AF, Sampaio F, JTjosm. A Geometric Model of Plaque Incision and Graft for Peyronie's Disease with Geometric Analyses of Different Techniques. *J Sex Med* 2014;11(6):1546-53.