

# Quantitative and Qualitative Assessment of Medial Osteotomy of the Greater Palatine Foramen in Wide Cleft Palate Repair

Hamidreza Fathi<sup>1,2</sup>, Seyed Saheb Hoseininejad<sup>3</sup>, Hojjat Molaei<sup>1\*</sup>

1. Department of Plastic & Reconstructive Surgery, School of Medicine, Tehran University of Medical Sciences, Tehran, Iran
2. Department of Plastic & Reconstructive Surgery, Amiraalam Hospital, Tehran, Iran
3. Department of Plastic & Reconstructive Surgery, School of Medicine, Ahvaz Joundishapour University of Medical Sciences, Ahvaz, Iran

## \*Corresponding Author:

Hojjat Molaei

Department of Plastic and Reconstructive Surgery, School of Medicine, Tehran University of Medical Sciences, Tehran, Iran AND Department of Plastic and Reconstructive Surgery, Amiraalam Hospital, Tehran, Iran

Tel.: +989127798804

Email: [hmggprs@gmail.com](mailto:hmggprs@gmail.com)

Received: 2022/05/27

Accepted: 2022/07/19

## ABSTRACT

**Background:** Repairing of a wide cleft palate faces with several problems, e.g. medialization of palatal flaps, lack of tissue for repair, and fistula formation. We aimed at quantitative and qualitative evaluation of medial osteotomy of the greater palatine foramen for patients with wide cleft palate and its postoperative outcomes.

**Methods:** Eight patients 4 males, 4 females with wide cleft palate and the median age of 1.5 year were operated using medial osteotomy of the greater palatine foramen from 2018-2020. In this technique, the osteotomy was carried in the outlet of vascular pedicle medially and posteriorly. This led to more degrees of freedom for the vascular pedicle and a palatoplasty without tension through mucoperiosteal flap movement toward the medial direction.

**Results:** After osteotomy and repairing for 8 patients (16 flaps), the mean (SD) length of mucoperiosteal flap pedicle was significantly increased from 2.78 mm to 6.09 mm ( $P < 0.001$ ). All patients were successfully repaired with no major complications, and none of them required any secondary repair. Three weeks postoperatively, all patients showed normal feeding, normal nasal resonance of speech with normal palatal mobility.

**Conclusion:** Osteotomy of the greater palatine foramen for the closure of wide palatal clefts showed a good efficiency, quantitatively and qualitatively. The mean length of mucoperiosteal pedicle increased by 3.22 mm (6.44 mm for bilateral) after repairing, which helps to more freely medial movement of the palatal flap and lesser tension across its closure. All patients were successfully improved without any major complications.

## KEYWORDS

Cleft Palate; Medial Osteotomy; Mucoperiosteal flap; Palate; Palatoplasty

## Please cite this paper as:

Fathi H., Hoseininejad SS., Molaei H. Quantitative and Qualitative Assessment of Medial Osteotomy of the Greater Palatine Foramen in Wide Cleft Palate Repair. *World J Plast Surg.* 2022;11(2):129-134.  
doi: 10.52547/wjps.11.2.129

## INTRODUCTION

A wide cleft palate causes an inability to close the velopharyngeal, making and sustaining the intraoral pressure. This significantly affects both normal speech and feeding. Moreover, the abnormal anatomy of the muscle in this area can affect the middle ear function through the anatomical derangement in the eustachian tube orifice<sup>1</sup>.

The cleft palate repair is aimed at anatomical closure of the defect, normal speech improvement through making a fit velopharyngeal valve,



This work is licensed under a Creative Commons Attribution-NonCommercial 4.0 International license (<https://creativecommons.org/licenses/by-nc/4.0/>). Non-commercial uses of the work are permitted, provided the original work is properly cited.

feeding improvement, and also minimizing the maxillary growth impairments and dentoalveolar anomalies<sup>2</sup>. An extremely wide cleft palate has been defined as a palatal defect greater than 60% of the entire palate width<sup>3</sup>.

Repairing of a wide cleft palate faces several challenges, including minimizing the wound dehiscence, fistulae, and denuded palate<sup>4</sup>. As regards cleft palatal repair, various surgical techniques have been used so far, including primary pharyngeal flap with palatoplasty<sup>4</sup>, a mucoperiosteal hinged flap with push-back palatoplasty<sup>5</sup>, free tissue transfer flaps<sup>6</sup>, the double transposition flap<sup>7</sup>, and buccal musculomucosal flaps<sup>8</sup>.

Global efforts continue to find out the best surgical techniques for the wide cleft palate repair and overcome its related challenges. In reconstructing using two flaps on either side of the wide cleft palate defect, the presence of a short vascular pedicle via the greater palatine artery is an obstacle to further dissection and movement of flap toward the midline. The outlet of the vascular pedicle contains the artery and vein that feeds the flap. This practical study was aimed at assessing the quality and quantity efficacy of medial osteotomy of the greater palatine foramen on patients with wide cleft palate and their postoperative outcomes. The osteotomy was done in the outlet of this vascular pedicle medially and posteriorly; this led to more degrees of freedom (a few millimeters) bilaterally for the vascular pedicle, which helps to repair without tension through mucoperiosteal flap movement toward the medial direction.

## METHODS

### Patients

Between Oct 2018 and Jan 2020, 8 patients 4 males and 4 females with the median age of 1.5 year were diagnosed with wide cleft palate based on the following criteria. Then, all patients were operated using Osteotome for Outfracture of the Greater Palatine Foramen in Imam Khomeini and Amir aalam Hospitals, Tehran, Iran<sup>9</sup>.

All procedures involving human participants were in accordance with the ethical standards of the national Research Committee and with the 2008 Helsinki declaration and its later amendments as well as Tehran University of Medical Sciences (Ethical Code: IR.TUMS.IKHC.REC.1398.190).

A wide cleft palate is defined as 1) the interval between the medial edges of the hard palate is >1.5 cm. 2) a palatal defect involves >60% of the entire palate width and/or 3) the width of the palatal defect is greater than the width of both palatal shelves<sup>3</sup>.

All patients were operated on following general anesthesia by intraoral placing an endotracheal Ring-Adair-Elwyn tube. After properly positioning the patient in a neurosurgical head holder, a solution of 1% lidocaine with 1:100,000 epinephrine was injected into the entire palate. Besides, patients were given antibiotics and dexamethasone (0.5 mg/kg) to lessen tongue and/or throat edema during the procedure.

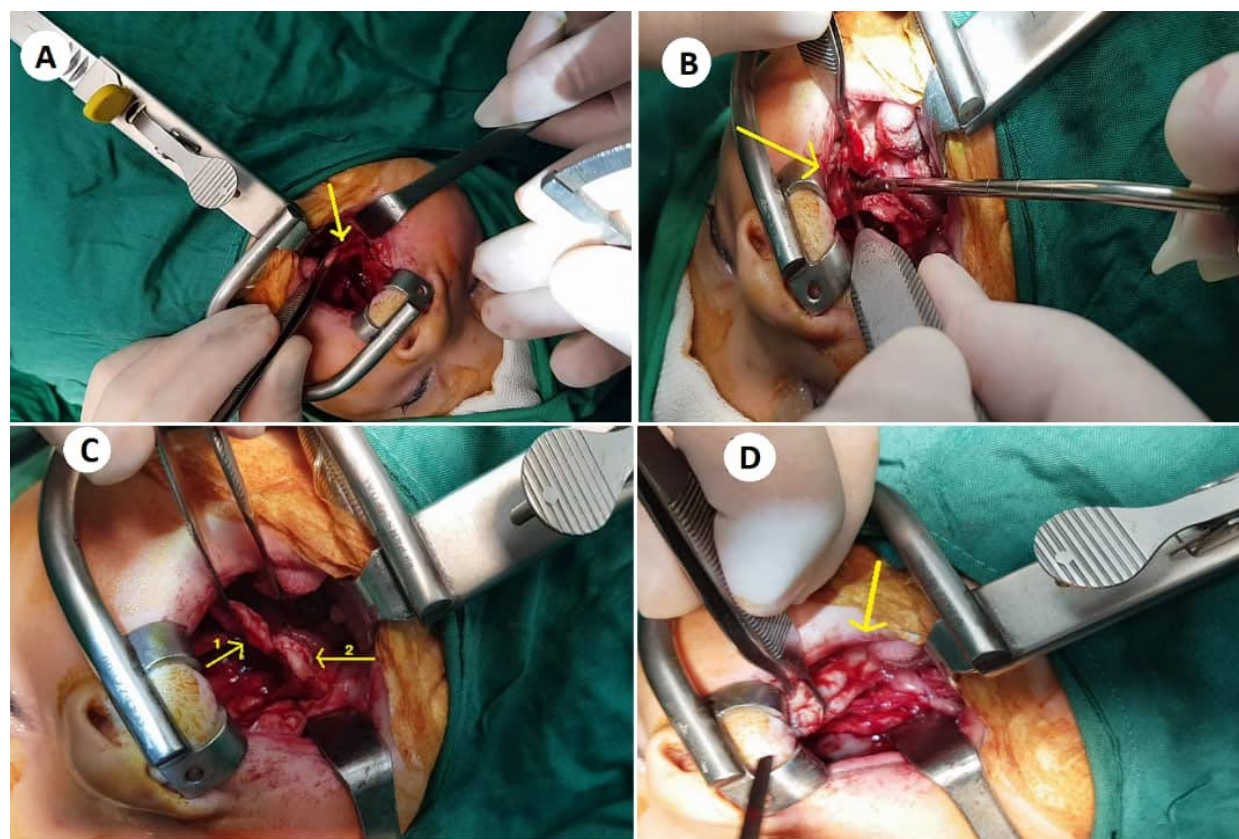
Palatal mucoperiosteal flap was dissected to repair cleft palate. In this regard, the osteotomy was carried out in the outlet of this vascular pedicle medially and posteriorly, and this led to more degrees of freedom (a few millimeters) for the vascular pedicle and a palatoplasty without tension through mucoperiosteal flap advancement toward the medial direction. The greater palatine neurovascular bundle was dissected to its foraminal exit. The osteotomy and out\_fracture was done in posteromedially direction with osteotome no. 4. The medially and then laterally osteotomies were done by Osteotome No.4 and these created a posterior osseous defect in the hard palate. The nerves and vessels located in the bigger palatine were dissected from the osteomized foramen, and so, this allows more freely medial movement of the palatal flaps and lesser tension across the closure (Fig. 1)

### Postoperative care

Postoperative monitoring of airway and oximetry should be done until the patients are quite awake and reach the normal levels of oxygen saturation without any support. Patients were given fluids after recovery. The liquid diet (milk feeding) was suggested for two weeks followed by a soft diet for an extra 3 weeks.

## RESULTS

A total of 8 patients with wide cleft palate were treated surgically. The demographic and clinical characteristics of the patients are briefed in Table 1. Only two patients had basic diseases, including Pierr Robin syndrome (PRS) and congenital Heart disease (CHD).



**Fig. 1.** Medial osteotomy of the greater palatine foramen on a patient with wide cleft palate. A) mucoperiosteal flap before osteotomy, B) Fracture site of the greater palatine foramen after osteotomy, C) Releasing and taking distance of two mucoperiosteal flaps from the hard palate anteriorly and posteriorly, D) Lengthening of the mucoperiosteal flap pedicle by average of 3.22 mm which helps to more freely its medial movement

**Table 1.** Demographic and clinical characteristics of the patients.

Patient	Sex	Age (months)	Basic disease	Bifid Uvula	Cleft Palate	Alveolar cleft	Width of cleft plate(mm)
1	Male	24	—	yes	Yes	N	17
2	Male	13	Congenital heart defect	yes	Yes	E	14
3	Male	12	—	yes	No	O	16.5
4	Male	14	Pierr Robin Syndrome	yes	No	Π	16
5	Female	9	—	yes	Yes	P	18
6	Female	14	—	yes	No	Σ	19
7	Female	13	—	yes	Yes	T	24
8	Female	25	—	yes	No	Υ	19

The postoperative follow-up period was 6 months. After osteotomy of the greater palatine foramen, the mucoperiosteal flap pedicle length was increased by 3.22 mm, and this helps to more freely medial movement of the palatal flap and lesser tension across its closure (Table 2, 3).

During the study follow up, all patients were successfully repaired with no major complications, e.g. disruption, infection, wound dehiscence,

hematoma and fistula formation, necrosis, and flap loss; also, none of them required any secondary repair. Three weeks postoperatively, all patients showed normal feeding and normal nasal resonance of speech with normal palatal mobility confirmed by the Cleft Palate Committee of Tehran University of Medical Sciences. There was a significant improvement, and no secondary procedures were required either.

**Table 2.** Mucoperiosteal flap pedicle length before and after osteotomy for 16 flaps (from the flap to foramen).

Valid length before osteotomy	Frequency N(%)	Valid length after osteotomy	Frequency N(%)
1.5	1(6.30%)	5	6(37.5%)
2	6(37.5%)	5.50	2(12.50%)
2.50	2(12.5%)	6	1(6.30%)
3	1(6.30%)	6.50	1(6.30%)
3.5	2(12.5%)	7	4(25%)
4	4 (25%)	8	2 (12.5%)
TOTAL	16 (100)		16(100)

**Table 3.** Comparison of mucoperiosteal flap pedicle length before and after osteotomy

	Mucoperiosteal flap pedicle length (mean $\pm$ _SD)	P value	Effect size
Before	2.78 $\pm$ 0.912		
After	6.09 $\pm$ 1.113	<0.001	3.22

## DISCUSSION

A variety of techniques for the wide cleft palate closure have been specially developed. However, with regard to postoperative consequences, the incidence of oronasal fistula formation is high. At the first, Dr. Johanson described an extended pharyngeal flap for closing of an extremely wide cleft palate<sup>10</sup>. Subsequently, Holmstrom et al<sup>4</sup> applied this operation on 11 patients with extensive clefts using an elongated pharyngeal flap and a Wardill-Kilner palatoplasty. All patients had cleft lip with cleft palate. Anterior palatal fistulas developed in two cases. Three patients had transient dysphagia. Two patients had a better speech after the operation<sup>4</sup>.

Chen and Zhong<sup>6</sup> introduced a bilateral musculomucosal buccal flap method for repairing the cleft palate. They had repaired the cleft palate of 26 patients without any occurrence of postoperative complications. Mann and Fisher<sup>11</sup> used this technique for closure of wide cleft palate in combining with the Furlow double opposing z-plasty. This combination led to a more prolongation of the palate and lessen tension in wide clefts by adding bilateral buccal flaps.

Free autologous tissue transfer (Free flaps) is also reported to close the extensive palatal defects. Although free flaps can improve defects with minimum incision of the palate, this operation requires a long time, and so can be technically very challenging<sup>12,7</sup>.

Bakthavachalam and Ducic treated a very extensive cleft palate with a double transposition flap. There was no flap dehiscence, and none of the patients have required a secondary repair. After treatment, all patients had a proper diet. The double-transposition flap can simply close the extensive palatal defects without any tension<sup>5</sup>. However, it does not make the palatal prolongation for anatomical closure of the velopharyngeal space during the speech. Moreover, too many dissections of the muscles are needed that should be closed in the midline, which will affect the blood supply and function in this area. The mentioned techniques depend mostly on extra tissues in the form of distant or regional flaps, mainly the muscles. This will affect the palate function, especially speech. Dr. Aboul-Wafa operated on 36 patients with an extensive cleft palate using islandized mucoperiosteal flaps. All patients attained good speech without any fistula formation, scar, and/or constriction in the lateral defects of the palate<sup>13</sup>.

Many surgeons advocate of minimal manipulation of the greater palatine foramen as well as palatine nerve and vessels to minimize damages to these tissues. Accordingly, stretching the neurovascular bundle<sup>14, 15</sup> and or its lengthening were applied by dissection from the mucoperiosteal flaps<sup>16-18</sup>. Some surgeons transected the vessels in cleft palate because they believed that the greater palatine neurovascular bundle is unimportant<sup>19, 20</sup>.

More recently, some researchers developed a guarded osteotome for out-fracturing of the greater



palatine foramen with the aim of medializing the greater palatine foramen. The out fracture of the greater palatine foramen and medialization of palatine vessels can reduce the lateral restriction and injury in the neurovascular bundle<sup>9</sup>. Osteotomy of the greater palatine foramen helps in further medial movement of oral mucoperiosteal flaps to tension-free closure of the oral layer as well as minimize the risk of fistula formation<sup>21</sup>.

In the present clinical study, we repaired the wide cleft palate using the greater palatine foraminal osteotomy to a movement toward the medial aspect of hard palate mucoperiosteal flap. Previous clinical reports have only described the quality of this technique while the present study evaluated this technique quantitatively and qualitatively. The mucoperiosteal flap pedicle length was increased from 2.78 (0.912) mm to 6.09 (1.113) mm after repair and this bilateral lengthening helps to close the cleft palate without tension. Also, during the follow up of patients, there was no evidence of hematoma, necrosis and fistula formation.

## CONCLUSION

The osteotomy of the greater palatine foramen in wide cleft palate patients increased the mucoperiosteal flap pedicle by average of 3.22 mm in length (6.44 mm bilaterally). This osteotomy helps to more freely medial movement of the palatal flap and lesser tension across its closure. Particularly, there was no evidence of hematoma, necrosis, and fistula formation. Using a microscope and magnification will help increase surgical accuracy and prevent injuries.

## ACKNOWLEDGMENTS

We would like to thank Tehran University of Medical Sciences, Tehran, Iran which supported this project.

## FUNDING

None

## CONFLICTS OF INTEREST

None declared

## REFERENCES

1. Bauer BS, Patel PK. Cleft palate. In: Georgiade GS,

- Riefkohl R, Levin LS, editors. *Georgiade Plastic and Reconstructive Surgery*. 3rd edn. Baltimore: Williams & Wilkins; 1997. pp. 239–46.
2. Lindsay WK, Witzel MA. Cleft palate repair: Von Langenbeck technique. In: Bardach J, Morris HL, editors. *Multidisciplinary Management of Cleft Lip and Palate*. Philadelphia: WB Saunders Company; 1990. p. 303.
3. Bumsted RM. A new method for achieving complete two-layer closure of a massive palatal cleft. *Arch Otolaryngol* 1982;108:147–50.
4. Holmstrom H, Stenborg R, Blomqvist G. Elongated pharyngeal flap in extensive clefts of hard and soft palate. *Cleft Palate J* 1986;23:41–7.
5. Bakthavachalam S, Ducic Y. The double transposition flap for closure of the extremely wide hard palate cleft. *Arch Facial Plast Surg* 2006;8:123–7.
6. Chen GF, Zhong LP. A bilateral musculomucosal buccal flap method for cleft palate surgery. *J Oral Maxillofac Surg* 2003;61:1399–404.
7. Eufinger H, Machtens E. Microsurgical tissue transfer for rehabilitation of the patient with cleft lip and palate. *Cleft Palate Craniofac J* 2002;39:560–7.
8. Lee SI, Lee HS, Kun H. Reconstruction of palatal defect using mucoperiosteal hinge flap and pushback palatoplasty. *J Craniofac Surg* 2001;12:561–3.
9. Oh Albert, Wong Granger B. An Osteotome for Outfracture of the Greater Palatine Foramen in Cleft Palate Repair. *Plastic and Reconstructive Surgery* 2001;107(3):820–822.
10. Bardach J, editor. *Atlas of Craniofacial and Cleft Surgery*. Vol. 2. Philadelphia: Lippincott Raven; 1999.
11. Mann RJ, Fisher OM. Bilateral buccal flaps with double opposing z-plasty for wider palatal clefts. *Plast Reconstr Surg* 1997;100:1139–43.
12. Furnas OW. Temporal osteocutaneous island flaps for complete reconstruction of cleft palate defects. *Scand J Plast Reconstr Surg Hand Surg* 1987;21:119–28.
13. Aboul-Wafa A. M. Islandized mucoperiosteal flaps: A versatile technique for closure of a wide palatal cleft. *The Canadian Journal of Plastic Surgery* 2012;20(3):173–177.
14. Brown JB. Double elongations of partially cleft palates and elongations of palate with complete clefts. *Surg Gynecol Obstet* 1940;70:815.
15. McDowell F, Brown JB, Fryer MP. *Surgery of the Face, Mouth, and Jaws*. St. Louis: Mosby, 1954;120–121.
16. Edgerton MT. Surgical lengthening of the cleft palate by dissection of the neurovascular bundle. *Plast Reconstr Surg* 1962;29:551.
17. Bardach J, Salyer KE. Cleft palate repair. In J. Bardach and K. E. Salyer (Eds.), *Surgical Techniques in Cleft*

- Lip and Palate. Chicago: 1987;180:224.
18. Smith HW. Surgical techniques of cleft lip and cleft palate. In H. W. Smith (Ed.), *The Atlas of Cleft Lip and Cleft Palate Surgery*. New York: Grune and Stratton, 1983;227\_263.
  19. Wardill WEM. Cleft palate. *Br J Surg* 1933;21:347.
  20. Cuthbert J. Transposed flaps in cleft palate repair. *Br J Plast Surg* 1951;4:185.
  21. Pezas T, Khan K, Richard B. What We Do: Greater Palatine Medializing Foraminal Osteotomy for Repair of the Wide Cleft Palate. *Cleft Palate Craniofac J* 2019;56(8):1080-1082.