

Functional Considerations in Reconstruction of the Nasal Ala

Matthew I. Saleem¹, McKenna Hawthorne², Tristan Tham¹, Alexandros Georgolios^{2*}

1. Department of Otolaryngology, Donald and Barbara Zucker School of Medicine at Hofstra/Northwell, New York, USA
2. Poplar Bluff Regional Medical Center, Poplar Bluff, MO 63901, USA

ABSTRACT

We present the case of a 33-year-old female referred with a 13x10 mm surgical defect immediately after Mohs micrographic surgery for excision of basal cell carcinoma. Functional considerations for the external nasal valve were accounted for using free alar rim cartilage graft, soft tissue tunnels, and pre-auricular full-thickness skin grafts. Our post-operative experience demonstrates excellent nasal valve integrity and acceptable aesthetic outcomes for the patient by providing structural support for the nasal ala. Our management has minimal additional morbidity and minimizes the risk of external nasal valve compromise in the long-term.

KEYWORDS

Carcinoma; Nasal valve; Surgery; USA

Please cite this paper as:

Saleem MI., MK., Tham T., Georgolios A. Functional Considerations in Reconstruction of the Nasal Ala. *World J Plast Surg.* 2022;11(2):150-152. doi: 10.52547/wjps.11.2.150

INTRODUCTION

The anatomic region of the nasal ala is anatomically complex, highly contoured, and contains major importance for the function of the external nasal valve. Skin cancers of the nasal ala are primarily treated with surgical resection, either cold knife excision or Mohs micrographic surgery. Surgical defects in this anatomic region have important technical considerations because they are not typically amenable to primary closure, due to limited ability of undermining in the surrounding skin and risk to cause retraction of the adjacent nostril margin¹.

Although relative studies are scarce in the literature, it is generally accepted that if the nasal ala defect is limited to the skin and the lower lateral cartilage is intact, reconstruction can proceed without consideration for providing structural support to the ala¹. In addition to thickness, size of the surgical defect will significantly weigh in the reconstructive management. Defects less than or equal to 1 cm are good candidates for full-thickness skin grafting, while larger defects are often addressed with local soft tissue flaps capable of replacing the subunit, such as the melolabial flap and the paramedian forehead flap². Furthermore, structural support is considered necessary in all surgical defects that involve the area of the nostril margin³.

*Corresponding Author:

Alexandros Georgolios MD FACS

Poplar Bluff Regional Medical Center, MO 63901, USA

Tel.: +1 573-778-2600

Email: ageorgol@hotmail.com

Received: 2022/01/10

Accepted: 2022/04/21



This work is licensed under a Creative Commons Attribution-NonCommercial 4.0 International license (<https://creativecommons.org/licenses/by-nc/4.0/>). Non-commercial uses of the work are permitted, provided the original work is properly cited.

CASE PRESENTATION

Informed consent has been given by the patient for publication of the clinical images, which are deidentified.

In our view, there should be a low threshold for providing structural support in the nasal ala even in smaller, thinner defects and defects that lie more superiorly to the nostril rim. This can be easily accomplished with the utilization of a free alar rim cartilage graft of either septal or auricular source (Fig. 1). Nasal ala reconstruction was performed by the corresponding author utilizing a free alar rim cartilage graft. Graft was harvested from conchal cartilage. Patient was reevaluated 12 months post operatively to assess external nasal valve integrity.

The depicted 33-year-old female was referred with a 13x10 mm surgical defect immediately after Mohs micrographic surgery for excision of basal cell carcinoma. A conchal cartilage graft was used to span the width of the defect at the margin of the nostril. Soft tissue tunnels on either side of the defect were created to accommodate the medial and lateral ends of the graft. Finally, a pre-auricular full-thickness skin graft was used to provide excellent color match to the area. Due to the relatively small size of the defect, overlapping of the two free grafts does not typically affect healing. Our experience is consistent with long-term excellent results in preserving nasal valve function as well as acceptable aesthetic outcomes (Fig. 2).

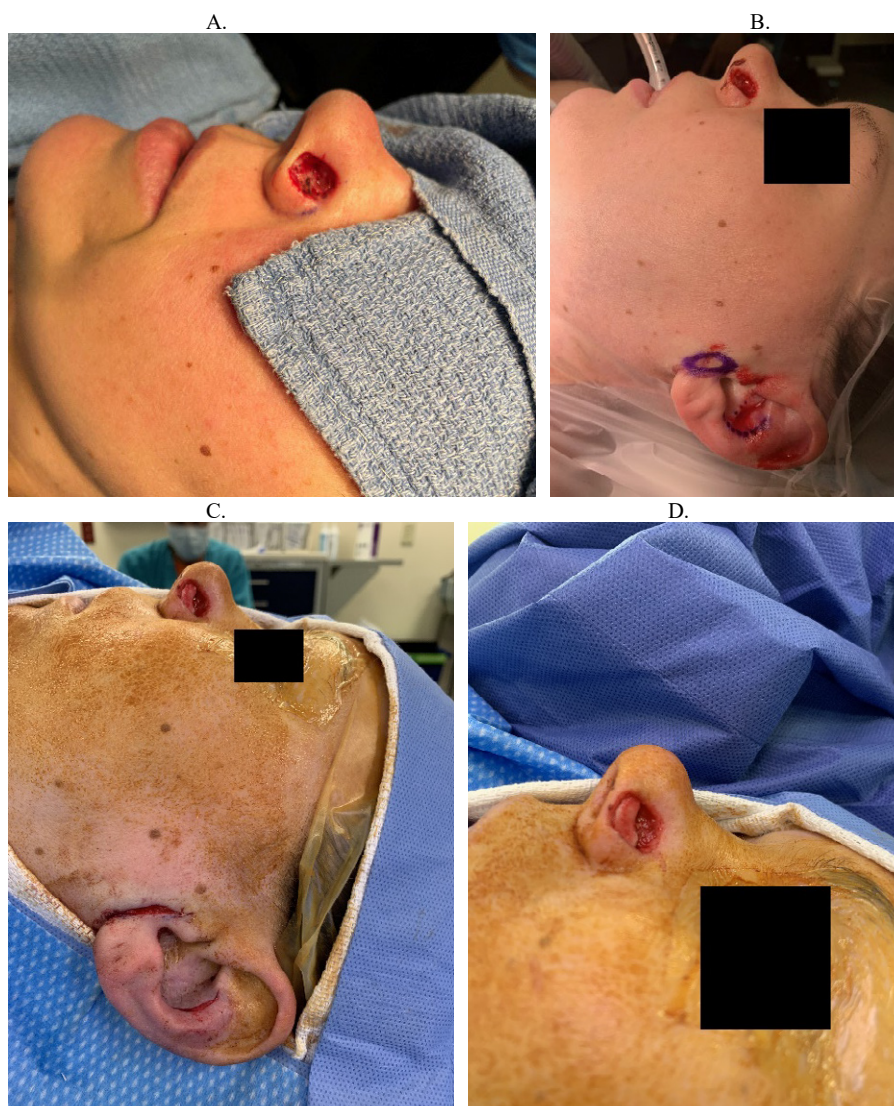

Figure 1: Reconstruction of nasal ala surgical defect post Mohs micrographic surgery. (A) Surgical defect on nasal ala. (B) Markings for grafts. (C) Surgical incisions for grafts. (D) Conchal cartilage graft in nasal ala.

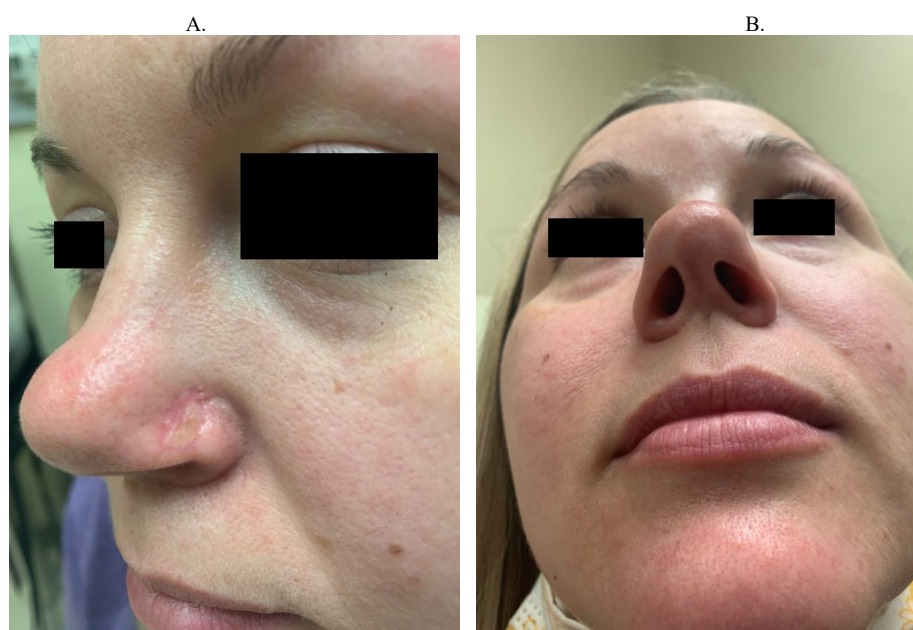


Figure 2: (A) Nasal ala surgical defect 12 months post reconstruction and (B) basal view of nasal valve.

DISCUSSION

The patient's skin thickness, distance from the nostril rim, and idiosyncratic healing responses are included in a number of unpredictable, poorly controlled factors that can compromise the external nasal valve during the healing process. The critical importance of this anatomic area in nasal function is reflected in long-term post rhinoplasty patients where external nasal valve dysfunction ensues not only as a result of aggressive cephalic trimming of the lower lateral cartilage, but just due to poor adaptation of the vestibular skin, lacking sutures, or abnormal scarring⁴. Our proposed management has minimal additional morbidity for the patient while minimizing the risk of external nasal valve compromise in the long-term.

ACKNOWLEDGEMENTS

No financial support was received.

CONFLICT OF INTEREST

The authors declare that there is no conflict of interests.

REFERENCES

1. Chen C, Patel R, Chi J. Comprehensive Algorithm for Nasal Ala Reconstruction: Utility of the Auricular Composite Graft. *Surg J (N Y)* 2018;4(2):e55-e61. doi:10.1055/s-0038-1639581
2. McCluskey PD, Constantine FC, Thornton JF. Lower third nasal reconstruction: when is skin grafting an appropriate option? *Plast Reconstr Surg* 2009;124(3):826-835. doi:10.1097/PRS.0b013e3181b03749
3. Baker SR, ed. Reconstruction of the Nose. In: *Local Flaps in Facial Reconstruction*. Third edition. Elsevier/ Saunders; 2014.
4. Torres S, Marianetti T. Management of Common Complications in Rhinoplasty and Medical Rhinoplasty. In: Motamedi MHK, ed. *A Textbook of Advanced Oral and Maxillofacial Surgery Volume 3*. IntTech; 2016. doi:10.5772/63130.