



# Nephroprotective Effect of *Nasturtium officinale* (Watercress) Ethanol Extract and Vitamin E on Vancomycin-Induced Nephrotoxicity in Rats

Masoumeh Karami,<sup>1</sup> Mostafa Mostafazadeh,<sup>2,3</sup> Hossein Sadeghi,<sup>4,5,\*</sup> Heibatollah Sadeghi,<sup>5,6</sup> Fouad Mehraban,<sup>7</sup> Esmaeel Panahi Kokhdan,<sup>5</sup> Moslem Sayahi,<sup>5</sup> and Seyed Reza Abtahi<sup>8</sup>

<sup>1</sup>Biochemistry Department, Faculty of Medicine, AJA University of Medical Sciences, Tehran, IR Iran

<sup>2</sup>Department of Biochemistry and Clinical Laboratories, Tabriz University of Medical Sciences, Tabriz, Iran

<sup>3</sup>Student Research Committee, Tabriz University of Medical Sciences, Tabriz, IR Iran

<sup>4</sup>Department of Pharmacology, Faculty of Medicine, Yasuj University of Medical Sciences, Yasuj, IR Iran

<sup>5</sup>Medicinal Plants Research Center, Yasuj University of Medical Sciences, Yasuj, IR Iran

<sup>6</sup>Cellular and Molecular Research Center, Yasuj University of Medical Sciences, Yasuj, IR Iran

<sup>7</sup>Institute of Biochemistry and Biophysics (IBB), Tehran University, Tehran, IR Iran

<sup>8</sup>Physiology and Pharmacology Department, Faculty of Medicine, AJA University of Medical Sciences, Tehran, IR Iran

\*Corresponding author: Hossein Sadeghi, Medicinal Plants Research Center, Yasuj University of Medical Sciences, Yasuj, IR Iran. Tel: +98-7413346070, Fax: +98-7413346071, E-mail: h\_sadeghi\_m@yahoo.com

Received 2016 March 28; Revised 2016 December 03; Accepted 2017 August 06.

## Abstract

**Background:** Vancomycin (VCM) is an important antibiotic that is active against gram-positive cocci, and its nephrotoxicity remain as a major problem in clinical use.

**Objectives:** This study was designed to investigate the effect of *Nasturtium officinale* hydro-alcoholic extract (NOE) and vitamin E against VCM-induced nephrotoxicity in adult male wistar rats.

**Methods:** A total of 36 animals were randomly divided into 6 equal groups (n = 6) including 1, control group; 2, VCM group; 3, VCM + NOE (250 mg/kg) group; 4, VCM + NOE (500 mg/kg) group; 5, VCM + vitamin E (250 mg/kg) group; and 6, VCM + vitamin E (500 mg/kg) group. VCM (200 mg kg<sup>-1</sup> i.p.) was given every 12 hours for 7 consecutive days. NOE and vitamin E were orally given to rats 30 minutes prior to i.p. injection of VCM. Acute renal failure was evaluated by measuring serum urea, creatinine levels, and creatinine clearance. Change in body weight and kidney weight (g/100 g body weight) were measured. The right kidney was fixed in formalin for pathological evaluation and the left kidney was homogenized for determination of malondialdehyde (MDA).

**Results:** VCM significantly increased serum creatinine and urea levels, MDA levels, kidney weight/100 mg weight of body, as well as reduced creatinine clearance. NOE (250, 500 mg kg<sup>-1</sup>) and vitamin E (500 mg kg<sup>-1</sup>) pretreatment considerably alleviated all of these changes when compared with VCM treated alone. Histological examination of VCM-treated group showed a marked renal injury with tubular epithelial cell desquamation, swelling, and tubular dilatation. These changes were mitigated with NOE- and vitamin E.

**Conclusions:** The data indicate that NOE obviously attenuated VCM-induced nephrotoxicity. Elucidation of the exact mechanism(s) of this protection requires more research, however, it might be mediated by antioxidant effects of NOE.

**Keywords:** Vancomycin, Vitamin E, Nephrotoxicity, Rat, *Nasturtium officinale*

## 1. Background

Vancomycin (VCM) hydrochloride is a glycopeptide antibiotic that inhibits the biosynthesis of bacterial cell wall peptidoglycan polymer. It is a choice antibiotic for treating resistant infections such as methicillin-resistant *S. aureus* (MRSA) infections. VCM is mainly excreted via kidneys. One of the major adverse effects of this drug is nephrotoxicity, which has limited its dose and duration of administration (1, 2). Although the exact mechanism of renal toxicity of VCM is not fully understood, some published studies have suggested that the oxidative stress has a crucial

role in the pathogenesis of VCM-induced nephrotoxicity (VIN) (3-7). Several antioxidants including: vitamin E (8), 2, 3-dihydroxybenzoic acid (9), curcumin (10) and vitamin C (11) have been reported that reduces VIN. Based on these data, renal tubular ischemia due to the oxidative effects of VCM is the main known mechanism of VIN (5, 12, 13).

*Nasturtium officinale* R. Br (Watercress) is a perennial plant native to Europe, which has been found in the west and southwestern region of Iran. This plant is freshly used as a vegetable in salads, soups, and other recipes. In traditional medicine, the leaves of the plant are widely used as diuretic, expectorant, blood purifier, hypoglycemic, and

odontologic (14-17). Yazdanparast and colleagues reported that watercress supplementation in diet decreases serum lipids and alters blood antioxidant status in hypercholesterolaemic rats (18). They also reported that it has a potent antioxidant property in vitro and in vivo (18, 19). Our previous study showed that watercress produced a noticeable anti-inflammatory effect in different animals of inflammation (17).

Vitamin E is a potent radical scavenger, which is probably the most important inhibitor of membrane lipid peroxidation. It is a lipophilic agent, which can readily cross cell membranes and exert its effects both intracellularly and in membranes (20). Vitamin E has shown promising effects in gentamicin (21), cisplatin (22), and Adriamycin-induced nephrotoxicity (23).

## 2. Objectives

Therefore, regarding the role of oxidative stress in VIN and the antioxidant effects of NOE and vitamin E, the objective of this study was to investigate the effect of *N. officinale* ethanol extract and vitamin E against VIN in rats.

## 3. Methods

### 3.1. Drugs and Laboratory Kits

Vancomycin hydrochloride was purchased from Jaber Ebne Hayyan Pharmaceutical Co. (Tehran, Iran.). Trichloroacetic acid (TCA), 1,1,3,3-tetraethoxypropan (TEP), thiobarbituric acid (TBA), and vitamin E were obtained from Sigma Chemical Co. (Sigma, Germany). Creatinine and urea laboratory kits were purchased from Ziest Chem Diagnostics Co. (Tehran, Iran).

### 3.2. Plant Material and Extraction

Aerial parts of *N. officinale* were obtained from the suburbs of Yasuj (kohgiluyeh boyerahmad, Iran) at the end of spring 2014 and was identified by a botanist (department of biology, faculty of Sciences, University of Yasuj). A voucher specimen of it was deposited in the herbarium of biochemistry lab, Faculty of Medicine, Yasuj University of Medical Sciences, Yasuj, Iran. The plant aerial parts were dried in room temperature, protected from direct sunlight, and then powdered. For preparation of hydroalcoholic extract, the powdered parts of the plant (300 g) were macerated with 2000 mL of EtOH-H<sub>2</sub>O (7:3) at 45°C for 48 hours. Then the extract was shaken, filtered, and concentrated under reduced pressure in a rotary evaporator at 60°C and dried at room temperature (24). The resulting extract as a percentage of the used dried powder of the plant was approximately 23.6%.

### 3.3. Determination of Total Phenol

Total phenol content of the extract was determined by Folin-Ciocalteu reagent method (25). An aliquot of 0.1 mL of the extract (1 mg/mL) was combined with 0.4 mL of sodium carbonate 7.5% and 0.5 mL Folin-Ciocalteu reagent. After 30 minutes of being maintained in laboratory temperature, its light absorption was read by spectrophotometer (Farmacia LKB model Neova spect II made in England) in wavelength of 756 nm. Experiments were performed in triplicate. Total phenolic was expressed as milligrams of gallic acid equivalents (GAE) per gram of sample using the standard calibration.

### 3.4. Determination of Total Flavonoids

The total flavonoids contents of the extract were estimated by aluminium chloride colorimetric method (26). An aliquot of 0.1 mL of the NOE (1 mg/mL) was added to sodium nitrate sodium nitrate (5%). Then 10% of aluminium chloride solution was added to the test tube. After incubation for 5 minutes in a dark place, 1 M NaOH (0.5 mL) was added. The absorbance of the sample was read in a fixed wavelength 510 nm. Experiments were performed in triplicate. The total flavonoid content was calculated from a calibration curve, and the result was expressed as mg rutin equivalent per g extract weight.

### 3.5. Experimental Animals

A total of 36 male wistar rats, weighting 250 to 350 g, were obtained from the Pasteur Institute of Iran, Tehran, Iran. The animals were fed with rat chaw and tap water ad libitum and acclimatized under a temperature of 21 ± 3°C with a 12 hours light/12 hours dark cycle. The experiments were carried out in accordance to the international guidelines for the care and use of experimental animals and approved by the ethical committee of the AJA University of Medical Sciences.

### 3.6. Experimental Protocol

This dose of VCM was selected based on previous studies (4, 6, 8, 9). The rats were weighed prior to the first injection of VCM and every other day in order to adjust the dose according to weight changes. VCM and NOE were dissolved in normal saline (N/S) and prepared freshly every day. The vitamin E solution was prepared in sesame oil. Vitamin E (250, 500 mg kg<sup>-1</sup>) or NOE (250 and 500 mg kg<sup>-1</sup>) administered orally (p.o.) 30 minutes prior to injection of VCM.

The animals were divided into 6 experimental groups as follows:

Control group: rats received a daily injection of 0.5 mL N/S for 7 days

VCM group: rats received VCM (200 mg kg<sup>-1</sup> i.p.) twice a day for 7 days

VCM + NOE group: rats received VCM (200 mg kg<sup>-1</sup> i.p.) and NOE (250 mg kg<sup>-1</sup> p.o.) twice a day for 7 days

VCM + NOE group: rats received VCM (200 mg kg<sup>-1</sup> i.p.) and NOE (500 mg kg<sup>-1</sup> p.o.) twice a day for 7 days

VCM + vitamin E group (250 mg kg<sup>-1</sup>, p.o.): rats received VCM (200 mg kg<sup>-1</sup> i.p.) and vitamin E group (250 mg kg<sup>-1</sup> p.o.) twice a day for 7 days

VCM + vitamin E group: rats received VCM (200 mg kg<sup>-1</sup> i.p.) and vitamin E group (500 mg kg<sup>-1</sup> p.o.) twice a day for 7 days

### 3.7. Sample Collection

After the 14th injection of VCM, the animals, while they had free access to tap water, placed individually in propylene metabolic cages at 8 p.m. and the 12 hours urine was collected and urine volume was measured. Blood samples were collected by cardiac puncture from all the animals under ether anesthesia. The blood and urine samples were centrifuged at 3000 rpm for 20 minutes at +4°. The supernatant was separated and stored at -20°C until analyzed. After collecting the blood specimens, the animals were sacrificed by diethyl ether and both kidneys were removed and weighed. The right kidneys were prepared for pathologic examinations and the left kidneys stored at -80°C for MDA measurement.

### 3.8. Biochemical Assays

Urea and creatinine levels were determined according to commercial kits instructions (Ziest Chem Diagnostics Co., Iran).

### 3.9. Measurement of Creatinine Clearance

The 12 hours urine volume was determined ( $U_{vol}$  in mL) and the creatinine concentration ( $U_{cr}$  in mg/dL) of it was measured by using the Jaffe method. In addition, serum creatinine ( $P_{cr}$  in mg/dL) concentrations were measured. The time span of the urine collection was calculated in minutes (12 hours = 720 minutes). The creatinine clearance ( $Cl_{cr}$ ) is calculated with the following formula (27, 28):

$$Cl_{cr} = \frac{U_{cr}}{P_{cr}} \cdot \frac{U_{vol}}{720} \quad (1)$$

### 3.10. Measurement of Renal Lipid Peroxidation

The concentrations of kidney MDA as proceeding of lipid peroxidation were determined according to a modified method of Ohkawa (29). The kidney tissues were homogenized in a Teflon glass homogenizer with a normal saline (NS) to obtain a 10% (w/v) kidney homogenate. Homogenates were centrifuged at 18,000 × g (+ 4°C) for 30

minutes. A total of 0.5 mL of kidney homogenate solutions was mixed with 2 mL of the TBA-TCA reagent (0.375% w/v TBA, 15% w/v TCA, 0.25 N HCl). The mixture was heated for 15 minutes in a boiling water bath. Next, it was cooled in a cold water bath for 10 minutes and centrifuged at 2000 × g for 15 minutes. The absorbance of solution was measured spectrophotometrically at 532 nm with respect to the blank solution and it was expressed as μmol/gram wet tissue.

### 3.11. Histopathologic Examination

The right kidney was excised after sacrifice, halved, and fixed by immersion in 10% formaldehyde solution for several days. After that, the fixed tissues were embedded in paraffin and cut into 4 - 5 μm slices. The slices were mounted on the glass slides and stained with hematoxylin and eosin (H and E) for light microscopy analysis. The assessment was conducted by a pathologist in a blinded way.

### 3.12. Statistical Analysis

All results are expressed as mean ± S.E.M. The differences between the control and treatment groups were tested by one-way analyses of variance (ANOVA) followed by the Tukey post-hoc test, using the SPSS 19 for windows. P values less than 0.05 were considered to show significant differences for all comparisons made.

## 4. Results

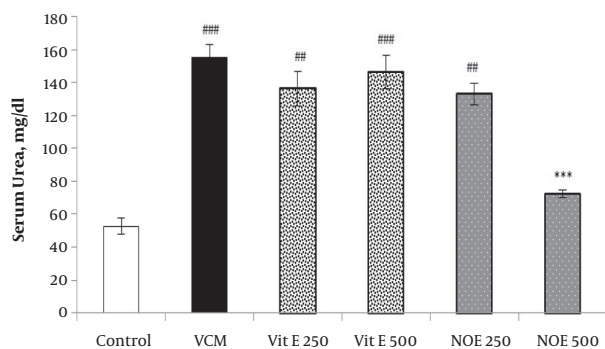
### 4.1. Total Phenolic and Flavonoid Contents

The overall mass yield of the extract from the plant material was 23.6%. Phenolic and flavonoid contents of *N. officinale* extract find out to be 78 ± 6.32 gallic acid equivalents per gram dried extract (mg GAE/g) and 96.46 ± 8.11 mg rutin equivalents per gram dried extract (mg RE/g), respectively.

### 4.2. Effect of NOE and Vitamin E on VCM-Induced Changes in Serum Creatinine and Urea Concentrations

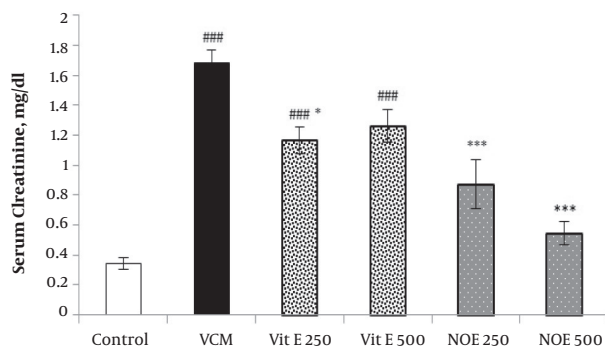
As shown in Figures 1 and 2, injection of VCM (200 mg kg<sup>-1</sup>) for 7 consecutive days significantly increased the serum creatinine and urea compared to the control groups ( $P < 0.001$ ). Oral pre-treatment with 250 and 500 mg kg<sup>-1</sup> NOE and 500 mg kg<sup>-1</sup> vitamin E considerably prevented vancomycin-induced increase in creatinine levels compared to the VCM group ( $P < 0.001$ ). NOE 500 mg kg<sup>-1</sup> also significantly inhibited the elevation in serum urea ( $P < 0.001$ ). Vitamin E at dose of 250 mg kg<sup>-1</sup> did not modify the vancomycin-induced changes in urea and creatinine levels.

**Figure 1.** Effect of Vitamin E and NOE on Serum Urea in VCM Induced Nephrotoxicity



All test groups received the indicated dose of Vit E or NOE plus 200 mg kg<sup>-1</sup> VAN. The control group received only normal saline. Values are mean  $\bar{X} \pm$  S.E.M. VCM, vancomycin; NOE, *N. officinale* extract; (n = 6) ##P < 0.01, ###P < 0.001 vs. normal saline group (I); \*\*\*P < 0.001 vs. VCM group (II).

**Figure 2.** Effect of Vitamin E and NOE on Serum Creatinine in VCM Induced Nephrotoxicity



All test groups received the indicated dose of Vit E or NOE plus 200 mg kg<sup>-1</sup> VAN. The control group received only normal saline. Values are mean  $\bar{X} \pm$  S.E.M. VCM, Vancomycin; NOE, *N. officinale* extract; (n = 6) #P < 0.05, ##P < 0.01, ###P < 0.001 vs. normal saline group (I); \*P < 0.05, \*\*P < 0.01, \*\*\*P < 0.001 vs. VCM group (II).

**4.3. Effect of NOE and Vitamin E on VCM-Induced Changes in on Creatinine Clearance**

VCM injection (200 mg kg<sup>-1</sup>) for 7 consecutive days induced a noticeable decrease in creatinine clearance compared to control groups (P < 0.001). Oral treatment with NOE and vitamin E at doses of 250 and 500 mg kg<sup>-1</sup> improved the creatinine clearance compared to the VCM group (P < 0.001).

**4.4. Effect of NOE and Vitamin E on VCM-Induced Changes in Renal MDA Level**

As shown in Table 1, kidney MDA content, an indicator of lipid peroxidation, was increase in VCM-treated rats compared to control groups (P < 0.001). NOE and vitamin E

at the all indicated doses inhibited elevation in the kidney MDA levels due to VCM injection (P < 0.001).

**4.5. Effect of NOE and Vitamin E on VCM-Induced Changes in Body and Kidney Weight**

As illustrated in Table 1, i.p. injection of VCM (200 mg kg<sup>-1</sup>) decreased the animal's weight significantly during treatment course compared to the initial weight (41.8 percent). The decline in body weight was markedly inhibited by pre-treatment with NOE 500 mg kg<sup>-1</sup> and vitamin E 500 mg kg<sup>-1</sup> (P < 0.001).

The ratio of average weight of left and right kidneys to 100 g body weight also significantly increased in the VCM-treated animals compared to the control group (P < 0.001, Table 1). Both NOE 500 mg kg<sup>-1</sup> and vitamin E 500 mg kg<sup>-1</sup> considerably reduced this change (P < 0.01 and P < 0.05, respectively).

**4.6. Effect of NOE and Vitamin E on VCM-Induced Changes in Urine Volume**

VCM treated animals characterized by having a considerably lower urine volume when compared with the control rats. This change was significantly reversed in the vitamin E (500 mg kg<sup>-1</sup>) and NOE (250 and 500 mg kg<sup>-1</sup>) groups. However, the changes of urine volume did not significantly inhibited at a lower dose of vitamin E (250 mg kg<sup>-1</sup>).

**4.7. Pathological Examination**

Figure 4 represented the histological micrographs of renal from the 4 groups used. Histopathological evaluation of VCM-treated rat kidney showed renal parenchymal damage, such as interstitial swelling, tubular dilatation, tubular epithelial cell desquamation. These histopathological changes observed were considerably inhibited by NOE and vitamin E.

**5. Discussion**

Renal toxicity is one of the most important side effects of VCM, therefore their clinical uses are limited (1, 2). Numerous therapeutic agents have been investigated clinically and experimentally against this adverse effect, however, none of them confirmed to be clinically effective as a complete protective component (8-11). In the present study, repeated i.p. administration of 200 mg kg<sup>-1</sup> VCM, for 7 consecutive days to rats, induced a considerable raise in serum creatinine and urea concentrations compared to the control group, suggesting an acute renal failure. These findings are in good agreement with the results of a previous

**Table 1.** Effect of Different Doses of Vitamin E and NOE on Percent Change in Body Weight, Kidney Weight (g/100 g Body Weight) and Urine Volume<sup>a</sup>

Treatment Groups	Percent Change in Body Weight	Kidney Weight, g/100 g body weight	Urine Volume, mL/12 h	MDA, $\mu\text{mol/gram tissue}$
I- Control	+1.30 $\pm$ 0.51	0.39 $\pm$ 0.01	6.88 $\pm$ 0.83	1.89 $\pm$ 0.32
II. VCM + Vit E 250	-10.2 $\pm$ 0.85 <sup>b</sup>	0.92 $\pm$ 0.04 <sup>b</sup>	4.45 $\pm$ 0.48	7.83 $\pm$ 0.75 <sup>b</sup>
III. VCM + Vit E 250	-6.30 $\pm$ 1.30 <sup>c,d,e</sup>	0.61 $\pm$ 0.10 <sup>f</sup>	7.80 $\pm$ 0.48	4.48 $\pm$ 0.55 <sup>g</sup>
IV. VCM + Vit E 500	-1.30 $\pm$ 0.77 <sup>g</sup>	0.67 $\pm$ 0.01 <sup>f,h</sup>	9.50 $\pm$ 1.43 <sup>f</sup>	2.54 $\pm$ 0.53 <sup>g</sup>
V. VCM + NOE 250	-5.51 $\pm$ 1.29 <sup>d,f</sup>	0.78 $\pm$ 0.04 <sup>b,e</sup>	9.58 $\pm$ 1.32 <sup>g</sup>	3.85 $\pm$ 0.52 <sup>g</sup>
VI. VCM + NOE 500	-1.40 $\pm$ 0.59 <sup>g</sup>	0.57 $\pm$ 0.03 <sup>g</sup>	11.6 $\pm$ 0.76 <sup>g,h</sup>	1.68 $\pm$ 0.15 <sup>g</sup>

Abbreviations: NOE, *N. officinale* Extract; VCM, Vancomycin.

<sup>a</sup>Values are mean  $\pm$  S.E.M. (n = 6).

<sup>b</sup>P < 0.001 vs. normal saline group (I).

<sup>c</sup>P < 0.05.

<sup>d</sup>P < 0.01.

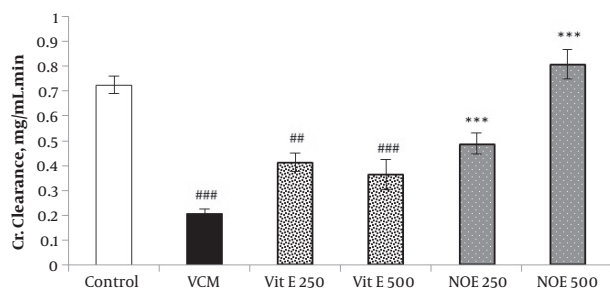
<sup>e</sup>P < 0.05 vs. group (VI).

<sup>f</sup>P < 0.01.

<sup>g</sup>P < 0.001 vs. VCM group (II).

<sup>h</sup>P < 0.05.

**Figure 3.** Effect of Vitamin E and NOE on Creatinine Clearance in VCM Induced Nephrotoxicity



All test groups received the indicated dose of Vit E or NOE plus 200 mg kg<sup>-1</sup> VAN. The control group received only normal saline. Values are mean  $\bar{A} \pm$  S.E.M. VCM, Vancomycin; NOE, *N. officinale* extract; (n = 6), ##P < 0.001, ###P < 0.001 vs. normal saline group (I); \*\*\*P < 0.001 vs. VCM group (II).

study about the nephrotoxicity of VCM in experimental animals (4-6). Naghibi and colleagues reported that i.p. injection of VCM at dose of 200 mg kg<sup>-1</sup> elevated these parameters in rats (8, 9).

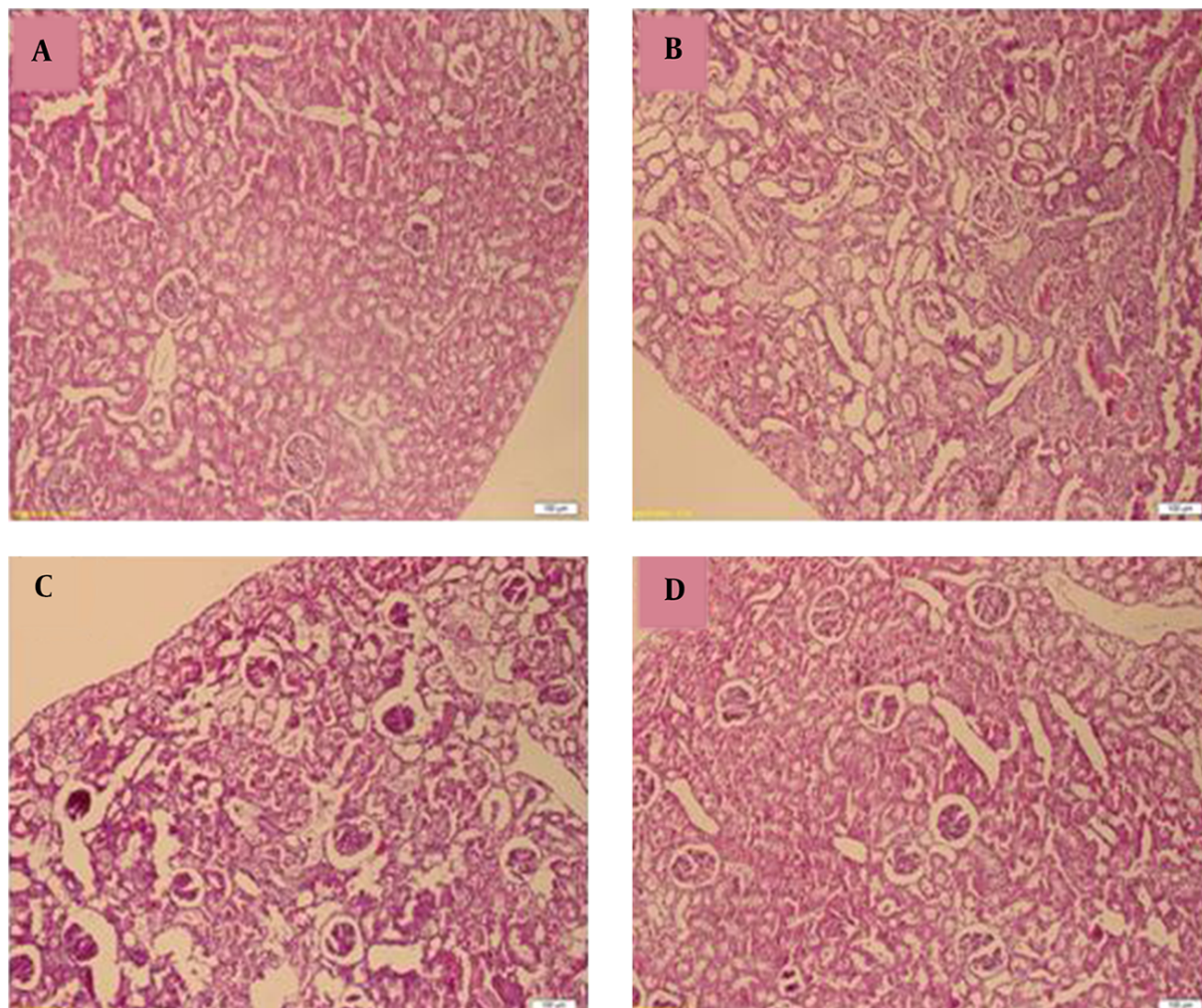
In the first stage of renal diseases, serum creatinine level is an important indicator than the urea. Serum urea concentrations start to elevate only after kidney parenchymal damage (30). Oral administration of NOE (250 and 500 mg kg<sup>-1</sup>) and 500 mg kg<sup>-1</sup> vitamin E reversed the increase in serum creatinine levels due to VCN injection. To our knowledge, there is no report on the nephroprotective effects of *N. officinale* in different models of renal injury. Similar inhibitory effect on serum creatinine concentration suggested about vitamin E and other antioxidant in the VIN (8-11). Kadkhodae and et al. observed that

co-administration of moderate doses of vitamins C and E had beneficial effects on renal preservation in GM-induced nephrotoxicity in rat (31). The increased levels of plasma urea, because of VCM injection, also significantly reduced by NOE at 500 mg kg<sup>-1</sup> dose, however, vitamin E reduced plasma levels approximately 6% -10%. This finding regarding vitamin E to some extent is inconsistent to what has been reported by Naghibi et al., (8). One possible explanation for these different results might be hidden in the fact that bioavailability of vitamin E in parenteral route is more than their oral intake (32). Therefore, in our experimental condition (oral administration), it is possible that vitamin E did not reach sufficient plasma levels to show his reducing effect on the plasma urea levels. It is important to mention that NOE and vitamin E efficiently prevented VCM induced decrease in creatinine clearance.

Changes in body and kidney weights are valuable indicators of severe renal toxicity in the experimental models (6, 8, 9, 33). In our experimental condition, VCM caused a significant reduction in the body weight and increased the ratio of average kidneys to 100 g body weight. Pre-treatment with NOE and vitamin E reversed the indicated changes at the applied dose, as their effects were statistically significant at the highest dose. In agreement with this finding Naghibi et al., observed that subcutaneous injection of vitamin E significantly reduced the changes in body and kidney weights due to VCM toxicity (8, 9).

The precise mechanism VCM-induced renal toxicity is not very clear, however, the role of oxidative stress in the pathogenesis of VCM-induced nephrotoxicity has been suggested by many investigators (3-7). Reactive oxygen species (ROS) induce lipid peroxidation through interaction with the membrane bound polyunsaturated fatty



**Figure 4.** Light Microscopy of Renal Tissue from Rats

A, Control (renal tubules are normal). B, vancomycin alone (Tubules show extensive and marked parenchymal damage, such as interstitial swelling, tubular dilatation and Neutrophil (PMN) infiltration. C, Simultaneous treatment with vancomycin and vitamin E; D, Simultaneous treatment with vancomycin and *Nasturtium officinale*. Administration of Vitamin E and *Nasturtium officinale* reduced the severity of the damage in the proximal renal tubules. (H and E).

acids. MDA is the final metabolite of lipid peroxidation chain; it indicates an increase of free radical generation (34). In the present study, the values of kidney MDA considerably increased in VCM-treated rats. Oral administration of NOE and vitamin E were able to inhibit the increase in the kidney MDA levels as a result of VCM toxicity. Several investigations suggested antioxidant properties of *N. officinale*. Watercress ingestion exhibited noticeable antioxidant effects against exercise-induced DNA damage and lipid peroxidation (35). Water and ethanol extracts of watercress also inhibited lipid peroxidation in linoleic acid, liver, brain, and kidney homogenate model systems (36). In our earlier study we found that NOE exhibited a no-

ticeable anti-inflammatory activity in several animal models of inflammation (17). Moreover, free radical scavenging properties of phenolic and flavonoid compounds were confirmed in some studies (37-39). In this study, phenolic and flavonoid contents of NOE detected to be  $71 \pm 6.23$  gallic acid equivalents/g dried extract and  $95.26 \pm 7.6$  mg rutin equivalents/g dried extract, respectively. Based on this, it is likely that beneficial effects of *N. officinale* in reducing of VCM renal toxicity, were mediated through antioxidant pathway. Histological observation confirmed the biochemical finding. Biopsies from the kidney of VCM-treated rats showed a marked renal injury with tubular epithelial cell desquamation, swelling, and tubular dilata-

tion. Histopathological changes were significantly ameliorated by NOE- and vitamin E administration.

In conclusion, this study is the first scientific demonstration that proposes renoprotective potential of NOE and also confirms its traditional use as a treatment for urinary disorders. Further studies are needed to recognize and purify the active phyto-ingredients from NOE that are important in its nephroprotective effect.

### Acknowledgments

The authors appreciate the staff of Medicinal plants research center of Yasuj University of Medical Sciences for their helps.

### Footnotes

**Authors' Contribution:** Study concept and design, Hossein Sadeghi, Masoumeh Karami, and Mostafa Mostafazadeh; analysis and interpretation of data, Hossein Sadeghi, Masoumeh Karami, Mostafa Mostafazadeh, Heibatollah Sadeghi, Fouad Mehraban, Esmaeel Panahi Kokhdan, Seyed Reza Abtahi, and Moslem Sayahi; drafting of the manuscript, Mostafa Mostafazadeh, critical revision of the manuscript for important intellectual content, Hossein Sadeghi.

**Funding/Support:** This work was supported by the research council of the AJA University of Medical Sciences, Tehran, IR Iran.

### References

- Elyasi S, Khalili H, Dashti-Khavidaki S, Mohammadpour A. Vancomycin-induced nephrotoxicity: mechanism, incidence, risk factors and special populations. A literature review. *Eur J Clin Pharmacol.* 2012;**68**(9):1243-55. doi: [10.1007/s00228-012-1259-9](https://doi.org/10.1007/s00228-012-1259-9). [PubMed: [22411630](https://pubmed.ncbi.nlm.nih.gov/22411630/)].
- Gupta A, Biyani M, Khaira A. Vancomycin nephrotoxicity: myths and facts. *Neth J Med.* 2011;**69**(9):379-83. [PubMed: [21978980](https://pubmed.ncbi.nlm.nih.gov/21978980/)].
- Alkhunaizi AM, Hinedi K. Vancomycin-induced acute tubular necrosis. *Saudi Med J.* 2014;**35**(9):1140-2. [PubMed: [25228192](https://pubmed.ncbi.nlm.nih.gov/25228192/)].
- Basarslan F, Yilmaz N, Ates S, Ozgur T, Tutanc M, Motor VK, et al. Protective effects of thymoquinone on vancomycin-induced nephrotoxicity in rats. *Hum Exp Toxicol.* 2012;**31**(7):726-33. doi: [10.1177/0960327111433185](https://doi.org/10.1177/0960327111433185). [PubMed: [22318306](https://pubmed.ncbi.nlm.nih.gov/22318306/)].
- Elyasi S, Khalili H, Hatamkhani S, Dashti-Khavidaki S. Prevention of vancomycin induced nephrotoxicity: a review of preclinical data. *Eur J Clin Pharmacol.* 2013;**69**(4):747-54. doi: [10.1007/s00228-012-1406-3](https://doi.org/10.1007/s00228-012-1406-3). [PubMed: [22996076](https://pubmed.ncbi.nlm.nih.gov/22996076/)].
- Konishi H, Morita Y, Mizumura M, Iga I, Nagai K. Difference in nephrotoxicity of vancomycin administered once daily and twice daily in rats. *J Chemother.* 2013;**25**(5):273-8. doi: [10.1179/1973947812Y.0000000067](https://doi.org/10.1179/1973947812Y.0000000067). [PubMed: [24070134](https://pubmed.ncbi.nlm.nih.gov/24070134/)].
- Oktem F, Arslan MK, Ozguner F, Candir O, Yilmaz HR, Ciris M, et al. In vivo evidences suggesting the role of oxidative stress in pathogenesis of vancomycin-induced nephrotoxicity: protection by erdoesteine. *Toxicology.* 2005;**215**(3):227-33. doi: [10.1016/j.tox.2005.07.009](https://doi.org/10.1016/j.tox.2005.07.009). [PubMed: [16112787](https://pubmed.ncbi.nlm.nih.gov/16112787/)].
- Naghbi B, Ghafghazi T, Hajhashemi V, Talebi A, Taheri D. The effect of vitamin E in prevention of vancomycin-induced nephrotoxicity in rats. *Res Pharm Sci.* 2007;**1**(2):104-11.
- Naghbi B, Ghafghazi T, Hajhashemi V, Talebi A, Taheri D. The effect of 2,3-dihydroxybenzoic acid and tempol in prevention of vancomycin-induced nephrotoxicity in rats. *Toxicology.* 2007;**232**(3):192-9. doi: [10.1016/j.tox.2007.01.005](https://doi.org/10.1016/j.tox.2007.01.005). [PubMed: [17296255](https://pubmed.ncbi.nlm.nih.gov/17296255/)].
- Ahmida MH. Protective role of curcumin in nephrotoxic oxidative damage induced by vancomycin in rats. *Exp Toxicol Pathol.* 2012;**64**(3):149-53. doi: [10.1016/j.etp.2010.07.010](https://doi.org/10.1016/j.etp.2010.07.010). [PubMed: [20832269](https://pubmed.ncbi.nlm.nih.gov/20832269/)].
- Ocak S, Gorur S, Hakverdi S, Celik S, Erdogan S. Protective effects of caffeic acid phenethyl ester, vitamin C, vitamin E and N-acetylcysteine on vancomycin-induced nephrotoxicity in rats. *Basic Clin Pharmacol Toxicol.* 2007;**100**(5):328-33. doi: [10.1111/j.1742-7843.2007.00051.x](https://doi.org/10.1111/j.1742-7843.2007.00051.x). [PubMed: [17448119](https://pubmed.ncbi.nlm.nih.gov/17448119/)].
- Humanes B, Jado JC, Camano S, Lopez-Parra V, Torres AM, Alvarez-Sala LA, et al. Protective Effects of Cilastatin against Vancomycin-Induced Nephrotoxicity. *Biomed Res Int.* 2015;**2015**:704382. doi: [10.1155/2015/704382](https://doi.org/10.1155/2015/704382). [PubMed: [26504822](https://pubmed.ncbi.nlm.nih.gov/26504822/)].
- Mergenhagen KA, Borton AR. Vancomycin nephrotoxicity: a review. *J Pharm Pract.* 2014;**27**(6):545-53. doi: [10.1177/0897190014546114](https://doi.org/10.1177/0897190014546114). [PubMed: [25266809](https://pubmed.ncbi.nlm.nih.gov/25266809/)].
- Asadi MS, Mirvaghefi AR, Nematollahi MA, Banaee M, Ahmadi K. Effects of Watercress (*Nasturtium nasturtium*) extract on selected immunological parameters of rainbow trout (*Oncorhynchus mykiss*). *Open Vet J.* 2012;**2**(1):32-9. [PubMed: [26623289](https://pubmed.ncbi.nlm.nih.gov/26623289/)].
- Bown D. *Encyclopedia of herbs and their uses*. New York: Dorling Kindersley Limited; 1995. p. 165-289.
- Hyun H, Park H, Jeong J, Kim H, Oh HI, et al. Effects of Watercress Containing Rutin and Rutin Alone on the Proliferation and Osteogenic Differentiation of Human Osteoblast-like MG-63 Cells. *Korean J Physiol Pharmacol.* 2014;**18**(4):347-52. doi: [10.4196/kjpp.2014.18.4.347](https://doi.org/10.4196/kjpp.2014.18.4.347). [PubMed: [25177168](https://pubmed.ncbi.nlm.nih.gov/25177168/)].
- Sadeghi H, Mostafazadeh M, Sadeghi H, Naderian M, Barmak MJ, Talebianpoor MS, et al. In vivo anti-inflammatory properties of aerial parts of *Nasturtium officinale*. *Pharm Biol.* 2014;**52**(2):169-74. doi: [10.3109/13880209.2013.821138](https://doi.org/10.3109/13880209.2013.821138). [PubMed: [24160746](https://pubmed.ncbi.nlm.nih.gov/24160746/)].
- Yazdanparast R, Bahramikia S, Ardestani A. *Nasturtium officinale* reduces oxidative stress and enhances antioxidant capacity in hypercholesterolaemic rats. *Chem Biol Interact.* 2008;**172**(3):176-84. doi: [10.1016/j.cbi.2008.01.006](https://doi.org/10.1016/j.cbi.2008.01.006). [PubMed: [18325487](https://pubmed.ncbi.nlm.nih.gov/18325487/)].
- Bahramikia S, Yazdanparast R. Antioxidant efficacy of *Nasturtium officinale* extracts using various in vitro assay systems. *J Acupunct Meridian Stud.* 2010;**3**(4):283-90. doi: [10.1016/S2005-2901\(10\)60049-0](https://doi.org/10.1016/S2005-2901(10)60049-0). [PubMed: [21185544](https://pubmed.ncbi.nlm.nih.gov/21185544/)].
- Halliwell B, Gutteridge JMC. *Free radicals in biology and medicine*. USA: Oxford University Press; 2015.
- Abdel-Naim AB, Abdel-Wahab MH, Attia FF. Protective effects of vitamin E and probucol against gentamicin-induced nephrotoxicity in rats. *Pharmacol Res.* 1999;**40**(2):183-7. doi: [10.1006/phrs.1999.0494](https://doi.org/10.1006/phrs.1999.0494).
- Atasayar S, Gurer-Orhan H, Orhan H, Gurel B, Girgin G, Ozgunes H. Preventive effect of aminoguanidine compared to vitamin E and C on cisplatin-induced nephrotoxicity in rats. *Exp Toxicol Pathol.* 2009;**61**(1):23-32. doi: [10.1016/j.etp.2008.04.016](https://doi.org/10.1016/j.etp.2008.04.016). [PubMed: [18684602](https://pubmed.ncbi.nlm.nih.gov/18684602/)].
- Kalaiselvi P, Pragasam V, Chinnikrishnan S, Veena CK, Sundarapandian R, Varalakshmi P. Counteracting adriamycin-induced oxidative stress by administration of N-acetyl cysteine and vitamin E. *Clin Chem Lab Med.* 2005;**43**(8):834-40. doi: [10.1515/CCLM.2005.140](https://doi.org/10.1515/CCLM.2005.140). [PubMed: [16201893](https://pubmed.ncbi.nlm.nih.gov/16201893/)].
- Sadeghi H, Zarezade V, Sadeghi H, Akbartabar Toori M, Jafari Barmak M, Azizi A, et al. Anti-inflammatory Activity of *Stachys Ptilifera* Benth. *Iran Red Crescent Med J.* 2014;**16**(9). e19259. doi: [10.5812/ircmj.19259](https://doi.org/10.5812/ircmj.19259). [PubMed: [25593730](https://pubmed.ncbi.nlm.nih.gov/25593730/)].

25. Blainski A, Lopes GC, de Mello JC. Application and analysis of the folin ciocalteu method for the determination of the total phenolic content from *Limonium brasiliense* L. *Molecules*. 2013;**18**(6):6852-65. doi: [10.3390/molecules18066852](https://doi.org/10.3390/molecules18066852). [PubMed: [23752469](https://pubmed.ncbi.nlm.nih.gov/23752469/)].
26. Louaileche H, Hammiche D, Hamoudi F. Total phenolic, flavonoid contents and in vitro antioxidant activity of Algerian date palm varieties: a comparative study. *Am J Food Sci Health*. 2015;**3**:63-8.
27. Burtis CA, Ashwood ER, Bruns DE. *Tietz textbook of clinical chemistry and molecular diagnostics*. Elsevier Health Sciences; 2015.
28. Fatima N, Zaman MU, Kamal S, Hameed A. Detection of early cisplatin induced nephrotoxicity by serial estimation of glomerular filtration rate: Comparison of various methods. *Int J Nephrol Urol*. 2010;**2**(3):422-30.
29. Ohkawa H, Ohishi N, Yagi K. Assay for lipid peroxides in animal tissues by thiobarbituric acid reaction. *Anal Biochem*. 1979;**95**(2):351-8. doi: [10.1016/0003-2697\(79\)90738-3](https://doi.org/10.1016/0003-2697(79)90738-3).
30. Bellomo R, Kellum JA, Ronco C. Acute kidney injury. *Lancet*. 2012;**380**(9843):756-66. doi: [10.1016/S0140-6736\(11\)61454-2](https://doi.org/10.1016/S0140-6736(11)61454-2). [PubMed: [22617274](https://pubmed.ncbi.nlm.nih.gov/22617274/)].
31. Kadkhodae M, Khastar H, Faghihi M, Ghaznavi R, Zahmatkesh M. Effects of co-supplementation of vitamins E and C on gentamicin-induced nephrotoxicity in rat. *Exp Physiol*. 2005;**90**(4):571-6. doi: [10.1113/expphysiol.2004.029728](https://doi.org/10.1113/expphysiol.2004.029728). [PubMed: [15769882](https://pubmed.ncbi.nlm.nih.gov/15769882/)].
32. Bourne N, Wathes DC, McGowan M, Laven R. A comparison of the effects of parenteral and oral administration of supplementary vitamin E on plasma vitamin E concentrations in dairy cows at different stages of lactation. *Livest Sci*. 2007;**106**(1):57-64. doi: [10.1016/j.livsci.2006.07.001](https://doi.org/10.1016/j.livsci.2006.07.001).
33. Sadeeshkumar V, Arul D, Ravichandran S. Protective effects of gallic acid in the renal markers, histopathology and immunohistochemical studies on vancomycin induced nephrotoxic rats. *Int J Adv Life Sci*. 2013;**6**:356-65.
34. Niki E. Biomarkers of lipid peroxidation in clinical material. *Biochim Biophys Acta*. 2014;**1840**(2):809-17. doi: [10.1016/j.bbagen.2013.03.020](https://doi.org/10.1016/j.bbagen.2013.03.020). [PubMed: [23541987](https://pubmed.ncbi.nlm.nih.gov/23541987/)].
35. Fogarty MC, Hughes CM, Burke G, Brown JC, Davison GW. Acute and chronic watercress supplementation attenuates exercise-induced peripheral mononuclear cell DNA damage and lipid peroxidation. *Br J Nutr*. 2013;**109**(2):293-301. doi: [10.1017/S0007114512000992](https://doi.org/10.1017/S0007114512000992). [PubMed: [22475430](https://pubmed.ncbi.nlm.nih.gov/22475430/)].
36. Ozen T. Investigation of antioxidant properties of *Nasturtium officinale* (watercress) leaf extracts. *Acta Pol Pharm*. 2009;**66**(2):187-93. [PubMed: [19719054](https://pubmed.ncbi.nlm.nih.gov/19719054/)].
37. Ciesla L, Kowalska I, Oleszek W, Stochmal A. Free radical scavenging activities of polyphenolic compounds isolated from *Medicago sativa* and *Medicago truncatula* assessed by means of thin-layer chromatography DPPH rapid test. *Phytochem Anal*. 2013;**24**(1):47-52. doi: [10.1002/pca.2379](https://doi.org/10.1002/pca.2379). [PubMed: [22745039](https://pubmed.ncbi.nlm.nih.gov/22745039/)].
38. Di Meo F, Lemaire V, Cornil J, Lazzaroni R, Duroux JL, Olivier Y, et al. Free radical scavenging by natural polyphenols: atom versus electron transfer. *J Phys Chem A*. 2013;**117**(10):2082-92. doi: [10.1021/jp3116319](https://doi.org/10.1021/jp3116319). [PubMed: [23418927](https://pubmed.ncbi.nlm.nih.gov/23418927/)].
39. Kumar S, Pandey AK. Chemistry and biological activities of flavonoids: an overview. *ScientificWorldJournal*. 2013;**2013**:162750. doi: [10.1155/2013/162750](https://doi.org/10.1155/2013/162750). [PubMed: [24470791](https://pubmed.ncbi.nlm.nih.gov/24470791/)].