



# Zingerone attenuates Bleomycin-Induced Pulmonary Fibrosis in Rats

Mohammad Taghi Mansouri<sup>1,2</sup>, Hossein Rajabi Vardanjani<sup>1,\*</sup>, Ali Asghar Hemmati<sup>1</sup>, Mohammad Reza Tabandeh<sup>3,4</sup>, Anahita Rezaie<sup>5</sup>, Marzie Pashmforosh<sup>1</sup> and Kambiz Ahmadi Angali<sup>6</sup>

<sup>1</sup>Department of Pharmacology, School of Pharmacy, Medicinal Plant Research Center, Ahvaz Jundishapur University of Medical Sciences, Ahvaz, Iran

<sup>2</sup>Department of Anesthesiology, Columbia University Medical center, New York, NY 10032, USA

<sup>3</sup>Department of Biochemistry and Molecular Biology, Faculty of Veterinary Medicine, Shahid Chamran University of Ahvaz, Ahvaz, Iran

<sup>4</sup>Stem Cells and Transgenic Technology Research Center, Shahid Chamran University of Ahvaz, Ahvaz, Iran

<sup>5</sup>Department of Pathobiology, Faculty of Veterinary Medicine, Shahid Chamran University of Ahvaz, Ahvaz, Iran

<sup>6</sup>Department of Biostatistics, School of Public Health, Ahvaz Jundishapur University of Medical Sciences, Ahvaz, Iran

\*Corresponding author: Department of Pharmacology, Faculty of Pharmacy, Jundishapur University of Medical Sciences, Ahvaz, Iran. Tel: +98-9132821433, Email: rajabi.h@ajums.ac.ir

Received 2018 June 02; Revised 2018 June 20; Accepted 2018 June 27.

## Abstract

**Background:** Idiopathic pulmonary fibrosis (IPF) is a progressive lung disorder that results in severe respiratory failure and death. The main characteristic of IPF is excess oxidative stress, fibroblast activation, increased collagen deposition, and multiple fibrotic lesions. Zingerone exhibits potent antioxidant, anti-inflammatory, and anti-fibrotic activities.

**Objectives:** The aim of the study was to evaluate the protective effect of zingerone on bleomycin-induced pulmonary fibrosis (PF) and underlying mechanisms in rats.

**Methods:** PF was induced by bleomycin (5 mg/kg, intratracheally) in male Sprague-Dawley rats and then, zingerone (10 - 40 mg/kg, orally) was administered for 21 days' post-bleomycin-instillation. After euthanizing the rats, the biochemical and histopathological markers of lung tissue were determined.

**Results:** The findings showed that bleomycin significantly increased inflammatory and fibrotic responses, the level of malondialdehyde (MDA), the influx of inflammatory cells into the bronchoalveolar fluid (BALF), and hydroxyproline content of the lung ( $P < 0.01$ ). In addition, the level of glutathione (GSH), the activity of superoxide dismutase (SOD) and glutathione peroxidase (GPx) decreased in the lung of bleomycin-instilled rats ( $P < 0.01$ ). However, zingerone (20 and 40 mg/kg) significantly decreased histopathological injuries in H&E (Hematoxylin and eosin) and Masson's trichrome-stained sections, hydroxyproline content and infiltration of leukocytes into BALF and oxidative markers, in a dose-dependent manner ( $P < 0.01$ ). In addition, zingerone (40 mg/kg) significantly reduced the level of MDA in bleomycin-instilled rats ( $P < 0.01$ ).

**Conclusions:** These findings suggest that zingerone has protective effects against bleomycin-induced PF, which may be due to its anti-inflammatory and antioxidant activity.

**Keywords:** Zingerone, Pulmonary Fibrosis, Bleomycin, Antioxidant

## 1. Background

Idiopathic pulmonary fibrosis (IPF) as a fibroproliferative lung disorder with unknown etiology is characterized by significant oxidative injury, massive collagen deposition, lung remodeling, and vigorous fibrotic lesions. The current treatment strategies cannot effectively ameliorate IPF. The lung failure is progressed and eventually, death occurs within 3 - 5 years after diagnosis (1).

A powerful and reproducible animal model of IPF is produced by bleomycin (BLM) as a cytotoxic antibiotic. The most prevalent mechanism suggested for the pathogenesis of pulmonary fibrosis (PF) is that bleomycin induces DNA-breakage and oxidative stress leading to apoptosis and obliteration of alveolar epithelial cells. These

events lead to the recruitment of leukocytes, overproduction of free radical species, and abnormal secretion of inflammatory and fibrotic mediators (such as IL-1 $\beta$ , TNF- $\alpha$ , and TGF- $\beta$ ). Then, collagen deposition and lung remodeling are progressed by myofibroblast activation (2). The TGF- $\beta$  signaling pathway and mitogen-activated protein kinases (MAPKs) signaling are involved in activating myofibroblasts (3). However, previous studies have shown that antioxidant and anti-inflammatory agents have protective effects against IPF (4).

Zingerone, an active non-volatile ingredient of ginger (*Zingiber officinale*), has been known as a multi-target agent, displaying various pharmacological effects. For instance, zingerone exhibits antioxidant activity equal to

ascorbic acid activity and can attenuate oxidative injuries in the lung (5), liver (6), and kidney (7). The protective effects of zingerone against lung injury induced by lipopolysaccharide (LPS) have been reported by suppressing neutrophil influx and production of proinflammatory cytokines in mice. The protective effects of zingerone are attributed to the inhibition of the signaling pathways of nuclear factor-kappa B (NF- $\kappa$ B) and mitogen-activated protein kinases (MAPKs) (8). In addition, zingerone reduces inflammatory and fibrotic responses in various experimental animal models of diseases accompanied by the decrease of TGF- $\beta$  levels (6, 9, 10).

## 2. Objectives

Despite evidence of zingerone anti-fibrotic activity in different animal models, there is no study of its effect on pulmonary fibrosis. Therefore, the present study was conducted to evaluate the probable beneficial effects of zingerone against bleomycin-induced PF and underlying mechanisms.

## 3. Methods

### 3.1. Chemicals

Zingerone and bleomycin sulfate were purchased from Sigma-Aldrich (St. Louis, MO, USA) and Nippon Kayaku Co., Ltd., respectively. All other reagents were of analytical grade. A fresh concentration of drugs was prepared immediately before use.

### 3.2. Animal

Healthy male Sprague-Dawley rats (200 - 250 g) were obtained from the animal house and research center of Jundishapur University of Medical Sciences, Ahvaz, Iran. They were kept in standard conditions with free access to water and rodent laboratory chow *ad libitum*. The experimental design was approved by the Institutional Animal Ethics Committee of Jundishapur University of Medical Sciences (IR.AJUMS.REC.1395.150) and the experiments were conducted according to the NIH Guide for Care and Use of Laboratory Animals.

### 3.3. Induction of Pulmonary Fibrosis

The PF model was induced in accordance with previous studies (11). After the rats were anesthetized with intraperitoneal injection of ketamine (75 mg/kg) and xylazine (5 mg/kg), bleomycin (5 mg/kg body weight in 0.25 mL saline) was instilled intratracheally. The vehicle group received equal amounts of 0.9% saline instead of bleomycin.

### 3.4. Experimental Design

The optimal dose of bleomycin (5 mg/kg) was obtained from a preliminary study that led to proper pulmonary fibrosis without affecting survival. Thirty-six rats were randomly assigned to the following groups: I (saline + saline), II (bleomycin (BLM) + vehicle), III (BLM + zingerone 10 mg/kg), IV (BLM + zingerone 20 mg/kg), V (BLM + zingerone 40 mg/kg), VI (saline + zingerone 40 mg/kg). Zingerone was dissolved in saline and administered by gavage for 21 consecutive days after intratracheal bleomycin administration. The route of administration, doses of zingerone, and the sample size were based on previous studies (8, 12). The body weight of the rats was evaluated weekly during the experiment. At the end of the experiments, the rats were euthanized and the whole lung was dissected out, washed with saline, and weighed. The lung index was calculated by the ratio of the lung wet weight (mg) to body weight (g).

### 3.5. Bronchoalveolar Fluid and Lung Sample Collection

By cannulating the trachea with a blunt needle, the airways were washed four times with 5 mL of phosphate-buffered saline (PBS). Then, cell suspensions were centrifuged and the cell pellet was suspended by hypotonic lysis using 1% glacial acetic acid. Total leukocytes and differential cell numbers were counted by using hemocytometer and Wright-Giemsa staining (4). Besides, the left lung was used for histological examination and right lung tissue was homogenized in cold radioimmune precipitation assay (RIPA) lysis buffer to make a 10% homogenate (w/v). After centrifuging at 11180 g for 10 min at 4°C, the supernatants were maintained at -80°C for subsequent assessment. The total protein content of tissue homogenates was estimated by the Bradford method.

### 3.6. Hydroxyproline Measurement

The hydroxyproline content of lung tissue was measured in accordance with the method described by Edwards and O'Brien (13). The absorbance was read at 550 nm. The hydroxyproline content was calculated as mg/g lung tissue.

### 3.7. Estimation of Malondialdehyde and Glutathione

The malondialdehyde (MDA) content of lung tissue homogenates was determined in accordance with the TBA method (14). The reaction of thiobarbituric acid with MDA at high temperature and low pH leads to the formation of a red fluorescent complex. The absorbance was determined at 532 nm. The results were given in nmol/g tissue protein. The glutathione (GSH) level of lung tissue was measured by the method previously described by Ellman (15). The values were expressed as nmol/mg protein.

### 3.8. Determination of Superoxide Dismutase and Glutathione Peroxidase Activities

The glutathione peroxidase (GPx) and superoxide dismutase (SOD) activity was measured using a commercial RANSOD and RANSEL kits (Randox Labs, Crumlin, UK), according to the manufacturer's instruction. The activities of GPx and SOD were expressed as IU/mg tissue protein.

### 3.9. Histopathological Studies

Buffered formaldehyde (10%) was used to fix the left lung tissue. Then, the tissue specimens were embedded in paraffin and were cut into 5- $\mu$ m sections and stained with H&E (hematoxylin and eosin) and Masson's trichrome. A single-blind examination was done by an experienced pathologist to score fibrosis in accordance with the modified numerical Ashcroft's scale (0 - 8) (16).

### 3.10. Statistical Analysis

The statistical analysis was performed using PRISM version 5.01. The scores of fibrosis were analyzed by the Kruskal-Wallis test and other variables by the Two-way ANOVA or One-way ANOVA, followed by an appropriate post hoc test. Data were expressed as means  $\pm$  SEM.  $P < 0.05$  was considered as statistical significance.

## 4. Results

### 4.1. Effect of Zingerone on Body Weight and Lung Index

Bleomycin caused a significant body weight loss in exposed rats compared to the vehicle group at weeks 1, 2, and 3 ( $P < 0.0001$ ). Zingerone (20 and 40 mg/kg) significantly increased weight gain compared to the bleomycin group during the experiments (group effect  $P < 0.0001$ , time effect  $P = 0.0002$ , and interaction effect  $P < 0.0001$  in Two-way ANOVA) (Figure 1A).

Bleomycin significantly increased the normal lung index on day 21. Zingerone treatment (20 and 40 mg/kg) significantly decreased the lung index compared to the bleomycin group ( $P < 0.0001$ ) (Figure 1B).

### 4.2. Effect of Zingerone on Bronchoalveolar Fluid Cells

BLM significantly increased the normal total leukocyte count in BLAF ( $P < 0.01$ ). Zingerone treatment (20 and 40 mg/kg) significantly reduced the total leukocyte number ( $P < 0.01$ ) (Figure 2A). BLM significantly increased the normal neutrophil and lymphocyte proportions and significantly decreased the macrophages proportion ( $P < 0.01$ ). Zingerone (20 and 40 mg/kg) significantly reversed the differential cell percentage changes in bronchoalveolar fluid (BALF) as compared to the BLM group ( $P < 0.01$ ). The total cell number and differential percentage of leukocytes were not significantly different between the zingerone-treated group (10 mg/kg) and the BLM group (Figure 2B-D).

### 4.3. Effect of Zingerone on Oxidative Markers of Lung Tissue

Bleomycin significantly enhanced the normal lung MDA level ( $P < 0.01$ ) and only did zingerone (40 mg/kg) significantly reduce the MDA group compared to the BLM group ( $P < 0.01$ ) (Figure 3A). Bleomycin significantly decreased the tissue GSH content and the activity of SOD and GPx as compared to the vehicle-treated group ( $P < 0.01$ ). Meanwhile, zingerone (10 - 40 mg/kg) significantly enhanced the GSH concentration and activity of SOD and GPx as compared to the BLM-group ( $P < 0.01$ ) (Figure 3B-D).

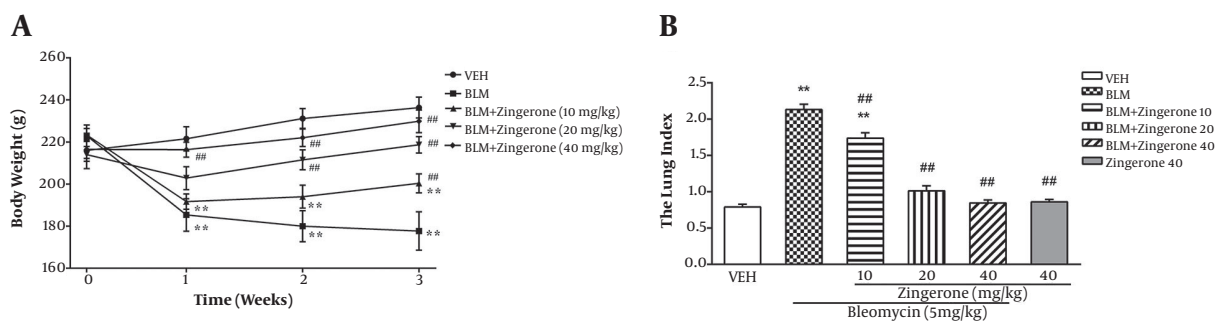
### 4.4. Effect of Zingerone on Histopathological Lesions and Lung Hydroxyproline

The evaluation of H&E and Masson's trichrome-stained sections revealed that the normal lung architecture was destroyed following bleomycin-instillation and a fibrotic pattern was observed (Figure 4A and B). BLM significantly increased the modified Ashcroft's scale and hydroxyproline content ( $P < 0.01$ ) (Figure 4C and D). Zingerone (10 - 40 mg/kg) dose-dependently decreased the fibrosis score as compared to the BLM group ( $P < 0.01$ ). Zingerone (20 and 40 mg/kg) significantly reduced lung hydroxyproline as compared to the BLM group ( $P < 0.01$ ), but zingerone (10 mg/kg) had no significant effect on hydroxyproline in BLM-instilled rats.

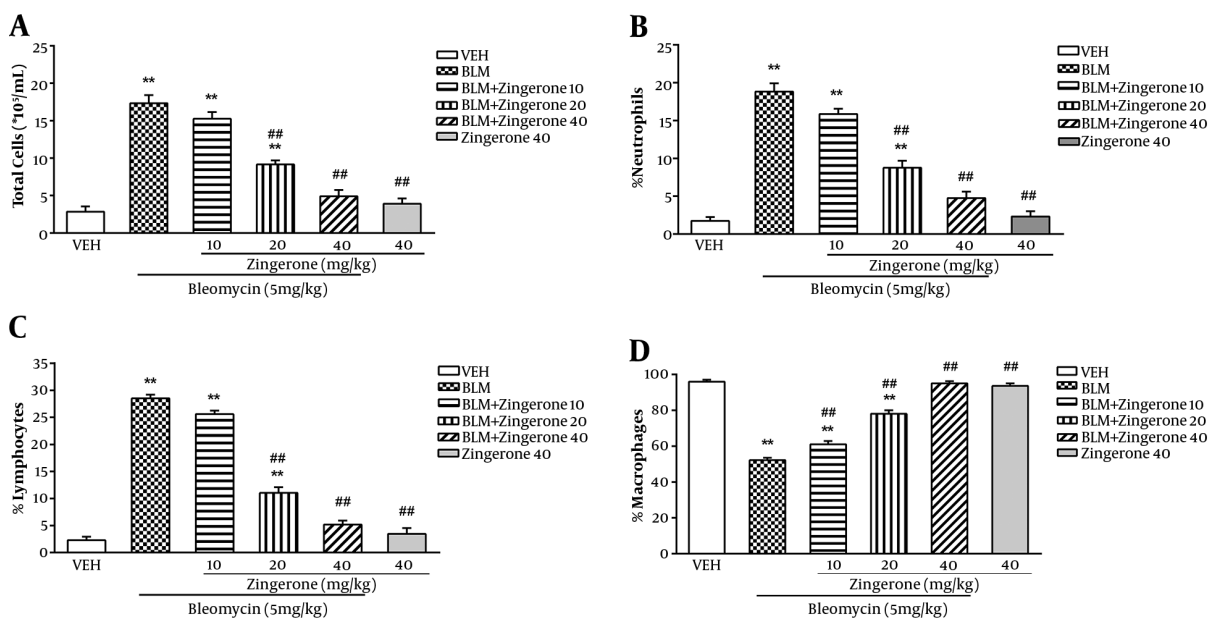
## 5. Discussion

Idiopathic pulmonary fibrosis is a deadly and progressive lung disorder. Despite numerous studies, a few drugs are available to treat this disorder (17). The bleomycin-induced animal model of IPF is widely used to investigate new anti-fibrotic compounds (18). Several agents with potent antioxidant and anti-inflammatory activities exhibit protective effects against bleomycin-induced lung injury (4, 19). Zingerone, as an interesting active ingredient of ginger (*Zingiber officinale*), exhibits potent antioxidant, anti-inflammatory, and anti-fibrotic activities in various animal models of disease (5-8, 20). However, its effect on pulmonary fibrosis has not been reported. For the first time in the present study, the possible ameliorative effect of zingerone against PF induced by bleomycin was determined in rats.

Our findings showed that zingerone clearly attenuated fibrotic lesions in the bleomycin group. The body weight loss, lung index, and total and differential cell numbers of BLAF, histopathological scores of fibrosis, and lung hydroxyproline content were significantly reversed by zingerone in a dose-dependent manner. In addition, zingerone reversed the GPx and SOD activity, as well as GSH and MDA levels, near to normal values in the vehicle group. In addition, zingerone solely did not have a significant effect on the measured variables compared to the vehicle group.



**Figure 1.** Effect of zingerone (10 - 40 mg/kg/day, orally) on PF induced by bleomycin (5 mg/kg, intratracheally) on body weight at weeks 1, 2, and 3 A, (Two-way ANOVA followed by Dunnett's test); and on lung index B, (One-way ANOVA followed by Tukey's test) in the rat model of PF. Data are expressed as means  $\pm$  SEM, (n = 6). \*\* P < 0.05 compared to the vehicle group; ## P < 0.05 compared to the BLM group.



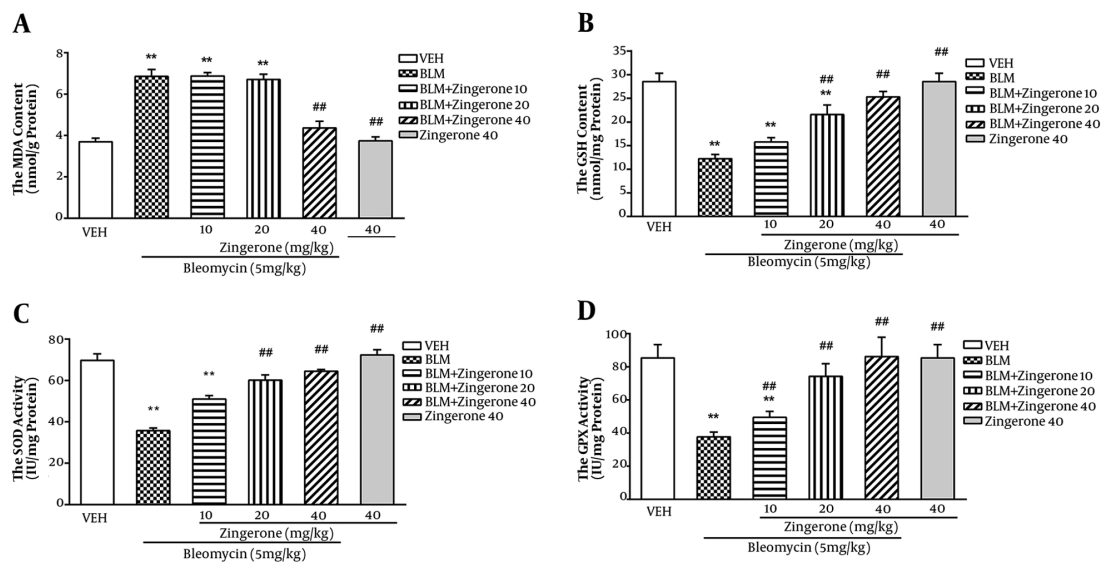
**Figure 2.** Effect of zingerone (10 - 40mg/kg/day, orally) on total cell count (A) percentages of neutrophils (B), lymphocytes (C) and macrophages (D) in BALF in bleomycin (5 mg/kg, intratracheally) rat model of PF. Data are expressed as means  $\pm$  SEM, (n = 6). \*\*P < 0.05 compared to the vehicle group; ##P < 0.05 compared to the BLM group. One-way ANOVA followed by Tukey's test.

The level of MDA, a lipid peroxidation by-product, mirrors the oxidative cell membrane damage that its level increases in the lung injury by bleomycin (19, 21). The tissue glutathione content and SOD and GPx enzymes as the most important antioxidant defenses play key roles in protection against oxidative stress caused by BLM (22, 23). In agreement with previous studies, our results showed that bleomycin markedly increased the levels of MDA in lung tissue. Meanwhile, SOD and GPx activities, as well as the GSH level, significantly reduced in bleomycin-instilled rats (24, 25). However, zingerone treatment significantly decreased the MDA level and improved the SOD and GPx ac-

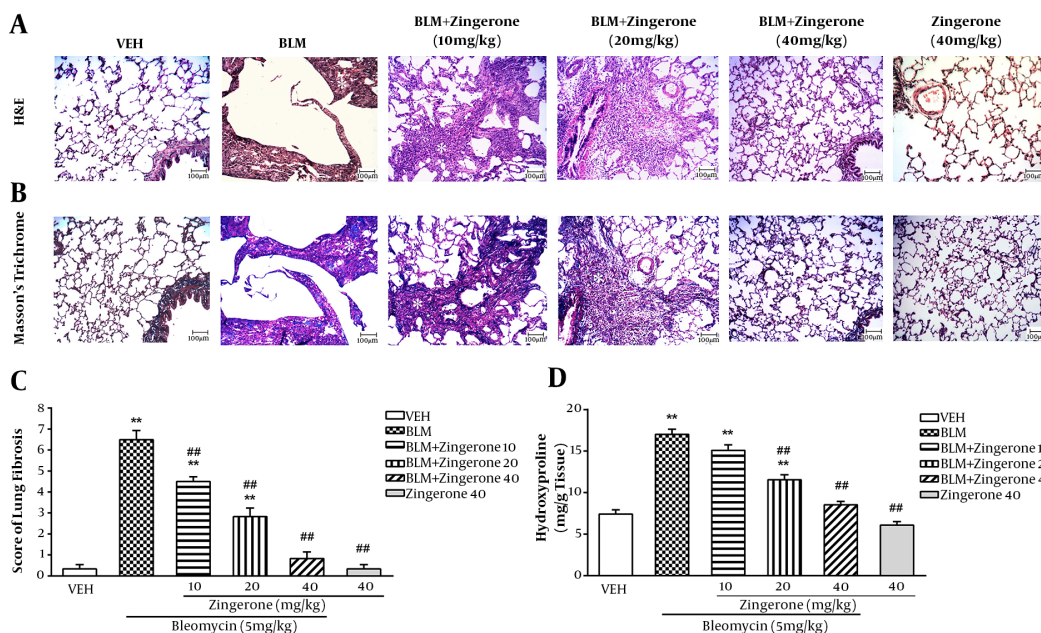
tivities, as well as, inhibited GSH depletion. The antioxidant effect of zingerone has been shown in other models of diseases including hepatic injury (6) and renal damage (7). Rao et al. showed that the oral administration of zingerone reduced the MDA content and elevated the SOD and GSH activity in gamma-radiated mice (26). Therefore, the ameliorative effect of zingerone against pulmonary fibrosis may be due to its potent antioxidant nature.

The influx of inflammatory cells in BALF as a lung inflammatory hallmark is exacerbated in pulmonary fibrosis. In addition, the percentage of lymphocytes and neutrophils increases while the macrophage proportion de-





**Figure 3.** Effect of zingerone (10 - 40 mg/kg/day, orally) on lung tissue levels of MDA (4A), GSH (4B) and activities of SOD (4C) and GPx (4D) in bleomycin (5 mg/kg, intratracheally) rat model of PF. Data are expressed as means  $\pm$  SEM, (n = 6). \*\*P < 0.05 compared to the vehicle group; ## P < 0.05 compared to the BLM group. One-way ANOVA followed by Tukey's test.



**Figure 4.** Effect of zingerone (10 - 40 mg/kg) on BLM-induced fibrosis shown in representative images of H&E (A) and Masson's trichrome-staining (B) (scale bars: 100  $\mu$ m, white star: Fibrotic foci) of rat lung sections on day 21. The dose-response of fibrosis changes (Kruskal-Wallis followed by Dunn's test)(C) and hydroxyproline content (One-way ANOVA followed by Tukey's test)(D) in different groups is shown. Data are expressed as means  $\pm$  SEM, (n = 6). \*\*P < 0.05 compared to the vehicle group; ## P < 0.05 compared to the BLM group.

creases in BALF in BLM groups (27, 28). The activated neutrophils and macrophage can produce toxic ROS and proteolytic factors, possibly worsening tissue damage (29).

The same pattern of leukocytes infiltration into BALF was observed in the present study in bleomycin-instilled rats. However, zingerone treatment ameliorated these patho-

logical changes in BALF. In agreement with our results, Xie et al. reported that zingerone suppressed neutrophil influx into BALF, alveolar hemorrhage, and pulmonary edema induced by lipopolysaccharide (8). Overall, our findings indicated that the protective effect of zingerone might be due to the attenuation of leukocytes recruitment into the lung.

The histopathological examination as a gold test is widely utilized to evaluate the efficiency of new anti-fibrotic drugs (30). Our findings support previous studies that bleomycin induces collagen deposition and lung fibrotic lesions (31). However, zingerone significantly reduced lung index and collagen deposition, as well as pulmonary fibrosis, in BLM-instilled rats. These results are consistent with other studies indicating that zingerone could improve inflammation and fibrosis via blocking the oxidative stress, as well as inhibiting the NF- $\kappa$ B and MAPKs activation, in various animal models such as hepatic and cardiac fibrosis (6, 10).

Taken together, zingerone exerts a protective effect against bleomycin-induced PF. Our findings suggested that zingerone exhibits antioxidant and anti-fibrotic activity and might be a novel therapeutic agent for the treatment of IPF. However, more investigations are needed to characterize the anti-fibrotic mechanism of zingerone.

## Footnotes

**Authors' Contribution:** Study concept and design: Mohammad Taghi Mansouri and Hossein Rajabi Vardanjani. Analysis and interpretation of data: Mohammad Taghi Mansouri, Hossein Rajabi Vardanjani, Mohammad Reza Tabandeh, Anahita Rezaie and Marzie Pashmforosh. Statistical analysis: Hossein Rajabi Vardanjani and Kambiz Ahmadi Angali.

**Conflict of Interests:** We would like to confirm that there is no known conflict of interests associated with this publication.

**Ethical Considerations:** The experimental design was approved by the Institutional Animal Ethics Committee of Jundishapur University of Medical Sciences (IR.AJUMS.REC.1395.150) and conducted according to the NIH Guide for Care and Use of Laboratory Animals.

**Funding/Support:** This study was supported by a grant (MPCR-9508) from the Medicinal Plants and Natural Products Research Center, funded by the Vice Chancellor for Research, Ahvaz Jundishapur University of Medical Sciences (Iran).

## References

1. Datta A, Scotton CJ, Chambers RC. Novel therapeutic approaches for pulmonary fibrosis. *Br J Pharmacol*. 2011;**163**(1):141-72. doi:

- 10.1111/j.1476-5381.2011.01247.x. [PubMed: 21265830]. [PubMed Central: PMC3085875].
2. Kalayarasan S, Sriram N, Sudhandiran G. Diallyl sulfide attenuates bleomycin-induced pulmonary fibrosis: Critical role of iNOS, NF- $\kappa$ B, TNF- $\alpha$  and IL-1 $\beta$ . *Life Sci*. 2008;**82**(23-24):1142-53. doi: 10.1016/j.lfs.2008.03.018. [PubMed: 18462759].
3. Meng XM, Nikolic-Paterson DJ, Lan HY. TGF- $\beta$ : The master regulator of fibrosis. *Nat Rev Nephrol*. 2016;**12**(6):325-38. doi: 10.1038/nrneph.2016.48. [PubMed: 27108839].
4. Cortijo J, Cerda-Nicolas M, Serrano A, Bioque G, Estrela JM, Santangelo F, et al. Attenuation by oral N-acetylcysteine of bleomycin-induced lung injury in rats. *Eur Respir J*. 2001;**17**(6):1228-35. doi: 10.1183/09031936.01.00049701. [PubMed: 11491169].
5. Rajan I, Narayanan N, Rabindran R, Jayasree PR, Manish Kumar PR. Zingerone protects against stannous chloride-induced and hydrogen peroxide-induced oxidative DNA damage in vitro. *Biol Trace Elem Res*. 2013;**155**(3):455-9. doi: 10.1007/s12011-013-9801-x. [PubMed: 24006104].
6. Cheong KO, Shin DS, Bak J, Lee C, Kim KW, Je NK, et al. Hepatoprotective effects of zingerone on carbon tetrachloride- and dimethylnitrosamine-induced liver injuries in rats. *Arch Pharm Res*. 2016;**39**(2):279-91. doi: 10.1007/s12272-015-0696-2. [PubMed: 26667466].
7. Safhi MM. Nephroprotective effect of zingerone against CCl<sub>4</sub>-induced renal toxicity in swiss albino mice: Molecular mechanism. *Oxid Med Cell Longev*. 2018;**2018**:2474831. doi: 10.1155/2018/2474831. [PubMed: 29636837]. [PubMed Central: PMC5831687].
8. Xie X, Sun S, Zhong W, Soromou LW, Zhou X, Wei M, et al. Zingerone attenuates lipopolysaccharide-induced acute lung injury in mice. *Int Immunopharmacol*. 2014;**19**(1):103-9. doi: 10.1016/j.intimp.2013.12.028. [PubMed: 24412620].
9. Lee W, Hwang MH, Lee Y, Bae JS. Protective effects of zingerone on lipopolysaccharide-induced hepatic failure through the modulation of inflammatory pathways. *Chem Biol Interact*. 2018;**281**:106-10. doi: 10.1016/j.cbi.2017.12.031. [PubMed: 29289488].
10. El-Bassossy HM, Al-Thubiani WS, Elberry AA, Mujallid MI, Ghareib SA, Azhar AS, et al. Zingerone alleviates the delayed ventricular repolarization and AV conduction in diabetes: Effect on cardiac fibrosis and inflammation. *PLoS One*. 2017;**12**(12). e0189074. doi: 10.1371/journal.pone.0189074. [PubMed: 29206854]. [PubMed Central: PMC5716606].
11. Egger C, Cannet C, Gerard C, Jarman E, Jarai G, Feige A, et al. Administration of bleomycin via the oropharyngeal aspiration route leads to sustained lung fibrosis in mice and rats as quantified by UTE-MRI and histology. *PLoS One*. 2013;**8**(5). e63432. doi: 10.1371/journal.pone.0063432. [PubMed: 23667616]. [PubMed Central: PMC3646779].
12. Kumar L, Chhibber S, Harjai K. Hepatoprotective effect of zingerone (4-(4-hydroxy-3-methoxyphenyl) butan-2-one) in lipopolysaccharide induced liver injury mouse model through down regulation of inflammatory mediators. *Int J Pharmacogn Phytochem Res*. 2014;**6**(2):308-14.
13. Edwards CA, O'Brien WJ. Modified assay for determination of hydroxyproline in a tissue hydrolyzate. *Clin Chim Acta*. 1980;**104**(2):161-7. doi: 10.1016/0009-8981(80)90192-8. [PubMed: 7389130].
14. Mihara M, Uchiyama M. Determination of malonaldehyde precursor in tissues by thiobarbituric acid test. *Anal Biochem*. 1978;**86**(1):271-8. doi: 10.1016/0003-2697(78)90342-1. [PubMed: 655387].
15. Ellman GL. Tissue sulfhydryl groups. *Arch Biochem Biophys*. 1959;**82**(1):70-7. doi: 10.1016/0003-9861(59)90090-6. [PubMed: 13650640].
16. Hubner RH, Gitter W, El Mokhtari NE, Mathiak M, Both M, Bolte H, et al. Standardized quantification of pulmonary fibrosis in histological samples. *Biotechniques*. 2008;**44**(4):507-11. 514-7. doi: 10.2144/000112729. [PubMed: 18476815].
17. Puglisi S, Torrisi SE, Vindigni V, Giuliano R, Palmucci S, Mule M, et al. New perspectives on management of idiopathic pulmonary fibrosis. *Ther Adv Chronic Dis*. 2016;**7**(2):108-20. doi: 10.1177/2040622315624276. [PubMed: 26977280]. [PubMed Central: PMC4772343].

18. Serrano-Mollar A, Closa D, Prats N, Blesa S, Martinez-Losa M, Cortijo J, et al. In vivo antioxidant treatment protects against bleomycin-induced lung damage in rats. *Br J Pharmacol*. 2003;**138**(6):1037-48. doi: [10.1038/sj.bjp.0705138](https://doi.org/10.1038/sj.bjp.0705138). [PubMed: [12684259](https://pubmed.ncbi.nlm.nih.gov/12684259/)]. [PubMed Central: [PMC1573750](https://pubmed.ncbi.nlm.nih.gov/PMC1573750/)].
19. Liang X, Tian Q, Wei Z, Liu F, Chen J, Zhao Y, et al. Effect of Feining on bleomycin-induced pulmonary injuries in rats. *J Ethnopharmacol*. 2011;**134**(3):971-6. doi: [10.1016/j.jep.2011.02.008](https://doi.org/10.1016/j.jep.2011.02.008). [PubMed: [21333727](https://pubmed.ncbi.nlm.nih.gov/21333727/)].
20. Goudarzi M, Kalantar M, Kalantar H. The Hepatoprotective effect of gallic acid on mercuric chloride-induced liver damage in rats. *Jundishapur J Nat Pharm Prod*. 2017;**12**(4).
21. Guan C, Qiao S, Lv Q, Cao N, Wang K, Dai Y, et al. Orally administered berberine ameliorates bleomycin-induced pulmonary fibrosis in mice through promoting activation of PPAR-gamma and subsequent expression of HGF in colons. *Toxicol Appl Pharmacol*. 2018;**343**:1-15. doi: [10.1016/j.taap.2018.02.001](https://doi.org/10.1016/j.taap.2018.02.001). [PubMed: [29408570](https://pubmed.ncbi.nlm.nih.gov/29408570/)].
22. Noh YH, Baek JY, Jeong W, Rhee SG, Chang TS. Sulfiredoxin translocation into mitochondria plays a crucial role in reducing hyperoxidized peroxiredoxin III. *J Biol Chem*. 2009;**284**(13):8470-7. doi: [10.1074/jbc.M808981200](https://doi.org/10.1074/jbc.M808981200). [PubMed: [19176523](https://pubmed.ncbi.nlm.nih.gov/19176523/)]. [PubMed Central: [PMC2659205](https://pubmed.ncbi.nlm.nih.gov/PMC2659205/)].
23. Kilic T, Ciftci O, Cetin A, Kahraman H. Preventive effect of chrysin on bleomycin-induced lung fibrosis in rats. *Inflammation*. 2014;**37**(6):2116-24. doi: [10.1007/s10753-014-9946-6](https://doi.org/10.1007/s10753-014-9946-6). [PubMed: [24973983](https://pubmed.ncbi.nlm.nih.gov/24973983/)].
24. Kandhare AD, Bodhankar SL, Mohan V, Thakurdesai PA. Effect of glycosides based standardized fenugreek seed extract in bleomycin-induced pulmonary fibrosis in rats: Decisive role of Bax, Nrf2, NF-kappaB, Muc5ac, TNF-alpha and IL-1beta. *Chem Biol Interact*. 2015;**237**:151-65. doi: [10.1016/j.cbi.2015.06.019](https://doi.org/10.1016/j.cbi.2015.06.019). [PubMed: [26093215](https://pubmed.ncbi.nlm.nih.gov/26093215/)].
25. You XY, Xue Q, Fang Y, Liu Q, Zhang CF, Zhao C, et al. Preventive effects of Ecliptae Herba extract and its component, ecliptasaponin A, on bleomycin-induced pulmonary fibrosis in mice. *J Ethnopharmacol*. 2015;**175**:172-80. doi: [10.1016/j.jep.2015.08.034](https://doi.org/10.1016/j.jep.2015.08.034). [PubMed: [26385580](https://pubmed.ncbi.nlm.nih.gov/26385580/)].
26. Rao BN, Rao BS, Aithal BK, Kumar MR. Radiomodifying and anti-clastogenic effect of Zingerone on Swiss albino mice exposed to whole body gamma radiation. *Mutat Res*. 2009;**677**(1-2):33-41. doi: [10.1016/j.mrgentox.2009.05.004](https://doi.org/10.1016/j.mrgentox.2009.05.004). [PubMed: [19463966](https://pubmed.ncbi.nlm.nih.gov/19463966/)].
27. Chitra P, Saiprasad G, Manikandan R, Sudhandiran G. Berberine attenuates bleomycin induced pulmonary toxicity and fibrosis via suppressing NF-kappaB dependant TGF-beta activation: A biphasic experimental study. *Toxicol Lett*. 2013;**219**(2):178-93. doi: [10.1016/j.toxlet.2013.03.009](https://doi.org/10.1016/j.toxlet.2013.03.009). [PubMed: [23523906](https://pubmed.ncbi.nlm.nih.gov/23523906/)].
28. Izbicki G, Segel MJ, Christensen TG, Conner MW, Breuer R. Time course of bleomycin-induced lung fibrosis. *Int J Exp Pathol*. 2002;**83**(3):111-9. doi: [10.1046/j.1365-2613.2002.00220.x](https://doi.org/10.1046/j.1365-2613.2002.00220.x). [PubMed: [12383190](https://pubmed.ncbi.nlm.nih.gov/12383190/)]. [PubMed Central: [PMC2517673](https://pubmed.ncbi.nlm.nih.gov/PMC2517673/)].
29. Otsuka M, Takahashi H, Shiratori M, Chiba H, Abe S. Reduction of bleomycin induced lung fibrosis by candesartan cilexetil, an angiotensin II type 1 receptor antagonist. *Thorax*. 2004;**59**(1):31-8. doi: [10.1136/thx.2003.000893](https://doi.org/10.1136/thx.2003.000893). [PubMed: [14694243](https://pubmed.ncbi.nlm.nih.gov/14694243/)]. [PubMed Central: [PMC1758867](https://pubmed.ncbi.nlm.nih.gov/PMC1758867/)].
30. Ruscitti F, Ravanetti F, Essers J, Ridwan Y, Belenkov S, Vos W, et al. Longitudinal assessment of bleomycin-induced lung fibrosis by Micro-CT correlates with histological evaluation in mice. *Multidiscip Respir Med*. 2017;**12**:8. doi: [10.1186/s40248-017-0089-0](https://doi.org/10.1186/s40248-017-0089-0). [PubMed: [28400960](https://pubmed.ncbi.nlm.nih.gov/28400960/)]. [PubMed Central: [PMC5387277](https://pubmed.ncbi.nlm.nih.gov/PMC5387277/)].
31. Chaudhary NI, Schnapp A, Park JE. Pharmacologic differentiation of inflammation and fibrosis in the rat bleomycin model. *Am J Respir Crit Care Med*. 2006;**173**(7):769-76. doi: [10.1164/rccm.200505-717OC](https://doi.org/10.1164/rccm.200505-717OC). [PubMed: [16415276](https://pubmed.ncbi.nlm.nih.gov/16415276/)].