

In the name of God

Shiraz E-Medical Journal
Vol. 10, No. 1, January 2009

<http://semj.sums.ac.ir/vol10/jan2009/87018.htm>

A Very Unusual Case of Mediastinal Impalement Injury.

Hosseinnejad H*, Vaziri M**.

* Cardiac Surgeon, Milad Hospital, Tehran, Iran, ** Associate Professor, Section of Thoracic Surgery, Hazrat Rasool Hospital, Iran University of Medical Sciences, Theran, Iran.

Correspondence: Dr. M. vaziri, Hazrat Rasool Hospital, Iran University of Medical Sciences, Tehran, Iran, Telephone: +98(912) 171-1348, Fax: +98(21) 665-09056, E-mail: dr_m_vaziri@yahoo.com

Received for Publication: July 15, 2007, Accepted for Publication: August 16, 2008.

Abstract:

Mediastinal impalement is a very uncommon and often fatal injury and one of the most severe types of penetrating chest injuries. Patients with this type of injury always undergo operative intervention regardless of the hemodynamic state or associated injury and only a few cases have been reported in which the patient recovered without any sequel.

We present a previously unreported case of mediastinal impalement injury in which a 20-cm long stab was entered through the manubrium and remained within the anterior mediastinum with no cardiac, great vessel or hilar injury. The patient remained hemodynamically stable and the foreign body which had penetrated the pericardium and been stopped near the pulmonary artery was extracted via sternotomy incision.

Follow-up of the patient for about 9 months revealed no complication or residual effect of his accident.

Key Words: Mediastinum - Penetrating Trauma – Impalement Injury

Introduction:

Impalement injuries, in which a large foreign body traverses or penetrates a body cavity or extremity in a through and through fashion and still in place, combine aspects of both blunt and penetrating trauma and have a substantial operative intervention rate and mortality.⁽¹⁾ Mediastinal impalement injuries are quite rare and often fatal and it is very improbable that such injuries have avoided a major structure.

We report a very unusual case in which a long stab traversed the whole length of the anterior mediastinum in a vertical fashion with no injury at all and with successful operative outcome.

Case Report:

A 27-year-old male patient who was involved in a quarrel got impalement injury by a long stab through the manubrium. The patient was admitted in our center after about two hours of injury and was conscious and hemodynamically stable. About three centimeters of the object was seen above the sternum with no external bleeding and exit wound (Fig 1 Part A). The patient's physical examination revealed a pectus excavatum deformity and was unremarkable for any significant signs of deep injury including signs of cardiac tamponade, abnormal rhythm and decreased breath sounds. The patients' vital signs and results of laboratory tests included the following: BP=110/70 mmgh, PR=105/min,

RR=25/min, WBC=18400 (PMN=70%) Hb=12.6^{gr/dl}, and normal electrolytes and arterial blood gas (ABG).

Chest X Ray of the patient (Fig 1 Part B) revealed a long retracted stab facing the left hilum and the heart with no hemopneumothorax. The impaling object was extracted under direct vision via sternotomy incision and with cardiopulmonary bypass (CPB) on stand by. The pericardium with no bleeding within it had been injured but was not traversed and the object had been stopped near the pulmonary artery with no associated cardiac, vascular and visceral injuries (Fig 2 Part A). Following retrieval of the impaled object (Fig 2 Part B) thorough re-evaluation of the operative field was done and no missed injury or secondary foreign body was evident.

Discussion:

Any penetrating injury to the mediastinum including the rarely encountered impalement injury can be lethal which is related to the high concentration of major vascular and visceral structures that reside within the mediastinum.⁽²⁾ The resulting tissue damage in impalement injuries is often due to combination of blunt and penetrating forces and patients may present with deceptively few signs or symptoms.⁽³⁾

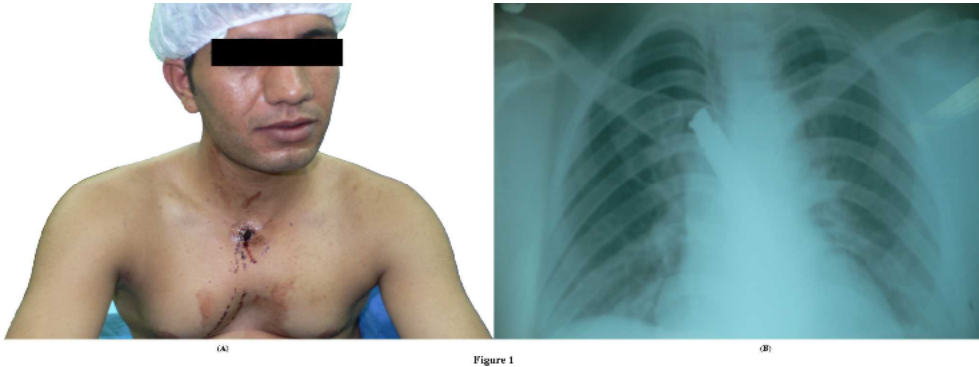


Figure 1, Part A: Impalement injury through the manubrium with no exit wound in a stable patient with pectus excavatum, Part B: Chest X Ray shows a retained impaling object in the mediastinum.

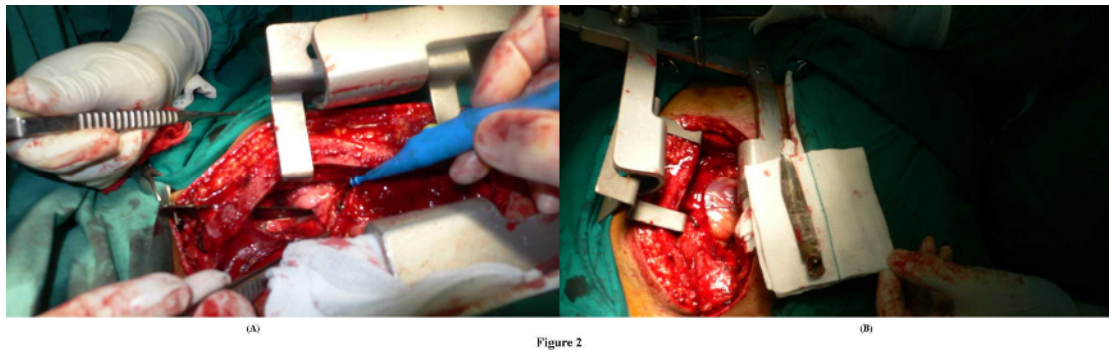


Figure 2, Part A: Intraoperative view of the impaling stab location, Part B: The removed impaling object.

The most important principle of management is that the impaling object should remain in situ, stabilized and not manipulated while the patient is rapidly transported to the operative theatre, regardless of the hemodynamic state.⁽⁴⁾ Removal of the impaling object should be done with adequate wound exposure and under direct vision and following retrieval of the impaled object, thorough re-evaluation of the operative field is necessary because associated injuries previously not visible with the object in situ may become evident after its removal.

In addition, the wound track should be examined for secondary foreign bodies carried into the wound by the impaling agent and introduction of unusual bacterial organisms at the time of impalement should be considered.

Although no preoperative diagnostic evaluation is required in patients with impalement injuries, various imaging modalities have been recommended in hemodynamically stable patients with trans-mediastinal penetrating trauma including multidetector CT^(2,5), contrast enhanced helical CT scanning⁽⁶⁾ and mul-

tislice helical computed tomography angiography (MCTA).⁽⁷⁾ In many instances, it is implausible that a transmediastinal penetrating injury has avoided a major structure and in the first hour after hospital admission of such injuries, thoracic vascular and neurologic trauma are the most common causes of death.⁽²⁾ In the initial evaluation of stable penetrating neck injuries, MCTA appears to be a sensitive and safe screening modality and in the future, the evaluation of many stable mediastinal penetrating trauma victims may be reduced to a solitary evaluation with rapid multidetector CT scan.⁽⁸⁾

The patient presented in this paper is very unusual because he suffered an impalement type of penetrating injury in the anterior mediastinum with no morbidity and mortality. The chest wall deformity of the patient (pectus excavatum) reasonably makes the mediastinum tight and should facilitate the deeper penetration of the object and injury of vital structures.

We think the following factors may contribute to the survival of patients with this type of injuries: 1-the age of the patient. Young patients are in good health and therefore more resistant to massive injury. 2-proper handling by the paramedics and rapid transport to a well

equipped hospital. 3-no attempt at the scene to remove the intruding object from the chest. 4-performing an immediate operation.

References:

1. Darbari M. Thoracic impalement injuries. *IJTCVS* 2005; 21: 229-231.
2. Burack JH, Kandil E, Sawas A, O'Neill PA, Sclafani SJ, Lowery RC, Zenilman ME. Triage and outcome of patients with mediastinal penetrating trauma. *Ann Thorac Surg* 2007; 83: 377-82.
3. Rosenthal MA, Ellis JL. Cardiac and mediastinal trauma. *Emerg Med Clin North Am* 1995 Nov; 13 (4): 887-902.
4. Shimokawa S, Shiota K, Ogata S, Toyohira H, Moriyama Y, Taira A. Impalement injury of the thorax: report of a case. *Surg Today* 1994; 24 (10): 926-8.
5. Shanmuganathan K, Matsumoto j. Imaging of penetrating chest trauma. *Radiol Clin North Am* 2006 Mar; 44 (2): 225-38.
6. Stassen NA, Lukan JK, Spain DA, Miller FB, Carrillo EH, Richardson JD, Battistella FD. Reevaluation of diagnostic procedures for transmediastinal gunshot wounds. *J Trauma* 2002 Oct; 53 (4): 635-8.
7. Inaba K, Munera F, McKenney M, Rivas L, de Moya M, Bahouth H, Cohn s. Prospective evaluation of screening multislice helical computed tomographic angiography in the initial evaluation of penetrating neck injuries. *J Trauma* 2006 Jul; 61 (1): 144-9.
8. Mirvis SE. Diagnostic imaging of acute thoracic injury. *Semin Ultrasound CT MRI* 2004; 25: 156-79.