

Shiraz E-Medical Journal
Vol. 10, No. 4, October 2009

<http://semj.sums.ac.ir/vol10/oct2009/88013.htm>

Aggressive Angiomyxoma of the Vulva: a Case Report.

Mehrzaad Sadaghiani M*, Nazari F**, Atashkhoei S±.

* Assistant Professor, ** Resident, Department of Obstetrics and Gynecology, ± Anesthesiologist, Alzahra Hospital, Tabriz University of medical sciences, Tabriz, Iran.

Correspondence: Dr. M. Mehrzaad Sadaghiani, Telephone: +98(914) 4419-229, Fax: +98(411) 5566-449, E-mail: mahzadms@yahoo.com

Received for Publication: May 30, 2009, Accepted for Publication: July 20, 2009.

Abstract:

Aggressive angiomyxoma (AAM) is a rare vulvovaginal mesenchymal neoplasm with a marked tendency for local recurrence, but usually does not metastasize. We describe a case of (AAM) in the left labium majus in a 35 year-old woman.

Introduction:

Aggressive angiomyxoma is an uncommon mesenchymal neoplasm occurring predominantly in the pelvi-perineal region of adults, and was first described in 1983 by Steeper and Rosai.⁽¹⁾ Fewer than 150 cases have been reported in the world medical literature since then.⁽²⁾ About 90% of patients are women, usually of reproductive age.⁽³⁾ A few cases have been described in males, usually in the scrotum. The female to male ratio is 6.6/1.⁽⁴⁾ It presents as a painless, poorly circumscribed gelatinous vulvar mass and

clinically simulates a Bartolin gland cyst or an inguinal hernia. It is a slow growing tumor, but problematic due to frequent local recurrences (30-72%), sometimes even decades later.^(5,6,7) This tumor usually does not metastasize.

Case presentation:

A 35 year-old woman G4 P3 Ab1 without medical history presented to an outpatient clinic of a gynecology department, and complained of a painless swelling of

the left labium major that existed since she was 3 months old, and which enlarged gradually without any remarkable symptoms. Clinical examination showed a non-tender 5*6 cm mass in the region between the labium major and minor.

An ultrasound revealed a subcutaneous hypo-echoic cyst 55*60 mm in the left labium major. The uterus, adnexa, and other pelvic organs were normal. With the diagnosis of Bartholin's gland cyst she underwent surgery. During surgery we found that the mass which had a polypoid and gelatinous appearance, and which had extended upward toward the inguinal canal, was not a Bartholin's cyst. The mass resected as high as possible and further investigation was postponed until after surgery. The histopathological examination of the mass indicated it was an aggressive angiomyxoma.

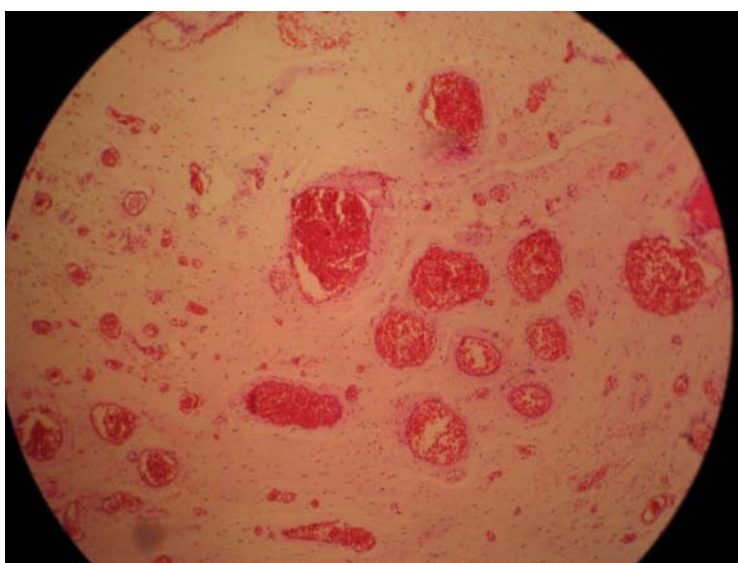
Two weeks after initial surgery, the patient underwent a pelvic CT-scan with contrast.

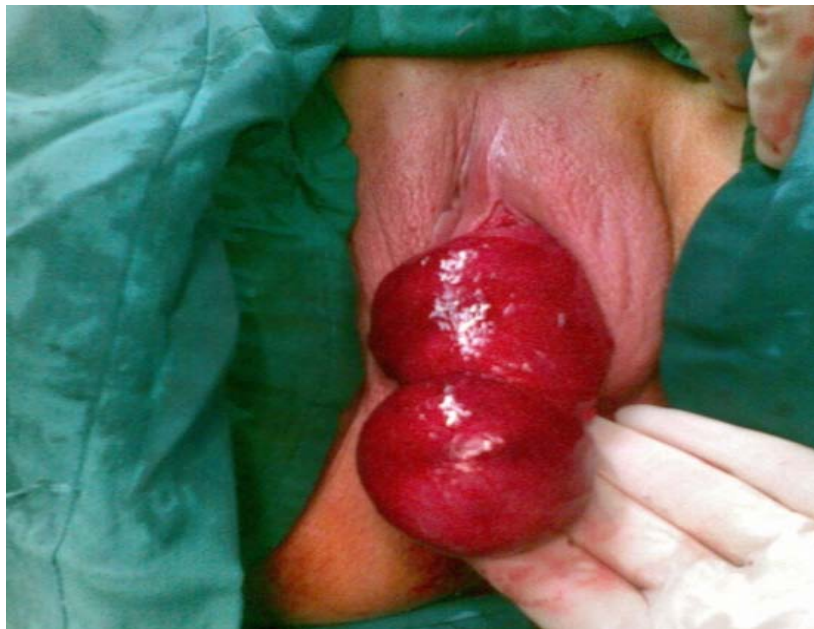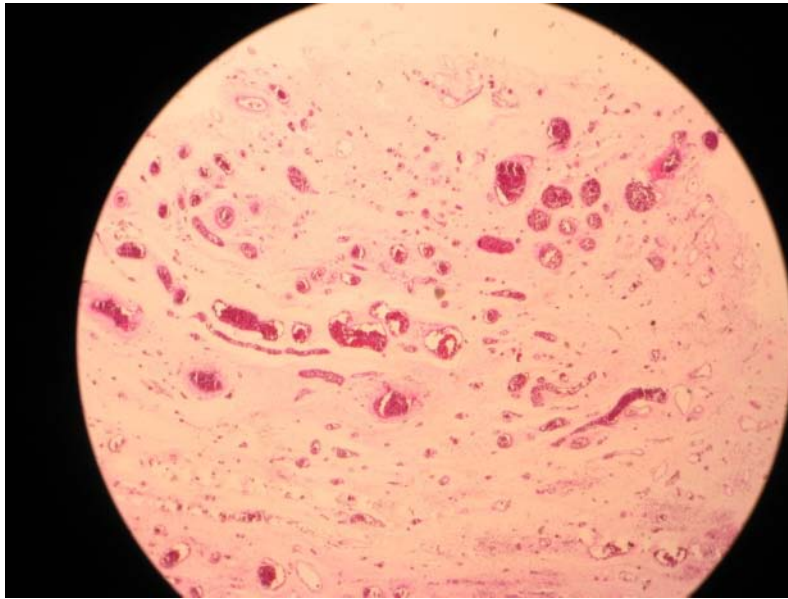
On CT-scan, the tumor had well-defined margins with attenuation less than that of muscle, and was located left of the uterine cervix, and was apart from rectum bladder and internal obturator muscle. The mass had extended to the medial margins of pubic ramus.

The patient underwent a second surgery four weeks later with wide local excision of the tumor remnants and partial vulvectomy by a general surgeon.

Histological examination: vulvar mass (6*3, 5*2 cm), multiple fragments of fibrofatty, and muscular tissue and remnants of tumoral tissue with the presence of mesenchymal spindle cells. Some of these have scant cytoplasmic processes without pleomorphism, mitotic activity, or proliferation of many dilated and congested arterioles that invades within normal fat and adjacent muscular tissue.

Diagnosis: pelvic mass, excisional biopsy: consistent with remnants of aggressive angiomyxoma with abundant fibrotic tissue and foreign reaction around it.





Discussion:

Carcinoma of the vulva is an uncommon malignancy accounting for 0.5% of all female cancers in the USA and 2% of all female genital malignancies. It is predominantly a disease of older women. The predominant histological type is squamous cell carcinoma which accounts for about 90% of the tumors in most series. Primary sarcoma constitutes 1% to 3% of all vulvar malignancies. The most

common histological type of primary vulvar sarcoma is leiomyosarcoma.

According to our review, 14 cases of dermatofibrosarcoma protuberans (DFSP) of the vulva were been reported in patients ranging from 37 to 87 years old. In addition, six cases of malignant fibrous histiocystoma of the vulva were reported. At least 100 cases of aggressive angio-myxoma involving the female pelvis or perineum, or both, have been described. At least 14 of these primarily involved

the vulva. It is an unusual tumor derived from fibroblasts or myofibroblasts with nuclei that have no atypical features or mitotic activity. There have been no reported deaths attributed to this tumor.

AAM is a mesenchymal tumor that affects women in > 90% of cases.^(7,9) It may involve the pelvis, retroperitoneum, vagina, vulva perineum, or buttocks, and usually presents as a polypoid or cystic mass.⁽¹⁰⁾ Although the age distribution ranges from 6 to 77, the peak incidence is in the fourth decade of life.^(4,9) The size is also variable, but most are larger than 10 cm.⁽⁹⁾

On gross examination, the tumors appear lobulated, soft to rubbery, as a solid mass, and with a gelatinous appearance on cut section. Some have finger-like projections that extend into neighboring tissues. Although invasions are rare, AAM can invade the bladder, bowel and pelvic bone.⁽⁷⁾

Histologically, the tumor consists of a rather hypocellular population of small, somewhat satellite to fusiform cells with thin cytoplasmic processes. The cells are scattered in a loose myxoid matrix composed of delicate wavy collagen fibrils, which gives the tumor a pale-pink color by eosin staining. There is also an accompanying prominent vascular component, ranging from tiny capillary-like vessels to larger vessels with a distinct smooth muscle cell, but with no evidence of anastomosis or arborization.

Immunohistochemically, these tumors express estrogen and progesterone receptors, thus suggesting that they may be hormone dependent, as rapid growth has been observed during pregnancy.

There is no complete consensus regarding the tumor pathogenesis. Translocation at the level of chromosome 12 with aberrant expression of the HMGIC protein involved in DNA transcription was demonstrated in this tumor. This hormonally responsive tumor is believed to arise from specialized mesenchymal cells of the pelvic-perineal region or from the multipotent perivascular progenitor cells, which often display variable myofibroblastic and fibroblastic features.⁽¹¹⁾

Imaging of these tumors is important to determine extent and thus, the optimal surgical approach. Sonography shows a mass that is hypoechoic or appears frankly cystic.

Angiography usually shows a generally hypervascular mass.

These tumors have a characteristic appearance on CT and MR imaging and these techniques reveal the extent of the tumor as well. On CT, the tumor has a well-defined margin and attenuation less than that of muscle. On T2 weighted MR imaging, the tumor has high signal intensity.⁽¹²⁾ Fibro-epithelial stromal polyp, superficial angiomyxoma, angiomyofibroblastoma, aggressive angiomyxoma, cellular angiofibroma and smooth muscle tumors need to be considered in the differential diagnosis of a polypoid mass in the perineum.⁽¹³⁾ Treatment is usually surgery in the form of wide local excision. Preoperative angiographic embolization, preoperative external beam irradiation, and intraoperative electron beam radiotherapy are useful to decrease the chances of local recurrences.⁽¹⁴⁾

Hormonal treatment with a gonadotropin-releasing hormone agonist (GnRh-a) can be applied for small primary AAM, in

addition to adjuvant therapy for residual tumors.⁽¹⁵⁾

Conclusion:

Although a rare diagnosis, AAM can present with unusual features. Detailed radiological examination is helpful in detecting the problem, but histology is the gold standard for diagnosis. Wide excision is curative and prognosis of such tumors is good. Long-term follow-up is necessary and MRI is the preferred method for detecting recurrences.^(16, 17)

References:

1. Steeper TA, Rosai J: Aggressive angiomyxoma of the pelvis and perineum: report of nine cases of a distinctive type of gynaecologic soft tissue neoplasm. *Am J Clin Pathol* 1983; 7: 453.
2. Wiser A, Korach J, Gotlieb WH, Fridman E, Apter S, Ben-Baruch G: Importance of accurate preoperative diagnosis in the management of aggressive angiomyxoma: report of three cases and review of the literature. *Ab-GRP ,P DJIQJ* ±
3. Magtibay PM, Salmon Z, Keeney GL, Podratz KC: Aggressive angiomyxoma of the female pelvis and perineum: a case series. *,QW- * \QHFRO&DOFHU* ±
4. Chan YM, Hon E, Ngai SW, Ng TY, Wong LC, Chan IM: Aggressive angiomyxoma in females: is radical resection the only option? *\$FVØ 2 EVMW* \QHFRO6FDOG* ± 220.
5. Steeper TA: Aggressive angiomyxoma of the female pelvis and perineum: report of nine cases of an distinctive type of gynaecologic soft-tissue neoplasm. *Am J Surg Pathol* ±
6. Behranwala KA, Thomas JM: Aggressive angiomyxoma: a distinct clinical entity. *Eur J 6XUJ 2 QFRO* ±

7. Smith HO, Worrell RV, Smith AY, Dorin MH, Rosenberg RD, Bartow SA: Aggressive angiomyxoma of the female pelvis and perineum: review of the literature. *Gynecol On-FRO* ±

8. Mitchel S. Hoffman: Malignancies of the vulva. In: John A. Rock, Howard W. Jones III; *Telinde's Operative Gynecology* 10th ed. Wolters Kluwer, Lippincott, 2008: 1151-1192-1193.

9. Fetsch JF, Laskin WB, Lefkowitz M et al: Aggressive angiomyxoma: a clinicopathologic study of 29 female patients. *Cancer* ±

\$ZDG = 2¶ RZG * 6SURXØ - 5\DQ 7 2¶HØ 7 \$JJUHMYH DQJIRP \[RP D ,UØHG J 1999; 92: 343

11. Alameda F, Munne A, Baro T, Iglesias M, Condom E, Lloreta-Trull J, et al: Vulvar angiomyxoma, aggressive angiomyxoma and angiomyofibroblastoma: An immunohistochemical and ultrastructural study. *Ultra-struct Pathol* 2006; 30: 193-205.

12. Outwater E, Marchetto BE, Wagner BJ, Evan SS: Aggressive Angiomyxoma: Findings on CT and MR imaging. *American J Ra-GRØJ* ±

13. Nucci MR, Fletchr CD: Vulvovaginal soft tissue tumors: update and review. *Histopa-thology* 2000; 36: 97-108.

14. Nyam D, Pemberton JH: Large aggressive angiomyxoma of the perineum and pelvis: An alternative approach. *Diseases of the &RØQ 5HFMP* ±

15. Shinohara N, Nonomura K, Ishikawa S, Seki H, Koyanagi T: Medical management of recurrent aggressive angiomyxoma with gonadotropin-releasing hormone agonist. *International Journal of Urology* 2004; 11: ±

16. Dragoumis K, Drevlengas A, Chatzigeorgiou K, Assimakopoulos E, Venizelos I, Togaridou E, et al: Aggressive angiomyxoma of the vulva extending into the pelvis: Report of two cases. *J Obstet Gynaecol Res* 2005; 31: 310-3.

17. Sharma JB, Wadhwa L, Malhotra, Arora R, Singh S. recurrent aggressive angiomyxoma of vagina: A case report. *Indian J Pathol Microbiol* 2004; 47: 425-7.