



# COVID-19 with Pneumomediastinum and Emphysema, A Case Report

Hamid Reza Samimaghani<sup>1</sup>, Mitra Kazemi Jahromi<sup>2,\*</sup> and Leila Kazemi Jahromi<sup>1</sup>

<sup>1</sup>Clinical Research Development Center, Shahid Mohammadi Hospital, Hormozgan University of Medical Sciences, Bandar Abbas, Iran

<sup>2</sup>Endocrinology and Metabolism Research Center, Hormozgan University of Medical Sciences, Bandar Abbas, Iran

\*Corresponding author: Endocrinology and Metabolism Research Center, Hormozgan University of Medical Sciences, Bandar Abbas, Iran. Email: mitra.kazemijahromi@gmail.com

Received 2020 September 14; Accepted 2020 September 18.

## Abstract

COVID-19 may have various radiological manifestations on the patient's chest computed tomography (CT) scan. Few cases with COVID-19 and pneumomediastinum have been reported to date. Here we present a patient with COVID-19, pneumomediastinum and emphysema.

**Keywords:** COVID-19, Pneumomediastinum, Emphysema

## 1. Introduction

Following the COVID-19 epidemic toward the end of 2019 and its rapid spread, the resulting disease was declared pandemic by the World Health Organization on March 11th.

A variety of radiological manifestations can be observed in pulmonary CT scans of COVID-19 patients with affected lungs.

Spontaneous pneumomediastinum is a rare event that is normally observed in diseases such as asthma, chronic pulmonary diseases, infections and mechanical ventilation, but it is not common in viral pneumonia.

Few COVID-19 pneumomediastinum cases have been reported to date (1-5). The present study introduces a patient with COVID-19 who developed pneumomediastinum and severe ARDS, but he was finally discharged in good condition.

## 2. Case Presentation

A 34-year-old man presented to Shohada Hospital in Bandar Lengeh, Hormozgan, Iran with no underlying diseases, and with chief complaints of cough, hemoptysis, and respiratory distress since eight days prior to admission ( $O_2$  sat without  $O_2 = 67\%$ ). The patient developed neck pain and massive bilateral subcutaneous emphysema of the neck extending to half of the thorax. Emergency CT scan of the neck and lungs was performed immediately which showed severe bilateral subcutaneous emphysema of the neck with intense diffusion into the medi-

astinum and pneumomediastinum and severe compression on the heart, without pneumothorax (Figure 1).

On admission, the patient was treated with Favipiravir and subcutaneous interferon-beta, methylprednisolone, bronchodilators, aspirin, 40 mg atorvastatin and therapeutic dose of heparin. Given the emphysema and severe pneumomediastinum, the patient's mask was swapped with a reservoir bag of 15 L/min maximum aiming to achieve maximum oxygen saturation to prevent barotrauma. In daily examinations, high-pressure oxygen was applied and remdesivir and consecutive hemoperfusion were initiated for five days, followed by four occasions of plasmapheresis, which gradually reduced the rate of emphysema and pneumomediastinum in clinical and radiological evaluation. The patient also received plasma from a COVID-19 survivor on two occasions.

Lab Tests during hospitalization:

LDH U/L: (on admission) 806 → 692 (on discharge);

CPK U/L: (on admission) 943 → 95 → 68 (on discharge);

CRP mg/L: (on admission) 46 → 37 → 11 (on discharge).

The patient oxygen was changed from a reservoir mask to a 5 L/min to 10 L/min simple mask, and then to a 2 L/min to 5 L/min nasal cannula. The patient had 97% saturation with a 2 L/min nasal oxygen.

The patient did not suffer oxygen saturation drop in the 6-min walking test. Pirfenidone was initiated to control proliferation of pulmonary fibroblasts. The patient was discharged after 21 days in good general status, without fever and without oxygen requirements.

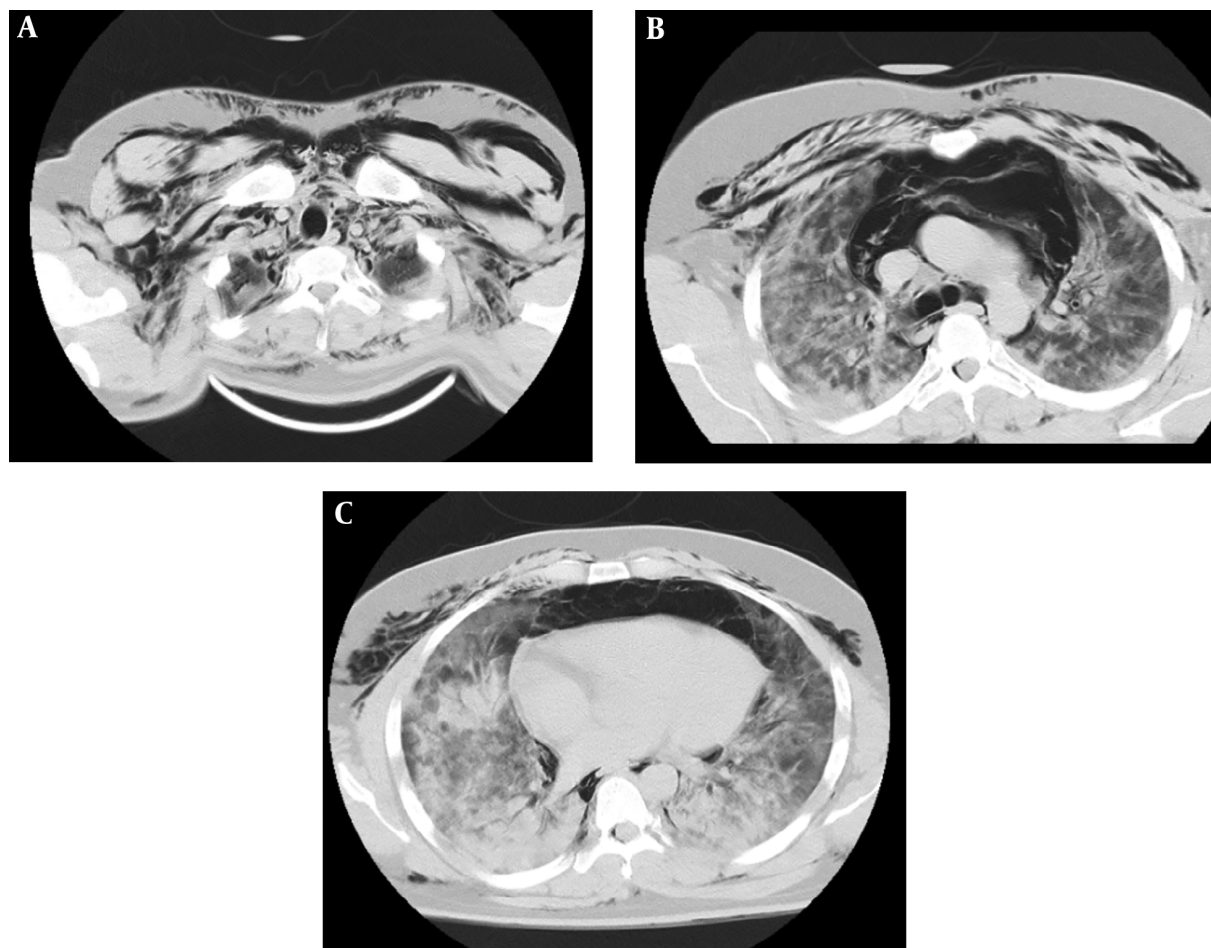


Figure 1. Diffuse pneumomediastinum and emphysema

### 3. Discussion

The present study introduced a COVID-19 patient with pneumomediastinum and emphysema who was finally discharged in good conditions.

Since the onset of COVID-19 pandemic, various radiological manifestations have been reported in CT scans of patients with COVID-19, the most common of which is “ground glass appearance”. However, pneumomediastinum has rarely been reported in recent studies (1, 2, 4, 5).

Spontaneous pneumomediastinum is caused by the pressure gradient between alveoli and pulmonary interstitium, which can lead to the alveolar rupture (6). In the context of COVID-19, spontaneous pneumomediastinum can be explained by the alveolar membrane destruction and rupture caused by the virus (7, 8).

Few cases of COVID-19 with spontaneous pneumomedi-

astinum have so far been reported (1, 2, 4, 5), some of which have led to pneumothorax (1). Although pneumomediastinum usually improves spontaneously, it is a COVID-19 complication, and can indicate its exacerbation (3).

### Footnotes

**Authors' Contribution:** HRS and MKJ contributed in conception and design. All authors contributed in data collection and manuscript drafting. MKJ supervised the study. All authors approved the final version of the manuscript.

**Conflict of Interests:** Authors have no conflict of interest.

**Ethical Approval:** The ethical approval code was IR.HUMS.REC.1399.317.

**Funding/Support:** Clinical Research Development Center of Hormozgan University of Medical Sciences, Bandar-Abbas, Iran.

## References

1. Sun R, Liu H, Wang X. Mediastinal Emphysema, Giant Bulla, and Pneumothorax Developed during the Course of COVID-19 Pneumonia. *Korean J Radiol.* 2020;21(5):541-4. doi: [10.3348/kjr.2020.0180](https://doi.org/10.3348/kjr.2020.0180). [PubMed: [32207255](https://pubmed.ncbi.nlm.nih.gov/32207255/)]. [PubMed Central: [PMC7183834](https://pubmed.ncbi.nlm.nih.gov/PMC7183834/)].
2. Mohan V, Tauseen RA. Spontaneous pneumomediastinum in COVID-19. *BMJ Case Rep.* 2020;13(5). doi: [10.1136/bcr-2020-236519](https://doi.org/10.1136/bcr-2020-236519). [PubMed: [32457032](https://pubmed.ncbi.nlm.nih.gov/32457032/)]. [PubMed Central: [PMC7252963](https://pubmed.ncbi.nlm.nih.gov/PMC7252963/)].
3. Zhou C, Gao C, Xie Y, Xu M. COVID-19 with spontaneous pneumomediastinum. *Lancet Infect Dis.* 2020;20(4):510. doi: [10.1016/S1473-3099\(20\)30156-0](https://doi.org/10.1016/S1473-3099(20)30156-0). [PubMed: [32164830](https://pubmed.ncbi.nlm.nih.gov/32164830/)]. [PubMed Central: [PMC7128610](https://pubmed.ncbi.nlm.nih.gov/PMC7128610/)].
4. Volpi S, Ali JM, Suleman A, Ahmed RN. Pneumomediastinum in COVID-19 patients: a case series of a rare complication. *Eur J Cardiothorac Surg.* 2020;58(3):646-7. doi: [10.1093/ejcts/ezaa222](https://doi.org/10.1093/ejcts/ezaa222). [PubMed: [32754730](https://pubmed.ncbi.nlm.nih.gov/32754730/)]. [PubMed Central: [PMC7454539](https://pubmed.ncbi.nlm.nih.gov/PMC7454539/)].
5. Sonia F, Kumar M. A Complication of Pneumothorax and Pneumomediastinum in a Non-Intubated Patient With COVID-19: A Case Report. *Cureus.* 2020;12(8). e10044. doi: [10.7759/cureus.10044](https://doi.org/10.7759/cureus.10044). [PubMed: [32983734](https://pubmed.ncbi.nlm.nih.gov/32983734/)]. [PubMed Central: [PMC7515794](https://pubmed.ncbi.nlm.nih.gov/PMC7515794/)].
6. Macia I, Moya J, Ramos R, Morera R, Escobar I, Saumench J, et al. Spontaneous pneumomediastinum: 41 cases. *Eur J Cardiothorac Surg.* 2007;31(6):1110-4. doi: [10.1016/j.ejcts.2007.03.008](https://doi.org/10.1016/j.ejcts.2007.03.008). [PubMed: [17420139](https://pubmed.ncbi.nlm.nih.gov/17420139/)].
7. Kolani S, Houari N, Haloua M, Alaoui Lamrani Y, Boubbou M, Serraj M, et al. Spontaneous pneumomediastinum occurring in the SARS-COV-2 infection. *IDCases.* 2020;21. e00806. doi: [10.1016/j.idcr.2020.e00806](https://doi.org/10.1016/j.idcr.2020.e00806). [PubMed: [32395425](https://pubmed.ncbi.nlm.nih.gov/32395425/)]. [PubMed Central: [PMC7212974](https://pubmed.ncbi.nlm.nih.gov/PMC7212974/)].
8. Gralinski LE, Baric RS. Molecular pathology of emerging coronavirus infections. *J Pathol.* 2015;235(2):185-95. doi: [10.1002/path.4454](https://doi.org/10.1002/path.4454). [PubMed: [25270030](https://pubmed.ncbi.nlm.nih.gov/25270030/)]. [PubMed Central: [PMC4267971](https://pubmed.ncbi.nlm.nih.gov/PMC4267971/)].