

Percutaneous transvenous mitral commissurotomy in a patient with
situs inversus and dextrocardia: a case report

Aliakbar Tavassoli⁽¹⁾, Masoud Pourmoghaddas⁽²⁾, Mahmood Emami⁽³⁾,
Mostafa Mousavizadeh⁽⁴⁾, Tohid Emami Meybodi⁽⁵⁾

Abstract

BACKGROUND: Dextrocardia situs inversus refers to the heart being a mirror image situated on the right side of the body. Distorted cardiac anatomy provides technical difficulties during fluoroscopy-guided transcatheter procedures. This is even more difficult in the case with percutaneous transvenous mitral commissurotomy (PTMC). Mitral valvuloplasty is a minimally invasive therapeutic procedure to correct an uncomplicated mitral stenosis by dilating the valve using a balloon. Here, we describe a case of a 25 years-old male with situs inversus and dextrocardia.

CASE REPORT: A 25 years-old man, having situs inversus and suffering from mitral stenosis was referred to hospital for PTMC. His initial examination findings were unremarkable and an electrocardiographic (ECG), trans-esophageal and transthoracic echocardiographic evaluation were performed. Mitral valve (MV) was dome shape and severely stenotic with mild mitral regurgitation (MR). Left ventricular ejection Fraction (LVEF) was about 40%, Femoral arterial and venous punctures were made on the left side; the left femoral artery and vein were cannulated with a 5F arterial and 6F venous sheaths, respectively. Then special maneuvers were done to solve the mitral valve stenosis. At the end of the procedure, no MR was documented by checking LV angiogram and there were no signs of mitral stenosis (MS).

CONCLUSION: Mirror-image dextrocardia, as in our case, has been estimated to occur with a prevalence of 1:10,000. However, there are only a few case reports in the literature on PTMC in similar settings. This might be due to the fact that many of these patients undergo surgical commissurotomy due to the technical difficulties involved in a percutaneous procedure in general. Trans-septal catheterization is considered a technical challenge in anatomically malpositioned hearts, as it is fraught with a higher risk of cardiac perforation. Despite the challenging anatomy, PTMC has been demonstrated to be a safe and feasible option for MS in patients with unusual cardiac anatomy.

Keywords: PTMC, Dextrocardia, Surgical Commissurotomy

ARYA Atherosclerosis 2011; 7(1): 47-50.

Date of submission: 3 Mar 2011, *Date of acceptance:* 22 May 2011

Introduction

Dextrocardia situs inversus refers to the heart being a mirror image situated on the right side. For all visceral organs to be mirrored, the correct term is dextrocardia situs inversus totalis. Dextrocardia is believed to occur in approximately 1 in 12,000 people,¹ while one in 3 of these will have situs inversus. Distorted cardiac anatomy provides

technical difficulties during fluoroscopy-guided transcatheter procedures. This is even more difficult in the cases with percutaneous transvenous mitral commissurotomy (PTMC), where the cardiac malpositions substantially increase the complications in interatrial septal puncture and left ventricular entry. Mitral valvuloplasty is a minimally invasive therapeutic procedure to correct an uncomplicated

1- MD, Associate Professor of Cardiology, Cardiac Rehabilitation Research Center, Isfahan Cardiovascular Research Institute, Isfahan University of Medical Sciences, Isfahan, Iran.

2- Professor, Cardiac Rehabilitation Research Center, Isfahan Cardiovascular Research Institute, Isfahan University of Medical Sciences, Isfahan, Iran.

3- Cardiologist, Department of Cardiology, School of Medicine, Yazd Cardiovascular Research Center, Shahid Sadoughi University of Medical Science, Yazd, Iran.

4- Medical Student, Department of Medicine, School of Medicine, Tehran University of Medical Sciences, Tehran, Iran.

5- Medical Student, Student Research Committee, Department of Medicine, School of Medicine, Shahid Sadoughi University of Medical Science, Yazd, Iran.

Correspondence To: Masoud Pourmoghaddas, Email: m.pourmoghaddas@gmail.com

mitral stenosis by dilating the valve using a balloon. Though PTMC is the procedure of choice in a selected subset of patient with rheumatic mitral stenosis (MS), there are only a few reports on successful PTMC in altered cardiac position and anatomy using the standard Inoue technique. Here, we described a case of a 25 years-old male with situs inversus and dextrocardia.

Case Report

In November 2009, a 25 years-old man, having situs inversus and suffering from mitral stenosis was referred to Chamran Heart Hospital for PTMC. The patient presented with shortness of breath NYHA class I. His initial examination findings were unremarkable. The left sided electrocardiograph (ECG) showed reduction in the R wave voltage across the chest leads (Figure 1). Moreover, this demonstrated an inverted P wave in leads I and aVL, an upright P wave and R wave in aVR. Chest x-ray showed dextrocardia (Figure 2).

Transesophageal and transthoracic echocardiography evaluation (Figure 3) showed 0.6 cm² of mitral valve area. Mitral Valve (MV) was dome shape and severely stenotic with mild mitral regurgitation (MR). He had Massachusetts General Hospital (MGH) score of 8 and his pulmonary artery pressure was significantly dropped. Dextrocardia, arteio-ventricular (AV) and ventriculo-arterial (VA) were present. Right atrium (RA) and left atrium (LA) pressure was 12 and 45 mmHg, respectively. Moreover, normal left ventricular (LV) size and left ventricular ejection fraction (LVEF) of about 40% was revealed. Both groins were prepared for vascular access. Femoral arterial and venous punctures were

made on the left side. However, the left femoral artery and vein were cannulated with a 5F arterial and 6F venous sheaths. A 5F pigtail catheter was passed retrograde into the aorta and taken to the left ventricle. No mitral regurgitation was seen. The pigtail catheter was then withdrawn and parked in the aortic root on the top of the aortic valve. A 0.032" guide wire was then passed up the femoral vein into the inferior vena cava (IVC) and up into the left sided superior vena cava (SVC) via the left sided 'right atrium'. An 8 F Mullins sheath was passed up on the guide wire, into the left SVC. For septal puncture, the patient was imaged in left anterior oblique (LAO) 40° projection. The Brockenbrough needle was oriented to 9 o'clock position in the SVC. Septal descent was done by withdrawing the needle and the sheath in tandem into the heart with the needle pointer in 7-8 o'clock position. The puncture point was chosen to be the point one disc space below the horizontal line stretching across the lower level of the pigtail; and the point was roughly midway between the posterior wall of the LA and the imaginary line drawn vertically from the pigtail catheter's shaft. A 'loopy' wire was then passed through the sheath and the latter was withdrawn leaving the loopy wire inside. The 14F dilator was then used to make the entry point wider. The balloon was then threaded over the loopy wire to enter the LA. The balloon was flushed and simultaneous LA/LV pressures were taken. Now, the J-wire was used to guide the balloon into the LV. For withdrawing this balloon while still keeping the wire in the LA, the balloon shaft was cut 20 cm from the proximal hub and removed it without any hassle. No MR was documented by checking the LV angiogram.

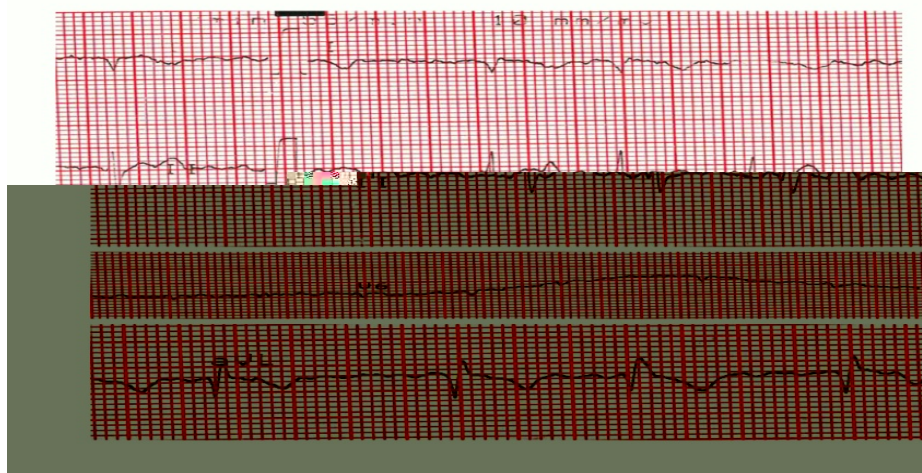


Figure 1. Left sided ECG, reduction in the R wave voltage across the chest leads, inverted P wave in leads I and aVL, also atrial fibrillation (AF) rhythm is seen in ECG.

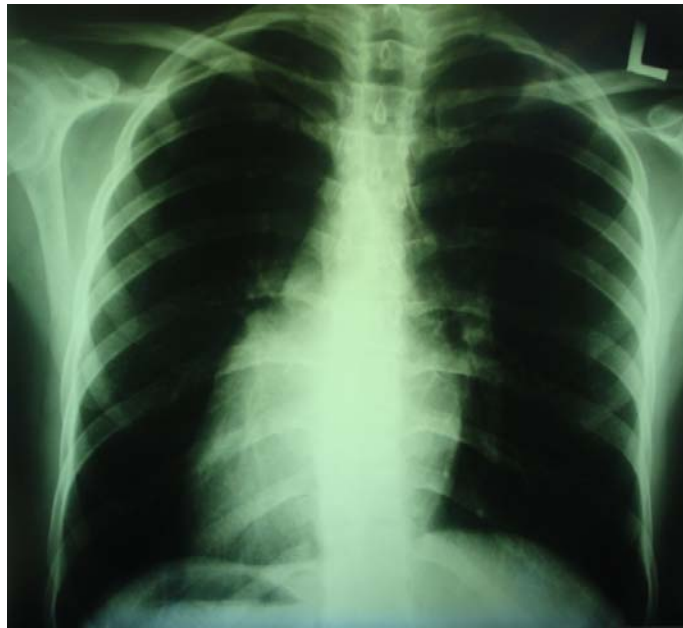


Figure 2. Chest x-ray showed dextrocardia

Discussion

Mirror-image dextrocardia, as in our case, has been estimated to occur with a prevalence of 1:10,000 patients. However, there are only a few case reports in the literature on PTMC in similar settings.²⁻⁵ This might be due to the fact that many of these patients undergo surgical commissurotomy due to the technical difficulties involved in a percutaneous procedure in general. Trans-septal catheterization is considered a technical challenge in anatomically malpositioned hearts, as it is fraught with a higher risk of cardiac perforation. The problem has been addressed in pregnancy with successful PTMC in anatomically challenging hearts⁶. We decided to proceed with this technically demanding procedure in view of the significant experience we had with PTMC in the past. Trans-septal catheterization was performed from the left groin to reduce the puncture needle angulations at the confluence of the iliac veins to the left-sided inferior vena cava³. Entry into the LA, and its depth can be confirmed by squinting contrast into the left atrium.^{3,6,7} Transesophageal and intracardiac echo are important adjunctive pathfinders for the interventionist cases as complex as this.⁸ The trans-jugular approach is thought to overcome many of the technical problems encountered with the trans-femoral route in cases with anatomical alterations.⁹ Despite the challenging anatomy, PTMC has been demonstrated to be a safe and feasible option for MS in patients with unusual cardiac anatomy.⁴⁻⁵

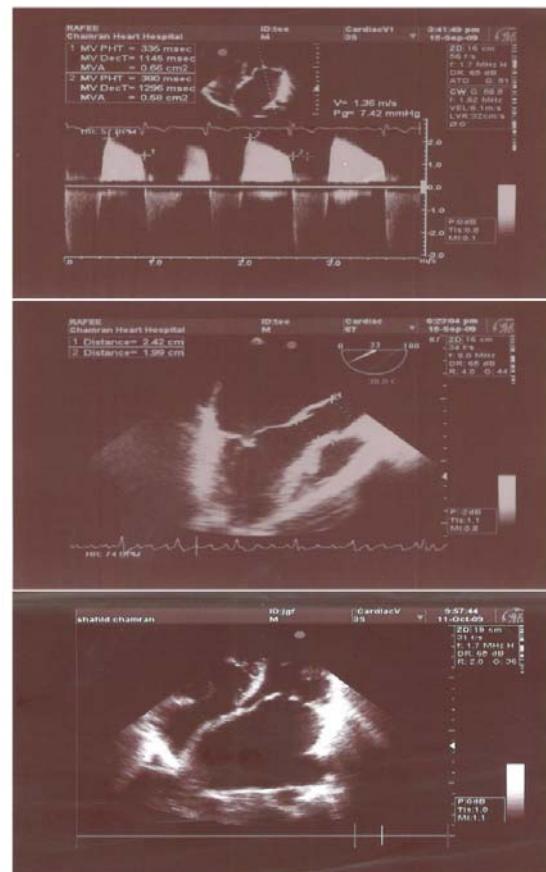


Figure 3. Transesophageal and trans-thoracic echocardiography, severe MS and mild MR.

Conflict of Interests

Authors have no conflict of interests.

References

1. Bohun CM, Potts JE, Casey BM, Sandor GG. A population-based study of cardiac malformations and outcomes associated with dextrocardia. *Am J Cardiol* 2007; 100(2): 305-9.
2. Hussain S, Ahmed W. Percutaneous transvenous mitral commissurotomy in mitral restenosis with situs inversus. *J Coll Physicians Surg Pak* 2009; 19(2): 117-9.
3. Namboodiri N, Harikrishnan SP, Ajitkumar V, Tharakan JA. Percutaneous mitral commissurotomy in a case of mirror-image dextrocardia and rheumatic mitral stenosis. *J Invasive Cardiol* 2008; 20(1): E33-E35.
4. Patel TM, Dani SI, Thakore SB, Chaq MC, Shah SC, Shah UG, et al. Balloon Mitral and Aortic Valvuloplasty in Mirror-Image Dextrocardia. *J Invasive Cardiol* 1996; 8(3): 164-8.
5. Raju R, Singh S, Kumar P, Rao S, Kapoor S, Raju BS. Percutaneous balloon valvuloplasty in mirror-image dextrocardia and rheumatic mitral stenosis. *Cathet Cardiovasc Diagn* 1993; 30(2): 138-40.
6. Said SA, Veerbeek A, van der Wieken LR. Dextrocardia, situs inversus and severe mitral stenosis in a pregnant woman: successful closed commissurotomy. *Eur Heart J* 1991; 12(7): 825-8.
7. Nallet O, Lung B, Cormier B, Porte JM, Garbarz E, Michel PL, et al. Specifics of technique in percutaneous mitral commissurotomy in a case of dextrocardia and situs inversus with mitral stenosis. *Cathet Cardiovasc Diagn* 1996; 39(1): 85-8.
8. Shalghanov TN, Paprika D, Borbas S, Temesvari A, Szili-Torok T. Preventing complicated transseptal puncture with intracardiac echocardiography: case report. *Cardiovasc Ultrasound* 2005; 3: 5.
9. Joseph G, George OK, Mandalay A, Sathe S. Transjugular approach to balloon mitral valvuloplasty helps overcome impediments caused by anatomical alterations. *Catheter Cardiovasc Interv* 2002; 57(3): 353-62.