

Dolichoectasia in vertebrobasilar arteries presented as transient ischemic attacks: A case report

Mohammad Reza Najafi⁽¹⁾, Nafiseh Toghianifar⁽²⁾, Morteza Abdar Esfahani⁽³⁾,
Mohammad Amin Najafi⁽⁴⁾, Mohammad Javad Mollakouchakian⁽⁵⁾

Images in Clinical Medicine

Abstract

BACKGROUND: Vertebrobasilar dolichoectasia (VBD) is a rare vasculopathy. The etiology of this disease is unknown. Transient ischemic attacks (TIAs) of vertebrobasilar system refer to a transient (< 24 hours) lowering of blood flow in the posterior circulation of the brain. We present a case of dolichoectasia in the vertebrobasilar artery that presented with TIAs.

CASE REPORT: A hypertensive 54-year-old man with true vertigo, nausea, imbalance, dysarthria, dysmetria, horizontal nystagmus, and gait ataxia was referred to Alzahra Hospital, Isfahan, Iran. The symptoms improved in the 1st day, but recurred in the 2nd day, lasting for 6-7 hours. According to clinical manifestations, a diagnosis of TIAs in the vertebrobasilar circulation was made. Imaging studies showed vascular anomaly. The vascular anomaly was considered as the cause of the patient's symptoms. A medical management was started using antiplatelet and antihypertensive drugs. The patient was referred for a more evaluation for other vascular anomalies.

CONCLUSION: Dolichoectasia usually affects vertebral and basilar arteries and simultaneous involvement of carotid arteries is rare seen in only 0.5% of these patients. The usual symptom of dolichoectasia is ischemia and rarely hemorrhages. The most common type of ischemic stroke is lacunar type. Ischemia evolves from embolic that originate from thrombi or plaques in the walls of the ectatic artery. While hemodynamic effects are the most common cause of the presenting signs and symptoms of the anomaly. We report a case of dolichoectasia that presented with TIAs of the vertebrobasilar artery. VBD is a distinct arteriopathy known as stroke risk.

Keywords: Vertebrobasilar Dolichoectasia; Transient Ischemic Attacks; Vasculopathy

Date of submission: 14 May 2015, *Date of acceptance:* 11 Oct 2015

Introduction

Vertebrobasilar dolichoectasia (VBD) is a rare vasculopathy. The etiology of this disease is unknown. Arterial wall of vertebral and/or basilar arteries are affected by VBD. VBD cause elongation, torsion, and enlargement of arteries that followed by hemodynamic and hemostatic changes. Finally, these changes cause thrombosis, microembolization, and brainstem compression, with or without aneurysm formation.¹ Its prevalence has been reported to vary from 0.06 to 5.8% according to different studies.²

Transient ischemic attacks (TIAs) of vertebrobasilar system refer to a transient (< 24 h) lowering of blood flow in the posterior circulation

of the brain.³

The presentation of dolichoectasia is usually due to hemodynamic disturbances and sometimes due to compressive effects. There are different clinical syndromes that are in association with ectatic vertebrobasilar arteries.² It may present with a headache, vertigo, sudden deafness, trigeminal neuralgia, facial spasm or palsy and basilar-type migraine.^{4,5} Rare presentations such as hydrocephalus have also been reported with bilateral obstruction of Monro foramina by posterior cerebral arteries.⁶

The pathophysiology of dolichoectasia seems to have association with hypertension, atherosclerosis,

1- Professor, Isfahan Neurosciences Research Center AND Department of Neurology, School of Medicine, Isfahan University of Medical Sciences, Isfahan, Iran

2- Resident, Isfahan Neurosciences Research Center AND Department of Neurology, School of Medicine, Isfahan University of Medical Sciences, Isfahan, Iran

3- Professor, Cardiac Rehabilitation Research Center, Cardiovascular Research Institute, Isfahan University of Medical Sciences, Isfahan, Iran

4- Student of Medicine, Isfahan Neurosciences Research Center, Isfahan University of Medical Sciences, Isfahan, Iran

5- General Practitioner, Isfahan University of Medical Sciences, Isfahan, Iran

Correspondence to: Mohammad Amin Najafi, Email: najafi.ma@yahoo.com

and destruction of the internal elastic membrane.⁷ The anomalous arteries usually have degeneration and gaps in the internal elastic lamina, thinning of media due to the reduction of reticular fibers and atrophy of smooth muscle cells.⁵ It is associated with Marfan, Ehlers-Danlos, and tuberous sclerosis.¹ Furthermore, dolichoectasia is in association with increasing age, male sex, hypertension and previous myocardial infarction.⁸

In this study, a case of dolichoectasia in the vertebrobasilar artery that presented with TIAs has been discussed.

Case Report

A hypertensive 54-year-old man referred to Alzahra Hospital, Isfahan, Iran, with true vertigo, nausea, and imbalance from the previous night.

In the neurologic physical examination, the patient had dysarthria, dysmetria, horizontal nystagmus and gait ataxia. The strength of the extremities was symmetric. The symptoms improved in the 1st day, but recurred in the 2nd day, lasting for 6-7 hours.

According to clinical manifestations, a diagnosis of TIAs in the vertebrobasilar circulation was made and the patient underwent imaging studies. Brain computed tomography scan (CT scan) showed hyperdense lesion in the brain stem and cerebellum (Figure 1).

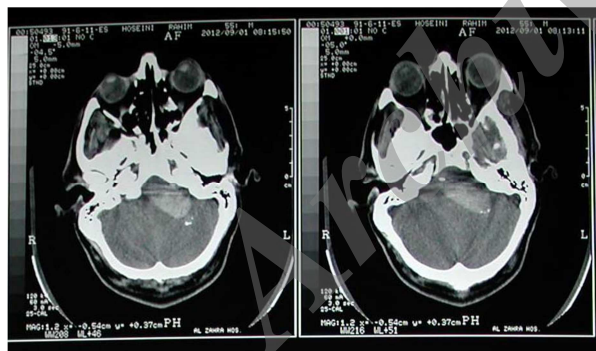


Figure 1. Brain computed tomography scan (CT scan) showing a hyperdense lesion in the brain stem and cerebellum

Brain magnetic resonance imaging (MRI) in both axial and sagittal views showed fusiform dilatation of an intracranial segment of internal carotid artery (ICA) as well as basilar artery, with extrinsic pressure over both sides of the medulla, pons and anterior aspect of left cerebellar hemisphere. Moreover, there was a marked compression and a displacement of the left pons and lower mesencephalic by the basilar artery (Figure 2). Brain

MRI showed long segment dilatation and severe tortuosity of basilar artery, as well as long segment slight dilated ICA proximal to bifurcation (Figure 3). MR angiography (MRA) of cerebral arteries showed fusiform dilatation of left vertebral artery and proximal two-thirds of basilar artery (dolichoectasia), with similar changes in supraclinoid portion of both internal carotid arteries as well as (Figure 4).

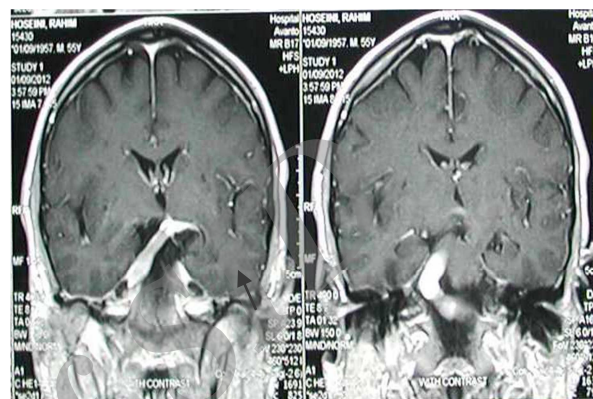


Figure 2. Brain magnetic resonance imaging (MRI), with contrast showing dilatation of intracranial segment of basilar artery, with extrinsic pressure over both sides of medulla

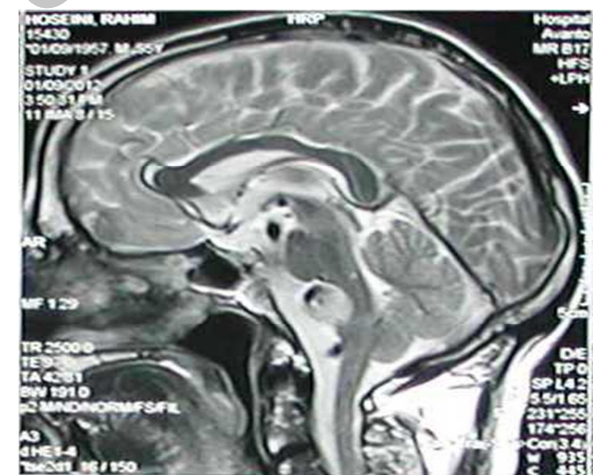


Figure 3. Brain magnetic resonance imaging (MRI) sagittal view showing dilatation of intracranial segment of basilar artery, with extrinsic pressure over both sides of medulla

The vascular anomaly was considered as the cause of the patient's symptoms. Medical management was started using antiplatelet and antihypertensive drugs. The patient was referred for more evaluation for other vascular anomalies in the setting of a systemic condition (especially cardiovascular systems) involving large to medium size arteries and for vascular intervention.

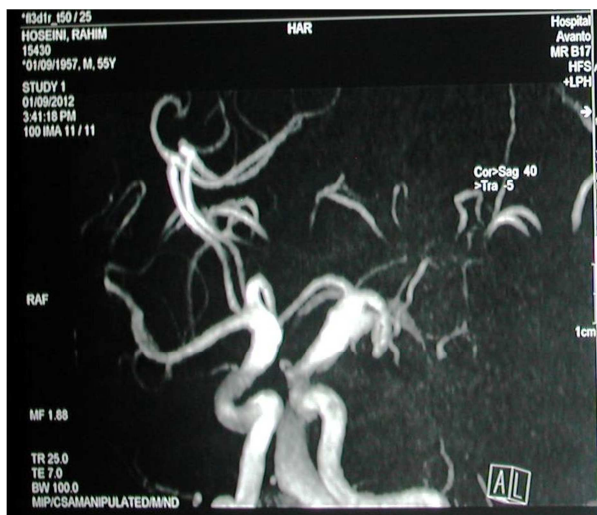


Figure 4. Magnetic resonance angiography of brain showing fusiform dilation of basilar artery and the segment of bilateral internal carotid arteries

Discussion

We presented very rare condition, TIAs of posterior circulation due to dolichoectasia,⁹ a case of vertebrobasilar and carotid dolichoectasia. There are some studies reported the relationship between cerebrovascular events and VBD in occasional cases and in a few patient series.¹⁰ It is usually presented as ischemia and sometimes with hemorrhage.⁴

Dolichoectasia usually affects vertebral and basilar arteries, and simultaneous involvement of carotid arteries is rare seen in only 0.5% of this patients.¹¹ The ICA is also at high risk to be affected. Our patient had this rare entity.

The usual symptom of dolichoectasia is ischemia and rarely hemorrhages. The most common type of ischemic stroke is the lacunar type.⁸ Ischemia evolves from embolic that originate from thrombi or plaques in the walls of the ectatic artery. While hemodynamic effects are the most common cause of the presenting signs and symptoms of the anomaly.⁴ VBD was defined as the diameter of the basilar artery ≥ 4.5 mm and the diameter of the intracranial vertebral artery ≥ 4.0 mm on MRA.¹² Although MRA showing ICA involvement, the manifestations were limited to posterior circulation, brain MRI showed fusiform dilatation of intracranial segment of ICA as well as basilar artery, with extrinsic pressure over both sides of medulla, pons and anterior aspect of left cerebellar hemisphere. Our patient showed some compressive effects of the dolichoectasia on the medulla, pons and anterior aspect of left cerebellar hemisphere. Moreover, this case presented with TIA in the vertebrobasilar field which is a less frequent presentation.

A study estimated the prevalence of dolichoectasia in stroke patients to be about 3.1%. Age, sex, hypertension, diabetes and previous history of TIA did not seem to have statistically significant difference between patients with dolichoectasia and without it. Patients with dolichoectasia had better survival but higher recurrence rate of stroke.⁴ There are studies which have been reported a higher rate of hypertension among patients with dolichoectasia.⁷ In another study, patients had a 60.0% survival rate after 3 years follow-up independent of the type of symptoms is ischemic versus compressive.¹² According to a cohort study dolichoectasia may be considered a risk factor for stroke and was associated with higher mortality in a 4-7 year period.¹³ Stroke event in VBD patients could be achieved by intensive management of these clinicoradiological factors.

We report a case of dolichoectasia that presented with TIAs of the vertebrobasilar artery. VBD is a distinct arteriopathy known as stroke risk.

Acknowledgments

The authors wish to thank Dr. Farideh Najafi for his valuable comments.

Conflict of Interests

Authors have no conflict of interests.

References

- Bradley WG. Neurology in clinical practice: Principles of diagnosis and management. London, UK: Taylor & Francis; 2004.
- Lou M, Caplan LR. Vertebrobasilar dilatative arteriopathy (dolichoectasia). *Ann N Y Acad Sci* 2010; 1184: 121-33.
- Najafi MR, Golshiri P, Khodabandehloo R, Najafi F. Outcome of patients with stroke admitted in stroke care unit and Neurologic. *Hormozgan Med J* 2007; 11(2): 153-8. [In Persian].
- Ince B, Petty GW, Brown RD, Chu CP, Sicks JD, Whisnant JP. Dolichoectasia of the intracranial arteries in patients with first ischemic stroke: a population-based study. *Neurology* 1998; 50(6): 1694-8.
- Levine RL, Turski PA, Grist TM. Basilar artery dolichoectasia. Review of the literature and six patients studied with magnetic resonance angiography. *J Neuroimaging* 1995; 5(3): 164-70.
- Celik O, Berkman ZM, Orakdogan M, Ayan E, Somay H, Duzkalir HA. Obstructive hydrocephalus due to vertebrobasilar dolichoectasia: diagnostic and therapeutic considerations. *J Neurol Surg A*

- Cent Eur Neurosurg 2013; 74(Suppl 1): e4-e8.
7. Borota L, Jonasson P. Basilar and bilateral carotid dolichoectasia with spontaneous dissection of C2 segment of the internal carotid artery. *AJNR Am J Neuroradiol* 2006; 27(6): 1241-4.
 8. Pico F, Labreuche J, Touboul PJ, Leys D, Amarenco P. Intracranial arterial dolichoectasia and small-vessel disease in stroke patients. *Ann Neurol* 2005; 57(4): 472-9.
 9. Caplan LR. Dilatative arteriopathy (dolichoectasia): What is known and not known. *Ann Neurol* 2005; 57(4): 469-71.
 10. Passero S, Filosomi G. Posterior circulation infarcts in patients with vertebrobasilar dolichoectasia. *Stroke* 1998; 29(3): 653-9.
 11. Romi F, Krakenes J, Thomassen L, Tysnes OB. Dolichoectasia of the intracranial arteries and stroke. *Tidsskr Nor Laegeforen* 1999; 119(20): 3004-5. [In Norwegian].
 12. Ikeda K, Hirayama T, Nakamura Y, Kano O, Kawabe K, Iwasaki Y. Comparative analysis of clinicoradiological factors between asymptomatic subjects and stroke patients with vertebrobasilar dolichoectasia in Japan. Honolulu, USA: International Stroke Conference; 2013.
 13. Ubogu EE, Zaidat OO. Vertebrobasilar dolichoectasia diagnosed by magnetic resonance angiography and risk of stroke and death: a cohort study. *J Neurol Neurosurg Psychiatry* 2004; 75(1): 22-6.

How to cite this article: Najafi MR, Toghianifar N, Abdar Esfahani M, Najafi MA, Mollakouchakian MJ, et al. **Dolichoectasia in vertebrobasilar arteries presented as transient ischemic attacks: A case report.** *ARYA Atheroscler* 2016; 12(1): 55-8.

Archive of SID