

A rare case of spontaneous and simultaneous multivessel coronary artery spasm leading to multisite myocardial infarction and ventricular fibrillation

Leili Iranirad⁽¹⁾, Mohammad Saleh Sadeghi⁽²⁾

Case Report

Abstract

BACKGROUND: Coronary artery spasm (CAS) can result in life-threatening arrhythmia and sudden cardiac death. Although this disorder has been known for a long time, little is known about it, and its mechanisms have been not identified yet.

CASE REPORT: We describe a 52-year-old woman with no significant cardiovascular risk factors who experienced several episodes of spontaneous and coincident multivessel coronary artery spasm, which led to myocardial infarction as well as malignant arrhythmias. Coronary angiography revealed severe migratory narrowing in the left anterior descending artery and right coronary artery.

CONCLUSION: Simultaneous multivessel coronary artery spasm develop multisite myocardial infarction (MI), and malignant arrhythmias could occur even in the absence of significant stenosis and triggering factors, which would lead to an increased risk of life-threatening cardiac events.

Keywords: Variant Angina Pectoris, Myocardial Infarction, Coronary Angiography

Date of submission: 26 Sep. 2017, *Date of acceptance:* 21 Nov. 2017

Introduction

Variant angina is a discrete form of angina pectoris, which typically occurs during normal activity or at rest, without evident classical triggers such as exercise. In this syndrome, episodes usually occur at night or in the early hours of the morning.¹⁻³

The occurrence of coronary artery spasm (CAS) shows extensive variances in different countries. For instance, the incidence of CAS seems to be three-times greater in the Japanese population compared to Caucasians, suggesting the probable role of genetic factors in the pathogenesis.^{2,4}

CAS is rare in young persons. Most patients suffering from CAS are between 40-70 years old. Death rates reported in patients with Prinzmetal angina are relatively low.^{4,5} Although this disorder has been described since long time ago, little is known about it and its mechanisms remain unclear. In this report, we describe a rare occurrence of spontaneous and simultaneous multivessel CAS, which led to myocardial infarction and malignant arrhythmias.

Case Report

A 52-year-old woman was presented to the emergency room with acute epigastric pain and cold sweating. Admission electrocardiography (ECG)

indicated ST-segment raising in the inferior leads (Figure 1); and the patient was managed with trinitroglycerin (TNG) and fibrinolytic therapy.

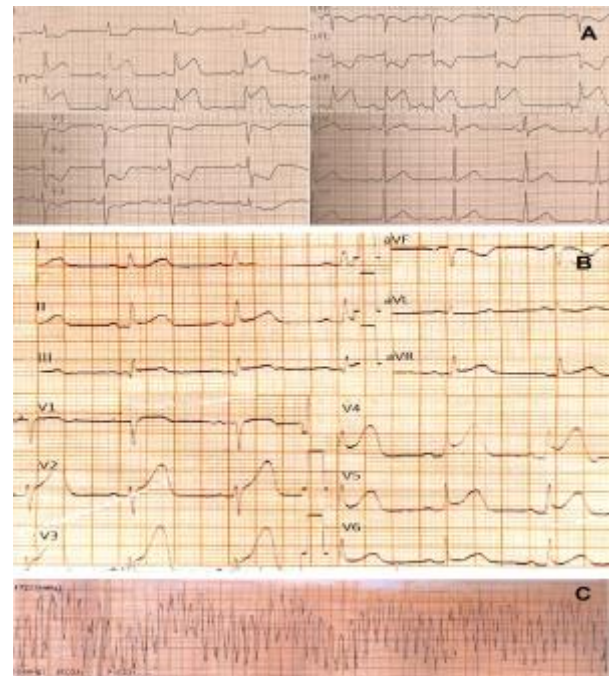


Figure 1. A: ST elevation in inferior leads; B: ST elevation in anterior leads; C: Polymorphic ventricular tachycardia

1- Assistant Professor, Department of Cardiology, School of Medicine, Qom University of Medical Sciences, Qom, Iran

2- Researcher AND General Practitioner, School of Medicine, Zahedan University of Medical Sciences, Zahedan, Iran

Correspondence to: Mohammad Saleh Sadeghi, Email: salehsadeghi87@gmail.com

Coronary angiography (CAG) was performed and showed severe stenosis in the left anterior descending artery (LAD) and right coronary artery (RCA) (Figures 2 and 3). Biochemical tests showed troponin level of 7.1 ng/ml (normal < 0.01 ng/ml); and other important factors such as complete blood count (CBC), fasting blood sugar (FBS), blood sugar (BS), triglyceride (TG), total cholesterol, high-density lipoprotein (HDL), low-density lipoprotein (LDL), Na, K, Mg, Ca, Cr, prothrombin time (PT), partial thromboplastin time (PTT), and international normalized ratio (INR) were at normal levels. The patient did not have any risk factors such as diabetes, smoking, alcohol consumption, use of ergonovine or other drugs, family history of cardiovascular disease, hypercholesterolemia, or history of angina.

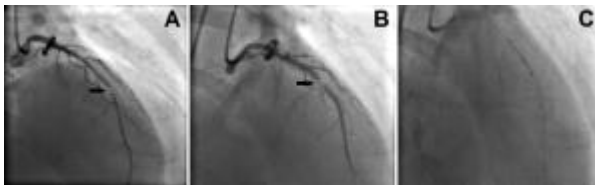


Figure 2. A: Severe stenosis at mid-portion of left anterior descending artery (LAD); B: Severe stenosis before last seen lesion; C: Stenting of LAD lesion

Since the patient showed stable vital signs and did not experience any chest pain, revascularization was planned for 48 hours later, based on the literature.⁶ Suddenly, after a day, the patient developed polymorphic ventricular fibrillation (VF) and was treated with successful defibrillation.

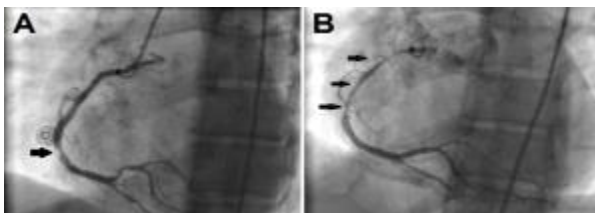


Figure 3. A: Severe stenosis at mid-portion of right coronary artery (RCA); B: Severe long stenosis at proximal to mid-portion of RCA

After defibrillation, ECG showed ST-segment elevation in anterior leads; thus, coronary stenting was urgently performed in the LAD. Surprisingly, there was no stenosis at the prior position when we proceeded with RCA revascularization; this indeed signified a spasm that had shifted to the proximal site. Furthermore, we understood that stenting of the LAD was mistakenly performed on a spasm because stenosis had shifted slightly in relation to the last performed angiography. Interestingly, in

spite of spasm, the patient did not have ischemic symptoms during the intervention.

Finally, the patient was placed on oral diltiazem, isosorbide mononitrate, and nicorandil to suppress coronary artery spasm attacks. During a one-year follow-up, the patient was free of symptoms.

Discussion

In 1950, Prinzmetal et al. described a variant form of angina pectoris resulting from temporary occlusion of a large diseased coronary artery with a narrow lumen due to increase in the tonus of the vessel wall.^{2,3} Although the exact pathophysiology of Prinzmetal angina remains unclear, the possible mechanisms that have been suggested include endothelial dysfunction, increased vasomotor tone, and increased platelet activation. Other precipitating factors include increased oxidative stress, physical or mental stress, magnesium deficiency, hyperventilation, inflammation, ergot alkaloids, alcohol consumption, and genetic susceptibility.^{2,4} Furthermore, cigarette smoking, age, and C-reactive protein with high sensitivity (hs-CRP) are major risk factors for vasospastic angina.^{4,5}

Several cases have been reported of coronary spasms in the literature.^{5,7,9} In a report, a 57-year-old man with a history of hypertension and diabetes mellitus, and variant angina developed simultaneous anterior and inferior MI, cardiogenic shock and VF.⁷ In another report, a 58-year-old woman with a history of hypertension and hypercholesterolemia developed ST-segment elevation and VF. Coronary angiography was initially performed and the second CAG revealed no lesions and she was diagnosed with CAS.⁸

Here, we described a case with simultaneous multiple CAS leading to multisite MI and malignant arrhythmias, a rare occurrence of CAS. Furthermore, the present case did not exhibit any risk factors and triggering factors; however, some cardiac episodes were silent, which is noteworthy.

ECG changes usually develop; however, they may appear ordinary at the start of CAS or in mild CAS.^{3,4} ST-segment elevation shows entire or subentire spasm of a main coronary artery. However, CAS is more often related to ST-segment depression, subendocardial myocardial ischemia, which indicates less severe case than ST-segment elevation. In addition, a taller and broader R wave, disappearance of the S wave, a taller T wave, and negative U wave may also appear during ST-segment changes.^{2,4}

The only convinced method for diagnosing CAS relies on coronary angiography and provocative tests. However, coronary angiography is normal in about half of the cases.^{3,4}

The occurrence of arrhythmias is prevalent during variant angina crises. Bradyarrhythmia, complete atrioventricular block, paroxysmal atrial fibrillation, ventricular tachycardia (VT), VF, and asystole are among the severe arrhythmias. Therefore, continuous ECG monitoring or Holter monitoring is useful for detecting ECG changes in patients suffering from variant angina.²⁻⁴

Early treatment of variant angina is important to prevent complications such as acute MI, fatal arrhythmias, and sudden death. Intravenous or sublingual nitroglycerine are effective in relieving attacks of variant angina.² It is obvious that any factor accelerating CAS probably, specially smoking, or specific drugs (e.g., ergotamine, sumatriptan) must be avoided. Calcium channel blockers have a crucial role in controlling CAS. Long-acting calcium antagonists are recommended to be taken at night when frequent CAS attacks occurrence, in this regard.^{1,4} For suppressing CAS attacks in patients with variant angina, nicorandil, a nitrate, and K-channel opener are also useful.^{2,4} A combination of different classes of calcium antagonists and nitrates or nicorandil or both is essential for patients suffering from variant angina, which is resistant to standard antianginal medications.²

Coronary stenting may express a different and viable option for some patients who are resistant to medical treatment. Chu et al. reported that for severe refractory coronary vasospasm, coronary stenting was effective with no serious complications.¹⁰ Moreover, it is suggested that coronary stenting together with adequate medical treatment can be considered in patients with CAS suffering considerable coronary stenosis.⁴ However, adequate information on late clinical consequence followed by stenting is limited, and further controlled clinical studies are necessary to determine coronary stenting for drug-refractory CAS. In this regard, revascularization procedures such as coronary artery bypass surgery (CABG) have resulted in limited success.^{1,4} Using an implantable cardioverter defibrillator in CAS cases are associated with life-threatening arrhythmias, VT, or VF.^{1,4} Long-term survival in patients with variant angina seems to be generally good.^{2,4}

In conclusion, simultaneous multivessel CAS developed multisite MI and malignant arrhythmias could occur even in the absence of significant stenosis, risk factors, and triggering factors, and would lead to an increased risk of life-threatening cardiac events.

Acknowledgments

The authors would like to thank Mrs. Sedighe Givi for her cooperation.

Conflict of Interests

Authors have no conflict of interests.

References

1. MacAlpin RN. Some observations on and controversies about coronary arterial spasm. *Int J Cardiol* 2015; 181: 389-98.
2. Kusama Y, Kodani E, Nakagomi A, Otsuka T, Atarashi H, Kishida H, et al. Variant angina and coronary artery spasm: The clinical spectrum, pathophysiology, and management. *J Nippon Med Sch* 2011; 78(1): 4-12.
3. de Luna AB, Cygankiewicz I, Baranchuk A, Fiol M, Birnbaum Y, Nikus K, et al. Prinzmetal angina: ECG changes and clinical considerations: A consensus paper. *Ann Noninvasive Electrocardiol* 2014; 19(5): 442-53.
4. Hung MJ, Hu P, Hung MY. Coronary artery spasm: Review and update. *Int J Med Sci* 2014; 11(11): 1161-71.
5. Falsoleiman H, Bayani B, Deghani M, Moohebbati M, Rohani A. Global coronary arteries spasm in a young patient. *ARYA Atheroscler* 2013; 9(4): 260-2.
6. O'Gara PT, Kushner FG, Ascheim DD, Casey DE Jr, Chung MK, de Lemos JA, et al. 2013 ACCF/AHA guideline for the management of ST-elevation myocardial infarction: A report of the American College of Cardiology Foundation/American Heart Association Task Force on Practice Guidelines. *J Am Coll Cardiol* 2013; 61(4): e78-140.
7. Chuang YT, Ueng KC. Spontaneous and simultaneous multivessel coronary spasm causing multisite myocardial infarction, cardiogenic shock, atrioventricular block, and ventricular fibrillation. *Circ J* 2009; 73(10): 1961-4.
8. Hendriks ML, Allaart CP, Bronzwaer JG, Res JJ, de Cock CC. Recurrent ventricular fibrillation caused by coronary artery spasm leading to implantable cardioverter defibrillator implantation. *Europace* 2008; 10(12): 1456-7.
9. Hovasse T, Jariwala P, Lefevre T. Spontaneous coronary artery spasm during coronary angiography: An uncommon manifestation of variant angina. *Journal of Indian College of Cardiology* 2015; 5(1): 103-6.
10. Chu G, Zhang G, Zhang Z, Liu S, Wen Q, Sun B. Clinical outcome of coronary stenting in patients with variant angina refractory to medical treatment: A consecutive single-center analysis. *Med Princ Pract* 2013; 22: 583-7.

How to cite this article: Iranirad L, Sadeghi MS. A rare case of spontaneous and simultaneous multivessel coronary artery spasm leading to multisite myocardial infarction and ventricular fibrillation. *ARYA Atheroscler* 2018; 14(1): 41-3.