

Right ventricular (RV) echocardiographic parameters in patients with pulmonary thromboembolism (PTE)

**Javad Shahabi⁽¹⁾, Reihaneh Zavar⁽¹⁾, Afshin Amirpour⁽²⁾, Mohammad Bidmeshki⁽³⁾,
Melinaz Barati-Chermahini⁽⁴⁾**

Original Article

Abstract

BACKGROUND: Acute pulmonary thromboembolism (PTE) is a common disease with a high mortality rate, and a variable and nonspecific clinical presentation. To detect the nonspecific signs and symptoms associated with this condition, several right ventricular (RV) echocardiographic parameters have been proposed as practical marker.

METHODS: This cross-sectional study was performed on 93 patients with PTE diagnosed by computed tomography (CT) angiography, and 57 patients with negative PTE based on CT angiography. During the experiment, all patients underwent both transthoracic echocardiography (TTE) and multi-slice CT pulmonary angiography. Transthoracic echocardiography measurements were obtained as patients went through both experimental procedures. These measurements were later compared between the patients with and without PTE.

RESULTS: Tricuspid annulus plain systolic excursion (TAPSE) (1.65 ± 0.09 vs. 2.00 ± 0.08 cm, $P < 0.001$) and left ventricular (LV) end-diastolic diameter (4.54 ± 0.26 vs. 5.40 ± 0.24 cm, $P < 0.001$) were significantly lower in patients with PTE as compared to patients without it. Whereas, RV end-diastolic and end-systolic diameters at the papillary muscle levels (3.41 ± 0.09 vs. 3.02 ± 0.12 cm, and 2.48 ± 0.08 vs. 2.16 ± 0.06 cm, respectively, $P < 0.001$ for both), and tricuspid valve (TV) annulus tissue Doppler imaging (TDI) measurements (6.02 ± 0.10 vs. 5.78 ± 0.14 , $P < 0.001$) were significantly greater in patients with PTE. On the other hand, no significant difference was found between the two groups of patients regarding pulmonary artery pressure (PAP) ($P = 0.416$), and RV fractional shortening ($P = 0.157$). Moreover, our results indicated that RV/LV (cut-off point: 0.6898) had high sensitivity (93.5%), specificity (100%), positive predicting value (PPV) (100%), and negative predicting value (NPV) (90.4%) in diagnosing PTE.

CONCLUSION: TTE may be valuable as a substitute diagnostic method for patients with PTE. This technique may also assist in detecting the severity of the illness, by evaluating RV/LV in cut-off point of 0.6898.

Keywords: Pulmonary Thromboembolism, Transthoracic Echocardiography, Computed Tomography Angiography

Date of submission: 29 Sep. 2016, *Date of acceptance:* 29 Jan. 2018

Introduction

Acute pulmonary thromboembolism (PTE) is a common disease with a 3-month death rate of up to 17.4%.^{1,2} Even if patients are treated with anticoagulation, the death rate in hemodynamically ranges from 8.1% to 15.1%.² Furthermore, over 42 million deaths were reported from the United States within a 20-year period, in a previously conducted study.¹ About 1.5% of patients were diagnosed with

PTE, and PTE was the presumed cause of death for 200,000 patients.¹ Considering local regions, a study based on three National Healthcare Group hospitals in 2006, estimated the population-based incidence of PTE to be 15 per 100,000.³ In addition, lower rates of venous thromboembolism were found for Asians, compared to Caucasians and Eurasians.³

Since PTE is associated with variable and nonspecific symptoms, accurate diagnosis is

1- Heart Failure Research Center, Cardiovascular Research Institute, Isfahan University of Medical Sciences, Isfahan, Iran
2- Cardiac Rehabilitation Research Center, Cardiovascular Research Institute, Isfahan University of Medical Sciences, Isfahan, Iran
3- Hypertension Research Center, Cardiovascular Research Institute, Isfahan University of Medical Sciences, Isfahan, Iran
4- Honours of Biology, York University, Toronto, Canada
Correspondence to: Javad Shahabi, Email: j.shahabi@yahoo.com

challenging. Yet, computed tomography (CT) angiography is used as a common diagnostic technique for PTE. Furthermore, several right ventricular (RV) echocardiographic parameters have been proposed as sensitive markers, to detect nonspecific signs and symptoms of this illness. Studies showed that acute PTE increases the pressure of the pulmonary arterial system and RV that results in RV dysfunction, and may progress further to right heart failure and circulatory collapse. Thus, these studies suggest that patients with PTE experience RV echocardiographic changes;³ however, there has not been a specific study to further analyze these changes. In our study, we evaluated RV echocardiographic finding, in patients with PTE, diagnosed by CT angiography.

Materials and Methods

This cross-sectional study was conducted in Department of Cardiology, Alzahra Hospital, Isfahan, Center of Iran, from August to December 2015. The transthoracic echocardiography (TTE) findings of patients who had PTE diagnosed by CT angiography, were compared to patients without PTE.

Inclusion criteria consisted of patient referred to cardiology department of Alzahra hospital with a probability diagnosis of PTE, with age of 18-70 years, and satisfaction to enter the study. Exclusion criteria consisted of low quality images based on patient's condition, patients with chronic lung disease, history

of heart failure, or heart attack, history of high pulmonary arterial pressure, including a previous history of pulmonary embolism^{4,6} proven by CT angiography, life expectancy of less than 3 months, pregnancy, kidney malfunction (creatinine clearance of 30 ml/minute), unable to complete CT testing (e.g., allergy to intravenous contrast material, unavailability of CT, patient too ill), or hemodynamic instability at presentation (such as cardiogenic shock, systolic blood pressure of more than 90 mmHg,⁷ or use of inotropic drug). Patients that did not tolerate the protocol-required TTE, were excluded from this study.

The study flowchart is shown in figure 1. 160 patients with a probability diagnosis of PTE, diagnosed by internist and based on inclusion and exclusion criteria were included. Then, CT angiography was performed for all patients, and PTE was confirmed by showing a complete or partial filling defect in the pulmonary vessels.

Patients with signs and symptoms of pulmonary embolism undergone 64 multi-slice CT pulmonary angiography, after intravenous injection of Wheezy Pack contrast agent.⁴ 150 patients had completed data and entered to the study; 93 from PTE group and 57 from individuals without PTE. Pulmonary arterial CT obstruction index (PACTOIR) was calculated in case group by in charge radiologist. Case group were divided into two subtype of moderate to severe PTE (PACTOIR: ≥ 40), and mild to moderate PTE (PACTOIR: < 40).

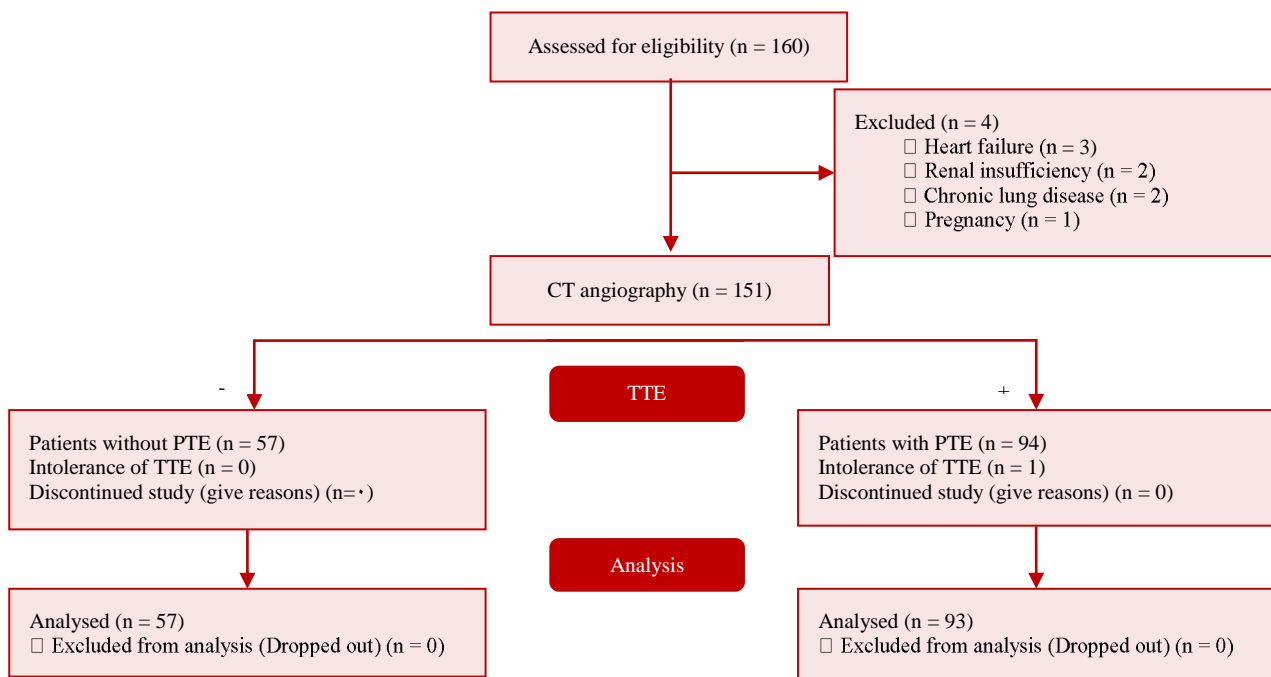


Figure 1. Study flowchart

CT: Computed tomography; TTE: Transthoracic echocardiography; PTE: pulmonary thromboembolism

The patients underwent TTE (Vivid 3, GE Medical Systems, Horten, Norway) in left lateral decubitus position, with measurements of parameters based on the recommendations of the American Society of Echocardiography, up to 24 hours after acute PTE diagnosis.⁵ The left ventricular (LV) and RV distances were measured in the 4-chamber apical view at papillary muscle level, to obtain the RV/LV ratio. The parasternal, apical, and subcostal views were used for the objective calculation of the RV systolic function. The pulmonary artery systolic pressure (PAPs) was resultant from the tricuspid regurgitation (TR), added to right atrial pressure as assessed from the inferior vena cava diameter and collapsibility.

Standard features of echocardiography included parasternal (long/short axis), apical (2/4 chamber), and subxiphoid (long axis) that were recorded in all patients. In addition, LV ejection fraction (LVEF) was measured using Simpson method. The diameter of the right ventricle and left ventricle at the papillary muscle level, and their ratio in systole and diastole were measured in apical view (4 chamber).

RV fractional shortening was calculated by the following formula:

$$\frac{(\text{RV end-diastolic diameter} - \text{RV end-systolic diameter})}{\text{RV end-diastolic diameter}}$$

Myocardial velocity in systolic and diastolic (early/late) in view of the apical (4 chamber) at the junction of the RV free wall and anterior cusp tricuspid valve (TV) was obtained with tissue Doppler imaging (TDI), and transmitral to basal septal myocardial early diastolic velocity ratio (E/E_m) was measured.⁸

The common method of evaluating the performance of the right ventricle through the tricuspid valve annulus is M-mode imaging using

tricuspid annulus plain systolic excursion (TAPSE).

Data were analyzed for patients with completed data, and reported as mean ± standard deviation (SD) for continuous, and frequency (percent) for categorical variables. To compare qualitative variables between the groups, chi-square test was performed. Kolmogorov-Smirnov test was used for evaluating normal distribution of all quantitative parameters. Moreover, Student's t test was used for variables distributed in a normal way. Besides, Mann-Whitney test was performed for variables that had not normal distribution. Roc-curve was used in order to evaluate the diagnostic accuracy of studied variables in distinguishing pulmonary thromboembolism,⁸ and the optimal cut-off values were defined as the point at which the value of "sensitivity + specificity - 1"^{9,10} was maximum (Youden index). We used Pearson correlation to find correlation between studied variables. The two tailed p-value of less than 0.050 was considered significant. Statistical analysis of data was performed using SPSS software (version 20, SPSS Inc., Chicago, IL, USA).^{11,12}

Results

Demographic features in terms of age (P = 0.446) and gender (P = 0.864) were similar in both groups. Ten patients were dropped out and finally, 150 patients completed the study. In patients with PTE and patients without PTE, 40.9% (n = 38) and 38.6% (n = 22) were men, respectively.

As is shown in table 1, TAPSE was significantly lower in PTE group as compared to patients without PTE (P < 0.001). Moreover, RV end-diastolic and end-systolic diameters in PTE group were significantly greater (P < 0.001).

Table 1. Characteristics and transthoracic echocardiography (TTE) results of the study sample

Variables	CT angiography results	PTE (n = 93)	Without PTE (n = 57)	P
Gender: Men [n (%)]		38 (40.9)	22 (38.6)	0.864
Age (year) [Mean ± SD]		55.68 ± 4.19	56.26 ± 4.62	0.446
TAPSE (cm) [Mean ± SD]		1.65 ± 0.09	2.00 ± 0.08	< 0.001
TDI (E/E') [Mean ± SD]		6.02 ± 0.10	5.78 ± 0.14	< 0.001
RVEDD (cm) [Mean ± SD]		3.41 ± 0.09	3.02 ± 0.12	< 0.001
RVESD (cm) [Mean ± SD]		2.48 ± 0.08	2.16 ± 0.06	< 0.001
LVEDD (cm) [Mean ± SD]		4.54 ± 0.26	5.40 ± 0.24	< 0.001
PAP (mmHg) [Mean ± SD]		25.00 ± 83.30	26.00 ± 86.70	0.416
RV Fractional shortening (%) [Mean ± SD]		27.00 ± 2.70	27.64 ± 2.60	0.157
RV/LV [Mean ± SD]		0.75 ± 0.04	0.56 ± 0.03	< 0.001
PACTOIR [Mean ± SD]		47.48 ± 6.53	-	-

CT: Computed tomography; PTE: Pulmonary thromboembolism; SD: Standard deviation; TAPSE: Tricuspid annular plane systolic excursion; TDI: Tissue Doppler imaging; RVEDD: Right ventricular end-diastolic diameter; RVESD: Right ventricular end-systolic diameter; LVEDD: Left ventricular end-diastolic diameter; PAP: Pulmonary artery pressure; RV: Right ventricle; LV: Left ventricle; PACTOIR: Pulmonary artery computed tomography obstruction index ratio

Table 2. Diagnostic accuracy of studied variables in detecting pulmonary thromboembolism (PTE)

Variables	TP	FP	TN	FN	Sensitivity (%)	Specificity (%)	PPV (%)	NPV (%)	LR ⁺	LR ⁻	Overall accuracy (%)
TDI (E/E') (cut-off point: 5.95; area: 0.947)	75	0	57	18	80.6	100	100	76.00	-	0.194	88.00
PAP (cut-off point: 35.50; area: 0.880)	93	7	50	0	100	87.7	93.00	100	8.13	0	95.33
RV fractional shortening (cut-off point: 0.2419; area: 0.391)	83	45	12	10	89.2	21.1	64.84	54.54	1.13	0.510	63.33
RV/LV (cut-off point 0.6889; area: 0.993)	87	0	57	6	93.5	100	100	90.47	-	0.065	96.00

PTE: Pulmonary thromboembolism; TP: True positive; FP: False positive; TN: True negative; FN: False negative; PPV: Positive predictive value; NPV: Negative predictive value; LR⁺: Positive likelihood; LR⁻: Negative likelihood; TDI: Tissue Doppler imaging; PAP: Pulmonary artery pressure; RV: Right ventricle; LV: Left ventricle

Whereas, LV end-diastolic diameter in patients with PTE was significantly lower than patients without PTE ($P < 0.001$). Furthermore, we found that TV annulus TDI (E/E') in patients without PTE was significantly lower as compared to patients with PTE ($P < 0.001$). On the other hand, PAPs ($P = 0.416$) and RV fractional shortening ($P = 0.157$) were similar in both groups, and no statistically significance were observed.

According to tables 2 and 3, RV/LV (cut-off point: 0.6898) had the highest diagnostic accuracy in distinguishing PTE among the other studied variables with the sensitivity of 93.5%, specificity of

100%, positive predicting value (PPV) of 100%, and negative predictive value (NPV) of 90.47%. In following, PAP (cut-off point: 35.5) had the second place in the term of highest diagnostic accuracy in distinguishing PTE with sensitivity of 100%, specificity of 87.7%, PPV of 93%, and NPV of 100%.

In addition, we found that PACTOIR for patients with PET had a significant positive correlation with RV end-systolic diameter (Pearson correlation: 0.211). None of demographic and TTE results had significant differences in patients with different severity of PTE ($P > 0.050$) (Table 4).

Table 3. Pearson correlation between quantitative variables in patients with pulmonary thromboembolism (PTE)

		TAPSE	TDI(E/E')	RVEDD	RVESD	LVEDD	PAP	RV fractional shortening	RV/LV	PACTOIR
TAPSE	Correlation	1	-	-	-	-	-	-	-	-
	P	-	-	-	-	-	-	-	-	-
TDI (E/E')	Correlation	0.051	1	-	-	-	-	-	-	-
	P	0.629	-	-	-	-	-	-	-	-
RVEDD	Correlation	0.054	-0.193	1	-	-	-	-	-	-
	P	0.610	0.063	-	-	-	-	-	-	-
RVESD	Correlation	0.039	-0.192	0.229*	1	-	-	-	-	-
	P	0.710	0.065	0.028	-	-	-	-	-	-
LVEDD	Correlation	-0.082	-0.079	-0.143	-0.065	1	-	-	-	-
	P	0.434	0.454	0.173	0.534	-	-	-	-	-
PAP	Correlation	-0.002	-0.008	-0.049	-0.097	0.119	1	-	-	-
	P	0.982	0.938	0.643	0.354	0.255	-	-	-	-
RV fractional shortening	Correlation	0.002	0.029	0.523**	-0.709**	-0.047	0.052	1	-	-
	P	0.984	0.779	<0.001	<0.001	0.653	0.621	-	-	-
RV/LV	Correlation	0.084	-0.029	0.571**	0.161	-0.892**	-0.124	0.273**	1	-
	P	0.422	0.785	<0.001	0.123	<0.001	0.235	0.008	-	-
PACTOIR	Correlation	-0.054	-0.180	0.125	0.211*	0.007	0.091	-0.094	0.064	1
	P	0.610	0.084	0.234	0.042	0.946	0.388	0.371	0.544	-

*: Correlation is significant at the 0.050 level (2-tailed); **: Correlation is significant at the 0.010 level (2-tailed).

TAPSE: Tricuspid annular plane systolic excursion; TDI: Tissue Doppler imaging; RVEDD: Right ventricular end-diastolic diameter; RVESD: Right ventricular end-systolic diameter; LVEDD: Left ventricular end-diastolic diameter; PAP: Pulmonary artery pressure; RV: Right ventricle; LV: Left ventricle; PACTOIR: Pulmonary artery computed tomography obstruction index ratio

Table 4. Characteristics and transthoracic echocardiography (TTE) results in patients with pulmonary thromboembolism (PTE) based on PTE severity

Variables	PTE severity	Mild to moderate (n = 15)	Moderate to severe (n = 78)	P
Gender: Men [n (%)]		8 (53.3)	30 (38.5)	0.283
Age (year) [Mean ± SD]		55.66 ± 4.01	55.69 ± 4.25	0.983
TAPSE (cm) [Mean ± SD]		1.66 ± 0.08	1.65 ± 0.10	0.971
TDI (E/E') [Mean ± SD]		6.07 ± 0.08	6.02 ± 0.11	0.088
RVEDD (cm) [Mean ± SD]		3.40 ± 0.09	3.41 ± 0.09	0.594
RVESD (cm) [Mean ± SD]		2.44 ± 0.14	2.49 ± 0.06	0.191
LVEDD (cm) [Mean ± SD]		4.51 ± 0.07	4.55 ± 0.28	0.578
PAP (mmHg) [Mean ± SD]		36.93 ± 0.45	38.55 ± 4.99	0.215
RV Fractional shortening (%) [Mean ± SD]		27.00 ± 4.00	26.00 ± 2.00	0.337
RV/LV [Mean ± SD]		0.75 ± 0.01	0.75 ± 0.04	0.928

PTE: Pulmonary thromboembolism; TAPSE: Tricuspid annular plane systolic excursion; TDI: Tissue Doppler imaging; RVEDD: Right ventricular end-diastolic diameter; RVESD: Right ventricular end-systolic diameter; LVEDD: Left ventricular end-diastolic diameter; PAP: Pulmonary artery pressure; RV: Right ventricle; LV: Left ventricle; SD: Standard deviation

Discussion

Acute PTE is a disease with high prevalence, frequently underdiagnosed, treated poorly, and often associated with complications. Prognosis of PTE is related to the pre-existing cardiovascular disease, the degree of pulmonary hypertension and vascular obstruction, and mainly, to the presence of RV dysfunction.¹³ Current studies have been focused on performance of echocardiography to evaluate RV function in patients with PTE, which further helps to identify cases with a higher risk of morbidity and mortality, and in need of a more aggressive treatment.¹⁴

PTE is associated with various signs and symptoms which may be mild or even absent, mainly in cases involving only the segmental pulmonary branches. Moreover, high or intermediate probability found based on clinical objective assessment, evokes the use of diagnostic techniques. However, a low probability based on objective clinical assessment does not exclude the need for further diagnosis. Further, maintaining a high level of suspicion by physicians is critical for diagnosis of PTE.

Our results showed that TAPSE was significantly lower in PTE group, as compared to patients without PTE (1.65 vs 2.00 cm). Vitarelli et al. study showed that TAPSE in patients with PTE was 1.5 cm, and 2.3 cm in patients without PTE.¹⁵ On the other hand, Gromadzinski et al. did not find any significant differences in TAPSE measurements between patients with and without PTE (1.45 vs 1.63 cm, P = 0.23).¹⁶

Furthermore, TAPSE plays an important role as predictor of survival, regarding patients with PTE. However, no studies had before assessed

interobserver reliability for this parameter. In the study of Kaul et al., TAPSE correlated powerfully with radionuclide angiography, with low interobserver variability.¹³ Even though, we did not evaluate variability of TAPSE in detecting PTE, TAPSE measurements were very low in patients with PTE, even lower than patients without PTE.

Moreover, TAPSE is a well-known, reproducible parameter that does not involve complex equipment and image analysis. In addition, this parameter has a proven prognostic value for detection of congestive heart failure. For patients with heart failure, decreased RV systolic function measured by TAPSE was found to be related to increased mortality, independent of other risk factors associated with this condition.¹⁵

Furthermore, in a previous study, TAPSE was used to detect the severity of RV function defined by plasma B-type natriuretic peptide (BNP). A significant correlation was also found for plasma BNP level and TAPSE ($r = -0.634$, $P < 0.001$).¹⁶ Interestingly, TAPSE measurement for lower reference value of RV function was recently stated as 16 mm. Moreover, TAPSE has been proposed as a prognostic tool on pulmonary arterial hypertension based on guidelines. In addition, TAPSE ≤ 15 is found to be an indicator of poor outcome.^{16,17} These studies and our show that patients with PTE had lower TAPSE, and having low amount of TAPSE has significant correlation with poor outcome in patients with PTE; which indicate that TAPSE measurement is a reliable factor in order to prove PTE, and outcome of these patients.

As obtained, RV end-diastolic diameter and RV end-systolic diameter in were significantly greater PTE group (3.41 vs 3.02 cm and 2.48 vs 2.16 cm, respectively), while end-systolic diameter in patients

with PTE was significantly lower than patients without PTE (4.5 vs 5.4 cm). Gromadzinski et al. study showed that end-systolic diameter in patients with PTE was significantly lower than patients without PTE (4.5 vs 5.7 cm), while no significant correlation was found between RV end-diastolic diameter and PTE (3.4 vs 3.0 cm).¹⁶

According to our findings, PACTOIR had significant positive correlation with RV end-systolic diameter. Moreover, in Varol et al. study, PACTOIR value for patients with RV dysfunction found to be significantly higher than those without RV dysfunction.¹⁸ Lastly, our results indicate that TV annulus TDI (E/E') in patients without PTE was significantly lower, compared to patients with PTE (5.78 vs 6.02). Some studies showed that in patients with PTE, systolic and diastolic tricuspid annular velocities were significantly lower than in healthy controls.¹⁸⁻²² There was a good reverse correlation between systolic TR velocity and systolic PAP (PAPs), as well as mean arterial PAP (PAPm), too.²³⁻²⁵

Conclusion

Our results showed that TTE can be helpful in patients with signs or symptoms of PTE, as an alternative diagnostic method which determined the severity of this illness. We found significant differences in TAPSE, TV annulus TDI, RV end-diastolic diameter, and RV end-systolic and end-systolic diameters between the patients with PTE and without PTE that by defining scores for each of these factors, we could diagnosis PTE by using TTE. Moreover, we found that RV/LV in cut-off point of 0.6898, had the highest sensitivity, specificity, PPV, and NPV value in diagnosing PTE.

Acknowledgments

This study was financially supported by Isfahan Medical Sciences University, Isfahan, Iran. We gratefully acknowledge the dedicated efforts of the investigators, the coordinators, the volunteer patients who participated in this study, and the Clinical Research Development Units (CRDU) of Isfahan Alzahra hospital.

Conflict of Interests

Authors have no conflict of interests.

References

- Alpert JS, Smith R, Carlson J, Ockene IS, Dexter L, Dalen JE. Mortality in patients treated for pulmonary embolism. *JAMA* 1976; 236(13): 1477-80.
- Carson JL, Kelley MA, Duff A, Weg JG, Fulkerson WJ, Palevsky HI, et al. The clinical course of pulmonary embolism. *N Engl J Med* 1992; 326(19): 1240-5.
- Molina JA, Jiang ZG, Heng BH, Ong BK. Venous thromboembolism at the National Healthcare Group, Singapore. *Ann Acad Med Singapore* 2009; 38(6): 470-8.
- van Beek EJ, Kuijjer PM, Buller HR, Brandjes DP, Bossuyt PM, ten Cate JW. The clinical course of patients with suspected pulmonary embolism. *Arch Intern Med* 1997; 157(22): 2593-8.
- Goldhaber SZ, Visani L, De Rosa M. Acute pulmonary embolism: Clinical outcomes in the International Cooperative Pulmonary Embolism Registry (ICOPER). *Lancet* 1999; 353(9162): 1386-9.
- Kasper W, Konstantinides S, Geibel A, Olschewski M, Heinrich F, Grosser KD, et al. Management strategies and determinants of outcome in acute major pulmonary embolism: Results of a multicenter registry. *J Am Coll Cardiol* 1997; 30(5): 1165-71.
- Givi M, Sadeghi M, Garakyaraghi M, Eshghinezhad A, Moeini M, Ghasempour Z. Long-term effect of massage therapy on blood pressure in prehypertensive women. *J Educ Health Promot* 2018; 7: 54.
- Rajabi F, Sadeghi M, Karbasian F, Torkan A. Is thromboprophylaxis effective in reducing the pulmonary thromboembolism? *ARYA Atheroscler* 2012; 8(1): 16-20.
- Mirdamadi A, Dashtkar S, Kaji M, Pazhang F, Haghpanah B, Gharipour M. Dabigatran versus Enoxaparin in the prevention of venous thromboembolism after total knee arthroplasty: A randomized clinical trial. *ARYA Atheroscler* 2014; 10(6): 292-7.
- Azari A, Bigdelu L, Moravvej Z. Surgical embolectomy in the management of massive and sub-massive pulmonary embolism: The results of 30 consecutive ill patients. *ARYA Atheroscler* 2015; 11(3): 208-13.
- Ribeiro A, Lindmarker P, Juhlin-Dannfelt A, Johnsson H, Jorfeldt L. Echocardiography Doppler in pulmonary embolism: Right ventricular dysfunction as a predictor of mortality rate. *Am Heart J* 1997; 134(3): 479-87.
- Horlander KT, Mannino DM, Leeper KV. Pulmonary embolism mortality in the United States, 1979-1998: An analysis using multiple-cause mortality data. *Arch Intern Med* 2003; 163(14): 1711-7.
- Kaul S, Tei C, Hopkins JM, Shah PM. Assessment of right ventricular function using two-dimensional echocardiography. *Am Heart J* 1984; 107(3): 526-31.

14. Stein PD, Beemath A, Matta F, Weg JG, Yusen RD, Hales CA, et al. Clinical characteristics of patients with acute pulmonary embolism: Data from PIOPED II. *Am J Med* 2007; 120(10): 871-9.
15. Vitarelli A, Barilla F, Capotosto L, D'Angeli I, Truscelli G, De Maio M, et al. Right ventricular function in acute pulmonary embolism: A combined assessment by three-dimensional and speckle-tracking echocardiography. *J Am Soc Echocardiogr* 2014; 27(3): 329-38.
16. Gromadzinski L, Targonski R, Pruszczyk P. Assessment of right and left ventricular diastolic functions with tissue Doppler echocardiography in congestive heart failure patients with coexisting acute pulmonary embolism. *Adv Clin Exp Med* 2014; 23(3): 371-6.
17. Kjaergaard J, Akkan D, Iversen KK, Kober L, Torp-Pedersen C, Hassager C. Right ventricular dysfunction as an independent predictor of short- and long-term mortality in patients with heart failure. *Eur J Heart Fail* 2007; 9(6-7): 610-6.
18. Varol K, Gumus C, Yucler H, Sezer F, Seker E, Inci MF, et al. Correlation of right ventricular dysfunction on acute pulmonary embolism with pulmonary artery computed tomography obstruction index ratio (PACTOIR) and comparison with echocardiography. *Jpn J Radiol* 2015; 33(6): 311-6.
19. Lobo JL, Holley A, Tapsen V, Moores L, Oribe M, Barron M, et al. Prognostic significance of tricuspid annular displacement in normotensive patients with acute symptomatic pulmonary embolism. *J Thromb Haemost* 2014; 12(7): 1020-7.
20. Ghio S, Recusani F, Klersy C, Sebastiani R, Laudisa ML, Campana C, et al. Prognostic usefulness of the tricuspid annular plane systolic excursion in patients with congestive heart failure secondary to idiopathic or ischemic dilated cardiomyopathy. *Am J Cardiol* 2000; 85(7): 837-42.
21. Hsiao SH, Chang SM, Lee CY, Yang SH, Lin SK, Chiou KR. Usefulness of tissue Doppler parameters for identifying pulmonary embolism in patients with signs of pulmonary hypertension. *Am J Cardiol* 2006; 98(5): 685-90.
22. Park JH, Kim JH, Lee JH, Choi SW, Jeong JO, Seong IW. Evaluation of right ventricular systolic function by the analysis of tricuspid annular motion in patients with acute pulmonary embolism. *J Cardiovasc Ultrasound* 2012; 20(4): 181-8.
23. Rudski LG, Lai WW, Afilalo J, Hua L, Handschumacher MD, Chandrasekaran K, et al. Guidelines for the echocardiographic assessment of the right heart in adults: A report from the American Society of Echocardiography endorsed by the European Association of Echocardiography, a registered branch of the European Society of Cardiology, and the Canadian Society of Echocardiography. *J Am Soc Echocardiogr* 2010; 23(7): 685-713.
24. Caijani EG, Toledo E, MacEneaney P, Bardo D, Cerutti S, Lang RM, et al. Automated interpretation of regional left ventricular wall motion from cardiac magnetic resonance images. *J Cardiovasc Magn Reson* 2006; 8(3): 427-33.
25. Petkov R, Yamakova Y, Petkova E. TDI velocities of tricuspid annulus in patients with acute pulmonary embolism. *Eur Respir J* 2013; 42: P4101.

How to cite this article: Shahabi J, Zavar R, Amirpour A, Bidmeshki M, Barati-Chermahini M. **Right ventricular (RV) echocardiographic parameters in patients with pulmonary thromboembolism (PTE).** *ARYA Atheroscler* 2018; 14(2): 78-84.