

## Distal accesses in the hand (two novel techniques) for percutaneous coronary angiography and intervention

Farshad Roghani-Dehkordi<sup>(1)</sup>, Omid Hashemifard<sup>(2)</sup>, Masoumeh Sadeghi<sup>(3)</sup>, Rohollah Mansouri<sup>(4)</sup>, Mehdi Akbarzadeh<sup>(5)</sup>, Asieh Dehghani<sup>(6)</sup>, Mojtaba Akbari<sup>(7)</sup>

### Case Series

#### Abstract

**BACKGROUND:** Trans-radial and trans-ulnar accesses have been practiced and recommended as default and alternative techniques for coronary angiography and angioplasty in recent years. In this study, we present new innovative approaches using more distal access points, i.e. trans-snuff box and trans-palmar approaches.

**METHODS:** We conducted dorsal hand access (trans-snuff box) for angiography and/or angioplasty on 235 patients, and trans-palmar access (superficial palmar branch of ulnar artery) on 175 patients in 3 hospitals in Isfahan City, Iran.

**RESULTS:** In 221 patients out of 235 ones (94.1%) [men: 76.5%, age: 57.4 ± 10.4 (years); women: 23.5%, age: 62.4 ± 9.5 (years)], our procedure through snuff box (dorsal hand) was successfully performed. In 159 patients out of 175 ones (90.8%) [men: 76.0%, age: 58.1 ± 10.5 (years); women: 24.0%, age: 61.2 ± 9.6 (years)], our procedure through palmar artery was successfully performed. In total, the evaluated patients had mild pain (3.4% for snuff box, and 4.5% for palmar), ecchymosis in distal forearm (5.1% for snuff box, and 2.8% for palmar), with no major complications even one (amputation, infection, thrombosis, need for surgery, hand dysfunction, nerve palsy, and so forth). In addition, percutaneous coronary intervention (PCI) was done in 28.9% and 18.2% of cases via snuff box and palmar approaches, respectively. Meanwhile, hemostasis was very fast and easy with discharge time equivalent to other upper limb accesses.

**CONCLUSION:** Although our procedures are at their early stages with about a follow-up period of 3-15 months, more researches are recommended to be conducted in forthcoming months and years, and this new innovative approaches could be suggested safe, feasible, and reliable with low complications.

**Keywords:** Coronary Angiography, Coronary Angioplasty, Trans-Palmar Approach, Trans-Snuff Box Approach, Distal Accesses, Novel Accesses

*Date of submission:* 24 Dec. 2017, *Date of acceptance:* 26 Feb. 2018

#### Introduction

Angiography and percutaneous coronary intervention (PCI) through arteries of the upper extremities is superior to femoral approach, and is on a rise due to less bleeding, easier practice of hemostasis, more patient convenience, shorter procedure time, lower cost imposed to patients and health system, and shorter period of hospitalization.<sup>1-8</sup> In addition, patients will sooner restore their routine physical activity in case of an

upper extremity approach.<sup>4,9</sup>

Currently, the most classic and routine method is trans-radial, suggested and conducted initially by Campeau et al. in 1989, followed shortly thereafter by the first trans-radial coronary stenting by Kiemeneij and Laarman in 1993, and has been done for more than two decades by other researchers and operators.<sup>4,10</sup>

Artery size, anatomical variations, arterial loop, hypoplasia, radial artery occlusion (RAO), previous

1- Associate Professor, Interventional Cardiology Research Center, Cardiovascular Research Institute, Isfahan University of Medical Sciences, Isfahan, Iran

2- Cardiologist, Isfahan Cardiovascular Research Center, Cardiovascular Research Institute, Isfahan University of Medical Sciences, Isfahan, Iran

3- Professor, Cardiac Rehabilitation Research Center, Cardiovascular Research Institute, Isfahan University of Medical Sciences, Isfahan, Iran

4- Hypertension Research Center, Cardiovascular Research Institute, Isfahan University of Medical Sciences, Isfahan, Iran

5- Heart Failure Research Center, Cardiovascular Research Institute, Isfahan University of Medical Sciences, Isfahan, Iran

6- School of Nursing and Midwifery AND Young Researchers and Elite Club, Isfahan (Khorasgan) Branch, Islamic Azad University, Isfahan, Iran

7- Department of Biostatistics, School of Medicine, Isfahan University of Medical Sciences, Isfahan, Iran

Correspondence to: Farshad Roghani-Dehkordi, Email: [frdehkordi@gmail.com](mailto:frdehkordi@gmail.com)

RA harvesting for coronary artery bypass graft (CABG), and so like are the most troublesome issues with trans-radial approach.<sup>2,11,12</sup> In other words, this approach is not always successful with obligatory shift to other routes.<sup>13</sup> Although many investigators have shown that complications of trans-ulnar approach are rather equal to trans-radial approach, and the latter is suggested as an alternative to trans-radial approach,<sup>9,14,15</sup> but trans-ulnar approach has also its own difficulties and limitations; so, more innovative routes with lower complications and higher patient and operator convenience are strongly warranted.

The term “more distal accesses” was introduced for the first time by Roghani et al. as those that are more distal to wrist crease. This new concept was presented technically by Farshad Roghani-Dehkordi at the 4<sup>th</sup> International Cardiovascular Joint Congress in Isfahan in 2016<sup>16</sup> with attendance of Dr. Ferdinand Kiemeneij, Dr. Tejas Patel, and Dr. Sasko Kedev.

We hereby present two novel accesses as follows:

1. Trans-snuff box approach that was also suggested and introduced by Kaledin et al. in 2014,<sup>17</sup> Babunashvili in 2016,<sup>18</sup> Roghani-Dehkordi in 2016,<sup>16</sup> Kiemeneij in 2016,<sup>3</sup> and Latsios et al. in 2018.<sup>19</sup>

2. Trans-palmar approach that was suggested and presented for the first time worldwide by Roghani-Dehkordi at the 4<sup>th</sup> Iranian Cardiovascular Joint Congress in 2016 (Isfahan, Iran), and at the 2<sup>nd</sup> Congress of Clinical Cases in Complex Cardiovascular

Therapeutics in April 2017 (Shiraz, Iran).

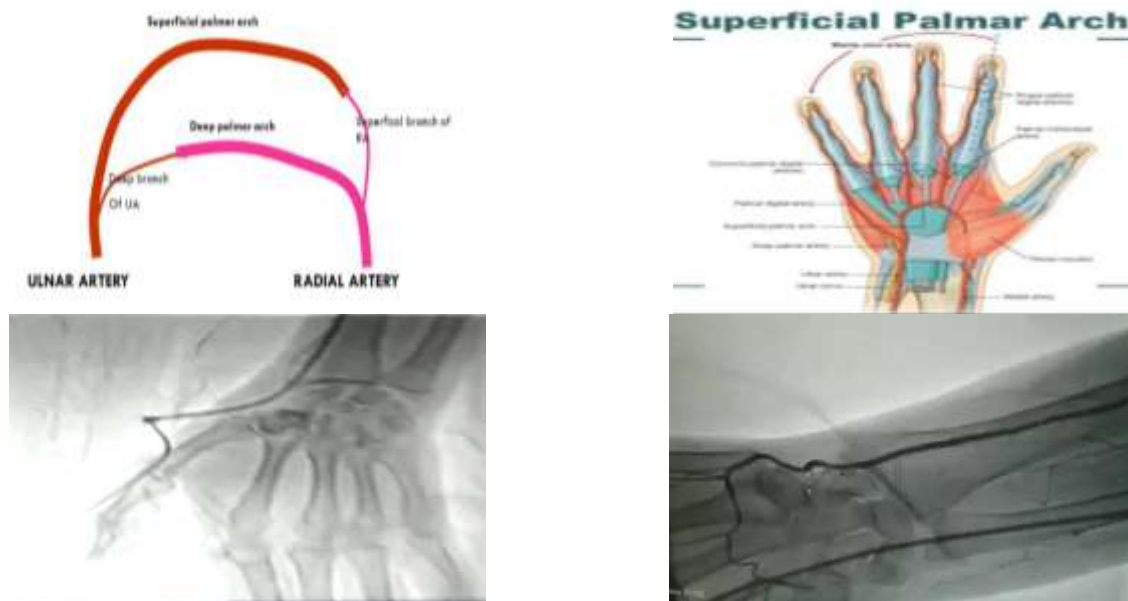
### Materials and Methods

In this multi-center and cross-sectional study, we conducted dorsal hand access (snuff box) for angiography and/or angioplasty in 235 patients during 1 Oct. 2016 till 1 Oct. 2017, and palmar approach on 175 patients during 15 Oct. 2016 till 15 Oct. 2018 in Shahid Chamran, Khorshid, and Shahid Saddoughi hospitals (Isfahan, Iran).

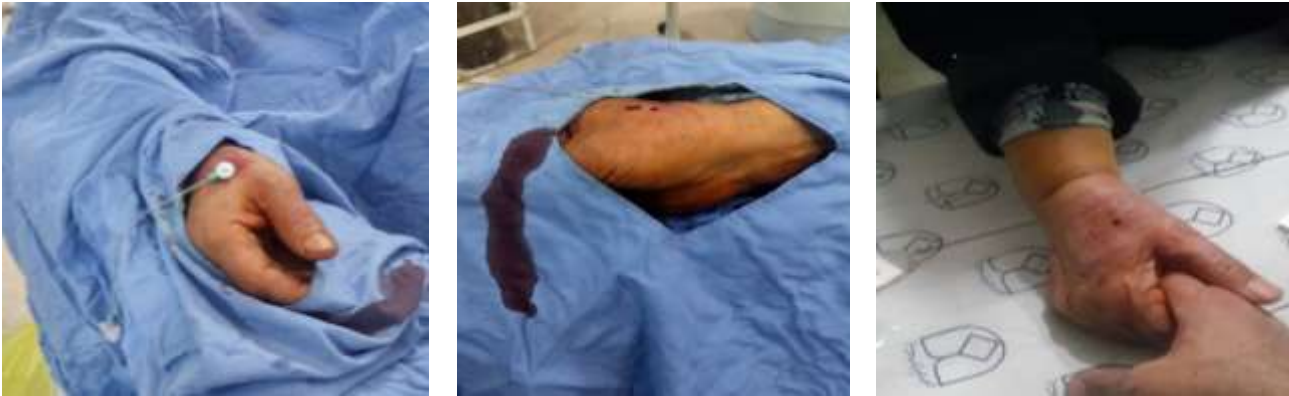Exclusion criteria for trans-snuff box and trans-palmar approaches were patients with Raynaud’s disease, upper limb vascular disorders, patients with carpal tunnel syndrome (only for palmar method), patients with neural disorders of radial nerve innervation area (for trans-snuff box) and sensory/motor disorders in territory of median and ulnar nerves (for trans-palmar approach), patients with chronic tenosynovitis, osteomyelitis, patients with marked deformities of hand, patients with recent fracture of scaphoid bone (for snuff box approach) and fractures of bones of medial aspect of the wrist (for trans-palmar approach), patients with ulnar tunnel (Guyon’s canal) syndrome (for trans-palmar approach), and patients with hypothenar hammer syndrome (for trans-palmar approach).

Before the procedure, a written and informed consent was taken by first operator.

Local anesthetic for trans-snuff box approach was lidocaine 2% [2-5 ml, subcutaneous (SC)] filling snuff cavity. Anatomically, snuff box artery is deep palmar branch of radial artery (Figure 1).



**Figure 1.** Snuff box artery is deep palmar branch of radial artery and palmar artery is superficial palmar branch of ulnar artery. The figure shows their schematic organization and their radiography.



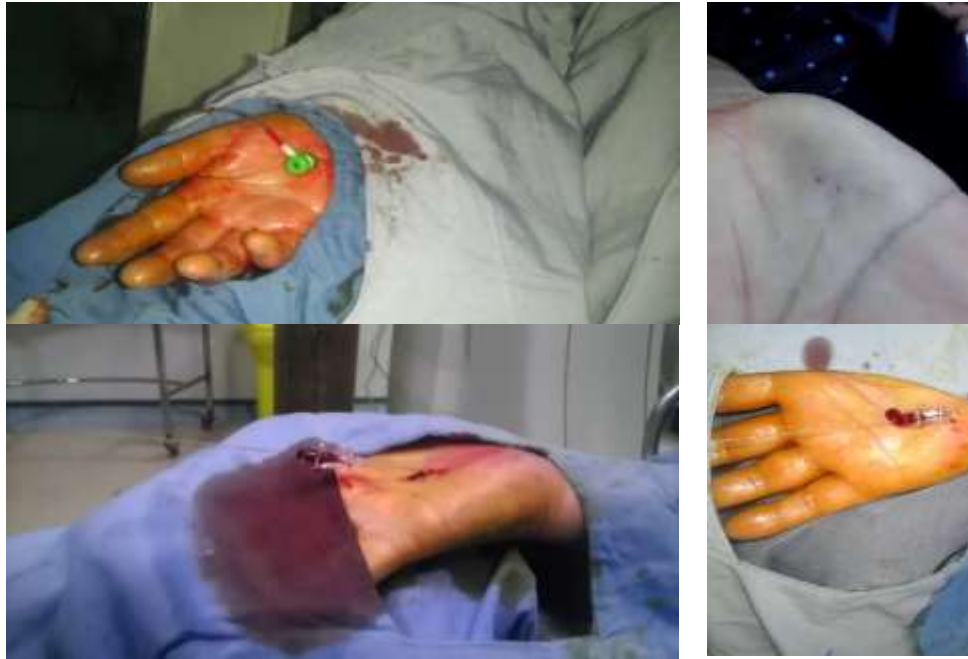**Figure 2.** The first successful coronary angiography performed on deep palmar branch of radial artery in a 65-year-old man in 1 October 2016.

The presence of an appropriate pulse in the anatomical snuff box was verified by manual palpation. We used intravenous (IV) midazolam (1-2 mg) and sublingual trinitroglycerin (TNG) (0.4 mg) in most patients (to minimize patient stress and arterial spasm).

The forearm was positioned on a soft bedding while applying ulnar deviation and semi-flexion position to the wrist (for easy palpation and puncture of snuff artery). Then, the artery was punctured with a 21G needle at an angle of 35-45 degrees. The needle was directed toward the place of strongest pulse. After arterial puncture, we passed 0.018 guide wire gently while holding semi abduction and extension position to the patient wrist (in order to minimize pressure effect of abductor pollicis longus and extensor pollicis brevis tendons). If any resistance was observed, we performed direct dye injection via the needle under fluoroscopic guide to verify the problem. Alternatively, we used 0.014 coronary guide wire in many patients in whom 0.018 inch wire had cross failure. In order to prevent damage to the tip of the introducer and sheath, which might damage the artery, a small skin incision was made, followed by introducing the 4, 5, or 6 F sheath, as needed. In the first 30 cases, we performed sheathogram in order to verify arterial anatomy. Additionally, we also used spasmolytic cocktail containing TNG (250 µg) and verapamil (2.5 mg) intra-arterially. Furthermore, we applied unfractionated heparin (2500-5000 IU) as anticoagulant. For arterial hemostasis, we immediately removed the sheath with local compression using contralateral thumb over puncture site, while other four fingers under patient wrist for 10-15 minutes (for initial hemostasis) and application of pressure using bandage packs for

completion of hemostasis (1-2 hours) (Figure 2). Local anesthetic for trans-palmar approach was subcutaneous lidocaine 2% (5 -10 ml) 1 inch proximal to pisiform bone and lateral to the tendon of flexor carpi ulnaris 15 minutes before the procedure. In some patients additional, lidocaine needed which was infiltrated subcutaneously distal to pisiform bone. Anatomically, palmar artery is superficial palmar branch of ulnar artery (Figure 1).

In trans-palmar approach, about 50% of cases were eligible for the operation according to clinical criteria like good palpable pulse. In about 70-80% out of this population, puncture was successful regarding guide wire and sheath insertion. Globally, in about one-third of all patients the procedure would be successful. Criteria of successful procedure were older age, high body mass index (BMI) (obese individuals), athletes, workers, and a history of previous radial occlusion and weak radial pulse in elderly. Technically, palmar artery is highly spastic, and for this reason, it was essential to sedate all the patients before the procedure. For this purpose, we used midazolam (1-2 mg) and sublingual TNG (0.4 mg). Additionally, we used spasmolytic cocktail intra-sheath containing TNG (250 µg) and verapamil (2.5 mg). Besides, we used heparin (2500-5000 IU) as anticoagulant. For this approach, patient's arm was positioned at 45 degrees and the hand was held in mildly extended position (about 20-30 degrees) with avoidance of hyperextension to prevent arterial stretching and collapse. The puncture site (medial aspect of palmar surface 1 cm distal and lateral to pisiform bone and about 1 inch distal to wrist crease) was gently examined for optimal anesthesia with insulin needle and additional lidocaine infiltrated locally (if needed).



**Figure 3.** The first successful coronary angiography preformed on right superficial palmar branch of ulnar artery in a 64-year-old man in 15 October 2016.

Superficial palmar artery was punctured by 21G needle, and 0.018 guide wire was passed under fluoroscopy guide (skin incision was crucial before sheath insertion). Then, 4, 5, or 6 F sheath was inserted.

Arterial hemostasis for trans-palmar approach was wrist hyperextension (up to 90 degrees) for 15 minutes followed by local compression thereafter. In a few cases, especially those with PCI and 6f sheaths, we used trans-radial band in ulnar side of distal forearm (Figure 3).

### Results

In 221 patients out of 235 ones (94.1%) (men: 76.5%, age:  $57.4 \pm 10.4$  years; women: 23.5%, age:  $62.4 \pm 9.5$  years), our procedure through snuff box artery was successfully conducted. In total, the evaluated patients had ecchymosis in distal forearm (5.1%), asymptomatic snuff artery occlusion (3 cases) that was verified in one case by ipsilateral trans-palmar angiography, no hematoma even one, and no major complications (amputation, infection, thrombosis, need for surgery, hand dysfunction, nerve palsy, and so forth). In 2 patients, we observed asymptomatic RAO during 1-month follow-up period.

In 159 patients out of 175 ones (90.8%) (men: 76%, age:  $58.1 \pm 10.5$  years; women: 24%, age:  $61.2 \pm 9.6$  years), our procedure through palmar artery was successfully performed.

Complications for trans-palmar approach included hand ecchymosis (2 cases), hematoma of proximal forearm (5 cases), and hematoma of distal arm (2 cases) that were self-limited in nature with no requirement for further therapy, and had no direct association with puncture at more distal sites. In addition, transient paresis and hyposthesia was observed in 7 cases in terminal branches of ulnar nerve that appeared in 4<sup>th</sup> and 5<sup>th</sup> fingers, and completely recovered within 1-2 weeks on follow-up. We had also no event of motor paralysis, cellulitis, and persistent pain. None of the patients with hematoma had major complications (ulnar occlusion, amputation, infection, thrombosis, need for surgery, hand dysfunction, nerve palsy, and so forth). No ulnar (palmar) artery occlusion even one observed.

In addition, PCI was done in 18.2% and 28.9% of cases via palmar and snuff box approaches, respectively. Meanwhile, hemostasis was very fast and convenient for all patients with discharge time equivalent to or even shorter than other upper limb accesses (15-30 minutes in angiography group, and 1-2 hours in angioplasty group). There was no difference in hemostasis time between snuffbox and palmar group.

### Discussion

In this novel and innovative research study, we presented new accesses in the upper limb at more distal points in contrast to conventional trans-radial



and trans-ulnar approaches. We also had a follow-up on patients for 3-15 months to check possible complications of these newly presented techniques. Our experience showed the safety and feasibility of more distal accesses in the hand at anatomical snuff box and/or palmar zone. We could enumerate several benefits for these approaches. Firstly, the patient could leave the hospital after several hours with no requirement of hospitalization. Secondly, these approaches were associated with lower risk of upstream artery occlusion at the site of puncture. Thirdly, we did not observe any soft tissue injury at puncture site, damage to the vessel wall by sheath insertion, and possible trauma due to hemostatic procedures. In addition, since we did puncture a smaller and more superficial artery, less time was certainly required for establishment of hemostasis. Of additional advantage, since no extra pressure is exerted on the local veins, no congestion of the hand region is expected. Furthermore, our approaches may be strongly recommended for those cases that show signs of radial and ulnar spasm at more proximal sites. Additionally, if we had a failure in performing these more distal approaches, upstream sites are still preserved for percutaneous coronary intervention. Finally, in the case of proximal arterial occlusions, distal accesses could be used for retrograde angiography and intervention.

However, new techniques have their own limitations, and more time is certainly needed for their performance on a large-scale population with a precisely-designed follow up to check possible benefits, limitations, and complications in long term.

The patients' inconvenience and complications of trans-palmar approach were significantly lower than classic trans-ulnar approach, but the rate of patient eligibility was lower. The failure rate of trans-palmar approach was higher than classic trans-ulnar approach. In the case of access failure, we crossed over to another hand accesses. The main cause of trans-palmar access failure was vascular tortuosity, siphon at distal part of ulnar artery, and spasm, which was negotiated by 0.014 coronary guide wire in many cases during study.

One challenging and important issue with our more distal approaches is that distal arteries are smaller and thinner and for this reason, their puncture needs much more experience and learning curve. Perhaps, our methods may be difficult to be performed by newly trained operators. In contrast to our findings, McNamara *et al.* reported ischemia of the index finger and thumb secondary to thrombosis of the radial artery in the anatomical

snuff box. These researchers ascribed the complications to local inflammation and/or systemic disease.<sup>20</sup> However, there is no reason that our approaches endanger and compromise blood flow to the fingers due to existence of collateral blood vessels.

Regarding postoperative course, recovery and hemostasis was very successful with great comfort and high satisfaction of the patients. Since number of studied cases was rather low, and duration of follow-up was not long, such study with a longer follow-up and on a higher number of cases is strongly warranted. Although our procedures are at their early stages with about a follow-up period of 3-15 months, more researches are recommended to be conducted in forthcoming months and this new innovative approaches could be suggested as safe and reliable with low complications to be used for coronary angiography and/or angioplasty. However, these new approaches require thoughtful decision by operators.

### Conclusion

As a conclusion, although these new innovative approaches could be suggested safe, feasible, and reliable to be used for coronary angiography and/or angioplasty with low complications, but they are at their early stages with about a follow-up period of 3-15 months; so, more researches based on large clinical trials are recommended to be conducted in forthcoming months and years.

### Acknowledgments

Hereby, we wish to acknowledge Dr. Ferdinand Kiemeneij at Department of Cardiology (Tergooi Blaricum, Blaricum, the Netherlands) for his great scientific support during this study.

### Conflict of Interests

Authors have no conflict of interests.

### References

1. Liu J, Fu XH, Xue L, Wu WL, Gu XS, Li SQ. A comparative study of transulnar and transradial artery access for percutaneous coronary intervention in patients with acute coronary syndrome. *J Interv Cardiol* 2014; 27(5): 525-30.
2. Sallam M, Al-Riyami A, Misbah M, Al-Sukaiti R, Al-Alawi A, Al-Wahaibi A. Procedural and clinical utility of transulnar approach for coronary procedures following failure of radial route: Single centre experience. *J Saudi Heart Assoc* 2014; 26(3): 138-44.
3. Kiemeneij F. Left distal transradial access in the

- anatomical snuffbox for coronary angiography (IdTRA) and interventions (IdTRI). *EuroIntervention* 2017; 13(7): 851-7.
4. Roghani F, Shirani B, Hashemifard O. The effect of low dose versus standard dose of arterial heparin on vascular complications following transradial coronary angiography: Randomized controlled clinical trial. *ARYA Atheroscler* 2016; 12(1): 10-7.
  5. Costa F, van Leeuwen MA, Daemen J, Diletti R, Kauer F, van Geuns RJ, et al. The rotterdam radial access research: Ultrasound-based radial artery evaluation for diagnostic and therapeutic coronary procedures. *Circ Cardiovasc Interv* 2016; 9(2): e003129.
  6. Kumar AJ, Jones LE, Kollmeyer KR, Feldtman RW, Ferrara CA, Moe MN, et al. Radial artery access for peripheral endovascular procedures. *J Vasc Surg* 2017; 66(3): 820-5.
  7. Maniotis C, Koutouzis M, Andreou C, Lazaris E, Tsiafoutis I, Zografos T, et al. Transradial approach for cardiac catheterization in patients with negative Allen's test. *J Invasive Cardiol* 2015; 27(9): 416-20.
  8. Rao SV, Kedev S. Approaching the post-femoral era for coronary angiography and intervention. *JACC Cardiovasc Interv* 2015; 8(4): 524-6.
  9. Roghani-Dehkordi F, Hadizadeh M, Hadizadeh F. Percutaneous trans-ulnar artery approach for coronary angiography and angioplasty; A case series study. *ARYA Atheroscler* 2015; 11(5): 305-9.
  10. Roghani F, Tajik MN, Khosravi A. Compare complication of classic versus patent hemostasis in transradial coronary angiography. *Adv Biomed Res* 2017; 6: 159.
  11. Valsecchi O, Vassileva A, Musumeci G, Rossini R, Tespili M, Guagliumi G, et al. Failure of transradial approach during coronary interventions: Anatomic considerations. *Catheter Cardiovasc Interv* 2006; 67(6): 870-8.
  12. Dehghani P, Mohammad A, Bajaj R, Hong T, Suen CM, ShariEFF W, et al. Mechanism and predictors of failed transradial approach for percutaneous coronary interventions. *JACC Cardiovasc Interv* 2009; 2(11): 1057-64.
  13. Biondi-Zoccai G, Sciahbasi A, Bodi V, Fernandez-Portales J, Kanei Y, Romagnoli E, et al. Right versus left radial artery access for coronary procedures: an international collaborative systematic review and meta-analysis including 5 randomized trials and 3210 patients. *Int J Cardiol* 2013; 166(3): 621-6.
  14. Dahal K, Rijal J, Lee J, Korr KS, Azrin M. Transulnar versus transradial access for coronary angiography or percutaneous coronary intervention: A meta-analysis of randomized controlled trials. *Catheter Cardiovasc Interv* 2016; 87(5): 857-65.
  15. Gokhroo R, Kishor K, Ranwa B, Bisht D, Gupta S, Padmanabhan D, et al. Ulnar artery interventions non-inferior to radial approach: Ajmer ulnar artery (AJULAR) intervention working group study results. *J Invasive Cardiol* 2016; 28(1): 1-8.
  16. Roghani-Dehkordi F. Merits of more distal accesses in the hand for coronary angiography and intervention. Proceedings of the 4<sup>th</sup> International Cardiovascular Joint Congress in Isfahan; 2016 Nov. 24-25; Isfahan, Iran.
  17. Kaledin A, Kochanov I, Podmetin P, Ardeev VN. Distal radial artery in endovascular interventions [Online]. [cited 2017]; Available from: URL: <https://www.researchgate.net/publication/319162208>
  18. Babunashvili A. Novel snuff-box technique for trans-radial approach: Let's go distal. Proceedings of the Aim-Radial 2016; 2016 Sep. 23-22; Budapest, Hungary.
  19. Latsios G, Toutouzas K, Synetos A, Vogiatzi G, Papanikolaou A, Tsiamis E, et al. Left distal radial artery for cardiac catheterization: Insights from our first experience. *Hellenic J Cardiol* 2018.
  20. McNamara MG, Butler TE, Sanders WE, Pederson WC. Ischaemia of the index finger and thumb secondary to thrombosis of the radial artery in the anatomical snuffbox. *J Hand Surg Br* 1998; 23(1): 28-32.

**How to cite this article:** Roghani-Dehkordi F, Hashemifard O, Sadeghi M, Mansouri R, Akbarzadeh M, Dehghani A, et al. **Distal accesses in the hand (two novel techniques) for percutaneous coronary angiography and intervention.** *ARYA Atheroscler* 2018; 14(2): 95-100.